

Immediate Implant Placement in the Upper Maxilla with IPG-DET Technique in Both Posterior Regions

Georgakopoulos P Ioannis^{1,3*}, Zafeiri Triantafillio^{1,2}, Melissinou Apollonia^{1,2}, Inchingolo Francesco³, Georgakopoulos Panagiotis¹ and Dipalma Gianna³

¹WAGRO (World Academy of Growth Factors and Stem Cells in Dentistry), Athens, Greece

²Postgraduate student, Interdisciplinary Department of Medicine, University of Bari Aldo Moro, Bari, Italy

³Professor, Interdisciplinary Department of Medicine, University of Bari Aldo Moro, Bari, Italy

***Corresponding Author:** Georgakopoulos P Ioannis, WAGRO (World Academy of Growth Factors and Stem Cells in Dentistry), Athens, Greece.

Received: October 25, 2019; **Published:** November 19, 2019

Abstract

Introduction: Nowadays there has been an increasing number of people who require quick, fixed and aesthetic prosthodontic treatment including implants. For this reason, dentists need to apply more simplified procedures during surgery. The IPG-DET [1] is a pioneering minimal invasive technique for implant placement and bone regeneration in the sinus without the need for sinus floor elevation.

Case Report: In this case, surgery proceeds in one session, 10 teeth were extracted from the upper maxilla and 8 implants were placed (B&B dental implants srl, Italy). The implants in posterior region were placed using the protocol of IPG-DET. In this case report only these implants will be examined. Beginning the procedure, patient's blood was collected into 8 ml sterile tubes (Vacuette) (Greiner Bio-one). The tubes were placed immediately into the Medifuge MF200 cell separation device (Silfradent s.r.l.-Italy), according to the CGF protocol [2,3]. Next appeared three blood fractions. In the middle layer (Buffy coat) a large number of growth factors and stem cells CD34+ was aggregated. These growth factors were used for the IPG-DET technique through the forms of: CGF matrix (highly concentrated growth factors and stem cells) and the LPCGF (liquid phase concentrated growth factors). Furthermore, alloplastic bone grafting material (Nonocor plus B&B dental implants srl, Italy) was used.

Conclusion: To sum up, over the years the IPG-DET becomes increasingly reliable and is preferred compared to the prevailing method of SFE procedure with all its known complications [4]. The implementation of IPG-DET, after patient's consent, is based on a specific protocol and prerequisite training, while it remains to be evaluated the long-term implant stability and also the quality and quantity of the new bone formation into the sinus with further studies.

Keywords: Dental Implants; Full Arch Rehabilitation; Immediate Implant Placement; Sinus Floor Elevation; IPG-DET; Titanium Mesh

Abbreviations

SFE: Sinus Floor Elevation [5]; IPG-DET: Placement of implants inside the sinus cavity with intentional perforation of the sinus membrane and simultaneous placement of concentrated growth factors and bone graft material of our choice [1]; CGF: Concentrated Growth Factors [6] They accelerate new bone formation.

CD34: is a transmembrane glycoprotein expressed extensively on blood vessels and hematopoietic stem cells [7]

Introduction

This case report presents the application of an innovative minimal invasive technique for implant placement and bone regeneration into the Sinus cavity, avoiding the elevation of the sinus floor membrane. The patient needed implant treatment for full-arch rehabilitation. The patient was 55 years old and had a free medical history, but with very poor oral hygiene.

Figures 1 to 3 present the clinical and x-ray examination. On the upper jaw existed the teeth #17, #16, root of #14, #12, #21, #22, #24, #25, #26 and #27. There were two bridges one from #14 to #21 and the second from #22 to #25. The periodontal assessment indicated poor survival rate. The treatment plan was to extract all teeth and immediately put a total of 8 implants in the maxilla, the 5 of them in the Sinus. On both posterior sites of the maxilla, bone augmentation was needed. The chosen technique for the posterior maxilla was the IPG-DET. In this case report only these implants will be examined.

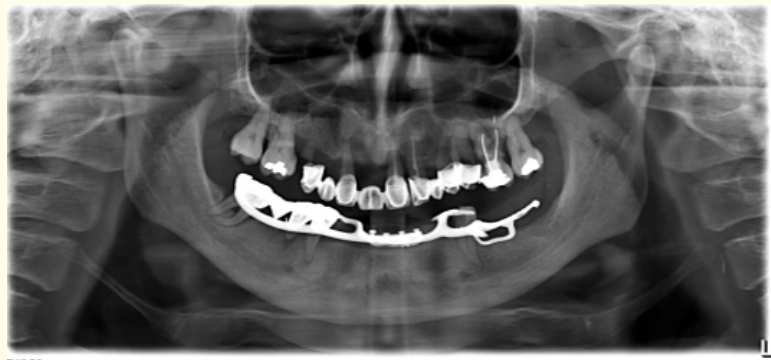


Figure 1: Pre-op X-ray.

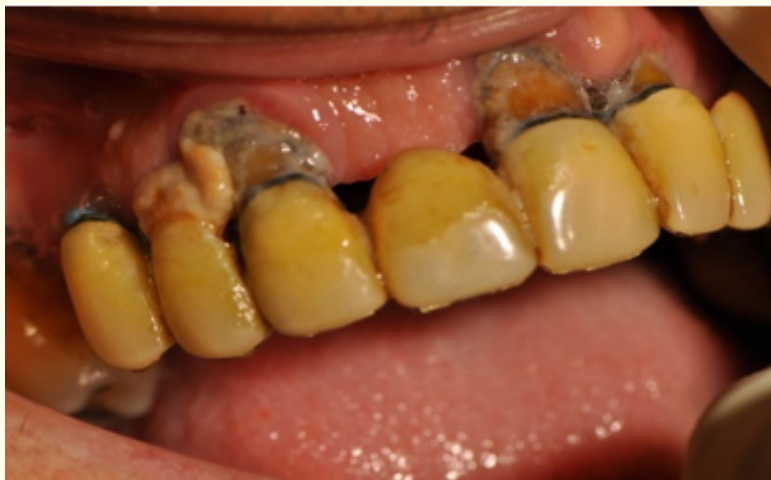

Figure 2: Pre-op clinical image a.

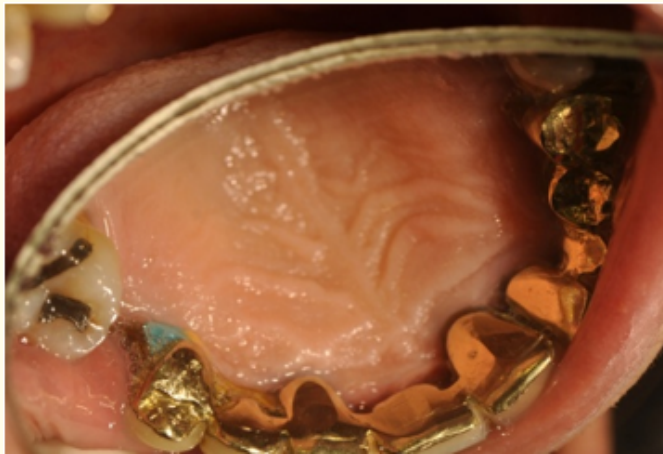


Figure 3: Pre-op clinical image b.

Materials and Methods

First of all, the following extractions was performed: #17, #16, #14, #12, #21, #22, #24, #25, #26, #27. It was decided to place eight implants (B&B Dental implant srl, Italy). In these case report we will examine only the implants in the posterior regions which were placed using the protocol of IPG-DET. The implants were: 4,0/10 mm at region #17, 4,0/10mm at region #16, 3,5/10 mm at region #24, 4,0/10 mm at region #26, 4,0/10 mm at region #27. Moreover, the implant 4,0/10 mm in region #26 was stabilized with a titanium mesh (B&B Dental implant srl, Italy). This membrane offers better primary stability to the implant.

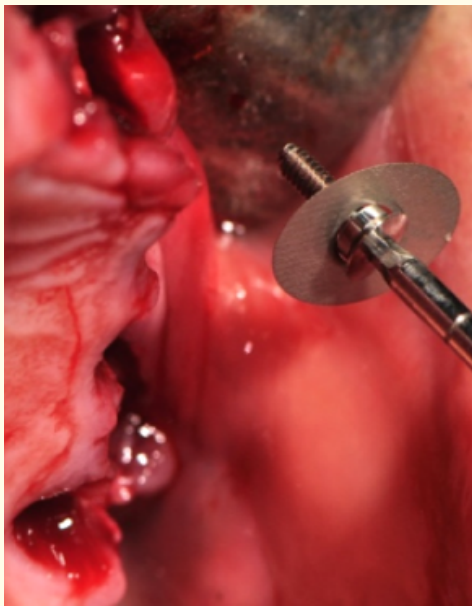


Figure 4: B&B titanium mesh during IPG-DET surgery procedures a.

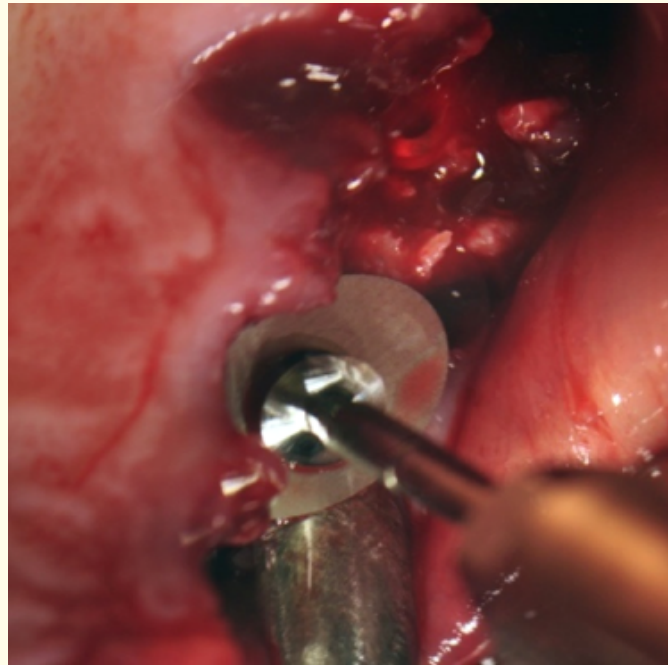


Figure 5: B&B titanium mesh during IPG-DET surgery procedures b.

At first, blood has been collected from the patient using eight 9 ml sterile tubes, (Vacuate) (Figure 6). These tubes were placed immediately into the Medifuge MF200 cell separation device, (Silfradent srl, Italy), according to the CGF protocol [8] (Figure 7).

At the end of the process, there were three blood fractions: (1) the upper platelet poor plasma (PPP) layer, (2) the middle buffy coat with concentrated growth factors (CGF), (3) the lower red blood cell (RBC) layer [3]. In other authors, regarding the middle layer there is a distinction between the very large and dense polymerized fibrin buffy coat on top and of a liquid phase containing the white blood cells on the bottom of the previous phase [9]. "A large number of growth factors and stem cells CD34+ are aggregated in this middle layer (between the dense polymerized fibrin buffy coat and the upper 3-4 mm of red blood corpuscles mass of the bottom layer (Figure 8-10).

This growth factor-rich segment was used for the technique and was separated from the rest of the red corpuscles using scissors in order to obtain the CGF-CD34+ matrix [10]. The osteotomy was extended through the full available bone height. Drilling was done with the initial drill (2,1 drill), followed by Duravit bone compactor - expanders (B&B srl Italy) until intentionally perforate the sinus membrane. A CGF matrix was inserted through the osteotomy site and membrane perforation into the sinus, using a fibrin injector (Silfradent, Italy). Another CGF matrix (highly concentrated growth factors and stem cells) was then cut into small pieces and mixed with a small quantity of the alloplastic bone grafting material Novocore Plus (0,5 mg, by B&B srl) (Figure 11). This mixture is then placed within the osteotomy site. Before placing each implant in the osteotomy site, it was first carefully and completely immersed into the LPCGF (liquid phase concentrated growth factors) in order to create a "bio-energetic membrane" around the implant. The LPCGF was prepared by squeezing one CGF matrix using the CGF forceps (Silfradent srl Italy) and was collected in a sterilized container for immersion of all implants. The implants were then placed using a hand wrench and the insertion torque value was measured to be between 25 Ncm² and 30 Ncm². Low insertion torque value (ITV) was expected since the bone height at all implant sites was very small [10].

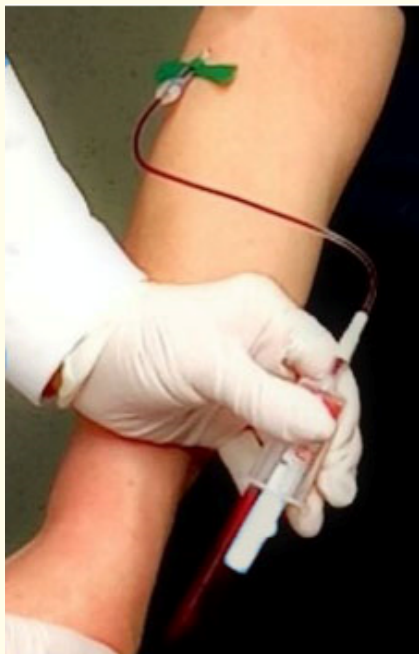

Figure 6: Blood collection.



Figure 7: Medifuge MF200 device.




Figure 8: Tubes after centrifugation with CGF.

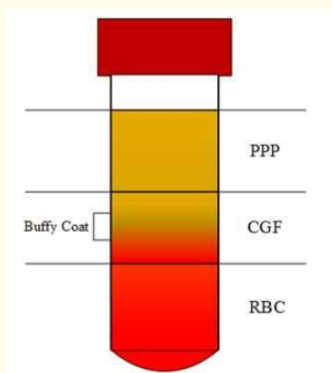


Figure 9: The three blood fractions PPP - CGF - RBC.




Figure 10: CGF matrix.



Figure 11: Novocor plus B&B and CGF grow factors before their mixing.

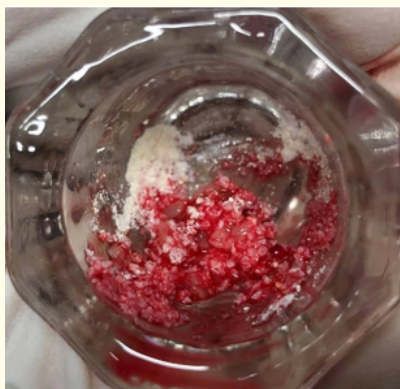


Figure 12: Novocor plus B&B and CGF grow factors after their mixing.

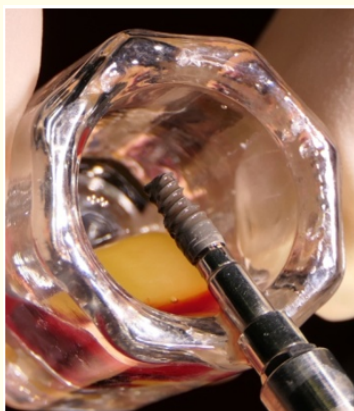

Figure 13: Implant completely immersed into LPCGF.

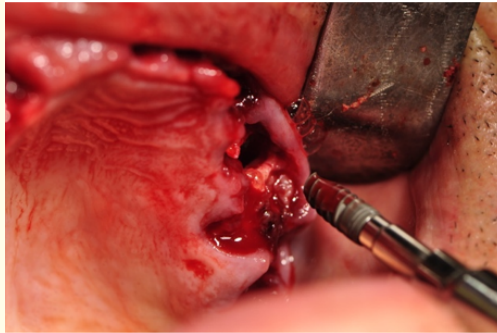


Figure 14: Implants placed using a hand wrench.

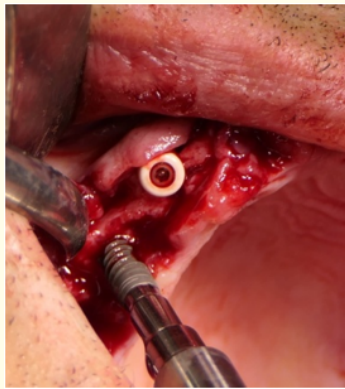


Figure 15: Insertion torque value was measured between 25 Ncm² and 30 Ncm².

Results

None of the patients' sinuses presented any postoperative complications of infection.

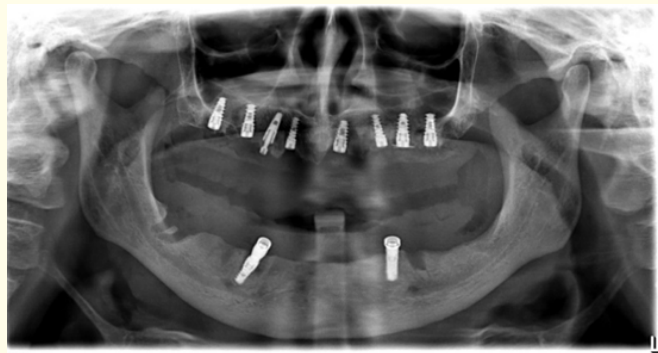

Figure 16: Post-op X-ray.

Discussion

Nowadays tooth loss leads patients to full arch rehabilitation with immediate implant placement. Clinical research shows that the dentists face difficulties when planning to place implants in the posterior region of the maxilla, because usually extensive bone resorption is present and low bone quality and density [11]. For this reason we need a technique that gives the dentist the ability to place implants in these regions of the maxilla in less time and cost. The IPG-DET is a pioneering regenerative technique of minimal invasive implant placement and bone regeneration in the sinus without the need for sinus floor elevation (SFE) [1,12]. This technique uses CGF-CD34+ Matrix concentrated growth factors and stem cells with simultaneous intentional perforation of the Schneider's membrane. The aim of this procedure is:

- To improve the regenerative sinus techniques
- To block the oroantral communication
- To use a CGF bioactive membrane for better osseointegration
- To reduce the time needed for implant placement
- To reduce bleeding.

To sum up, over the years the use of minimally invasive IPG-DET becomes increasingly reliable and acceptable compared to the prevailing method of SFE procedure.

Conclusion

To sum up, over the years the IPG-DET becomes increasingly reliable and is preferred compared to the prevailing method of SFE procedure with all its known complications [4]. The implementation of IPG-DET, after patient's consent, is based on a specific protocol and prerequisite training, while it remains to be evaluated the long-term implant stability and also the quality and quantity of the new bone formation into the sinus with further studies.

Bibliography

1. Georgakopoulos PI., *et al.* "“IPG” DET Minimal Invasive Sinus Implant Placement and Grafting without Sinus Floor Elevation - The Evolution of New Age Concepts". *Dentistry* 6.5 (2016).
2. Bonazza Veronica., *et al.* "Biological Characterization and In Vitro Effects of Human Concentrated Growth Factor Preparation: An Innovative Approach to Tissue Regeneration". *Biology and Medicine* 7.5 (2015).
3. Honda Hirotsugu., *et al.* "Bone Tissue Engineering with Bone Marrow-Derived Stromal Cells Integrated with Concentrated Growth Factor in Rattus Norvegicus Calvaria Defect Model". *Journal of Artificial Organs* 16.3 (2013): 305-331.
4. Fugazzotto Paul., *et al.* "Complications When Augmenting the Posterior Maxilla". *Dental Clinics of North America* 59.1 (2015): 97-130.
5. Boyne PJ and R A James. "Grafting of the Maxillary Sinus Floor with Autogenous Marrow and Bone". *Journal of Oral Surgery* 38.8 (1980): 613-616.
6. Pirpir Cagasan., *et al.* "Evaluation of Effectiveness of Concentrated Growth Factor on Osseointegration". *International Journal of Implant Dentistry* 3.1 (2017): 7.
7. Rodella Luigi Fabrizio., *et al.* "Growth Factors, CD34 Positive Cells, and Fibrin Network Analysis in Concentrated Growth Factors Fraction". *Microscopy Research and Technique* 74.8 (2011): 772-777.

8. Bernardi Mummolo., *et al.* "Histological Characterization of Sacco's Concentrated Growth Factors Membrane". *International Journal of Morphology* 35.1 (2006): 114-119.
9. Sohn Dong-Seok., *et al.* "Bone Regeneration in the Maxillary Sinus Using an Autologous Fibrin-Rich Block With Concentrated Growth Factors Alone". *Implant Dentistry* 20.5 (2011): 389-395.
10. Ioannis Georgakopoulos., *et al.* "A Case-Study of Seven Dental Implants Placed in the Maxillary Sinus with Intentional Schneiderian Membrane Perforation". *The Journal of Implant and Advanced Clinical Dentistry* 6.1 (2014): 9-19.
11. Kalavagunta Reddy. "Extensive Maxillary Sinus Pneumatization". *Rhinology* 41.2 (2003): 113-117.
12. Panagiotis I Georgakopoulos., *et al.* "The IPG-DET Technique: Innovative Approach of Implant Placement and Grafting in the Sinus". *Dental News* 26.1 (2019): 12-19.

Volume 18 Issue 12 December 2019

©All rights reserved by Georgakopoulos P Ioannis., *et al.*