

Non-Syndromic Multiple Hyperdontia with Mandibular Predominance in Monozygotic Twins

Daniel Alfonso Rey¹, Gabriel Durán-Rodríguez², Andrés Gómez-Delgado^{3*} and Jaime Castro-Núñez⁴

¹Former Oral and Maxillofacial Surgeon, Hospital Simon Bolivar, Bogota, Colombia

²Oral and Maxillofacial Surgeon, Clinica Versalles, Clínica de la Presentación, Manizales, Colombia

³Oral and Maxillofacial Surgeon, Hospital San Juan de Dios, Hospital UNIBE, San José, Costa Rica and Professor, Oral and Maxillofacial Surgery Residency Program, Universidad El Bosque, Bogotá, Colombia

⁴Oral and Maxillofacial Surgery Resident, University of Puerto Rico – Medical Sciences Campus, Postgraduate Program in Oral and Maxillofacial Surgery, San Juan, PR, USA and Researcher, School of Dentistry, Institution Universitaria Colegios de Colombia, Bogotá, Colombia

***Corresponding Author:** Andrés Gómez-Delgado, Oral and Maxillofacial Surgeon, Hospital San Juan de Dios, Clínica UNIBE, San José, Costa Rica, Colombia.

Received: October 09, 2019; **Published:** November 06, 2019

Abstract

The prevalence rate of supernumerary teeth varies between 0.1 and 3.6% on permanent dentition and it is usually associated to conditions such as cleidocranial dysostosis or Garner's syndrome. Males are more affected than females, with rates between 2:1 and 6:1. Even though the etiology of supernumerary teeth remains unclear or not completely understood, several theories have been given for the different manifestations based on epidemiological investigations. Inheritance or hyperactivity of the dental lamina has been suggested as possible causes of this condition. There are only few cases of supernumerary teeth in twins reported in literature. The presence of this condition in the mandibular bone is even more unusual. The aim of this article is to present a case of multiple supernumerary teeth in the maxillary and mandibular region in 2 Colombian twins with a 1-year follow-up.

Keywords: Monozygotic Twins; Hyperdontia; Supernumerary Teeth (STs)

Introduction

The pathologic condition characterized by the presence of erupted or unerupted extra teeth, known as hyperdontia or supernumerary teeth (STs), is widely described in the literature associated or not to syndromic patients. There is some evidence relating this condition to familial predisposition, although the exact etiology, is unclear [1]. The possibility of an autosomal dominant trait with lack of penetrance in some generations or a combination of genetics and environmental factors has been suggested [2,3].

The prevalence of a single supernumerary tooth ranges from 0.1 to 3.6%. Multiple extra teeth, nevertheless, is a much less common finding (0.06%). As it can be seen, STs usually presents as an isolated feature, but when there is more than one tooth involved, there are more chances to relate the condition to syndromes such as cleidocranial dysplasia, Gardner syndrome or Nance-Horan syndrome [4-6].

The occurrence of supernumerary teeth in twins is a very unusual situation. Papers addressing this matter, therefore, are scarce. Reporting dental features on identical twins are of much interest since they contribute to a better understanding of interactions between environmental and genetic influences on teeth development.

Cases reporting multiple STs in the mandibular region are rare, especially in monozygotic twins. The aim of the present work is to present a case of multiple mandibular STs in monozygotic Colombian twins seen at the Oral and Maxillofacial Surgery Department, Hospital Simón Bolívar.

Report of Case

First patient

A 14-year-old male patient presented to the Oral and Maxillofacial Surgery Department at Hospital Simón Bolívar (OMSD-HSB) in Bogota, Colombia with the chief complaint of missing maxillary and mandibular teeth. Familial and medical history did not disclose any systemic condition.

Extra oral examination did not reveal any abnormality. Clinical intraoral examination showed missing teeth in the maxillary and mandibular arches. A panoramic radiograph brought by the patient revealed a total of 12 STs and 7 impacted teeth (Figure 1). Cone-beam computed tomography (CBCT) was ordered to evaluate the exact number and position of STs.

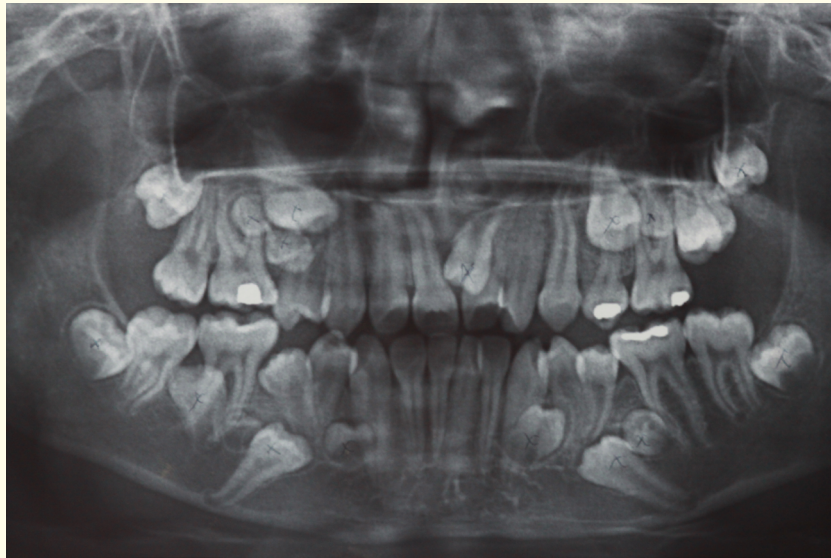


Figure 1: Case 1. This panoramic radiograph revealed 5 impacted supernumerary maxillary teeth, 2 premolars, and 2 third molar impacted teeth. In the mandible, 7 supernumerary teeth, 1 premolar impacted, and 2 third molar impacted teeth are seen.

Second patient

The second patient was similar to the first one, except that he had 3 more STs. Clinical intraoral examination showed missing teeth in the maxillary and mandibular arches. His panoramic radiograph revealed a total of 15 STs and 5 impacted teeth (Figure 2). Cone-beam computed tomography (CBCT) was ordered to evaluate the exact number and position of STs.

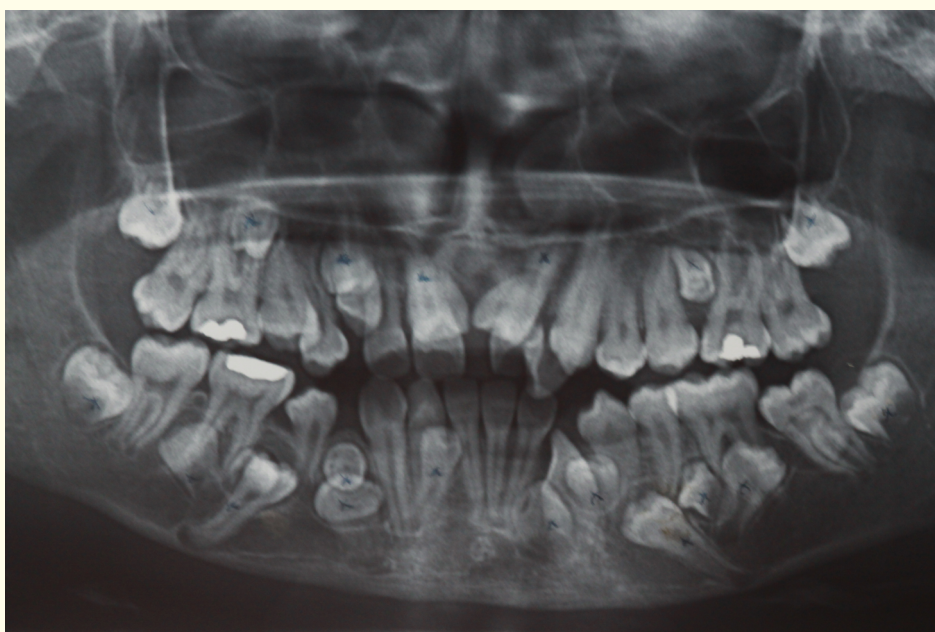


Figure 2: Case 2. Panoramic radiograph showing 5 maxillary STs, and 2 impacted third molars. In the mandible, 9 supernumerary teeth, 1 premolar, and 2 third molars impacted teeth are seen.

Clinical management

Patients were referred to the Department of Genetics to rule out a syndromic condition. The geneticist confirmed that the 14-year-old twin brothers were not syndromic. The parents of the both patients were informed of the presence of these STs and given the pros of surgical removal versus leaving them in position. They opted for surgical removal of STs and impacted teeth. One month later, after informed consent and with patients under general anesthesia, supernumerary and impacted teeth were removed using buccal, palatal and lingual flaps with bone was removed using a 702 low-speed bur (Figures 3 and 4). A 1-year-follow-up shows no signs of paresthesia, excellent bone healing, and adequate local conditions for orthodontic alignment (Figures 5 and 6).

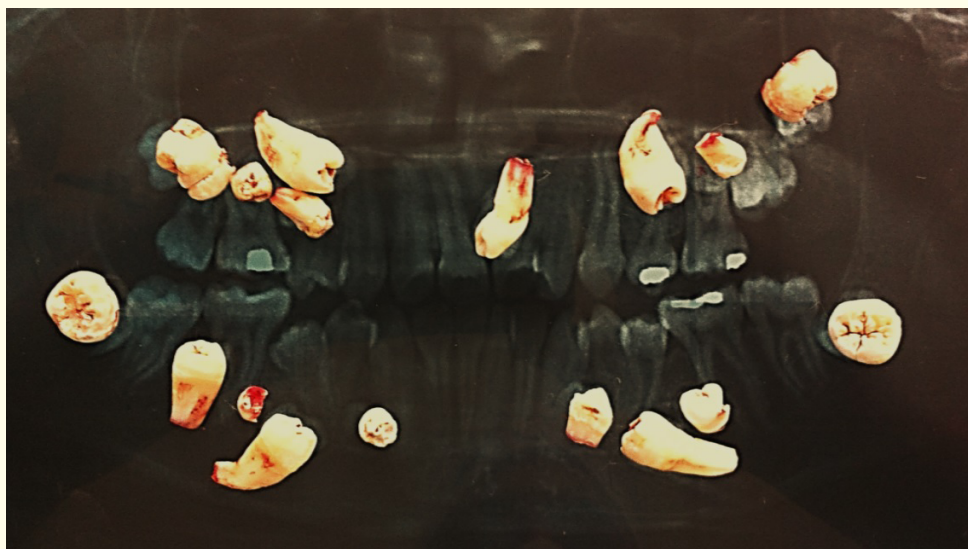

Figure 3: Case 1. Extracted STs and impacted teeth over the radiograph after surgical removal.



Figure 4: Case 2. Extracted STs and impacted teeth over the radiograph after surgical removal.

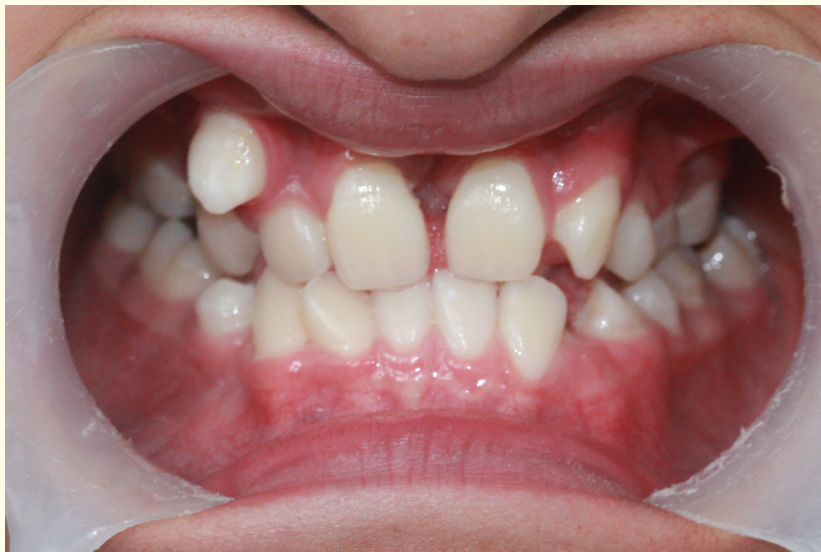

Figure 5: Case 1. Clinical appearance after 1-year follow-up.

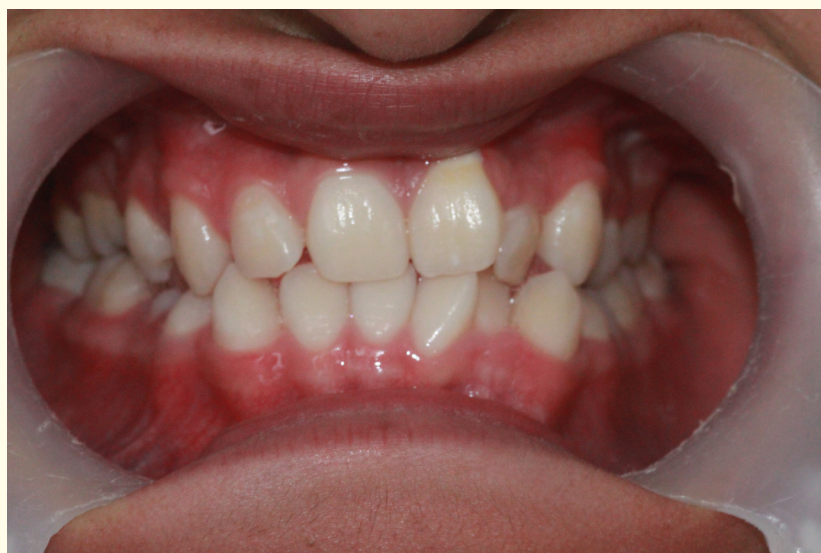

Figure 6: Case 2. Clinical appearance after 1-year follow-up.

Discussion

STs have been classified according to morphology (conical, tuberculate, supplemental); number (single or multiple); position (palatal or labial); condition (erupted or impacted); and syndromic or associated to other diseases [7]. In this particular case, we found non-syndromic twins with multiple, impacted, conical and unrooted forms of STs placed all over the jaws, with mandibular predominance.

Mesiodens, which is by far the most common form of STs, are usually located between the 2 central upper incisors. Surprisingly, no mesiodens was found in our patients.

Unlike the case recently reported by Liu and Chen [8], who described a case in twins in which only 1 of them presented 2 impacted mandibular STs, our case shows 16 mandibular STs (7 in case 1 and 9 in case 2), which is a significant amount considering the prevalence previously reported in twins, which is 0.03% [9]. Of note, finding STs in both the maxilla and mandible in monozygotic twins, as in our case, is a frank oddity.

Around 90% of all STs are found in the premaxilla, whereas less than 5% are located in the mandibular premolar area [10,11]. Our first patient (case 1) had 12 STs: 5 were in the upper jaw (1 in the premaxilla) and 7 were in the mandible. This means that 42% of STs are maxillary, while 58% are mandibular. The second patient (case 2) had 14 STs: 5 were in the upper jaw (2 in the premaxilla) and 9 in the mandible. This means that 36% of STs are maxillary, while 64% were in the lower jaw.

Although some articles report the presence of STs in non-syndromic monozygotic twins, our case differs from them in some aspects. First of all, the higher incidence of mandibular STs, especially in the anterior zone. Secondly, both twins had different amount of mesiodens. The fact that both patients had different amount of STs suggests that heredity may play a key role in the development of STs.

Conclusion

The commonest complications related to STs are root resorption, delayed or ectopic eruption of permanent teeth, and displacement of teeth. In this particular case, complications included alteration of dental eruption, principally in the premolar zone. Extraction under general anesthesia of these STs was performed and both patients referred to an orthodontist.

Conflict of Interests

None.

Bibliography

1. Wang X., *et al.* "Autosomal dominant inheritance of multiple supernumerary teeth". *International Journal of Oral and Maxillofacial Surgery* 36.8 (2007): 756-758.
2. Sedano HO and Gorlin RJ. "Familial occurrence of mesiodens". *Oral Surgery, Oral Medicine, Oral Pathology* 27.3 (1969): 360-361.
3. Brook AH. "A unifying aetiological explanation for anomalies of human tooth number and size". *Archives of Oral Biology* 29.5 (1984): 373-378.
4. Yusof WZ. "Non-syndromic multiple supernumerary teeth: literature review". *Journal of the Canadian Dental Association* 56.2 (1990): 147-149.
5. Açıkgöz A., *et al.* "Characteristics and prevalence of non-syndromic multiple supernumerary teeth: a retrospective study". *Dentomaxillofacial Radiology* 35.3 (2006): 185-190.
6. Bailleul-Forestier I., *et al.* "The genetic basis of inherited anomalies of the teeth. Part 2: Syndromes with significant dental involvement". *European Journal of Medical Genetics* 51.5 (2008): 383-408.
7. Brook AH. "Dental anomalies of number, form, and size: their prevalence in British schoolchildren". *Journal of the International Association of Dentistry for Children* 5.2 (1974): 37-53.

8. Liu J-F and Chen H-L. "Multiple maxillary and mandibular supernumerary teeth in twins: 5-year follow-up". *Journal of Dental Sciences* 9.2 (2014): 195-198.
9. Hyun HK., *et al.* "Nonsyndromic multiple mandibular supernumerary premolars". *Journal of Oral and Maxillofacial Surgery* 66.7 (2008): 1366-1369.
10. Choi WKL., *et al.* "Bilateral mesiodentes of identical twins: a case report". *Zhonghua Ya Yi Xue Hui Za Zhi* 9.3 (1990): 116-121.
11. Nazif MM., *et al.* "Impacted supernumerary teeth: a survey of 50 cases". *Journal of the American Dental Association* 106.2 (1983): 201-204.

Volume 18 Issue 12 December 2019

©All rights reserved by Andrés Gómez-Delgado., *et al.*