

## Topical Vitamin C, an Evolutionary Approach for the Treatment of Plaque Induced Gingivitis: A Randomized Controlled Clinical Trial

Daniah Alyahya<sup>1\*</sup>, Atheer Alhomid<sup>1</sup>, Areen Aljuhani<sup>1</sup> and Ghada Bassiouny<sup>2</sup>

<sup>1</sup>College of Dentistry, Qassim University, Kingdom of Saudi Arabia

<sup>2</sup>Department of Oral Medicine and Periodontology, College of Dentistry, Qassim University, KSA. and Faculty of Dentistry Alexandria University, Egypt

\*Corresponding Author: Daniah Alyahya, College of Dentistry, Qassim University, Kingdom of Saudi Arabia.

Received: September 13, 2019; Published: September 30, 2019

### Abstract

**Objective:** The purpose of this study is to determine the effectiveness of topically applied vitamin C as an adjunctive treatment for plaque-induced gingivitis.

**Methodology:** This study comprised a total of 22 patients with plaque-induced gingivitis. The subjects were randomly allocated to test and control groups. 11 subjects for the test group and 11 subjects for the control group. In the first visit, gingival health assessment was done for both groups using Plaque Index (PI) and Sulcus Bleeding Index (SBI) in addition to scaling. The test group was subjected in conjunction to scaling, to topically applied vitamin C solution in the same visit and two successive applications later with a one-week interval. The same records for assessing the gingival health were collected again in the fourth visit for both groups.

**Results:** There is a decrease in the Plaque Index (PI) and Sulcus Bleeding Index (SBI) scores in the test and control groups after the treatment. A significant statistical difference in Sulcus Bleeding Index (SBI) scores were found when comparing between the groups after the treatment. However, there was no significant difference in the Plaque Index (PI) scores.

**Conclusion:** Vitamin C solution is a safe anti-inflammatory adjunctive approach to control gingival inflammation and to maintain good oral and gingival health.

**Keywords:** Vitamin C; Gingivitis; Ascorbic Acid; Gingiva; Treatment

### Introduction

Plaque-induced gingivitis is considered the most common oral disease affecting the gingiva [1]. It is an inflammatory response of the gingival tissues due to bacterial plaque accumulation located at and below the gingival margin [2]. The ideal plaque control by the individual is the most effective method of preventing and controlling gingivitis by tooth brushing and other mechanical methods to remove the plaque [3]. The manifestations of gingivitis are redness, swelling, gingival crevice bleeding, especially during brushing and mild gingival enlargement [4]. The intensity of the manifestations will vary among individuals as well as among sites within a dentition [2]. It can be influenced by tooth-related factors such as tooth and root anatomy and restorative and endodontic considerations. Radiographic analysis, as well as probing attachment levels of individuals with plaque-induced gingivitis, will generally not indicate loss of supporting structures [2]. The histopathologic changes of plaque-induced gingivitis include vasculitis of blood vessels adjacent to the junctional epithelium, elongation of rete ridges into the gingival connective tissue, destruction of the collagen fiber network along with changes in collagen types, and a progressive inflammatory/immune cellular infiltrate [2].

Chlorhexidine is an antimicrobial agent that is considered the gold standard antiplaque and gingivitis agent. But it causes a well-recognized side effect which is extrinsic tooth staining [5]. A new approach to treating gingivitis is the use of vitamin C [1]. Vitamin C

is a powerful dietary supplement known to have an important role in the treatment and prevention of scurvy [4]. It is a well-known antioxidant which has a potential anti-inflammatory activity [7]. Other biological benefits include cancer prevention and anti-viral effect [8,9]. Besides, it has many dermatological functions, such as; skin-strengthening, photoprotection, collagen biosynthesis and inhibition of melanogenesis [7,10-13].

### Aim of the Study

The aim of this study is to determine the effectiveness of topically applied vitamin C as an adjunctive treatment for plaque-induced gingivitis.

### Materials and Methods

#### Patients selection

The present study was assigned as a randomized controlled clinical trial. All information, administration and data collection were carried out at Qassim University female dental clinic. A total of 29 subjects having plaque-induced gingivitis were screened, 7 subjects were excluded according to the exclusion criteria. The remaining 22 subjects were randomly allocated into test and control groups with 11 subjects of each using computer generated random list. The mean age of the participants was 32 years and all of them were females.

Inclusion criteria comprised of systemically free subjects having plaque-induced gingivitis. Exclusion criteria comprised of smokers, pregnancy, lactation, and mouth breathers. Informed consent was obtained from all the participants.

#### Clinical parameters

In the first visit, each participant of both groups has undergone gingival health assessment by use of: Sulcus Bleeding Index using William periodontal probe where four gingival units are scored systematically for each tooth: the labial and lingual marginal gingival (M units) and the mesial and distal papillary gingival (P units). Scores for these units are added and divided by four. Adding the scores of the undivided teeth and dividing them by the number of teeth [13].

#### Scores:

- Score 0: healthy-looking and no bleeding on probing
- Score 1: healthy-looking and bleeding on probing
- Score 2: bleeding on probing, change in color, and no edema
- Score 3: bleeding on probing, change in color, and slight edema
- Score 4: bleeding on probing, change in color, and obvious edema
- Score 5: spontaneous bleeding, change in color, and marked edema

O'Leary Plaque Index using disclosing tablets and record the discoloration of the four aspects of all dentition [14].

Dental prophylaxis, supragingival scaling and teeth polishing was done after assessing the gingival health for both groups. Then, for the control group, only oral hygiene instruction was given until the follow-up visit which is one month later. While the test group was subjected in conjunction with the scaling to topically applied vitamin C solution 250 mg/1 ML (Huons Ascorbic Acid ampoules).

The application was done on the gingival margin using cotton pellet that was soaked in the solution. The procedure was performed after isolation of the area with cheek retractor, cotton rolls, and suction to prevent the dissolution of the solution during application time which is for five minutes, then the patient is asked to spit the excess and advised not to rinse their mouth for thirty minutes. This procedure was done in the same visit and two successive applications later with a one-week interval. In the fourth week, follow up visit was scheduled for both groups where the same parameters for assessing the gingival health were collected.

Participants satisfaction was determined by asking them to fill a short form of McGill pain questionnaire.

**Results**

Twenty-two patients were included in the study. Seven patients were excluded from the study.

Age of the enrolled patients ranges from 21 to 43 years, with the mean age is about 32 years, consisted of females only.

Relative to the baseline, Plaque index (PI), and Sulcus Bleeding Index (SBI) scores were significantly different for the test group after the treatment (P = 0.000), (P = 0.001) respectively (Table 1 and Figure 1A).

PI		Preoperative	Postoperative	P value
Test group	Number	11	11	0.000
	Mean	58.447	25.445	
	SD	21.419	9.565	
Control group	Number	11	11	0.001
	Mean	59.381	36.718	
	SD	36.718	15.942	

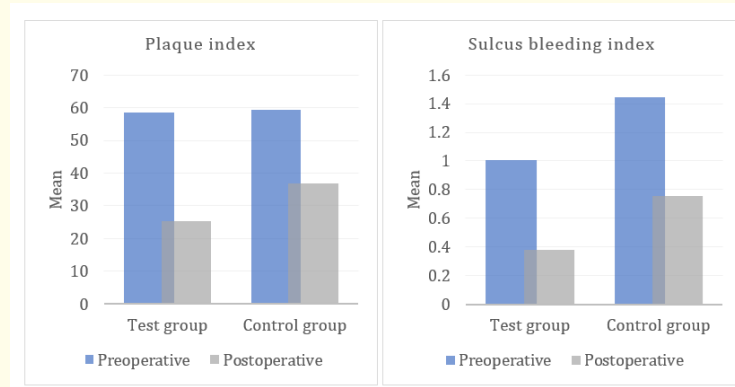
**Table 1:** Plaque Index (PI) means and standard deviation for the test and control groups.

Means that both Plaque Index (PI) and Sulcus Bleeding Index (SBI) scores were reduced and gingival inflammation had subsided.

Similarly, Plaque Index (PI) and Sulcus Bleeding Index (SBI) scores were significantly different from baseline for the control group (P = 0.001), (P = 0.003) respectively (Table 2 and Figure 1B).

SBI		Preoperative	Postoperative	P value
Test group	Number	11	11	0.001
	Mean	1.004	0.380	
	SD	0.533	0.226	
Control group	Number	11	11	0.003
	Mean	1.445	0.758	
	SD	0.632	0.246	

**Table 2:** Sulcus Bleeding Index (SBI) means and standard deviation for the test and control groups.



**Figure 1:** A: Change in Plaque Index (PI) between the groups after the treatment. B: Change in Sulcus Bleeding Index (SBI) between the groups after the treatment.

Comparing the means in each group after the treatment, there were a statistically significant difference in Sulcus Bleeding Index (SBI) sores (P = 0.001).

However, there were no significant difference in the Plaque Index (PI) scores after the treatment (P = 0.062) (Table 3).

	Group	Number	Mean	SD	P value
Postoperative PI	Test	11	25.718	9.276	0.061
	Control	11	36.714	15.933	
Postoperative SBI	Test	11	.380	.226	0.001
	Control	11	.758	.246	

**Table 3:** Comparison between the groups in Plaque Index (PI) and Sulcus Bleeding Index (SBI) means after the treatment.

All the enrolled patients reported no pain or discomfort after the treatment.

**Discussion**

The key factor responsible for the breakdown of periodontal tissues leading to periodontal disease is the dental plaque. To prevent periodontal disease, it is of utmost importance to remove this plaque regularly. Agents of chemical plaque control are given in the form of irrigation solutions, local drug delivery agents, and mouthwashes. They act as effective aids to mechanical plaque control in the prevention of plaque formation and the control of gingival inflammation. The commercially available Chlorhexidine remains the gold standard antiplaque agent due to its superior antiplaque and substantivity effects. However, it is not recommended for long-term use due to its reported adverse effects. The major side effects of chlorhexidine include brownish discoloration of teeth and tongue, alteration of taste sensation, supra-gingival calculus formation, and oral desquamation in children [15].

This made us assess the effect of vitamin C on gingival health and its use in the treatment of gingivitis. Very few studies have been done regarding vitamin C as an anti-gingivitis agent. Nermin, *et al.* (2016) claimed that there is a significant reduction in various degrees of chronic gingival inflammation using vitamin C injection.<sup>1</sup> Topical vitamin C dentifrice was used previously by Shimabukuro, *et al* [16].

Vitamin C has an important role in different body functions and is considered one of the most essential antioxidant agents [17,18]. The total volume of antioxidants drops to its lowermost levels under certain inflammatory conditions, which necessities their supplementation by an external source. Being a strong reducing agent, vitamin C can regulate the resolution of the inflammation and promote tissue healing [17,18].

In a study, they investigate the effect of a vitamin C deficient diet on the gingival and periodontal health of guinea pigs. Changes observed in gingival and periodontal tissues similar to the changes that occur in human gingivitis and periodontitis [19].

Tomofuji, *et al.* (2009) studied the relation between vitamin C plasma level and the degree of severity of periodontitis based on the level of production of reactive oxygen species. They concluded that vitamin C systemic administration down-regulate the inflammatory gene expression which could be beneficial in improving periodontitis-induced oxidative stress [2]. This study aimed to show the efficacy of vitamin C topical application in the control of gingivitis. In the present study, twenty-two patients were enrolled, and baseline data were evaluated and compared to both the postoperative and recall visit data. Analysis from the pre-interventional and post-interventional data showed a significant reduction in the plaque index and SBI index in both the groups at the subsequent visits. The difference was not significant in comparing PI between the two groups. However, there is a significant difference in Sulcus Bleeding Index scores between the groups after the treatment. These data suggest a significant enhancement of the gingival health in vitamin C group, which is probably due to the antioxidant, anti-inflammatory effects of vitamin C. These results were in accordance with Shimabukuro, *et al.* (2015) who reported that the regular application of a dentifrice containing L-ascorbic acid 2-phosphate magnesium salt (APM) could decrease gingival inflammation [16]. Bleeding on probing is an early sign of gingival inflammation. Therefore, the use of SBI in our study was helpful in the

assessment of early gingivitis [21]. Our results revealed a reduction in the mean SBI scores after vitamin C application with a statistically significant difference between pre and postoperative visits; this may be due to one or more of the following reasons. The first reason is evident by the significant reduction in the mean scores of plaque index between baseline and postoperative records, which indicate adherence to the oral hygiene instructions by the patients.

An additional cause is the role of vitamin C in collagen formation, tissue healing and angiogenesis [22,23]. It was suggested by Aguirre R. and May J., *et al.* (2008) that the inclusion of vitamin C in the periodontal treatment has a role in periodontal tissue healing and resistance of periodontal disease [23]. The last reason is that ascorbic acid enhances and modifies the immune responses as it blocks the needed signal for lipopolysaccharides (LPS) production, so it neutralizes the bacterial toxins especially endotoxins [24]. Moreover, it enhances the phagocytic properties of numerous immune cells [25].

One of the limitations of vitamin C is the superficial penetration effect, as it is water-soluble. Several researchers used different forms of lipid-soluble topical vitamin C in an attempt to overcome its limited absorption. These studies met many limitations such as very long-term improvement time, instability and easy dislodgement from the tissues and localized enamel erosions in some cases [26-28]. For that, we recommend the use of perio-chips, gingival cords impregnated with vitamin C, or injection of vitamin C containing gel in the gingival sulcus and cover it with perio pack to lengthen the time of contact of the material with the tissues and to decrease the wash effect of saliva. This study was carried out in a smaller sample size in a four weeks duration to assess the anti-gingivitis effect of topically applied vitamin C. Further long-term trials with a follow-up of at least three months have to be conducted with a larger sample size to determine the full potential of vitamin C and to validate our findings.

### Conclusion

It can be concluded, within the limits of the present study, that the topical application of vitamin C solution was effective in reducing the components of gingival inflammation. So, it can be recommended as a safe anti-inflammatory adjunctive approach to control gingival inflammation and to maintain good oral and gingival health.

### Conflict of Interest

There are no conflicts of interest.

### Bibliography

1. Yussif Nermin M., *et al.* "Evaluation Of The Anti-Inflammatory Effect Of Locally Delivered Vitamin C In The Treatment Of Persistent Gingival Inflammation: Clinical And Histopathological Study". *Journal of Nutrition and Metabolism* (2016).
2. Murakami Shinya., *et al.* "Dental Plaque-Induced Gingival Conditions". *Journal of Periodontology* 89 (2018): S17-S27.
3. He Jinfeng., *et al.* "The Efficacy and Safety of a Herbal Toothpaste In Reducing Gingivitis: A Double-Blind, Randomized, Placebo-Controlled, Parallel Allocation Clinical Trial". *Evidence-Based Complementary and Alternative Medicine* (2019).
4. Coventry J., *et al.* "ABC Of Oral Health: Periodontal Disease". *British Medical Journal* 321.1 (2000): 36-39.
5. Jones, Christopher G., *et al.* "Chlorhexidine: Is It Still the Gold Standard?". *Periodontology 2000* 15.1 (1997): 55-62.
6. Hemilä Harri. "Vitamin C And Common Cold-Induced Asthma: A Systematic Review And Statistical Analysis". *Allergy, Asthma and Clinical Immunology* 9.1 (2013).
7. Telang Pumori Saokar. "Vitamin C in dermatology". *Indian Dermatology Online Journal* 4.2 (2013): 143-146.
8. Harris, Holly R., *et al.* "Vitamin C and Survival Among Women with Breast Cancer: A Meta-Analysis". *European Journal of Cancer* 50.7 (2014): 1223-1231.

9. Fujiwara, Ayaka., *et al.* "Exogenous Ascorbic Acid Derivatives and Dehydroascorbic Acid Are Effective Antiviral Agents Against Turnip Mosaic Virus in Brassica Rapa". *Journal of General Plant Pathology* 79.3 (2013): 198-204.
10. Shimada Yasuko., *et al.* "Effects of Ascorbic Acid on Gingival Melanin Pigmentation In Vitro And In Vivo". *Journal of Periodontology* 80.2 (2009): 317-323.
11. Yussif, Nermin., *et al.* "Evaluation of Injectable Vitamin C As A Depigmenting Agent In Physiologic Gingival Melanin Hyperpigmentation: A Clinical Trial". *Report and Opinion* 8.6 (2016): 113-120.
12. Iqbal., Khalid., *et al.* "Biological Significance of Ascorbic Acid (Vitamin C) In Human Health - A Review". *Pakistan Journal of Nutrition* 3. 1 (2004): 5-13.
13. Augusta Bessa Rebelo Maria and Adriana Corrêa de Queiroz. "Gingival Indices: State of Art". 1<sup>st</sup> edition, INTECH Open Access Publisher (2011):41-44.
14. O'Leary Timothy J., *et al.* "The Plaque Control Record". *Journal of Periodontology* 43.1 (1972): 38-38.
15. Balagopal Shruti., *et al.* "Chlorhexidine: The Gold Standard Antiplaque Agent". *Journal of Pharmaceutical Sciences and Research* 5.12 (2013): 270-274.
16. Shimabukuro Yoshio., *et al.* "Effects of An Ascorbic Acid-Derivative Dentifrice in Patients with Gingivitis: A Double-Masked, Randomized, Controlled Clinical Trial". *Journal of Periodontology* 86.1 (2015): 27-35.
17. Nishikimi SP Morimitsu., *et al.* "Cloning and Chromosomal Mapping of The Human Nonfunctional Gene For L-Gulonolactone Oxidase, The Enzyme For L-Ascorbic Acid Biosynthesis Missing In Man". *Journal Of Biological Chemistry* 269.18 (1994): 13685-13688.
18. Omori Kazuhiro., *et al.* "Gingival Overgrowth Caused by Vitamin C Deficiency Associated with Metabolic Syndrome And Severe Periodontal Infection: A Case Report". *Clinical Case Reports* 2. 6 (2014): 286-295.
19. Burrill, Dan Y. "Relationship of Blood Plasma Vitamin C Level to Gingival And Periodontal Disease". *Journal of Dental Research* vol 21.4 (1942):353-363.
20. Tomofuji, Takaaki., *et al.* "Effects of Vitamin C Intake on Gingival Oxidative Stress In Rat Periodontitis". *Free Radical Biology and Medicine* 46. 2 (2009): 163-168.
21. Mühlemann HR., *et al.* "Gingival Sulcus Bleeding--A Leading Symptom in Initial Gingivitis". *Helvetica Odontological Acta* 15.2 (1971): 107-113.
22. Aguirre, Rene., *et al.* "Inflammation in The Vascular Bed: Importance of Vitamin C". *Pharmacology and Therapeutics* 119.1 (2008): 96-103.
23. Zanoni Jacqueline N., *et al.* "Histological Evaluation of The Periodontal Ligament from Aged Wistar Rats Supplemented with Ascorbic Acid". *Annals of the Brazilian Academy of Sciences* 85.1 (2013): 327-335.
24. Kalokerinos Archie., *et al.* "Endotoxin and Vitamin C Part 1--Sepsis, Endotoxin, And Vitamin C". *Journal of The Australasian College of Nutritional and Environmental Medicine* 24.1 (2005): 17-21.
25. Sorice Angela., *et al.* "Ascorbic Acid: Its Role in Immune System and Chronic Inflammation Diseases". *Mini-Reviews in Medicinal Chemistry* 14.5 (2014): 444-452.
26. Pinnell Sheldon R., *et al.* "Topical L-Ascorbic Acid: Percutaneous Absorption Studies". *Dermatologic Surgery* 27.2 (2001): 137-142.

27. Giunta John L., *et al.* "Dental Erosion Resulting from Chewable Vitamin C Tablets". *The Journal of The American Dental Association* 107.2 (1983): 253-256.

28. Bahal Priya., *et al.* "Dental Erosion from An Excess of Vitamin C". *Case Reports in Dentistry* (2014): 1-5.

**Volume 18 Issue 10 October 2019**

**©All rights reserved by Daniah Alyahya., *et al.***