

Rare Presentation of Calcifying Odontogenic Cyst: Report of Two Cases with Recent Updates

Dhara Dwivedi^{1*}, Nitin Prabhakar¹, Vinay Nataraj Kashi¹, Melese Tabor² and Srikanth Thammisetty³

¹Assistant Professor, Department of Dentistry, College of Health Sciences, Mekelle University, Ethiopia

²Head of Department, Department of Dentistry, College of Health Sciences, Mekelle University, Ethiopia

³Lecturer, School of Dentistry, University of Rwanda, Rwanda

***Corresponding Author:** Dhara Dwivedi, Assistant Professor, Department of Dentistry, College of Health Sciences, Mekelle University, Ethiopia.

Received: August 13, 2019; **Published:** September 11, 2019

Abstract

First described by Gorlin., *et al.* in 1962, Calcifying odontogenic cyst is a rare odontogenic lesion which arises from dental lamina and is characterized by the presence of “ghost cells”. Owing to its unpredictable clinical and biological course, it still remains an enigma to the most researchers. Presented here are two rare cases of calcifying odontogenic cyst which were treated with surgical enucleation. The former is the case of recurrent ameloblastomatous calcifying odontogenic cyst associated with a dentigerous cyst in an 18 years old African male while later case occurred in 13 years old African female with no recurrence. When compared to simple COC, the destructive behavior and the prognosis for ameloblastomatous variant of calcifying odontogenic cyst can be more aggressive. Therefore, formulation of the final treatment plan should be based on the clinico-pathological details which may differ for each case under the spectrum of this lesion.

Keywords: Calcifying Odontogenic Cyst; Calcifying Cystic Odontogenic Tumor; Odontogenic Cyst; WHO 2017 Classification; Maxillofacial Region; Maxillofacial Surgery

Abbreviations

COC: Calcifying Odontogenic Cyst; DC: Dentigerous Cyst; WHO: World Health Organization; OMFS: Oral and Maxillofacial Surgery; CT: Computed Tomography; H&E: Hematoxylin and Eosin; CCOT: Calcifying Cystic Odontogenic Tumor; AF: Ameloblastic fibroma

Introduction

Calcifying odontogenic cyst (COC) has undergone a plethora of changes with respect to its terminology i.e. being classified as a “simple /non- neoplastic cyst” to its identification as a “benign cystic neoplasm” by WHO (World Health Organization) from 1971 to 2005 respectively [1]. Later, it was agreed upon that COC is indeed a heterogeneous group of lesions with distinct histopathological findings. The latest 4th edition of WHO classification of odontogenic tumors decided to restore the term COC [2].

The highlights of this report are: a) presentation of two cases of COC with contrasting biological behavior, b) including the present case, only five cases showing association of COC with dentigerous cyst (DC) have been reported till date to the best of our knowledge.

Case 1

An 18 years old male patient of African origin reported to the department of Oral and Maxillofacial Surgery (OMFS) with the chief complaint of swelling on the right side of the face of ten years duration which gradually increased to the present size. On recording the

past dental history, it was found that the patient had been operated for a cyst in the same location at some other hospital; the details for which were not accessible. The medical history was uneventful. Clinical examination revealed a gross asymmetry over the right lower third of the face with poorly delineated margins (Figure 1). Intraorally, a solitary intrabony swelling of the right mandible extending from the ascending ramus crossing the midline till tooth number 34 was found with the obliteration of right buccal sulcus with the size of about 6cm x 7cm. It was an ill-defined, hard, non-tender swelling with smooth surface; overlying mucosa was intact and normal appearing.



Figure 1: Extra-oral photograph showing facial asymmetry and swelling over the entire right mandibular area.

The Computed tomography (CT) images revealed mixed lytic expansile and sclerotic lesions involving the mandible bilaterally, more on the right side with displacement of teeth and loculation of air inside the cavity formed by the lytic process. 46, 47, 48 were found to be impacted. Aspiration was performed which came out to be negative. On the basis of the history and clinical examination, provisional diagnosis of a DC and COC was established.

The lesion was surgically enucleated in the right mandible under general anesthesia. The excised specimen was sent for further histopathological examination. The hematoxylin and eosin (H and E) stained sections showed 2 - 4 cell layer thick epithelial cystic lining supported by fibro-vascular stroma with areas of mononuclear inflammatory cells, hemorrhage and normal appearing bone tissue supporting the diagnosis of DC (Figure 2).

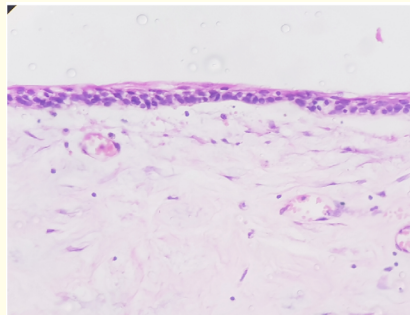


Figure 2: H&E stained photomicrograph showing wall of dentigerous cyst lined by thin 2 - 4 cell layers of flat to cuboidal cells supported by the fibrous capsule with moderate vasculature and a few mononuclear inflammatory cell infiltration.

The patient returned to the department with the recurrence of the swelling after four months. The radiographs revealed new bone formation over right ramus and body region; irregular radiolucency with small areas of radio-opacity seen extending from 41 to 34. Enucleation of the lesion along with the associated teeth was performed during the second surgery and the obtained tissue was submitted for the histopathological analysis.

Histopathological findings

Macroscopic features: The specimen comprised of multiple segments of a grayish - white soft tissue mass with few creamish brown flecks, firm in consistency, measuring approximately 6 x 4 cm.

Microscopic features: H and E stained sections revealed cystic lining comprising of well defined palisaded basal layer of tall columnar cells with hyperchromatic nuclei polarized away from the basement membrane along with overlying layer containing masses/sheets of ghost cells and focal calcifications (Figure 3a). Ameloblastomatous cells arranged in the form of cords and islands were seen embedded in the underlying fibrous connective tissue stroma along with few areas resembling ameloblastic fibroma (AF) (Figure 3b-3d). Few mono-nuclear inflammatory cells were distributed focally. Hence, the diagnosis of calcifying odontogenic cyst with ameloblastomatous proliferation was given.

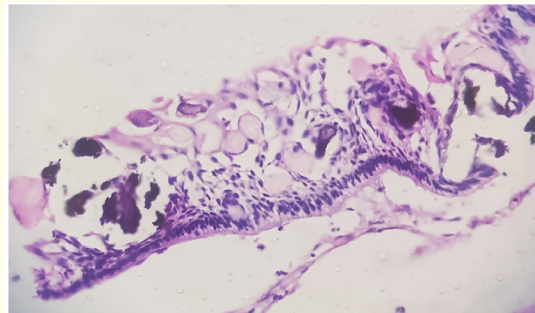


Figure 3A: H&E stained photomicrograph showing ameloblastomata like cystic lining comprised of round to oval homogenous eosinophilic staining ghost cells with eccentric nuclear remnants admixed with polyhedral cells and few basophilic areas representing calcification.

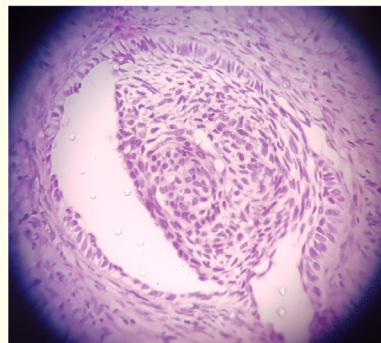


Figure 3B: Single ameloblastomatous island with peripheral tall columnar cells showing palisaded arrangement and central round cells within the stroma.

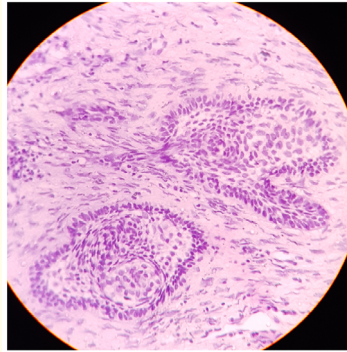


Figure 3C: Ameloblastomatous proliferating islands lying in the connective tissue capsule.

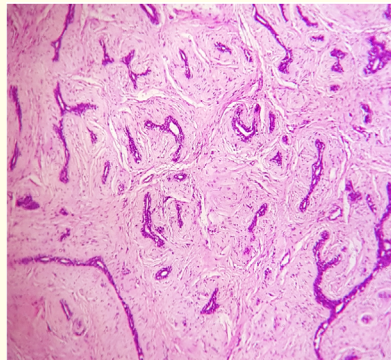


Figure 3D: Numerous cords and trabaculae of dark staining odontogenic epithelial cells in the fibrous stroma resembling ameloblastic fibroma.

Case 2

While performing root canal therapy for tooth number 46, a diffuse swelling over the posterior aspect of the right mandible was observed by the department endodontist (Figure 4). Thereafter patient was referred to the OMFS department. The duration of the swelling was eight months. When examined intra-orally, a non-tender, intra-osseous, bony hard swelling with intact overlying mucosa was found extending from midline to right second molar obliterating buccal vestibule. Radiographs revealed unerupted canine 43 beneath follicular expansion in the right posterior mandibular area. Axial CT of the mandible illustrated approximately 3 x 3 cm well defined, elliptical, unilocular expansile lesion with thinned buccal cortical plate in association with impacted canine 43. Brownish fluid was yielded on aspiration and cytological assessment was suggestive of a benign cyst. Therefore, clinical diagnosis of dentigerous cyst was formed. Following the surgical enucleation of the lesion, histopathological examination was performed.

Histopathological findings

Macroscopic features: A creamish -brown, irregular shaped soft cystic tissue specimen measuring 4.0 x 4.0 cm in size with soft consistency was received.



Figure 4: Extra oral view of the right mandibular swelling.

Microscopic features: The H and E stained tissue section showed cystic lining comprising of 1-2 layers of hyperchromatic basal cells and abundant ghost cells with retained cellular outlines and nuclear remnants in the superficial layers admixed with stellate reticulum like spindle cells (Figure 5a). The underlying fibrous stroma exhibited various calcified masses which established the diagnosis of calcifying odontogenic cyst (Figure 5b).

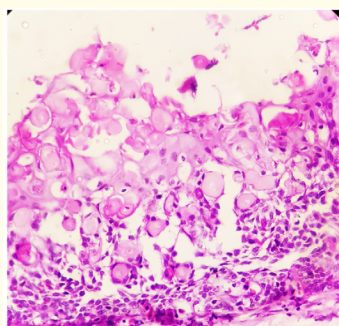


Figure 5A: H & E stained photomicrograph showing numerous ghost cells with admixed with loosely arranged polyhedral cells.

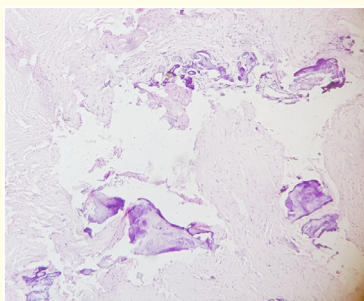


Figure 5B: Multiple foci of calcification in the connective tissue stroma.

Discussion

COC constitutes less than 1% of the entire odontogenic cysts. Most cases present as slow growing painless intraosseous expansile swelling of the jaws with the predilection for anterior regions; rare occurrence has been reported extra-osseously. It occurs over a wide age range with a peak incidence in second decade and no sex predilection. Radiographically, COC can present either as unilocular or a multilocular radiolucency in the early stages and finally mature to form a mixed radiolucent-opaque lesion [3,4]. One thirds of the cases present with unerupted teeth and about half cases have an odontome association [1]. In both the presented cases, age of occurrence and clinical and radiographic presentation was in accordance with the reported literature.

Review of literature with Recent Update:

One of the earlier approaches for the terminology was based on the 'monistic concept' which suggested the neoplastic nature of the predominantly cystic lesion followed by the 'dualistic concept' where cystic and solid lesions were considered synonyms to non-neoplastic and neoplastic nature of the lesion respectively [5,6]. Prætorius., *et al.* disregarded with the former concepts and proposed an extensive classification for this entity with four groups and several subgroups in an attempt to encompass its existence as a simple cyst together with its possible association with other benign and malignant tumors [7]. In 2005, COC (cyst) was re- categorized as Calcifying cystic odontogenic tumor (CCOT) in order to highlight its neoplastic potential and the solid variants were identified as separate entities [8,9].

In 2008, Ledesma- Montes., *et al.* conducted an elaborate multicentre research and concluded that over 85% of ghost cell lesions are either simple cysts alone or associated with odontomas (65%) with rare recurrence. Very few showed ameloblastomatous proliferations, and only 5% of lesions were solid and could be regarded as true neoplastic dentinogenic ghost cell tumours [10]. In agreement to them, Hong., *et al.* along with De Arruda., *et al.* reported the benign course of the lesion with negligible rate of recurrence in their respective research. Hence, it was suggested that the neoplastic status for simple cysts couldn't be condoned [11,12].

Thereafter, WHO (2017) re-defined COC as a simple cyst lined by ameloblastoma like epithelium which contains focal accumulations of ghost cells dismissing its former tumor status [1].

Among the presented cases, first one showed the rarer relationship of ameloblastomatous COC with DC including a few AF like areas; while hard tissue formation was observed in the second case. Alliance of COC with other odontogenic lesions has been known since long; among these, association with odontomas is most common followed by AF, dentigerous cyst, adenomatoid odontogenic tumor, ameloblastoma, ameloblastic fibro-odontoma, odontogenic keratocysts, orthokeratinized odontogenic cyst, and one case of ameloblastoma and adenomatoid odontogenic tumor [12,13]. Apart from these cases, Sarode., *et al.* reported two cases of COC arising in the dental follicle of impacted third molars [14]. Abrams and Howell mentioned that the multipotentiality of the odontogenic epithelium could explain the combined occurrence of the COC with another odontogenic lesion [15,16].

Conservative surgery constitutes the mainstay of treatment with low rates of recurrence.

Some authors suggested that the behavior and prognosis of COC associated with an ameloblastoma, will be that of an ameloblastoma, not of COC [17]. On the other hand Montes., *et al.* highlighted that cases classified as ameloblastoma arising from a COC, in fact, do not show the aggressive behavior of Ameloblastomas [10]. Enucleation was performed in both of the discussed cases. The cyst recurred twice in the first case; the actual reason can't be ascertained as the details of the first surgical procedure were not available. The second patient has been kept on a follow up with no recurrence since two years.

Registered literature on calcifying odontogenic cyst confirms its variegated presentation ranging from a benign developmental odontogenic cyst to a neoplasm with a possible malignant association. The need of the hour is the introduction of the new terminology indicative of the true biological behavior of the lesion. Even though, the cystic designation has aided to preclude the unnecessary extensive surgical treatment modalities (procedures which were advocated for the tumor); but the presence of a potential cystic neoplasm can be masqueraded.

Conclusion

The aim of this paper was to emphasize on the disparity in the presentation and clinical course of two cases of one lesion i.e. COC. Unlike a simple developmental cyst, a COC when exhibiting ameloblastomatous features can be correlated with a more disruptive potential and a greater tendency to reoccur; hence, the management should be modified appropriately with the emphasis on long term follow ups.

Acknowledgements

Nil.

Conflict of Interest

Nil.

Source/s of Funding

Nil.

Bibliography

1. Wright JM., *et al.* "Odontogenic tumors, WHO 2005: where do we go from here?" *Head and Neck Pathology* 8.4 (2014): 373-382.
2. El-Mofty SK., *et al.* "Cementoosseous dysplasia". WHO Classification of Head and Neck Tumours. 4th edition.
3. Rojo R., *et al.* "Calcifying odontogenic cysts". *Journal of Stomatology, Oral and Maxillofacial Surgery* 118.2 (2017): 122-124.
4. Tomich CE. "Calcifying odontogenic cyst and dentinogenic ghost cell tumor". *Oral and Maxillofacial Surgery Clinics of North America* 16.3 (2004): 391-397.
5. Moleri A., *et al.* "Comparative morphology of 7 new cases of calcifying odontogenic cysts". *Journal of Oral and Maxillofacial Surgery* 60.6 (2002): 689-696.
6. Kallalli BN., *et al.* "Ameloblastomatous calcifying odontogenic cyst: A rare histologic variant". *Journal of Indian Academy of Oral Medicine and Radiology* 27.1 (2015): 123-126.
7. Praetorius., *et al.* "Calcifying odontogenic cyst. Range, variations and neoplastic potential". *Acta Odontologica Scandinavica* 39.4 (1981): 227-240.
8. Barnes L., *et al.* "World Health Organization Classification of Tumours: Pathology and Genetics of Tumors of Head and Neck". Lyon: IARC (2005).
9. Sharma B., *et al.* "Calcifying odontogenic cyst with luminal and mural component (Type 1c)". *Indian Journal of Dentistry* 7.2 (2016): 95-98.
10. Ledesma-Montes C., *et al.* "International collaborative study on ghost cell odontogenic tumours: calcifying cystic odontogenic tumour, dentinogenic ghost cell tumour and ghost cell odontogenic carcinoma". *Journal of Oral Pathology and Medicine* 37.5 (2008): 302-308.
11. Hong SP., *et al.* "Calcifying odontogenic cyst. A review of ninety-two cases with reevaluation of their nature as cysts or neoplasms, the nature of ghost cells, and subclassification". *Oral Surgery, Oral Medicine, Oral Pathology* 72.1 (1991): 56-64.
12. de Arruda JAA., *et al.* "Calcifying odontogenic cyst, dentinogenic ghost cell tumor, and ghost cell odontogenic carcinoma: A systematic review". *Journal of Oral Pathology and Medicine* 47.8 (2018): 721-730.

13. Gamoh S., *et al.* "Calcifying cystic odontogenic tumor accompanied by a dentigerous cyst: A case report". *Oncology Letters* 14.5 (2018): 5785-5790.
14. Sarode GS., *et al.* "Calcifying cystic odontogenic tumor in radiologically normal dental follicular space of mandibular third molars: report of two cases". *Clinical Practice* 7.1 (2017): 933.
15. Abrams AM., *et al.* "Calcifying epithelial odontogenic tumors: report of four cases". *Journal of the American Dental Association* 74.6 (1967): 1231-1240.
16. Santos HBP., *et al.* "Calcifying Odontogenic Cyst with Extensive Areas of Dentinoid: Uncommon Case Report and Update of Main Findings". *Case Reports in Pathology* (2018): 8323215.
17. Buchner A., *et al.* "Central (intraosseous) calcifying odontogenic cyst". *International Journal of Oral and Maxillofacial Surgery* 19.5 (1990): 260-262.

Volume 18 Issue 10 October 2019

©All rights reserved by Dhara Dwivedi., *et al.*