

Surgical Management of Bilateral Impacted Maxillary Canines: A Case Report

Janardan B Garde¹ and Ashvini K Vadane^{2*}

¹Professor and H.O.D, M.A. Rangoonwala College of Dental Sciences and Research Centre, Pune, India

²Senior Lecturer, M.A. Rangoonwala College of Dental Sciences and Research Centre, Pune, India

***Corresponding Author:** Ashvini K Vadane, Senior Lecturer, M.A. Rangoonwala College of Dental Sciences and Research Centre, Pune, India.

Received: August 16, 2019; **Published:** September 09, 2019

Abstract

When according to the clinical as well as radiographic examination, there are very less chances of eruption of teeth; those teeth are considered as impacted teeth. Impacted permanent maxillary canines are found in approximately 1% to 2% of the population. These are the second most commonly impacted teeth after permanent third molars [1,2]. This article briefly reports a case of bilateral impacted permanent maxillary canines which was managed by surgical intervention.

Keywords: *Bilateral Impacted Canines; Impaction; Maxillary Canine; Permanent Canines*

Introduction

When according to the clinical as well as radiographic examination, there are very less chances of eruption of teeth; those teeth are considered as impacted teeth. Impacted permanent maxillary canines are found in approximately 1% to 2% of the population. These are the second most commonly impacted teeth after permanent third molars [1,2].

Case Report

A 17 years old female patient visited our institute with the chief complaint of pain in the upper front teeth region of jaw since 1 month. On clinical examination, deciduous canines were seen in the maxillary arch and both maxillary permanent canines were absent. Hence, orthopantomogram was advised. Radiographic examination revealed the presence of impacted maxillary permanent canines as shown in figure 1.

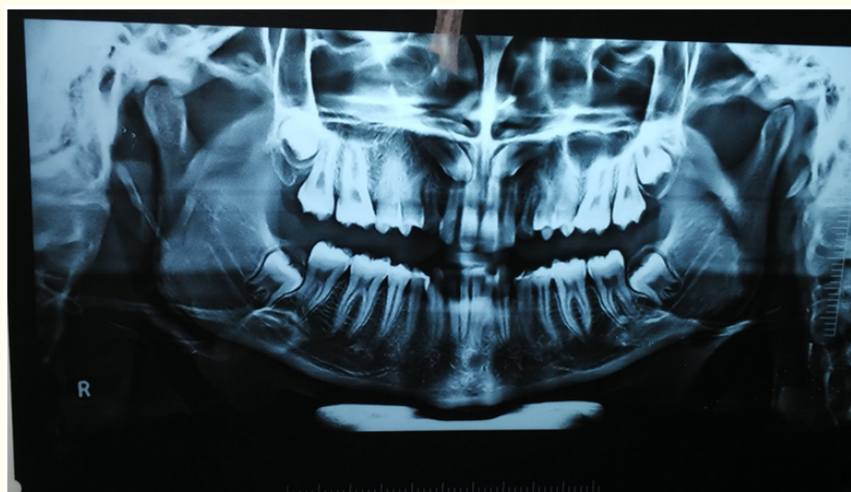

Figure 1: Orthopantomogram revealing the presence of impacted bilateral permanent canines.

Palatal canine bulge was felt on palpation. Surgical extraction of both impacted canines was planned under local anaesthesia. Patient was informed about the surgical procedure and her consent was taken for the treatment. All preoperative investigations were performed and they were within normal range.

Surgical procedure

Bilateral infraorbital nerve block was administered. Palatally, local anaesthetic infiltration was administered. Crevicular incision was given from distal side of maxillary right second premolar to the distal side of maxillary left second premolar. Mucoperiosteal flap was elevated with periosteal elevator. Figure 2 reveals the surgical exposure of the site. Bilateral impacted canines were located as shown in the figure 3 and was extracted with the help of elevators and extraction forceps.

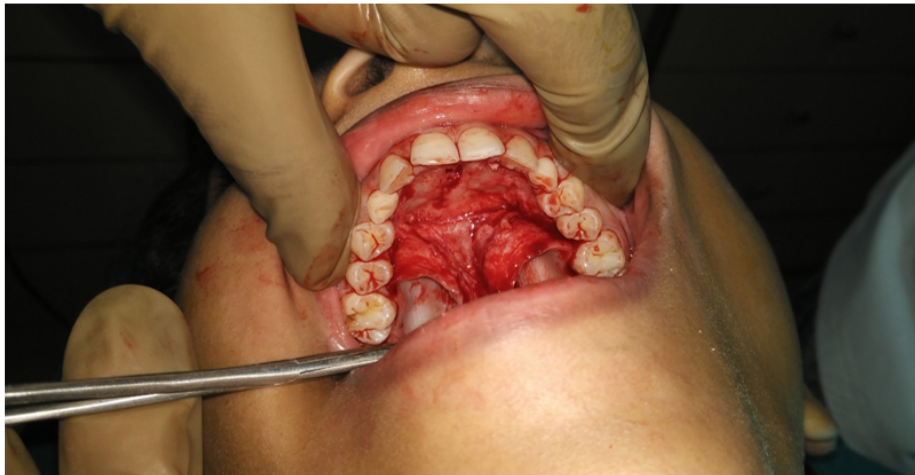

Figure 2: Surgical exposure of the site to be operated.

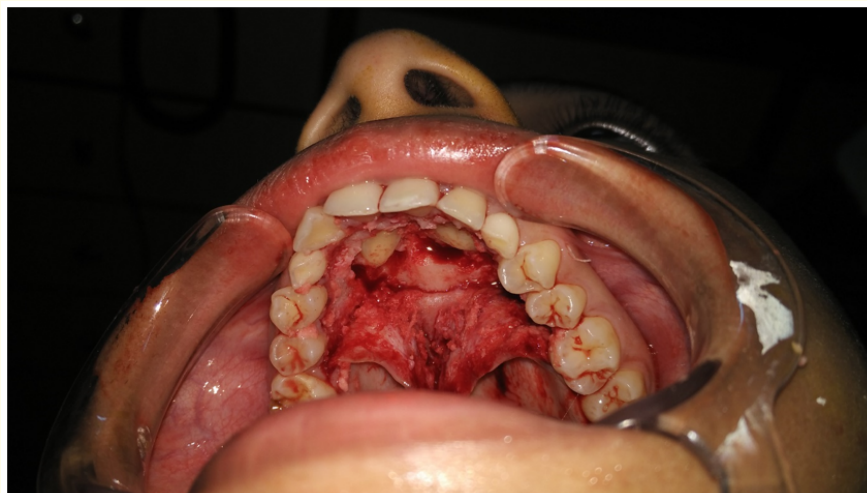

Figure 3: Bilateral impacted permanent canines located.

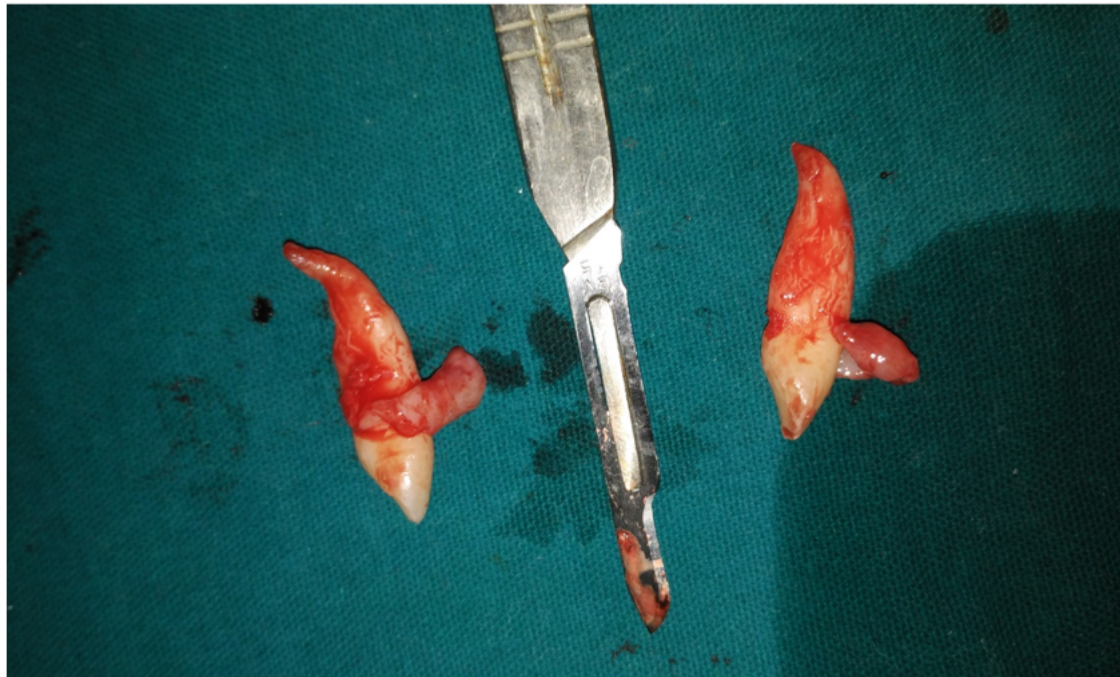


Figure 4: Extracted canines.

Discussion

Canine teeth or cuspids have an important functional as well as esthetic purpose [5]. They are considered as the foundation of an esthetic smile [11]. Permanent maxillary canines are most prevalent impacted teeth after permanent molars. Impacted maxillary canines are most commonly found in females [1]. Maxillary first molars are most commonly ectopically erupting teeth followed by maxillary cuspids and mandibular lateral incisors [11]. Mandibular canine impaction is rarely found [5]. The presence of unilateral ectopic eruption is more common, but bilateral canine impaction in maxillary arch is also found commonly [2,7]. Impacted maxillary canines are positioned either labially or palatally [1]. They can be positioned on alveolus also [2]. Almost 2/3rd of maxillary impacted canines are located palatally.

There can be various causes of canine impaction like trauma, odontoma, formation of cyst or genetic factors [1]. As per Bishara, over-retained primary canine teeth and the presence of palatal bulge indicates the impaction of permanent maxillary canines [2]. Clinical examination and radiographic evaluation is important for the diagnosis of impacted canines [2].

There are various options for the management of impacted canines. Observation, surgical intervention, relocation with the help of orthodontic treatment and extraction are the treatment options for the management of impacted canines. Management of labially impacted maxillary canine is difficult and challenging [1]. Closed eruption technique and surgical interventions like excisional uncovering and apically positioned flap are different treatment options for the management of labially impacted maxillary canines [2].

Conclusion

Maxillary canine impaction is commonly found anomaly [2]. Proper clinical examination and correct radiographic evaluation is important for the diagnosis of impacted canines [2]. Multidisciplinary approach is necessary for the management of impacted canines [2,6,8].

Bibliography

1. Yu-Shan Huang, *et al.* "Surgical considerations and management of bilateral labially impacted canines". *Journal of Dental Sciences* 11.2 (2016): 202 -206.
2. Abu-Hussein Muhamad, *et al.* "Clinical Management of Bilateral Impacted Maxillary Canines". *Scientific Journal of Research in Dentistry* 1 (2017): 1-7.
3. Grace Richardson and Kathy A Russell. "A Review of Impacted Permanent Maxillary Cuspids-Diagnosis and Prevention". *Journal of the Canadian Dental Association* 66.9 (2000): 497-501.
4. Giliana Zuccati. "Bilaterally impacted maxillary canines: a case report in an adult". *European Journal of Orthodontics* 16.4 (1994): 325-328.
5. Domenico Dalessandri, *et al.* "Impacted and transmigrant mandibular canines incidence, aetiology, and treatment: a systematic review". *European Journal of Orthodontics* 39.2 (2017): 161-169.
6. Sumitra. "Orthodontic-surgical treatment of bilateral maxillary canine impaction". *Contemporary Clinical Dentistry* 3.3 (2012): 363-366.
7. Hassan Al-Zoubi, *et al.* "Frequency of impacted teeth and categorization of impacted canines: A retrospective radiographic study using orthopantomograms". *European Journal of Dentistry* 11.1 (2017): 117 -121.
8. Nitubroto Biswas, *et al.* "Maxillary Impacted Canine: Diagnosis and Contemporary Ortho Surgical Management Guidelines". *International Journal of Scientific Study* 3.10 (2016).
9. Ranjit Manne, *et al.* "Impacted canines: Etiology, diagnosis and orthodontic management". *Journal of Pharmacy and Bioallied Sciences* 4.2 (2012): S234-S238.
10. Sonali Sharma, *et al.* "Kissing mandibular canines: Serendipity at its best". *Journal of Indian Academy of Oral Medicine and Radiology* 26.1 (2014): 82-84.
11. Col SM Londhe, *et al.* "Management of Bilateral Impacted Maxillary Canines". *Medical Journal Armed Forces India* 65.2 (2009): 190-192.
12. Sachin Agarwal, *et al.* "Correction of bilateral impacted mandibular canines with a lip bumper for anchorage reinforcement". *American Journal of Orthodontics and Dentofacial Orthopedics* 143.3 (2013): 393-403.
13. Adrian Becker and Stella Chaushu. "Etiology of maxillary canine impaction: A review". *American Journal of Orthodontics and Dentofacial Orthopedics* 148.4 (2015): 557-567.
14. Michael Schubert, *et al.* "Successful treatment of multiple bilateral impactions-a case report". *Head and Face Medicine* 12 (2016): 24.

Volume 18 Issue 10 October 2019

©All rights reserved by Janardan B Garde and Ashvini K Vadane.