

Atraumatic Extractions and Multiple Implants Placement in a Patient with Florid Cemento-Osseous Dysplasia

Rakan S Shaheen*

MSc in Periodontics, Preventive Department, College of Dentistry, Riyadh Elm University, Saudi Arabia

***Corresponding Author:** Rakan S Shaheen, MSc in Periodontics, Preventive Department, College of Dentistry, Riyadh Elm University, Saudi Arabia.

Received: August 23, 2019; **Published:** September 09, 2019

Abstract

The replacement of normal bone with fibrous connective tissues and cementum-like materials is known as Florid Cemento-Osseous Dysplasia (FCOD), which is a rare disease that is diagnosed radiographically as it appears as dense, ground-glass, lobulated, opaque masses present in two or more quadrants in the alveolar bone of tooth-bearing areas with an affinity for a symmetrical bilateral distribution. The most common complications in FCOD patients is the spreading of an infection through the lesion and the

In this case report of a 35 years old black female, a maxillary canine and a 2nd premolar were located near a FCOD lesion in the area of a missing maxillary 1st premolar and were deemed unrestorable, atraumatic extraction was carried out of the teeth avoiding any manipulation of the FCOD lesion, followed by implant placement 3 months later with the canine and 2nd premolar being the abutments and the 1st premolar as the pontic in the fixed dental prosthesis supported by the implants. The implants were successfully loaded and after 3 months of follow-up there is no change to the FCOD lesions neither in size nor number.

Implant placement in a FCOD patient can be accomplished with the proper diagnosis and treatment planning utilizing the Panoramic radiographs if the FCOD lesions are far from the surgery area or the Cone Beam Computed Tomography (CBCT) scans if the surgery area is in close proximity to the lesion. In order to state with certainty the success rates of the dental implant therapy in FCOD patients, there needs to be even more studies on the topic as currently there is a scarce number of reports in the literature.

Keywords: *Florid Cemento-Osseous Dysplasia; Implant; FCOD; Fibrous Dysplasia; Jaw Diseases; Bone Diseases; Cementoma*

Introduction

The term Florid Cemento-Osseous Dysplasia (FCOD) was first introduced in the year 1976 in a study by Melrose and colleagues where they studied thirty-four cases that shared the main characteristic features of what they called FCOD [1].

FCOD is a rare condition that most commonly affects middle-aged black females but can also affect Caucasians and Asians too [2]. The mandible is involved more than the maxilla [3] as it's affected in all the cases while the maxilla is only affected in two thirds of the cases [4]. FCOD affects two or more quadrants of the jaws and to have a tendency for a bilateral distribution, with the posterior areas being mostly involved [3].

Patients with FCOD have no blood or systemic abnormalities, also clinically FCOD has no extragnathic features and can commonly be asymptomatic in nature [1], but can develop symptoms when an infection occurs most commonly due to the thin ossifying margin being perforated [5].

Radiographically FCOD can be initially diagnosed on a routine Panoramic radiograph, mostly being caught coincidentally. On the Panoramic radiograph it appears as dense, ground-glass, lobulated, opaque masses present in two or more quadrants in the alveolar bone of tooth-bearing areas with an affinity for a symmetrical bilateral distribution [1,6]. And nowadays with the Computed Tomography (CT) scans and the Cone-Beam Computed Tomography (CBCT) scans being frequently used in dental practices it became easier to examine suspected lesions in three dimensions to confirm the diagnosis [3,7].

Aim of the Study

The aim of this paper is to report the clinical, radiographic and histological findings of placing multiple implants in a patient diagnosed with FCOD.

Case Report

A 35 years old black female patient visited the Riyadh Elm University clinics in order to restore her upper left canine and premolar. The routine screening radiographs were taken which included a Panoramic radiograph, after which the presence of multiple radiopaque lesions was evident, bilaterally wide-spread in the mandible and only localized foci were present bilaterally in the maxilla. The radiopaque masses in the mandible were located bilaterally in the periapical areas and extended from the mesial side of the lower left second molar to the distal side of lower right second molar. And in the maxilla, they were localized on the right side in the premolars area and on the left side in the missing first premolar area (#24) (Figure 1).

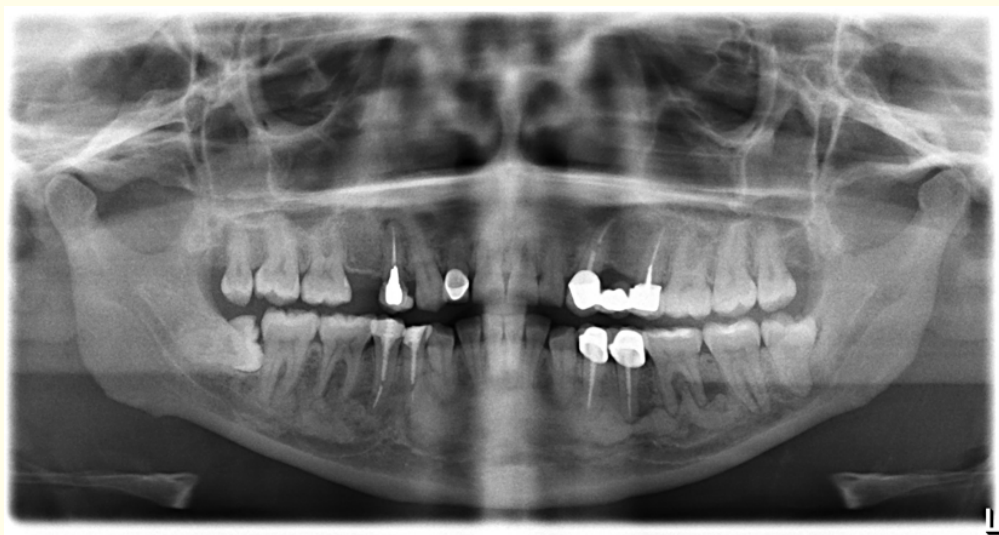


Figure 1: Pre-operative Panoramic radiograph.

After removal of the fixed dental prosthesis from the upper left canine (#23) and the upper left second premolar (#25) they were deemed unrestorable by the prosthodontist. The patient was informed of all the risk that the extraction and implant procedure might carry, and she was also informed of the alternative treatment options, but she elected to go with the dental implant treatment plan and gave a written consent.

The teeth had no radiopaque lesions associated with them, therefore atraumatic extractions of both teeth were carried, and the patient was prescribed antibiotics (Augmentin™ 625 mg + Flagyl™ 250 mg) post operatively alongside ibuprofen 400 mg as an analgesic. Follow-up was carried out every 2 days for a total of 10 days, and the healing of the sockets was uneventful (Figure 2).

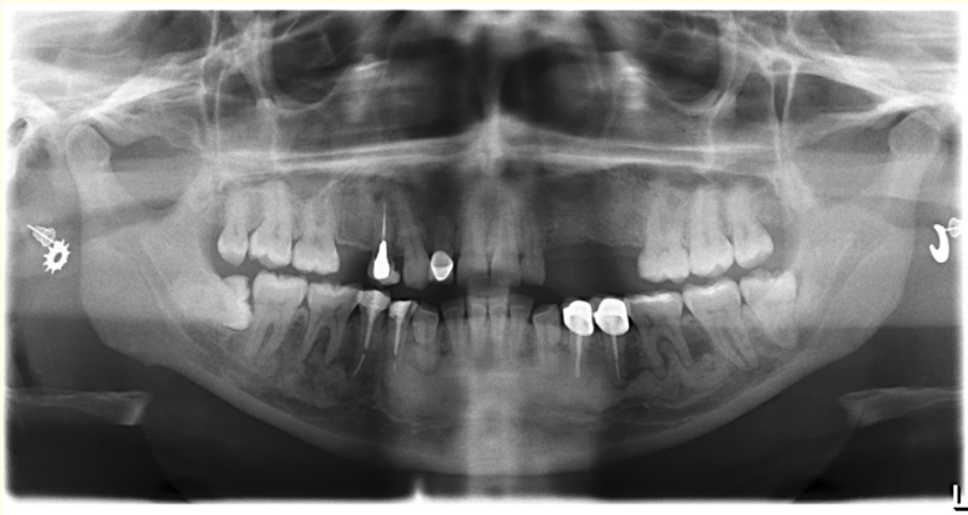
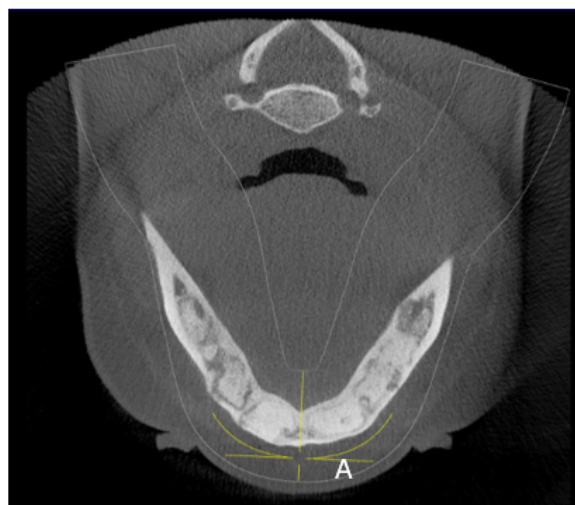


Figure 2: Post-extraction Panoramic radiograph.

After 3 months the patient was scheduled for a CBCT to evaluate the healing of the bone, and no additional radiopaque lesions have developed and none of the pre-existing lesions have expanded. Therefore, in order to avoid the aforementioned radiopaque lesion in the area of the missing first premolar (#24); the dental implants treatment plan was to place two implants in the extracted canine (#23) and second premolar (#25) using a two-stages approach with a fixed dental prosthesis supported by the two dental implants with the first premolar being replaced by a pontic and the canine and second premolar as abutments (Figure 3).



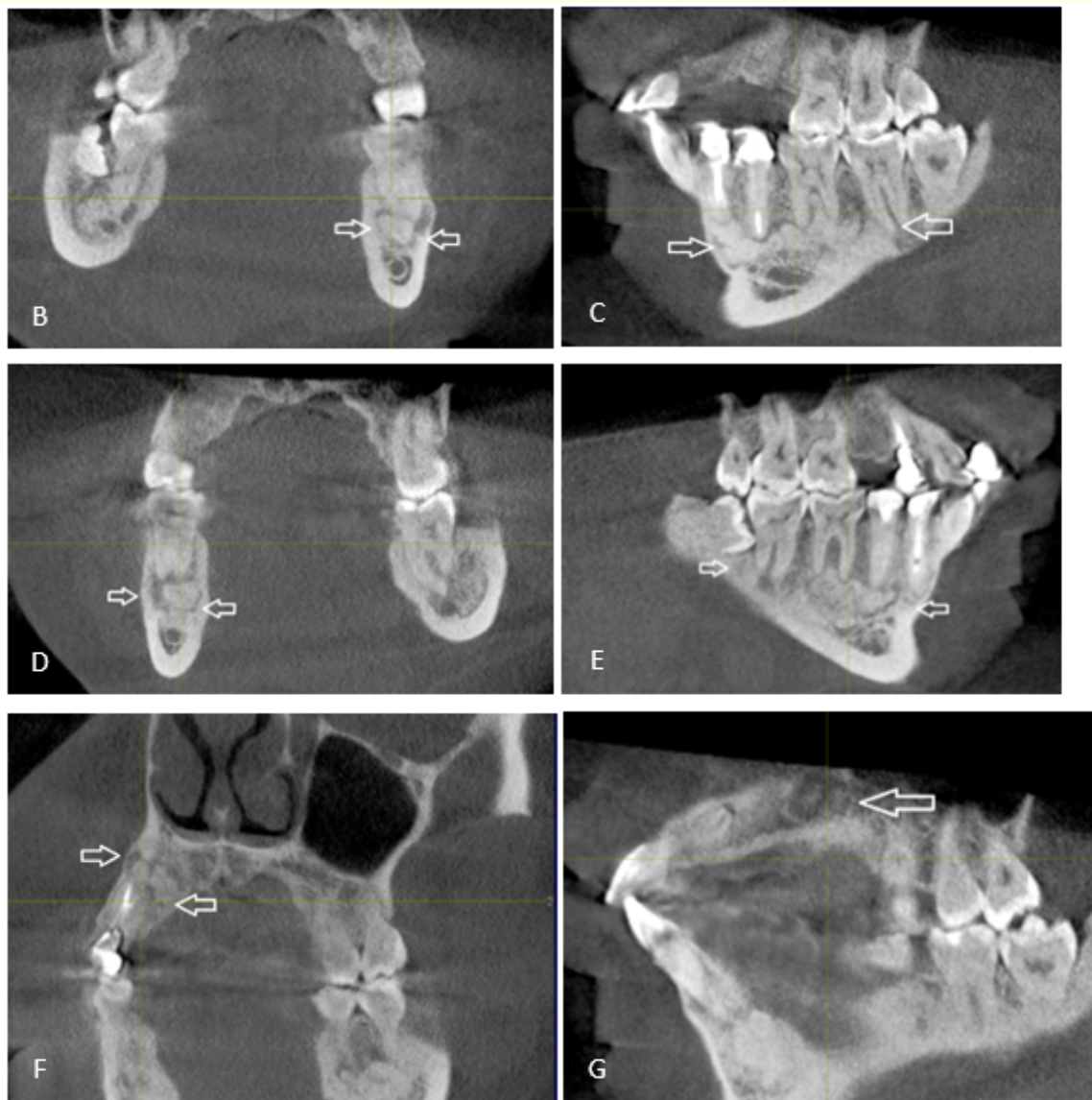
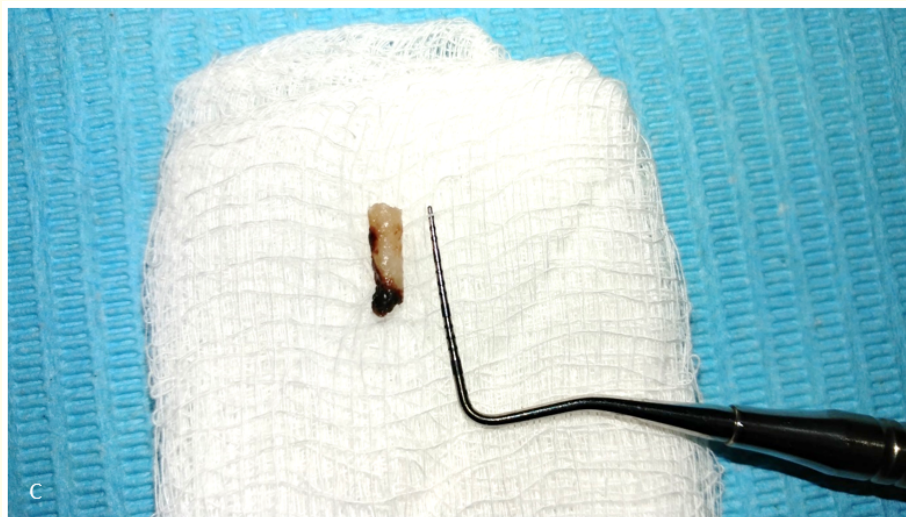
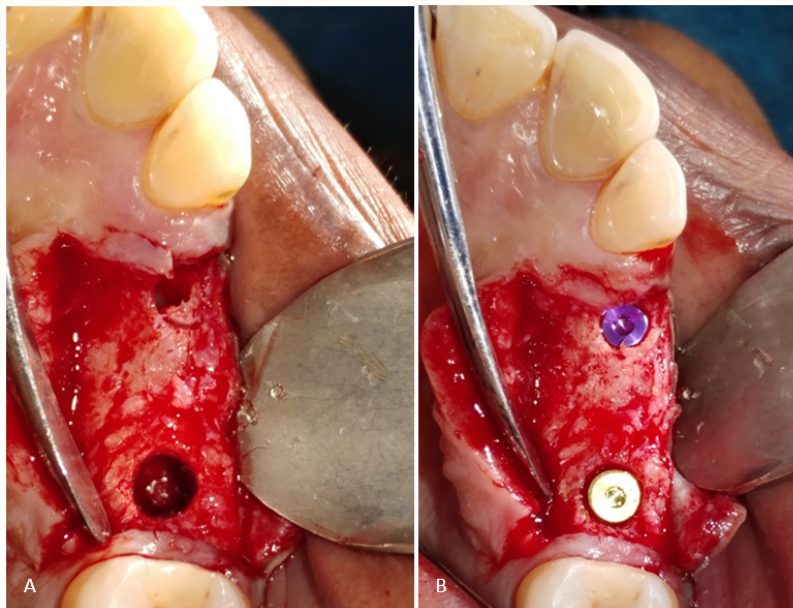


Figure 3: Post-extraction CBCT scan. A: A cross-sectional view of the mandible showing the extension of the FCOD lesions from the mesial aspect of the left 2nd molar to the distal aspect of the right 2nd molar. B: An axial view of a FCOD lesion in the left mandible. C: A sagittal view of a FCOD lesion in the left mandible. D: An axial view of a FCOD lesion in the right mandible. E: A sagittal view of a FCOD lesion in the right mandible. F: An axial view of a FCOD lesion in the maxillary right premolars area. G: A sagittal view of a FCOD lesion on the maxillary left 1st premolar area.

A combined full thickness and partial thickness flap was raised extending from the distal side of the upper left lateral incisor to the mesial side of the upper left first molar. A 3 mm trephine bur was used to successfully obtain a histological sample from the area of the second premolar (#25) but was unsuccessful in the area of the canine (#23) due to the ridge thickness and bone hardness. A histological

sample of 3 mm diameter and 10 mm length was collected and placed in a container containing formaldehyde. The implants were placed using the Nobel BioCare Replace Conical Connection system™, in the canine area (#23) an implant size 3.5 mm x 10 mm was placed with a 35 Ncm torque, and in the second premolar area (#25) an implant size 4.3 mm x 10 mm was placed with a 30 Ncm torque, both implants were covered by cover screws and the flap was sutured using 4.0 polyglycolic absorbable sutures. Again, the patient was prescribed antibiotics (Augmentin™ 625 mg + Flagyl™ 250 mg) post operatively alongside Ibuprofen 400 mg as an analgesic. The patient was followed-up every 2 days up to 14 days post operatively, and the healing was uneventful, after 14 days the sutures were removed, and then monthly follow-ups were scheduled (Figure 4).



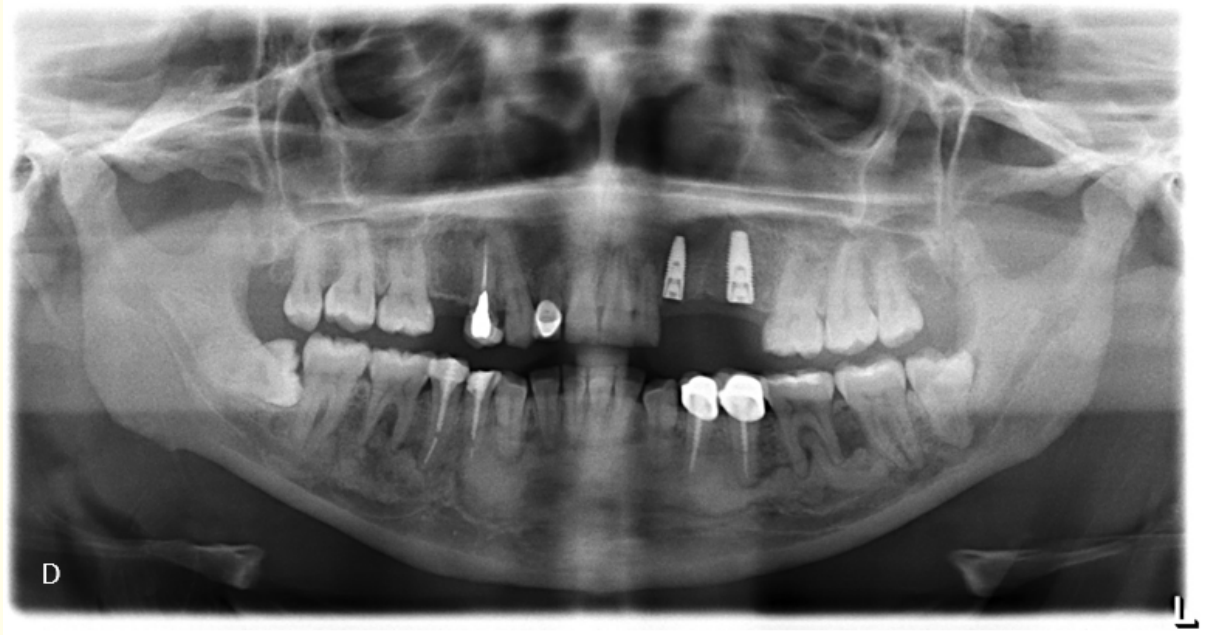


Figure 4: A: Osteotomy after histological sample collection. B: Implants placement in the canine and 2nd premolar areas. C: The collected histological sample 3mm x 8mm. D: Post-operative Panoramic radiograph of the implants' placement.

The Histological report by the oral pathologist on the sample obtained from the area of the upper left second premolar (#25) which has no radiographic signs or opacities stated that the hematoxylin and eosin stain view shows fragments of surgical curetted bone with numerous spicules of lamellated woven bone trabeculae rimmed by osteoblast cells embedded in a loose fibrous stroma. Areas of surgical hemorrhage are observed in the stroma with few scattered inflammatory cells infiltrates. The features are consistent with normal alveolar bone (Figure 5).

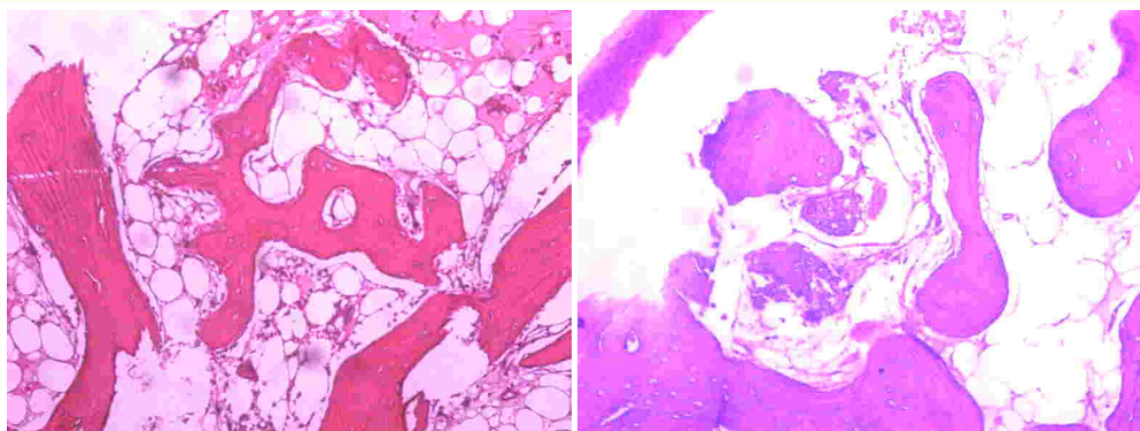


Figure 5: Histological analysis utilizing hematoxylin and eosin stain with 20x magnification.

After 3 months of the implant placement; the patient was scheduled for the healing abutments placement. A gingival punch drill was used to expose the implants' cover screws, and the healing abutments were placed successfully. Two weeks later the patient was referred to the prosthodontics clinics and finalized the placement of the metal ceramic fixed dental prosthesis as planned. 3 Months follow-up has shown no changes or signs of inflammation/infection to the areas of implants placements (Figure 6).

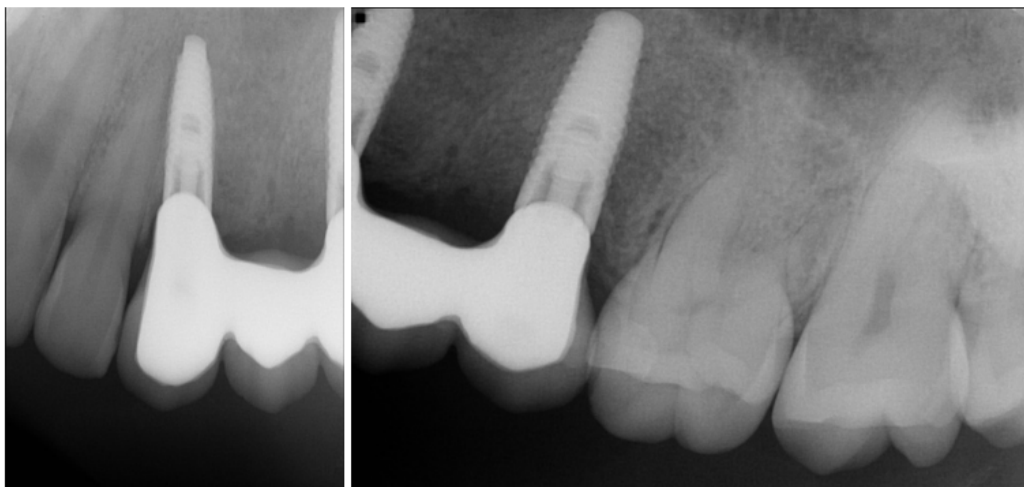


Figure 6: Periapical radiographs of the fixed dental prosthesis loaded implants.

Discussion

The osseous dysplasia (OD) lesions of the jaws still present a challenge in the diagnosis of oral and maxillofacial pathologies, of which there are three main categories to the OD lesions, the periapical, the florid and the focal cemental dysplasia [8]. The Florid Cemento-Osseous Dysplasia FCOD was first introduced in 1976 and currently includes lesions previously identified as cementomas and gigantiform cementomas [1].

In FCOD females are mostly affected, but males can be affected too with the ratio being 1:2.6 when compared to the females [9]. In this case report the patient falls in the most affected category being a 35 years old black female, and she had no other family member or relative having any radiographic signs resembling FCOD.

The main complications that might affect a patient with FCOD is spreading of the infection to the lesions, developing osteomyelitis or sequestration of the bone. Therefore, the best treatment modalities for patients with FCOD are prophylactic and preventive treatment options with constant follow-up and maintenance visits.

In this case report, the areas of FCOD lesions were avoided completely as the risks of infiltrating them is well documented in the literature [10]. But what was accomplished is to prove the safety of the dental implant placement procedure in the areas adjacent to the FCOD lesions in which falls in agreement with a recent case report [11] and with the histological sample showing no characteristics of FCOD in the radiographically safe area we can rely on the conventional dental radiographs to designate the safe areas for intervention if the FCOD lesions are far away from the surgery areas. And if the FCOD lesions are in close proximity to the surgery area then a CBCT scan is indicated as the 3 dimensional views offer a more accurate designation of the safe area [8].

Conclusion

FCOD is a serious condition that contraindicates most surgical procedures in the lesion areas, as to the adjacent safe areas some surgical procedures like atraumatic extractions and minimally invasive dental implant placement can be cautiously performed after informing the patient of all the associated risks and obtaining a written consent. And the Panoramic radiographs can be used to determine the safe areas with acceptable accuracy, while the CBCT scans offer much better accuracy and are indicated if the surgery area is in very close proximity to a FCOD lesion.

Acknowledgments

I would like to extend my appreciation to Dr. Raed Salma and Dr. Bara'a Abdulrahman for helping in the diagnosis of the case. And to Dr. Rohit Fernandez and Dr. Nida Al-Fataftah for the prosthodontic part of the treatment.

Bibliography

1. Melrose RJ, et al. "Florid osseous dysplasia. A clinical-pathologic study of thirty-four cases". *Oral Surgery, Oral Medicine, Oral Pathology* 41.1 (1976): 62-82.
2. Miyake M and S Nagahata. "Florid cemento-osseous dysplasia. Report of a case". *International Journal of Oral and Maxillofacial Surgery* 28.1 (1999): 56-57.
3. Fenerty S, et al. "Florid cemento-osseous dysplasia: review of an uncommon fibro-osseous lesion of the jaw with important clinical implications". *Skeletal Radiology* 46.5 (2017): 581-590.
4. MacDonald-Jankowski DS. "Florid cemento-osseous dysplasia: a systematic review". *Dentomaxillofacial Radiology* 32.3 (2003): 141-149.
5. Waldron CA. "Fibro-osseous lesions of the jaws". *Journal of Oral and Maxillofacial Surgery* 43.4 (1985): 2492-62.
6. Kutluay Koklu H, et al. "Florid cemento-osseous dysplasia: Report of a case documented with clinical, radiographic, biochemical and histological findings". *Journal of Clinical and Experimental Dentistry* 5.1 (2013): e58-e61.
7. Damm DD and JE Fantasia. "Multifocal mixed radiolucencies. Florid cemento-osseous dysplasia". *General Dentistry* 49.5 (2001): 461, 538.
8. Kim JH, et al. "Clinical, radiographic, and histological findings of florid cemento-osseous dysplasia: a case report". *Imaging Science in Dentistry* 41.3 (2011): 139-142.
9. Sanjai K, et al. "Florid cemento osseous dysplasia in association with dentigerous cyst". *Journal of Oral and Maxillofacial Pathology* 14.2 (2010): 63-68.
10. Consolaro A, et al. "Florid cemento-osseous dysplasia: a contraindication to orthodontic treatment in compromised areas". *Dental Press Journal of Orthodontics* 23.3 (2018): 26-34.
11. Esfahanizadeh N and H Yousefi. "Successful Implant Placement in a Case of Florid Cemento-Osseous Dysplasia: A Case Report and Literature Review". *Journal of Oral Implantology* 44.4 (2018): 275-279.

Volume 18 Issue 10 October 2019

©All rights reserved by Rakan S Shaheen.