

## Clinical Management of Maxillary Central Incisor Extraction for Orthodontic Treatment- A Case Report

Jose Jacob<sup>1\*</sup>, Balakrishna Shetty<sup>2</sup>, Vivek Suku Ninan<sup>3</sup>, Sudeep C Bhagavandas<sup>4</sup> and Joseph Johny<sup>5</sup>

<sup>1</sup>Assistant Professor, Department of Orthodontics, Sree Anjeneya Institute of Dental Sciences, Calicut, Kerala, India

<sup>2</sup>Professor, Department of Orthodontics, Coorg Institute of Dental Sciences, Karnataka, India

<sup>3</sup>Assistant Professor, Department of Orthodontics, Pushpagiri College of Dental Sciences, Thiruvalla, Kerala, India

<sup>4</sup>Assistant Professor, Department of Public health Dentistry, Sree Anjeneya Institute of Dental Sciences, Calicut, Kerala, India

<sup>5</sup>Assistant Professor, Department of Oral Medicine and Radiology, Sree Anjeneya Institute of Dental Sciences, Calicut, Kerala, India

**\*Corresponding Author:** Jose Jacob, Assistant Professor, Department of Orthodontics, Sree Anjeneya Institute of Dental Sciences, Calicut, Kerala, India.

**Received:** July 26, 2019; **Published:** August 27, 2019

### Abstract

Orthodontic treatment in patients with trauma to the anterior teeth is challenging particularly when it involves the maxillary incisor teeth. Careful treatment planning and mechanics is needed to ensure good treatment results. This case report is on a 12-year-old boy who suffered multiple trauma to his upper central incisors, with generalized crowding in the upper and lower arch. Extractions of both his central incisors were performed and lateral incisors were converted to central incisors and canines to laterals. This case report outlines the various esthetics and biomechanical constraints in the extraction of the central incisors and how to successfully counter them for optimum treatment results.

**Keywords:** Orthodontics; Aesthetics; Extraction

### Introduction

Extraction versus non-extraction in orthodontic patients has been an area of debate since the early 20<sup>th</sup> century. This still remains as an area of controversy. Though modern orthodontist prefers a non-extraction treatment approach for their patients, extraction is inevitable in certain situations like, Tooth size - arch length discrepancy (severe crowding), Bimaxillary dentoalveolar protrusion, Skeletal disharmony and camouflage treatment etc. The most common teeth extracted for an orthodontic procedure are the premolars. But in certain specific situations like dental caries, trauma, localized periodontitis, dilacerations, we do extract other teeth like the molars or the lower incisors. The maxillary central incisors are the least common tooth to be extracted owing to esthetics during and post orthodontic treatment [1].

The major challenges for extraction of the maxillary central incisors are [2-6]:

1. Size of the central and lateral incisors
2. Gingival margins of the anterior tooth
3. Canine root prominence
4. Aesthetics during the orthodontic procedure

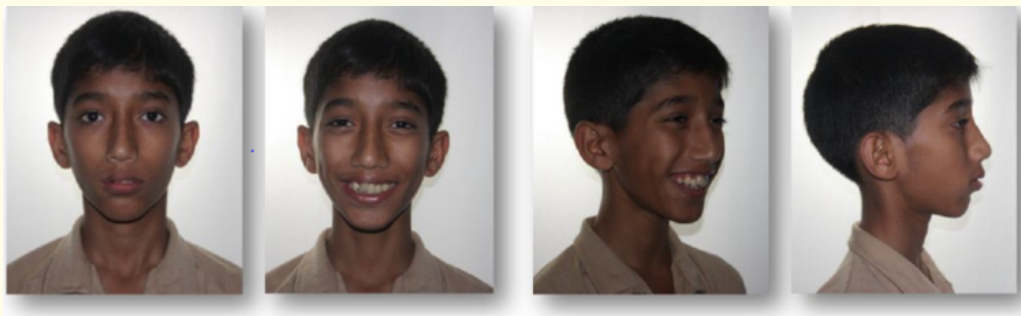In this case report we discuss the orthodontic treatment procedure done with extraction of two maxillary central incisors and lower premolars.

**Case Report**

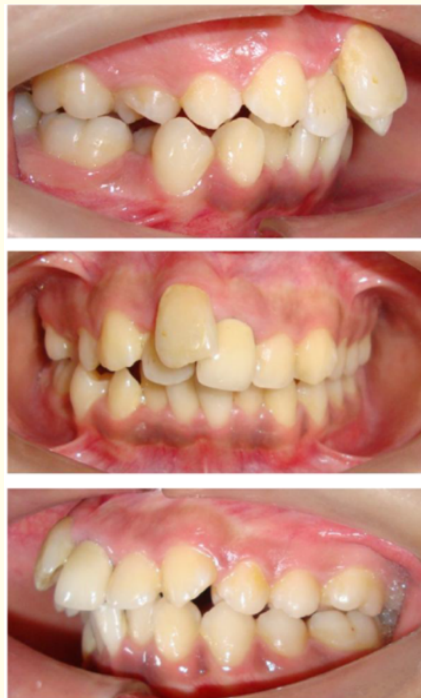The patient was a twelve-year-old boy with good physical health. He had a symmetric face with a convex soft tissue profile. His chief complaint was the misalignment of his anterior teeth. He had suffered a trauma to his central incisors and was avulsed. Immediately after avulsion the tooth was repositioned and splinting done Root canal treatment was done on both the incisors and crown was placed on 11. Extra oral examination showed increased vertical skeletal proportions, increased lower facial third and leptoprosopic facial type.

Intraoral examination showed end on molar relations, generalized crowding in the upper and lower arch with increased overjet.

Cephalometric evaluation showed class 2 skeletal pattern with vertical growth pattern with proclined upper and lower anteriors (Figure 1-12).



*Figure 1-4: Pretreatment extara oral.*



*Figure 5-7: Pre-treatment intra oral.*

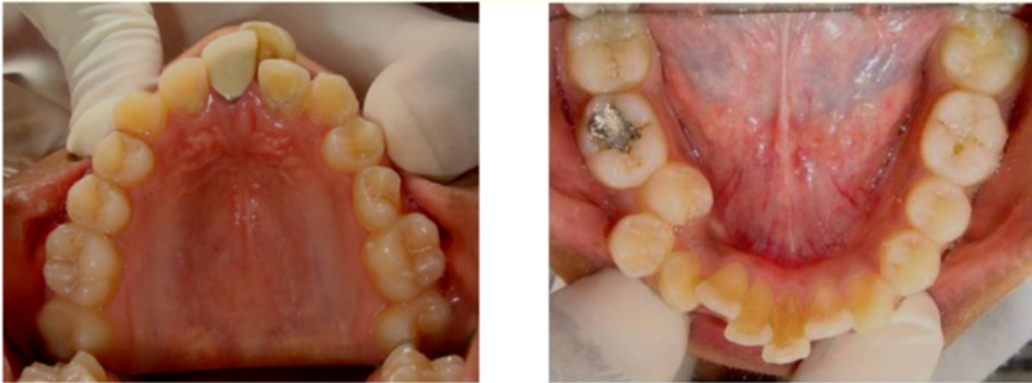

Figure 8 and 9: Pre-treatment occlusal.

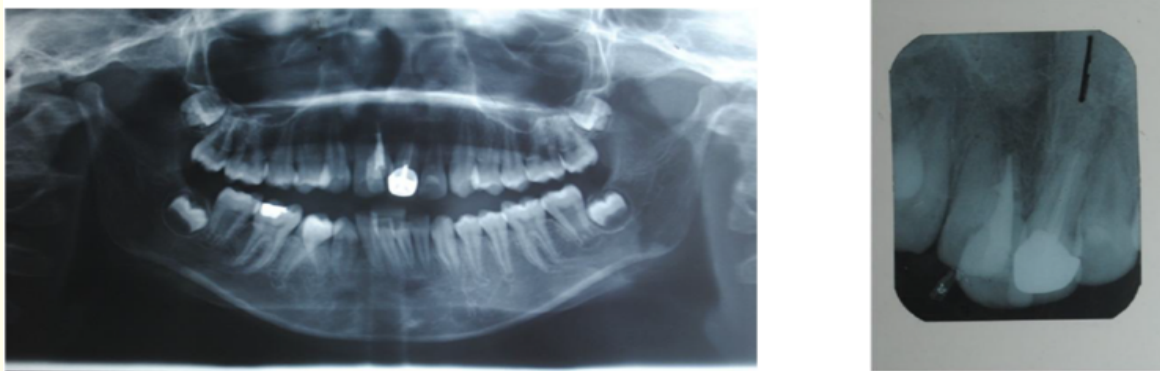

Figure 10 and 11: Pre-treatment Opg and IOPAR of 11, 12.

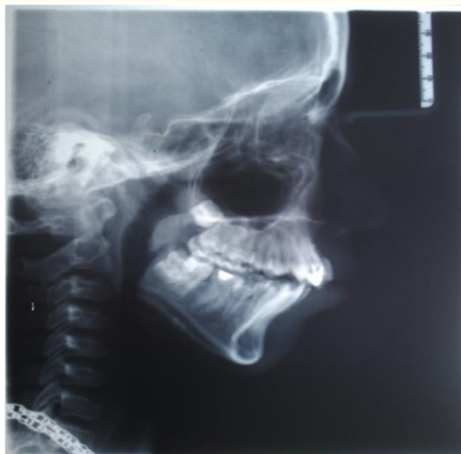

Figure 12: Pre-treatment lateral cephalogram.

Based on these findings the treatment options were made:

- **Option 1:** Extraction of all 4 premolars followed by retraction of incisors and alignment with corticotomy on the ankylose incisors.
- **Option 2:** Extraction of both central incisors and lower premolars followed by prosthetic correction of the lateral incisors and enameloplasty of the canines.
- **Option 3:** Extraction of both the central incisors and lower premolars followed by a complete prosthetic correction from upper 1<sup>st</sup> premolar to premolar.
- **Option 4:** Autotrasplantation of the premolars to the maxillary incisors extraction sockets [7,8].

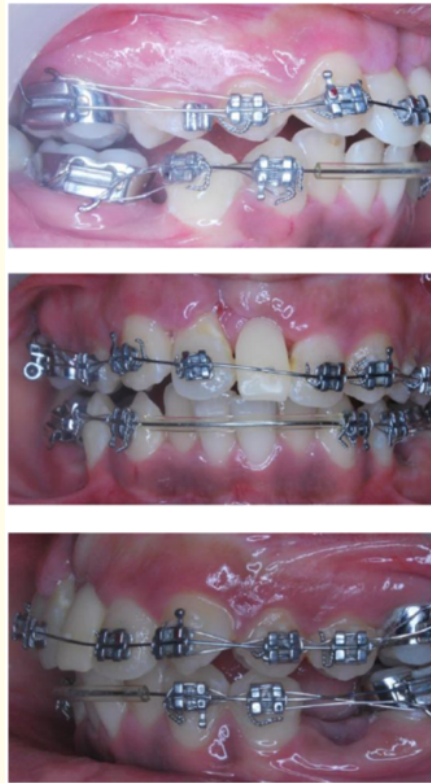All the treatment options were explained to the patient and based on surgical procedure involved and the patient preference it was decided for extraction of both the central incisors and prosthetic correction of lateral incisors.

**Treatment progress**

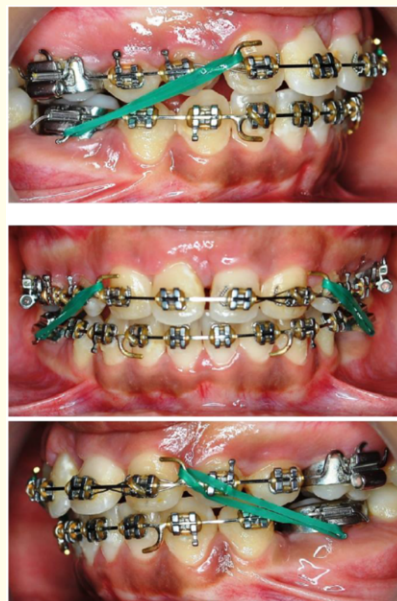
The first stage involved the removal of both the upper central incisors and lower second premolars. Care was taken to preserve the cortical bone during extraction particularly in the anterior region. Immediately after extractions the case was bonded with 022” MBT brackets and molars were banded with straight wire tubes. Care was taken during bonding to ensure the best esthetic out come due to the minimal prosthetic correction intended after the fixed treatment phase. The central brackets were placed on the laterals and the lateral brackets were placed on the canines to ensure the correct torque expression and positioning was intended to intrude the lateral incisors and extrude the canine.

Ryder pontic was placed on the central incisor extraction site and was gradually trimmed to provide space for alignment (Figure 13). Conventional treatment methods were followed. Initial leveling and alignment was done with 014” Ni-Ti wire, followed by 016” Ni-Ti wire and Rectangular Ni-Ti wires (17 X 25) were introduced for early torque expression. The leveling and alignment stage was followed by 19 X 25 stainless steel wire for space closure and class 2 elastics were worn for a short period of time to correct the molar relation. The space for the lateral build up was maintained by a metal sleeve introduced between the central incisors and a stop introduced in front of the molars (Figure 14). 21 X 25 stainless steel wire was introduced just before the finishing stages for adequate torque expression.

Normal MAXILLA	SNA 82 DEGREE
RETROGNATHIC MANDIBLE	SNB 76DEGREE
CL II SK RELATION	BY ANB OF 6 DEGREE
VERTICAL GROWTH PATTERN	MAND PLANE OF 44 DEGREE
<b>Proclined upper and lower incisors</b>	<b>Inter incisal angle 112 degree</b>
Proclined upper incisors	UI - SN=112 degree
Proclined lower incisors	LI-MP=97 degree
Nasolabial Angle	97 degree



**Figure 13:** Initial wire (014 niti) with ryder pontic.



**Figure 14:** Class 2 elastics with molar stops.

By the completion of orthodontic treatment, prosthodontic alteration was carried out. The maxillary lateral incisors were built up with Z100-3M resin composite to resemble central incisors. Enameloplasty was carried out on the canines to resemble lateral incisors. The palatal cusps of the first bicuspid were grinded as well to make these teeth ready to serve as canines (Figure 15-26).

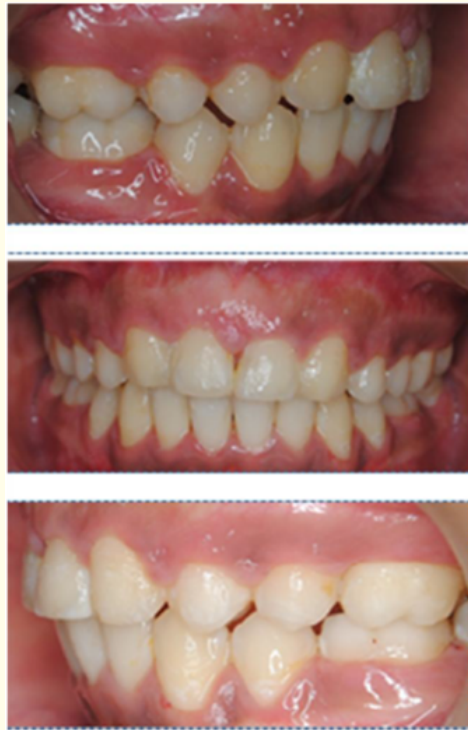

Figure 15-17: Post treatment intraoral.

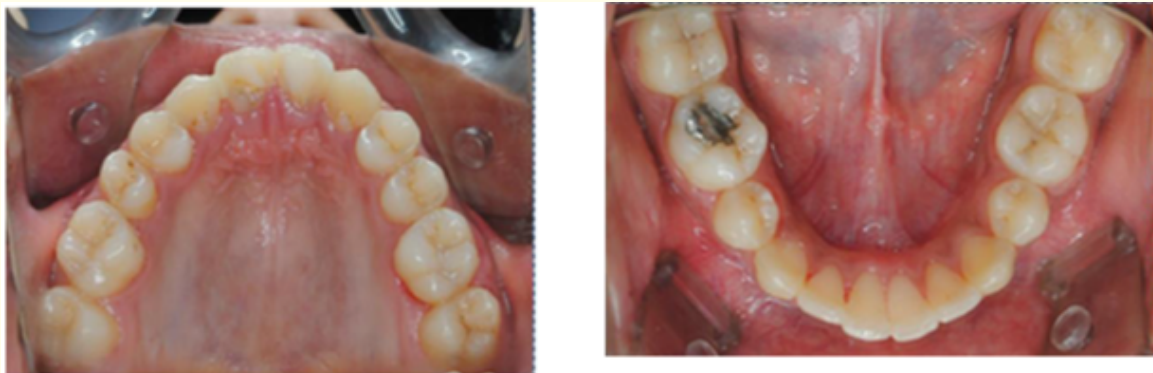

Figure 18 and 19: Post treatment occlusal.


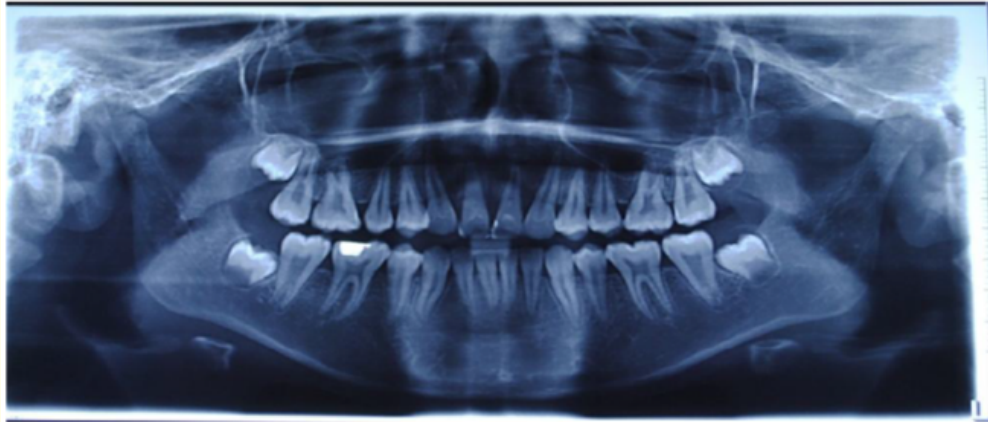


Figure 20-24: Post treatment extraoral.

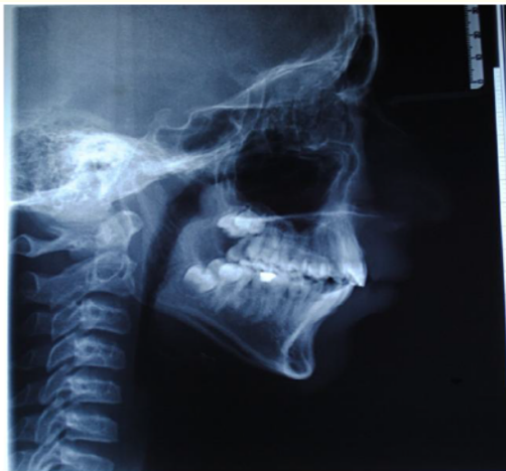

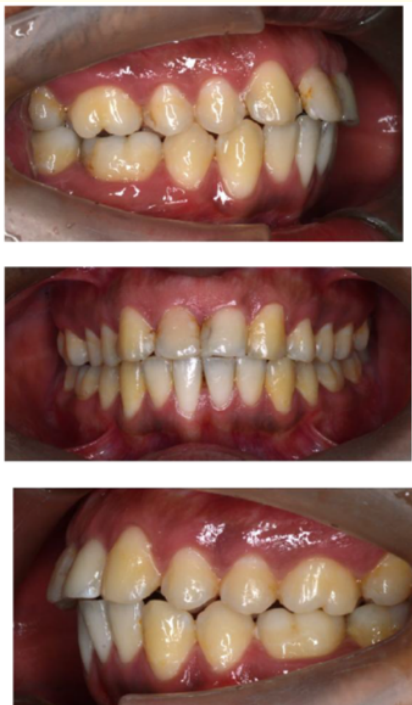Figure 25: Post treatment lateral cephalogram.

Normal MAXILLA	SNA 82 DEGREE
RETROGNATHIC MANDIBLE	SNB 79 DEGREE
CL II SK RELATION	BY ANB OF 3 DEGREE
VERTICAL GROWTH PATTERN	MAND PLANE OF 43 DEGREE
Normally positioned upper and lower incisors	Inter incisal angle 129 degree
Normally positioned upper incisors	UI - SN=98 degree
Normally positioned lower incisors	LI-MP=90 degree
Nasolabial Angle	Normal (102 degree)




**Figure 26:** Post treatment OPG.

Ginvioplasty was carried out in the maxillary anterior region to improve the esthetics. In spite of the extrusion of the canines the gingival margin was slightly highly placed but patient was satisfied with the results and was not willing for any further treatment to improve the esthetics. The patient was put on permanent retention at the end of active treatment. Follow up appointments were made every 6 months and the occlusion remained stable with minimal relapse even on 2 year follow-up (Figure 27-34).



**Figure 27-29:** 2-year follow-up post treatment intraoral.



**Figure 30-34:** 2-year follow-up post treatment extraoral.

## Discussion

The extraction of anterior teeth for orthodontic purpose is rare and challenging, but certain situations demand such a procedure. Careful treatment planning and mechanics can restore esthetics and function in such cases. Care should be taken right from case selection to retention and is indicated in such case were the roots are ankylosed due to a trauma as in above or there is a developmental anomaly and extraction for orthodontic procedure is advocated.

During the procedure care should be taken parallel the roots of the lateral incisors, match the gingival contours for esthetic post treatment appearance, rotate the first premolar mesiopalatally and leave space for the lateral incisor build-up.

Functional occlusion should also be taken into consideration and non working side interferences during mandibular extrusions should also be eliminated to achieve long term stability and good TMJ function. The prevalence of nonworking side interferences and overall temporomandibular joint health is almost identical in subjects treated with orthodontic space closure or prosthetic replacement with absent lateral incisors [10]. Therefore, central incisor substitution is also unlikely to have a prolonged influence on temporomandibular integrity [11]. The gingival margin is of prime concern in such central incisor extraction cases. The lateral incisor should be intruded to push the gingival margin more apically to mimic a central incisor and the canine should be extruded to pull the gingival margin more coronally. In this case initial bracket positioning was done to achieve the same. The torque expression is also of prime importance. The canine should be given a positive root torque to minimize the canine eminence, this can be either done by using a positive torque canine bracket or replacing a lateral incisor brackets. Individual root torquing auxiliaries can also be incorporated for additional torquing, the first premolars are given a mesiopalatal rotation to maintain the golden proportions. During space closure the force levels should be minimal to prevent the tipping of the lateral incisors. The roots should be kept parallel as possible to prevent unwanted space opening. A central incisor bracket on the lateral incisor would help in achieving this by providing good tip and torque control. Second order bends can also be used in the finishing stages to achieve this. Autotrasplantation is also an option in cases involving avulsion of the teeth with arch length discrepancy,

Successful auto transplantation for such cases has been effectively carried out,<sup>7</sup> but in this case the option was discarded owing to the tooth position and the surgical technique sensitivity involved.

In this case to correct the molar relation, second premolars were extracted, additional mesial tip was incorporated in the lower canine and short term class 2 elastics were given with molar stops and metal sleeve to maintain the upper arch length. But owing to the growth status of the patient and mild lower molar rotations we were not able to continue the class 2 elastics for a longer time. Age of the patient is definitely a criterion for case selection, older patients refrain from such anterior extractions considering the edentulous period involved, in this case we have managed it with a Ryder pontic attached to the adjacent tooth with composite.

At the end of treatment an acceptable esthetics and functional occlusion was achieved. It would have been better if the canine intrusion was carried to a few millimeters to make the gingival contour more apically. Option of extending the treatment phase for complete molar correction and settling was discussed with the patient, but due to his time constraints we were not able to do so. But we feel that we were highly successful in improving the patient esthetics, giving the patient a much-needed psychological boost, by following the most conservative treatment approach possible. A 2 year follow-up recall of the patient showed a well settled occlusion in molar and premolar regions. Cephalometric analysis showed a significant decrease in the ANB angle probably due to the natural repositioning of the mandible forward due to the removal of anterior teeth hindrances by alignment of teeth.

### Conclusion

Many factors attribute to the decision on which tooth to be extracted during an orthodontic treatment. But certain situations like trauma or developmental disturbances force a clinician to extract teeth that are not commonly indicated for treatment. Treatment planning and proper biomechanics can help us overcome this hurdle and restore esthetics and function.

### Bibliography

1. Kokich VG and Crabill KE. "Managing the patient with missing or malformed maxillary central incisors". *American Journal of Orthodontics and Dentofacial Orthopedics* 129.4 (2006): S55-S63.
2. Kokich V, et al. "Gingival contour and clinical crown length: their effects on the esthetic appearance of maxillary anterior teeth". *American Journal of Orthodontics* 86.2 (1984): 89-94.
3. Kokich VG and Kokich VO. "Interrelationship of orthodontics with periodontics and restorative dentistry". In: Nanda R, editor. *Bio-mechanics and esthetic strategies in clinical orthodontics*. St. Louis: Elsevier (2005).
4. Kokich V. "Anterior dental esthetics: an orthodontic perspective I Crown length". *Journal of Esthetic Dentistry* 5.1 (1993): 19-23.
5. Kokich VG and Spear F. "Guidelines for managing the orthodontic restorative patient". *Seminars in Orthodontics* 3.1 (1997): 3-20.
6. Kokich VG. "Esthetics and vertical tooth position: the orthodontic possibilities". *Compendium of Continuing Education in Dentistry* 18.2 (1997): 1225-1231.
7. Zachrisson B, et al. "Management of missing maxillary anterior teeth with emphasis on autotransplantation". *American Journal of Orthodontics and Dentofacial Orthopedics* 126.3 (2004): 284-288.
8. Bowden D and Patel H. "Autotransplantation of premolar teeth to replace missing maxillary central incisors". *British Journal of Orthodontics* 17.1 (1990): 21-28.
9. Kramer P, et al. "Rehabilitative treatment after unsuccessful teeth replantation: a case". *Journal of Clinical Pediatric Dentistry* 26.2 (2002): 119-124.
10. Robertsson S and Mohlin B. "The congenitally missing upper lateral incisor. A retrospective study of orthodontic space closure versus restorative treatment". *European Journal of Orthodontics* 22.6 (2000): 697-710.
11. Fleming PS, et al. "Combined orthodontic restorative management of maxillary central incisors lost following traumatic injury: a case report". *Orthodontics* 12 (2011): 242-251.

**Volume 18 Issue 9 September 2019**

**©All rights reserved by Jose Jacob, et al.**