

## Oral Myiasis in a Living Individual with Diabetes - A Case of Insect Colonisation and Review of Literature

Aditya Mohan Alwala<sup>1</sup>, MVS Sudhir<sup>2\*</sup>, Praveen Vasamsetty<sup>2</sup>, Ayona Saha<sup>2</sup> and Srikanth Damera<sup>3</sup>

<sup>1</sup>Reader, Department of Oral and Maxillofacial Surgery, MNR Dental College and Hospital, Sangareddy, Telangana, India

<sup>2</sup>Consultant Oral and Maxillofacial Surgeon, Hyderabad, Telangana, India

<sup>3</sup>Reader, Department of Oral and Maxillofacial Surgery, GSL Dental College and Hospital, Rajahmundry, Andhra Pradesh, India

\*Corresponding Author: MVS Sudhir, Consultant Oral and Maxillofacial Surgeon, Hyderabad, Telangana, India.

Received: July 24, 2019; Published: August 22, 2019

### Abstract

The term myiasis reveals the infestation of live human and vertebrate animals with Diptera fly larvae, which feed on living or dead host tissue, liquid body substance or ingested food for a certain period of time. Oral myiasis is related to poor oral hygiene, and if neglected, it tends to cause real life threatening damages. It occurs in tropical ranges with poor living conditions and lacking open and individual cleanliness. The commonest clinical indications of myiasis infestation are inflammatory, allergic reactions, and unfavorably susceptible responses. It can occur secondary to medical or anatomic conditions, such as cancrum oris, neglected mandibular fracture, cerebral palsy, uncontrolled diabetes, mouth breathing, anterior open bite, incompetent lips, and use of mechanical ventilation. It also has been described after tooth extraction. Treatment comprises of manual expulsion of larvae, followed by medical and surgical management. Use of broad spectrum anti-microbial like Ivermectin has been proved quite effective. Myiasis rarely affects the oro-dental complex. Here we presented a case report describes oral myiasis in a 40-year-old male patient who visited the dentist with a chief complaint of extrusion of insect larva from left eye region and regurgitation of fluids into the nose. Parasitological examination revealed the larvae as *Chrysomya bezziana*. Case details were discussed in relation to clinical presentation, pathogenesis, management, and prognosis.

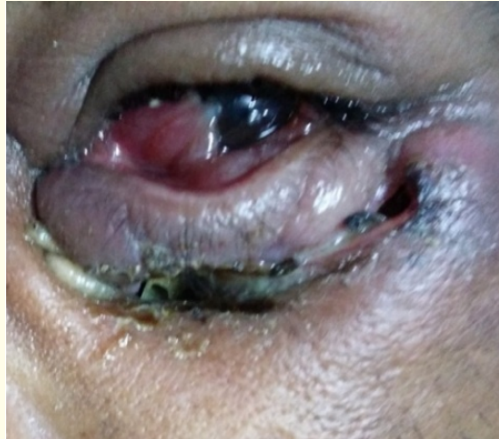**Keywords:** Myiasis; *Chrysomya bezziana*; Maggots; Larvae; Ivermectin

### Introduction

Myiasis is a parasitic disease that occurs when tissues, organs and body cavities of humans and animals are invaded and infested by fly larvae of order Diptera [1]. In humans, these larvae tend to develop in the skin, soft tissues, necrotic tissue, cutaneous wounds with non-necrotic tissue and in body cavities where secretions accumulated with higher bacterial load mimicking pabulum for larvae [2,3]. In general human myiasis can be classified into two groups, i.e. specific and semi specific. In specific myiasis, the flies are in need of a live host to develop through their immature stages, where as in semi specific myiasis the flies develop in decomposing organic matter and occasionally on/ in living organisms mainly in the presence of wounds [4,5]. In humans, myiasis prevails in unhealthy individuals and often occurs as evidence of neglect of hygiene, in immunocompromised and low socio-economic status individuals. Oral myiasis is a rare pathology and is associated with poor oral hygiene, alcoholism, senility, conditions that are likely to cause prolonged mouth opening, mouth opening at times of sleep and mental retardation [6-8]. As oral tissues are not in continuous exposure to the external environment; the incidence of oral myiasis is comparatively less compared to cutaneous myiasis [9]. In this paper, we present a case report of oral myiasis caused by *Chrysomya bezziana* in a 40-year-old male. The details of diagnosis and subsequent treatment planning were discussed in detail.

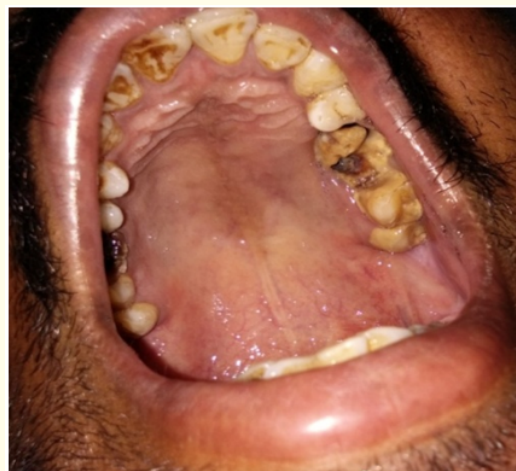### Case Report

A 40-year-old male patient was reported to the private Dental Clinic with a chief complaint of “bugs coming out near the left eye region and running nose” since past 4 - 5 days (Figure 1). The patient underwent extraction of left maxillary teeth one year ago. He is from a low socioeconomic background, malnourished, and had poor oral hygiene with severe halitosis. Medical history revealed that the patient was diabetic, and he had a deleterious habit of alcohol consumption since 10 - 15 years. The patient was febrile with a body temperature of 101°F.



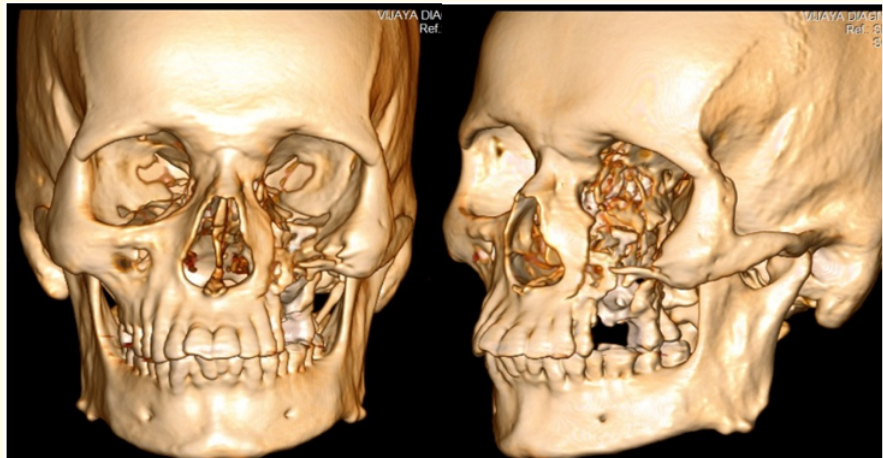
**Figure 1:** Extraoral photograph showing swelling in the left infraorbital region with maggots coming out of the sinus opening.

There was a sinus opening in the left infra-orbital region with inflamed surrounding conjunctiva. Maggots were seen coming out of the sinus opening. Oro-antral communication is seen in the left maxillary region around the region of the second premolar and first molar (Figure 2). The surrounding area was swollen and erythematous. The alveolar bone in area 25 and 26 is denuded and necrotic with persistent pus discharge.



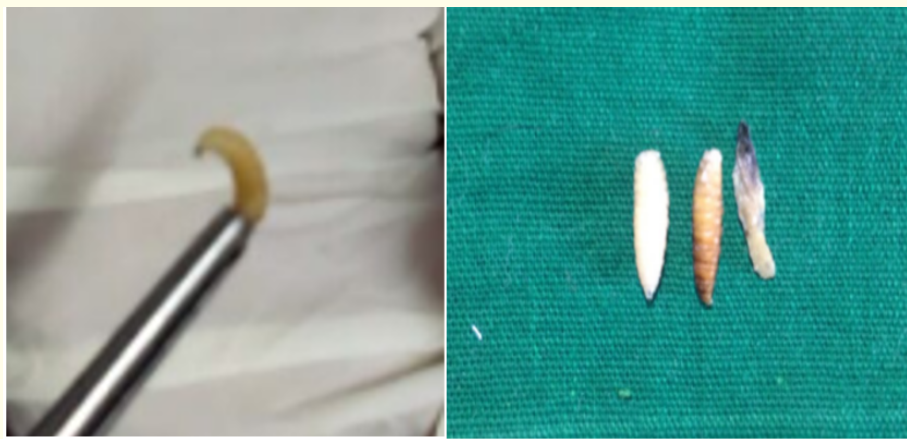**Figure 2:** Intraoral examination showing oro-antral communication in the left maxillary region.

Complete blood picture revealed leukocytosis (WBC count of 18000 cells/mm<sup>3</sup>). Random blood glucose estimated was 360mg/dl, which was quite high. 3D CT scan of the face showed gross destruction of the body of maxilla, maxillary sinus, ethmoid sinus, and infraorbital rim on the left side (Figure 3).



**Figure 3:** 3D CT Scan of the face showing gross destruction of Body of the maxilla.

Maggots were manually removed under local anesthesia prior to surgery by “occlusion or suffocation” method using turpentine oil. Cotton ball impregnated with the oil were placed within the sinus opening and intra-orally in the oro-antral communication. The larvae started coming out near the surface in search of air and then were removed (Figure 4). Later the larvae were sent to the department of parasitology for entomological examination, and the reports revealed that the larvae belonged to “Chrysomya bezziana” group which are predominantly found in the Indian subcontinent. Subsequent surgical management includes extraction of periodontally weakened teeth, debridement of necrotic bone and infected soft tissue. After extensive wound irrigation with saline solution and metronidazole, turpentine oil was applied to remove any remaining larvae. Hydrogen peroxide was applied over the wound to induce bleeding and subsequent healing. Lastly, wound closure was done in layers. The intra oral wound is left with an antibiotic soaked gauze pack. The patient was advised with a high protein diet and prescribed with Ivermectin 6mg orally for 15 days and Ceftriaxone 2 gm per day for 1 week.



**Figure 4:** Larvae collected from the location of the lesion.

Healing of intra oral wound was satisfactory, leaving wide oro-antral communication, managed by placing a palatal obturator. Ectropion of the lower eyelid was seen, which needs correction of lower lid and reconstruction of the orbital floor. However, there were no signs of loss of vision or diplopia post operatively. Lubricating eye drops were suggested.

Species	Patient Age/Sex	Number of Larvae	Underlying disorder	Location of the lesion
Bhatt and Jayakrishnan [10]	12/M	3	Incompetent lips, poor oral hygiene	Gingiva of the anterior mandible
Lata, Kapila and Aggarwal [11]	45/M	Multiple	Malnourished, mandibular fracture	Lips and floor of the mouth
Shikha, Prasad GR, Ashutosh-dutt, Meenakshi [12]	12/M	Multiple	Maxillofacial trauma, Incompetent lips, poor oral hygiene	Lingual sulcus of upper anterior tooth region (pre-maxillary region)
Fareedi MA., et al. [13]	13/M	Multiple	Incompetent lips, poor oral hygiene	Maxillary left labial vestibular region at 21 and 22
Sharma D., et al. [14]	21/M	Multiple	Type II occlusion, Incompetent lips, Habit of mouth breathing	Palatal surface of maxillary anterior region extending from incisor to 1 <sup>st</sup> premolar
Biradar S., et al. [15]	50/M	Multiple	Squamous cell carcinoma, Malnourished	Diffuse swelling on the right side of the face, two extra-oral ulcers were seen
Aggarwal., et al. [16]	70/F	Multiple	low socioeconomic background, malnourished, poor oral hygiene	Extensive necrotic oral lesion burrowing into the hard palate
Parwani., et al. [17]	42/F	Multiple	Class II overjet with incompetent lips, poor oral hygiene	Solitary swelling in anterior maxilla extending from maxillary right first premolar to left maxillary canine
Vinit GB., et al. [18]	40/M	Multiple	Maxillofacial trauma, Incompetent lips, poor oral hygiene	Laceration of the upper lip and palatal mucosa

Table 1: Case reports obtained from literature review in India.

Discussion

Oral myiasis is a rare clinical condition in which the parasitic larvae invades the soft tissues of the oral cavity. Myiasis is caused by many species, among which *Calliphoridae*, *Sarcophagidae* and *Oestridea* (dipteran families) are considered to be the primary cause. In the present case, the entomological examination revealed that the larvae are *Chrysomya bezziana*, which belongs to the Calliphoridae family.

Myiasis commonly occurs in rural areas, villages and usually affects those who live close to livestock. The methods of infestation are either by direct inoculation by fly or by ingestion of infected material such as meat [19]. The predisposing factors that are responsible for primary oral infection include open mouth with poor oral hygiene, facial trauma, suppurative lesions, and neurologic deficit [20]. It also can be seen secondary to medical or anatomic conditions, any maxillofacial trauma, mouth breathing, incompetent lips, anterior open

bite and use of mechanical ventilation [19]. In the present case, the presence of extraction wound and the diabetic status could be the predisposing factors for the initiation and progression of the disease. Moreover, poor oral hygiene and lack of self-ability and motivation to undergo treatment on the initial stage may have led to the preoperative condition.

*Chrysomya bezziana*, the Old-World screw-worm fly, is an obligatory myiasis producer whose larvae develop only in living tissue, and their human infestations are uncommon [21,22]. The female fly is attracted towards the wound's odor, and it lays approximately 150 - 200 eggs at a time. These eggs hatch after 24 hours and larvae come out, and they can persist for 6 - 8 days while they complete their development, then they fall to the ground to pupate [23]. The pupa stage is temperature dependent with warm weather favoring their growth. The pupa stage can last from 1 week to 2 months, depending on the temperature. The males become sexually mature after 24 hours of leaving their puparium (the hardened shell the pupae mature in), while females take about 6 - 7 days to become fully sexually mature. In the tropical climate, the entire life cycle lasts about 24 days whereas at relatively cooler temperatures (below 22°C) the life cycle can take 2 - 3 months to complete.

The standard treatment protocol for myiasis includes maintenance of nutrition, antibiotics for secondary infection, and manual removal of larvae with or without topical asphyxiating drugs. This requires the application of turpentine oil or any such agents which blocks the respiratory sinuses of the larvae, thereby forcing them to crawl out. Studies have shown that systemic administration of ivermectin, a semi-synthetic macrolide antibiotic is effective against maggots [24]. In the present case, myiasis was likely to be a complication of an open, neglected and untreated wound primarily due to uncontrolled diabetes status of the patient.

### Conclusion

Myiasis is by and large self-restricting and in many cases not risky to the host. However, complications can emerge. The disease ought to be counteracted by controlling the fly population, keeping good oral and personal hygiene. Good sanitation to one self and the surrounding is the basic step in the fly-management program. Special care should be taken for medically and immune-compromised patients as they can't keep up their basic essential oral hygiene.

### Bibliography

1. Service M. "Flies and myiasis". In: Service M, editor. Medical entomology for students. 4<sup>th</sup> edition. Cambridge: Cambridge University Press (2008): 152-163.
2. Dutto M., et al. "Nosocomial myiasis in a patient with diabetes". *Journal of Hospital Infection* 83.1 (2013): 74-76.
3. Jiang C. "A collective analysis on 54 cases of human myiasis in China from 1995-2001". *Chinese Medical Journal* 115 (2002): 1445-1447
4. Soler Cruz MD. "El estudio de lasmiiasis en Espanadurante los ultimo cienanos". *Ars Pharmaceutica* 41 (2000): 19-26.
5. Leclercq M. "Les myiases". *Annales de la Société entomologique de France* 26 (1990): 335-350.
6. Ramli R and Rahman AR. "Oral myiasis: Case report". *Malaysian Journal of Medical Sciences* 9 (2002): 47-50.
7. Baskaran M., et al. "Cutaneous myiasis of face". *Journal of Oral and Maxillofacial Pathology* 11 (2007): 70-72.
8. Abdo EN., et al. "Oral myiasis: A case report". *Medicina Oral Patologia Oral y Cirugia Bucal* 11.2 (2006): E130-131.
9. Sankari LS and Ramakrishnan K. "Oral myiasis caused by *Chrysomya bezziana*". *Journal of Oral and Maxillofacial Pathology* 14 (2010): 16-18.
10. Bhatt AP and Jayakrishnan A. "Oral myiasis: a case report". *International Journal of Paediatric Dentistry* 10 (2000): 67-70.
11. Lata J., et al. "Oral Myiasis. A case report". *International Journal of Oral and Maxillofacial Surgery* 25 (1996): 455-456.

12. Shikha S., *et al.* "Oral Myiasis: A Rare Case Report and Literature Review". *Journal of Dentistry of Tehran University of Medical Sciences* 12.6 (2015): 456-459.
13. Ali FM., *et al.* "Oral Myiasis Affecting Gingiva in a Child Patient: An Uncommon Case Report". *Case Reports in Dentistry* (2016): 2197450.
14. Sharma D., *et al.* "Oral gingival myiasis: A rare case report and literature review". *Contemporary Clinical Dentistry* 6.4 (2015): 548-551
15. Biradar S., *et al.* "Extensive Myiasis infestation associated with Oral Squamous Cell Carcinoma: Report of two cases". *Dental Research Journal* 12.1 (2015): 100-105.
16. Aggarwal A., *et al.* "Oral Myiasis Caused by *Chrysomya bezziana* in Anterior Maxilla". *Case Reports in Dentistry* (2014): 518427.
17. Parwani RN., *et al.* "Exuberant Oral Myiasis Caused by *Muscadomestica* (Housefly)". *Journal of Global Infectious Diseases* 6.1 (2014): 35-38.
18. Vinit GB., *et al.* "Oral myiasis in a maxillofacial trauma patient". *Journal of Pharmacy and Bioallied Sciences* (2013): S195-197.
19. Droma E., *et al.* "Oral myiasis: a case report and literature review". *Oral Surgery, Oral Medicine, Oral Pathology, Oral Radiology* 103.1 (2007): 92-96
20. Rossi-Schneider T., *et al.* "Oral myiasis-A case report". *Journal of Oral Science* 49.1 (2007): 85-88.
21. Manson Bahr PE and Bell DR. "Manson's Tropical Diseases". 19<sup>th</sup> edition. London: Balliere Tindall Publications (1987): 801-805.
22. Ng KH., *et al.* "A Case of Oral Myiasis due to *Chrysomya bezziana*". *Hong Kong Medical Journal* 9.6 (2003): 454-456.
23. Baskaran M., *et al.* "Cutaneous myiasis of face". *Journal of Oral and Maxillofacial Pathology* 11 (2007): 70-72.
24. Yuca K., *et al.* "Aural myiasis in children and literature review". *The Tohoku Journal of Experimental Medicine* 206.2 (2005): 125-130.

**Volume 18 Issue 9 September 2019**

**©All rights reserved by MVS Sudhir., *et al.***