ECRONICON OPEN ACCESS

EC DENTAL SCIENCE
Case Report

Seal to Heal: Gutta Flow Bioseal

Harpreet Singh[1] and Pooja Kapoor[2]

[1]*Professor and Head, Department of Conservative Dentistry and Endodontics, MN DAV Dental College and Hospital, Solan, India*

[2]*Professor and Head, Department of Orthodontics and Dentofacial Orthopaedics, MN DAV Dental College and Hospital, Solan, India*

***Corresponding Author:** Harpreet Singh, Professor and Head, Department of Conservative Dentistry and Endodontics, MN DAV Dental College and Hospital, Solan, India.

Received: July 22, 2019; **Published:** August 13, 2019

Abstract

One of the primary objectives of Endodontic therapy is to eradicate the bacterial flora from the root canal system and provide a three dimensional seal. It is needless to say that the root canal sealer has a significant role to play in order to ensure the success of this treatment. Since ages, several sealers have been used and evaluated, each having its own set of advantages over the rest. The 'Bioactive sealers', with their extraordinary healing potential along with osteoinductive and osteoconductive potential seem to be quite promising and look like to be the future of 'Modern Endodontics'. This paper presents the case report of a healed lesion wherein 'Guttaflow Bioseal', a novel 'Bioactive sealer' was used, depicting excellent results.

Keywords: *Bioactive Sealers; Endodontic Sealers; Guttaflow Bioseal*

Introduction

The backbone of successful endodontic therapy is the removal of bacteria and its components from the root canal system [1]. The onus of this magnanimous job lies on the shoulders of antibacterial irrigants and medicaments. Thereafter, antibacterial sealer is presumed to take over the charge for rest of life of the tooth as far as bacteriological aspect is concerned. This essentially implies that the biological properties of the endodontic sealer are of paramount significance [2]. Not only it should be anti-bacterial but also must possess certain amount of healing qualities in order to accentuate the bone formation especially in cases of chronic infections associated with periapical lesions [3,4]. Gutta Flow Bioseal (Coltene) is one iconic example of such Bioactive Sealers which have a unique potential of facilitating the formation of crystalline structure similar to tooth and bone apatite material as well as high degree of biocompatibility [5]. This case report shares a case of large periapical lesion showing substantial healing, utilizing the healing potential of Gutta Flow Bioseal.

Case Report

A 21 year old male patient reported to us with a history of Root Canal treatment already done about 4 years back in his Maxillary anterior teeth. However, he had been feeling pain in his teeth on and off since last two weeks. The radiograph, when taken, revealed a radiopaque material in right maxillary central incisor and a periapical lesion associated with the same central incisor and the adjacent lateral incisor (Refer to figure). The treatment plan of performing endodontic re-treatment of central incisor and endodontic treatment of lateral incisor was passed on to the patient, which he accepted.

The metallic post in the central incisor was removed using ultrasonics [6] and the gutta percha inside the canal was removed using gutta percha solvent (chloroform) and H-files following the standard protocol. The working length was established using apex locator CanalPro (Coltene) [7] and cleaning and shaping was performed using a combination of hand and rotary files, utilizing the hybrid technique.

2% chlorhexidine was used as irrigant as well as intracanal medicament in this case anticipating the presence of Enterococcus feacalis in such like cases of retreatment [8]. The lateral incisor was treated in a conventional manner. To ensure maximum disinfection of the root canals, 'Triple Antibiotic Paste' was placed as intracanal medicament in both the teeth [9]. Once the patient was completely asymptomatic, obturation was done using Gutta Flow Bioseal sealer in order to make use of its bioactive potential and healing effects (Refer to figure). The three months follow-up revealed a significant decrease in the size of the associated periapical lesion (Refer to figure).

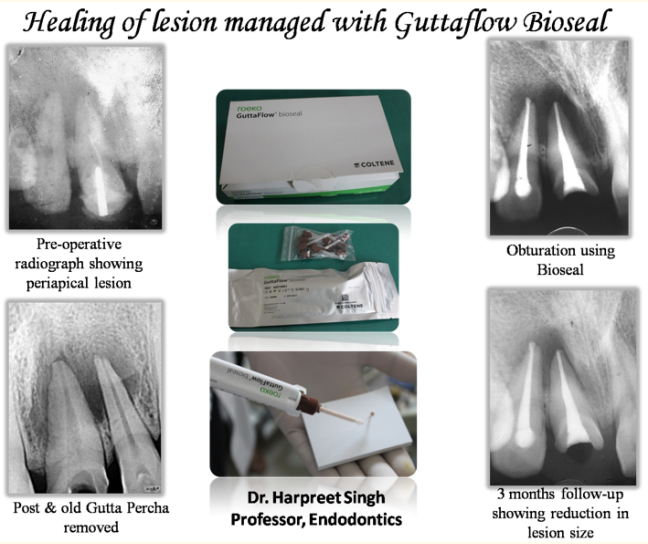

Figure : *Case of large periapical lesion associated with Maxillary central and lateral incisor showing significant healing after 3 months.*

Discussion

Cases of large periapical lesion and endodontic retreatment have always been a challenge for the treating clinician. The plethora of microbes involved poses a serious challenge when handling such like cases [1]. It becomes absolutely essential for the dentist to understand the means of eradicating such complex microbial strata from the root canal system during the entire procedure of cleaning and shaping. Also, the use of suitable intracanal medicaments must be done to ensure thorough disinfection [10].

After having all this done, the last but not the least onus comes on the antimicrobial and healing properties of the endodontic sealer with which the entire root canal system is to be sealed.

The new generation Bioactive endodontic sealers such as Gutta Flow Bioseal (Coltene) has such like amazing properties. Upon contact with fluids, the bioactive material provides natural repair constituents such as calcium and silicates. It also activates biochemical processes that provide additional support for regeneration in the root canal. Gutta Flow Bioseal forms hydroxylapatite crystals on the surface which significantly improve adhesion and also stimulate natural triggers, especially the regeneration of bone and dentine tissue. Additionally, Gutta Flow bioseal also combines free-flow gutta-percha with a sealer at room temperature [11]. Several studies have proven the excellent biocompatibility of this magical material as compared to other endodontic sealers, highlighting its extraordinary biological properties [5,12,13].

Conclusion

Having discussed all the beneficial properties of the bioactive materials, one must also realize that retreatment of cases sealed with these materials can be quite tricky as these sealers set into a very hard mass. It is essential here to mention that retreatment of cases, if at all needs to be done, would be much easier for the ones sealed with Gutta Flow Bioseal as the major component of this sealer is gutta percha which is a soluble material. The extraordinary healing potential and the bioactivity along with high biocompatibility make this sealer, the material of choice when handling difficult cases which are associated with periapical lesions and especially the ones exhibiting mild resorption as the seal would finally be created, thanks to its biological properties.

Bibliography

1. Singh H. "Microbiology of Endodontic Infections". *Journal of Dental and Oral Health* 2.5 (2016): 44.
2. Singh H., *et al*. "Endodontic sealers: Current concepts and comparative analysis". *Dentistry Open Journal* 2.1 (2015): 32-37.
3. Vasileios Kapralos., *et al*. "Antibacterial Activity of Endodontic Sealers against Planktonic Bacteria and Bacteria in Biofilms". *Journal of Endodontics* 44.1 (2018): 149-154.
4. Afaf AL-Haddad and Zeti A Che Ab Aziz. "Bioceramic-Based Root Canal Sealers: A Review". *International Journal of Biomaterials* (2016): 9753210.
5. FJ Rodriguez Lozano., *et al*. "GuttaFlow Bioseal promotes spontaneous differentiation of human periodontal ligament stem cells into cementoblast-like cells". *Dental Materials* 35.1 (2019): 114-124.
6. Feiz A., *et al*. "The influence of ultrasound on removal of prefabricated metal post cemented with different resin cements". *Dental Research Journal* 10.6 (2013): 760-763.
7. Singh H and Kapoor P. "Generations of apex locators: which generation are we in?" *Stomatological Disease and Science* 3 (2019): 4.
8. Singh H and Kapoor P. "Comparative Evaluation of Antibacterial Efficacy of 'Activ Points' And 'Combi Points' as Intra-Canal Medicaments Against Enterococcus faecalis: An Ex Vivo Study". *Oral Health and Dental Management* 13.3 (2014): 610-613.
9. Vijayaraghavan R., *et al*. "Triple antibiotic paste in root canal therapy". *Journal of Pharmacy and Bioallied Sciences* 4.2 (2012): S230-S233.
10. Madarati AA., *et al*. "Preference and usage of intracanal medications during endodontic treatment". *Saudi Medical Journal* 38.7 (2017): 755-763.
11. Guttaflow Bioseal (2019).
12. Mar Collado-Gonzalez., *et al*. "Cytotoxicity of GuttaFlow Bioseal, GuttaFlow2, MTA Fillapex, and AH Plus on Human Periodontal Ligament Stem Cells". *Journal of Endodontics* 43.5 (2017): 816-822.
13. Saygili G., *et al*. "In Vitro Cytotoxicity of GuttaFlow Bioseal, GuttaFlow 2, AH-Plus and MTA Fillapex". *Iranian Endodontic Journal* 12.3 (2017): 354-359.

Volume 18 Issue 9 September 2019