

## Osteosarcoma of the Jaws (JOS) Treatment/Two Case Reports

Abdul I Touleimat<sup>1\*</sup> and Nabila B Kabani<sup>2</sup>

<sup>1</sup>Professor, Damascus University, IUST University, Syria

<sup>2</sup>Associate Professor, Kalamon University, Syria

**\*Corresponding Author:** Abdul I Touleimat, Professor, Damascus University, IUST University, Syria.

**Received:** May 29, 2019; **Published:** June 25, 2019

### Abstract

Osteosarcoma is the most common malignant bone tumor among children, adolescents and young adults.

In the head and neck region, osteosarcoma is the most common primary malignant bone tumor, representing 23% of total head and neck malignancies. Osteosarcomas of the jaws are nevertheless rare lesions, representing only 2 to 10% of all osteosarcomas [1].

Osteosarcoma (OS) is the eighth common cancer of childhood and its incidence is 4 cases in one million in children younger than 14.

The reason for this article is to present two cases, 1<sup>st</sup> is in young male and the 2<sup>nd</sup> in the mandible of female.

**Keywords:** Bone Tumor; Facial Bone; Mandible; Osteosarcoma

### Abbreviations

os: Osteosarcoma; jos: Osteosarcoma of the Jaws

### Introduction

Osteosarcoma (OS) is one the most frequent malignant tumors that is derived from mesenchymal cells with bone formation capacity [2]. Male to female ratio is estimated at 5.4:4 in some reports [4]. Osteogenic sarcoma prevalence is 1 - 3 in one million, annually [2]. The disease has two peaks of incidence: first in children between 10 and 14 years and second in older ages. OS is the tumor of long bones and occurs in the metaphysis of the long bone near the epiphyseal plate. Distal femur and proximal tibia are the main sites [4]. OS is the eighth common form of cancer in childhood [3]. This malignant tumor is more frequent in boys, and tall children are more at risk for developing this malignancy. Positive history of radiotherapy is the main predisposing factor for childhood OS.

The biological behavior of jaw osteosarcoma (JOS) differs from osteosarcomas involving long bones. In JOS, the average age of onset is 10 to 20 years later, distant metastases occur less frequently, the histopathologic variables are more favorable, and the survival rates are higher [3,5]. The clinical presentation of osteosarcomas in the jaws and long bones is also different. Swelling is the most common complaint in patients with JOS, while bone pain during activity is characteristic of long bone osteosarcoma [4,6]. Despite the biological and clinical differences, JOS and osteosarcomas of the long bones are treated similarly.

The most significant prognostic factor and primary treatment modality of JOS is complete surgical resection, which is more difficult to achieve in the jaws than the long bones because of complicated and delicate anatomy [2,8,9]. While multimodal treatment of patients with osteosarcoma in long bones is well established, it is still controversial in JOS [10].

Osteosarcoma of Jaw Bones signs and symptoms include:

- In the initial growing phase of the tumors, they are normally asymptomatic. The soft tissue tumors grow at a moderate rate, and then they suddenly start to rapidly progress.
- Depending on the jaw bone that is affected, there may be pain, swelling, tenderness, displacement or bulging of teeth, tingling or pricking sensation (paresthesia), numbness.
- Due to large size of the tumor, the adjoining organs, nerves, and muscles may be compressed or restricted.
- The individual may have difficulty eating, swallowing, or breathing.
- In some individuals, organ dysfunction and internal hemorrhages may be observed. These may be sudden and spontaneous developments.

### Treatment

- 1- Surgery is the main treatment for osteosarcoma. taking into consideration, 1.5 to 2 cm of safety margins and the involved surrounded soft tissue would be removed. Then immediate replacement of the Missing bony parts of the effected jaw.
- 2- Chemotherapy (cytotoxic) drugs to destroy cancer cells was applied after surgery to reduce the risk and the rate of reoccurrence and sometimes before surgery, to shrink the main tumor before surgery) (many therapists try to use a combination of drugs).

Trials, aim to improve our understanding AND for developing a best way to treat these cases of osteosarcoma, collecting more information and comparing the outcome of different ways of treatment. This will help in getting enough information to which way of treatment was the most effective one. This study was performed in UK and after a longterm fellow up (5 - 10 years) to large number of cases.

The results of this study were analyzed, taking in consideration the rate of reoccurrence the length of time between surgery and reoccurrence. And the survival time after treatment.

This way a treatment protocol was achieved. To be applied, seeking the best results, concerning the behavior of the lesion after treatment and the length of the survival time

This approach of treatment was as follows:

- A dose of 70 mg of Doxorubicin, 100 mg of Cisplatinum and 20 ml of potassium chloride were added to two liters of dextrose and saline solution.
- The whole amount is introduced fusion for indurin for 6 hours period.
- Not more than six doses are given.
- The time between each dose is three weeks.
- Some prefer to divide the six doses; three before surgery and the other three after surgery.
- Fluid balance should be taken into consideration, In case of the output being decreased. The Urologist should be consulted.
- Anti-vomiting drugs might be necessary.
- surgery should be performed. Within 10 days after the last course.
- This type of treatment should be applied only if the lesion of Osteosarcoma can be treated surgically.

Patient fellow up should be continued for the next 10 years after treatment:

- X- ray of the lesion area every two months during the first 2 years after treatment.
- Then x-ray every 3 months during the 3<sup>rd</sup> year.

- Then every 6 months till the end of the 5<sup>th</sup> years after.
- Then every year till the end of the year ten.
- Then CT x-ray for the lungs every two years.

That protocol of treatment is what we have applied dealing with JOS. In our department, under the supervision of Associate professor Dr. Nabila Kabani Basha and the Chemotherapy specialist Dr.----- may occasionally be given. It was used the same way as Chemotherapy is used. Before or after surgery.

### **Report of Two Cases**

#### **Case 1**

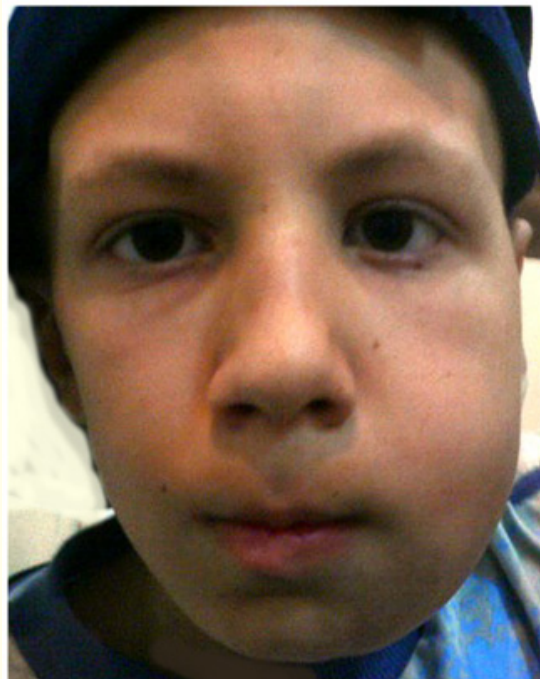
A 12 years old male consulted us with swelling and asymmetry of the left side of the face. He also complained of pain, fatigue and fever.

Clinical exam shows hard swelling in the left face with well palpated cervical lymph nodes. Parents said that this boy has had a trauma on his left side of the face 2 years before.

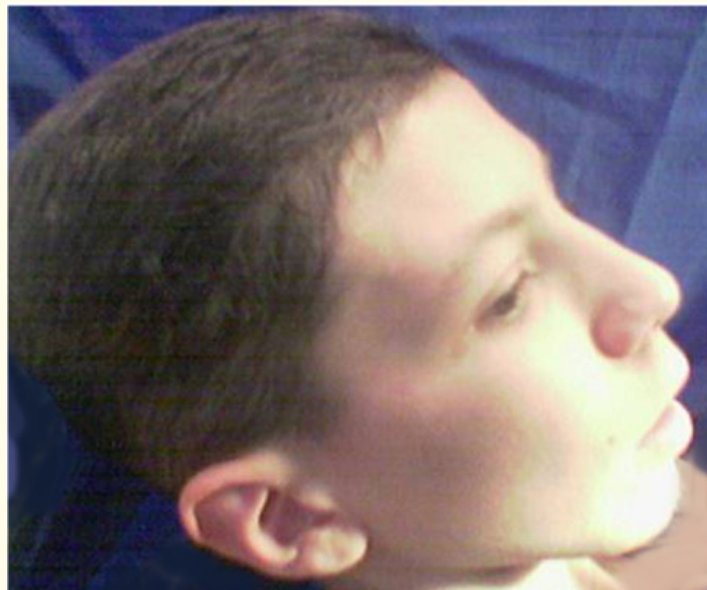The story started with a small swelling and pain in the left side of the lower jaw. His dentist treated the case as a Dental infection. During one dental appointment the boy felt a cracking sound coming from area close to his ear.

Next day a swelling developed in the area. That pushed him to seek another opinion, with no improvement.

In our department we saw him with a good amount of swelling of his left face (Figure 1 and 2) Panorax and CT scan Were done.

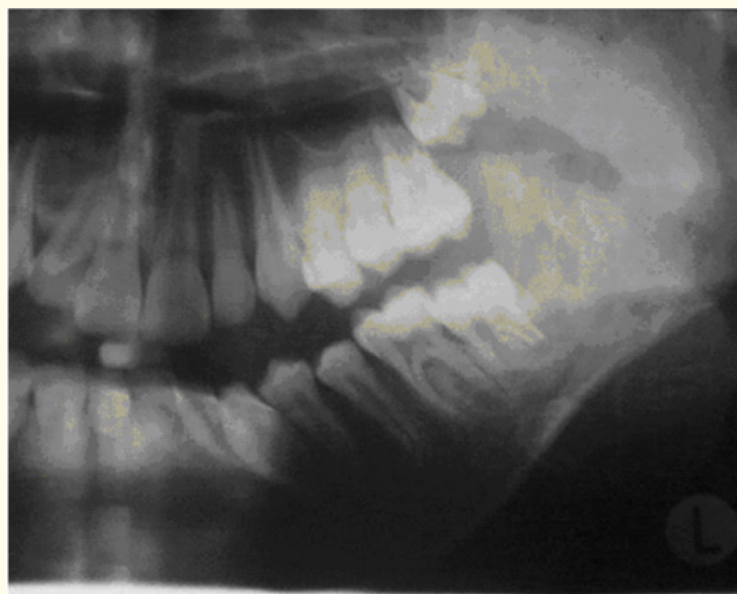

**Figure 1**

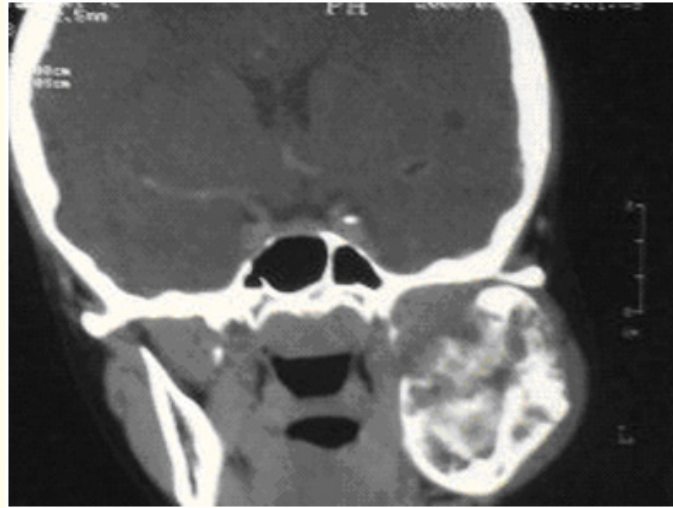


*Figure 2*

These exams revealed: A distractive mass of the left ramus area. Measured 5.5 X 6.5 cm. pushing the cervical blood vessels (Not involved), extending forward to reach the anterior wall of the maxillary sinus (sinus is not involved) and upward to reach the TMJ area. Clinically the lymph nodes were not involved. The right side was normal. No other bony involvement (Figure 3 and 4).



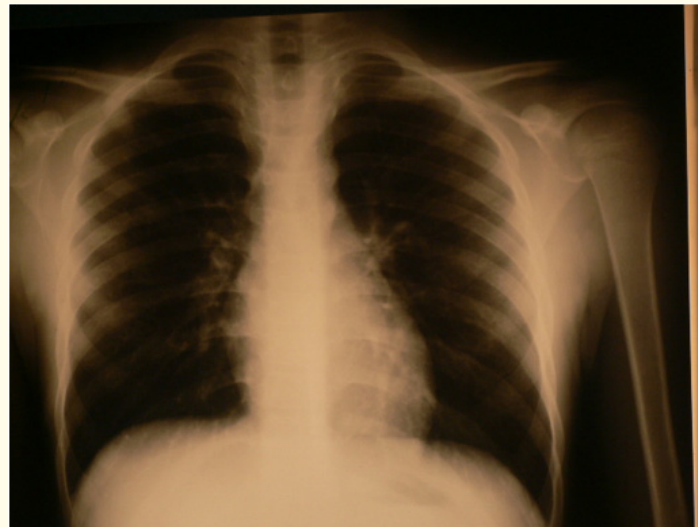*Figure 3*



*Figure 4*

Biopsy and the immune tests came to confirm Osteosarcoma.

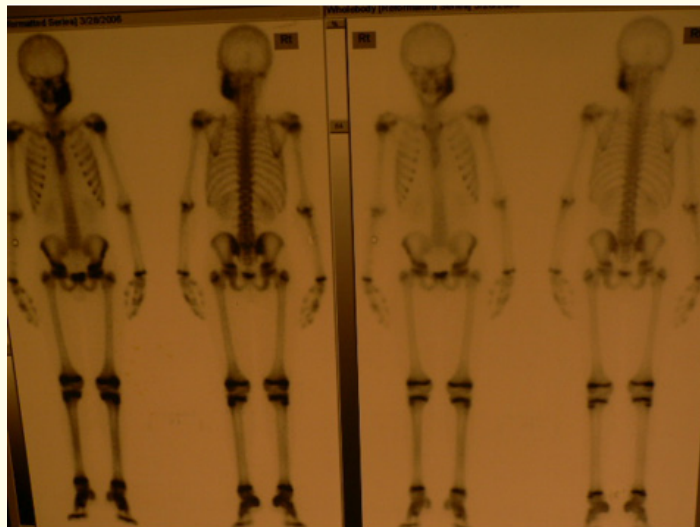
For farther evaluation Ct of the chest was done. that revealed some enlargement of few lymph nodes, lungs were normal (Figure 5).



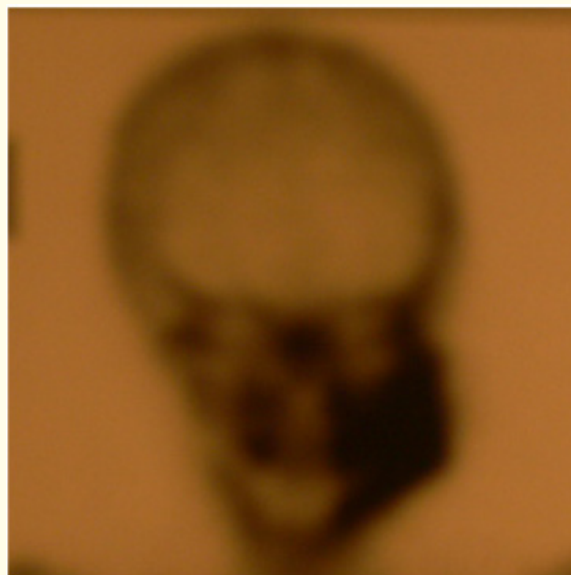*Figure 5*

Then was sent to have (screening) of his skeleton.

Where there are no other involvement (Figure 6 and 7).



*Figure 6*



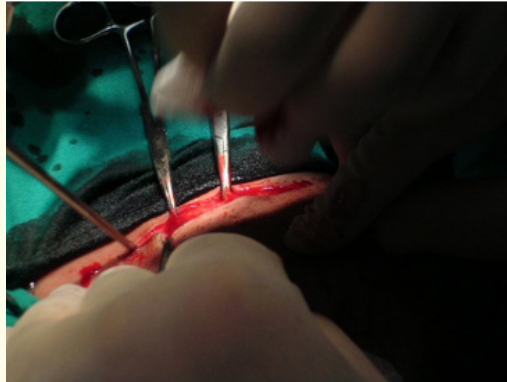*Figure 7*

Ultrasound for the abdomen, the Liver Kidneys and bankerias were normal.

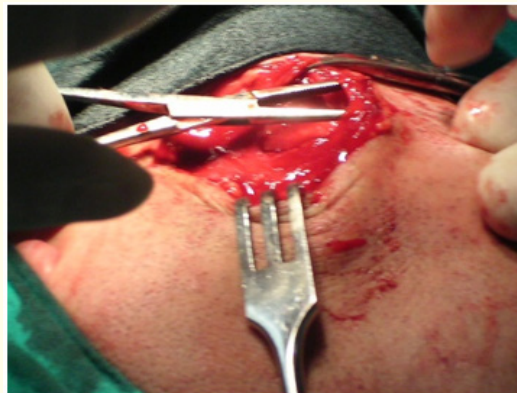Patient was sent for consultation to the Chemotherapist: The patient should follow the protocol of treatment.

After the 3<sup>rd</sup> course of therapy. The patient was reevaluated again to be ready for surgery.

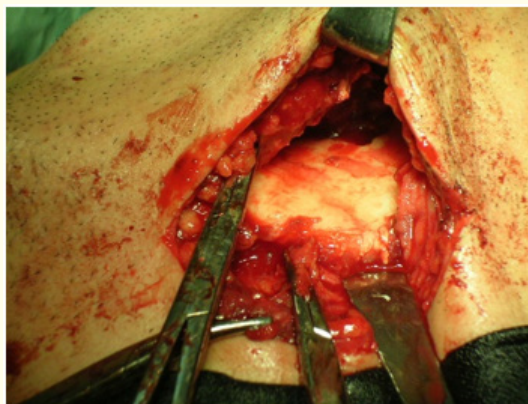
On the 20<sup>th</sup> day of the of the chemotherapy, the patient was underwent radical removal of the left side of the jaw with all the tissue surrounding the TMJ area, the deep fibers of the Masseter Muscle, the lateral fibers of the internal pterygoid muscle, the superficial part of the lateral pterygoid and the lower part of the temporalis all are removed with the lesion (Figure 8-10).



*Figure 8*



*Figure 9*



*Figure 10: The lesion exposed and removed with 2 Cm. Safety Margin.*

The Missing part of the left lower jaw was replaced with Metallic condyle attached to a reconstruction plate. The jaws were put together in the central occlusion to be immobilized for 20 days (Figure 11-15).




Figure 11

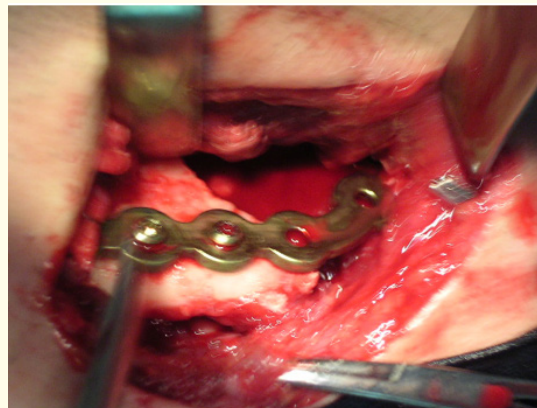

Figure 12

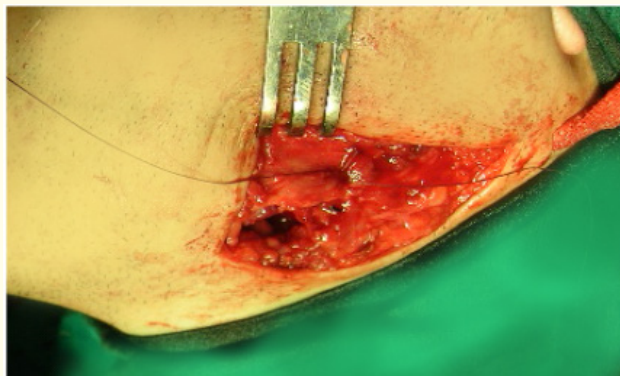


Figure 13



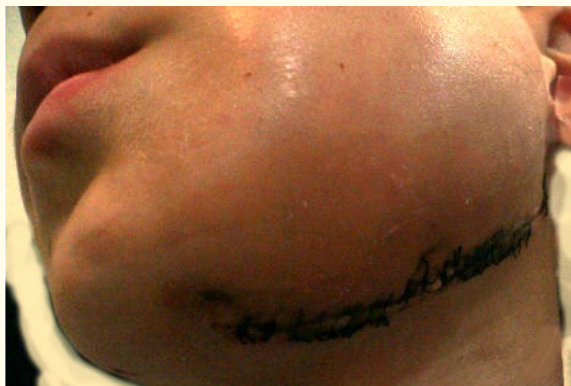

Figure 14

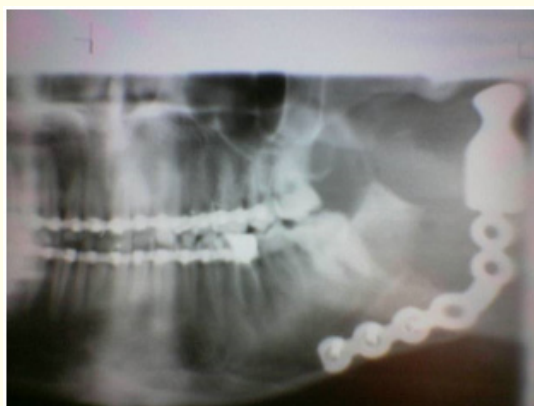

Figure 15

The recovery was good. Patient set again to the chemotherapist for farther fellow up and to continue on his course of treatment, chemo and then x-ray Radiation

- Post-surgery occlusion.
- A fellow up for year and half clinically radio graphically the patient very fine (Figure 16).

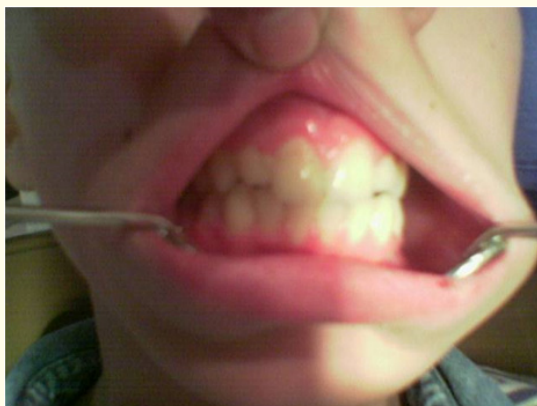

Figure 16

**Case 2**

A young 26 years old lady comes with swelling of the lower part of her face. Her past oral complains was a small swelling in the mouth, the lower molars area.

That time the case was treated as a dental abscess.

The patient was pregnant in her 5<sup>th</sup> months.

The case started to be more severe with enlargement of the area

And pain radiating to other parts of the oral cavity.

Panoramic X-ray shows a bony lesion in the lower posterior teeth area.

The first biopsy that was performed outside the city, interrupted as a mixed tumor.

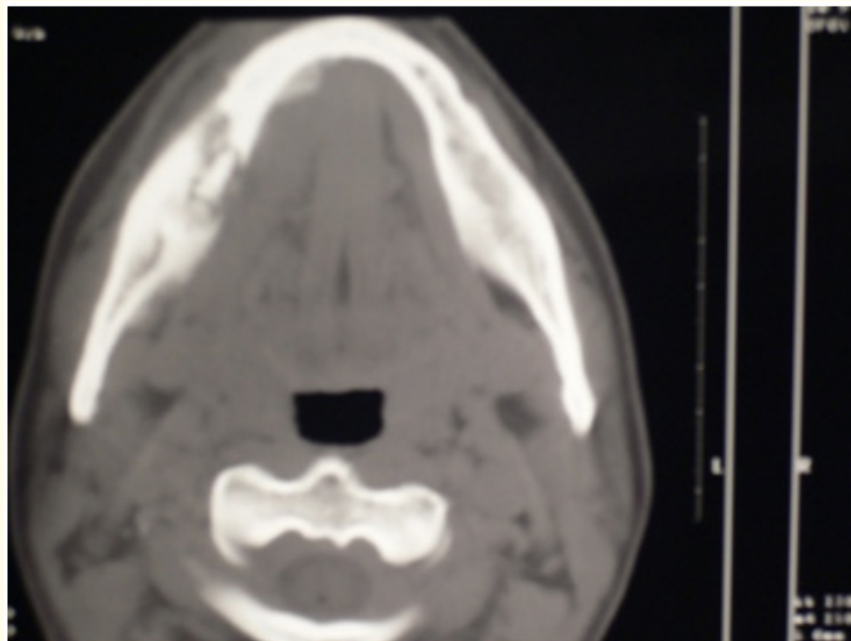
That time her surgeon tried to delay the surgery till she is through with her pregnancy

The case started to develop fast. This time she was referred to us.

A 2 x 2 cm. bony biopsy was taken intraorally. The pathologist conclusion was osteosarcoma.

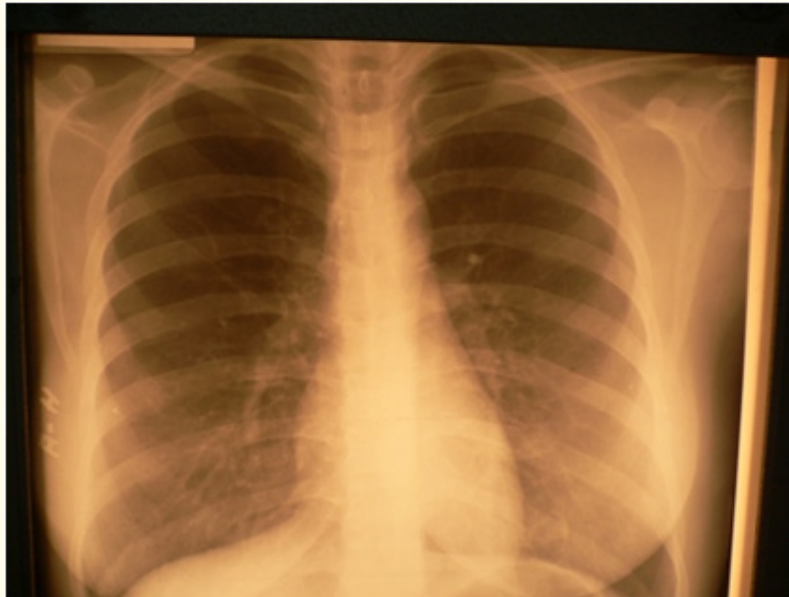That time she was in the beginning of her 7<sup>th</sup> months of pregnancy. Her dr. advised her to terminate her pregnancy. To be started on the protocol of treatment that mentioned above.

CT scan shows the extensions and destruction of the lesion (Figure 17).



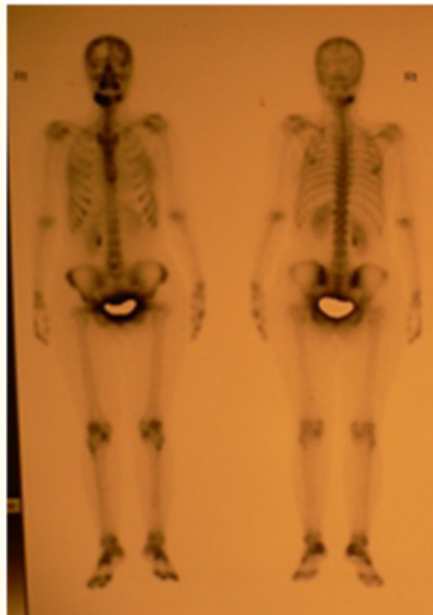
**Figure 17**

Chest x-ray lungs not involved (Figure 18).



*Figure 18*

Other skeleton bones are not involved (Figure 19).



*Figure 19*

Figure 20 shows the involvement of the mandible.

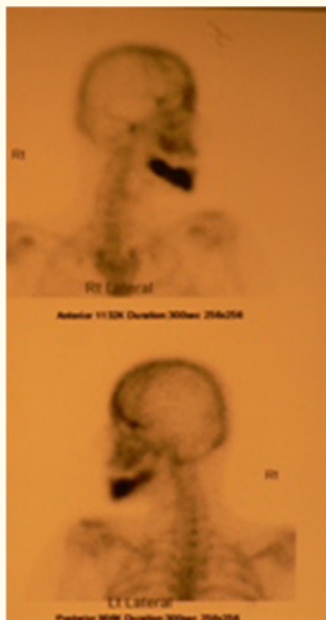


Figure 20

### Surgery

A radical removal of The lesion with the surrounding soft tissue; Constructing the boney defect with constructive plate. Through submandibular incision (Figure 21).

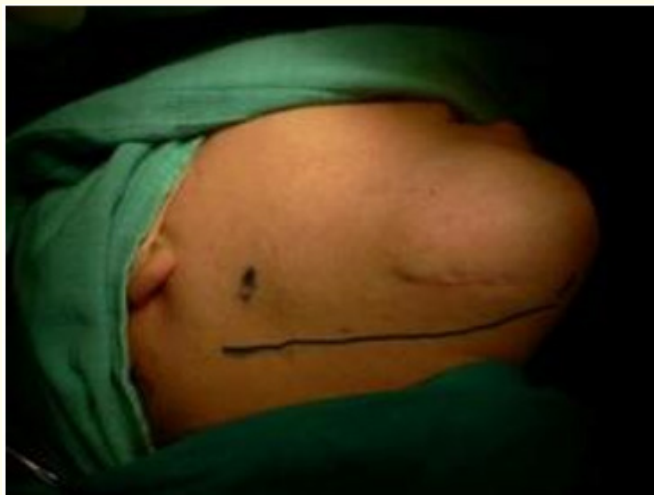
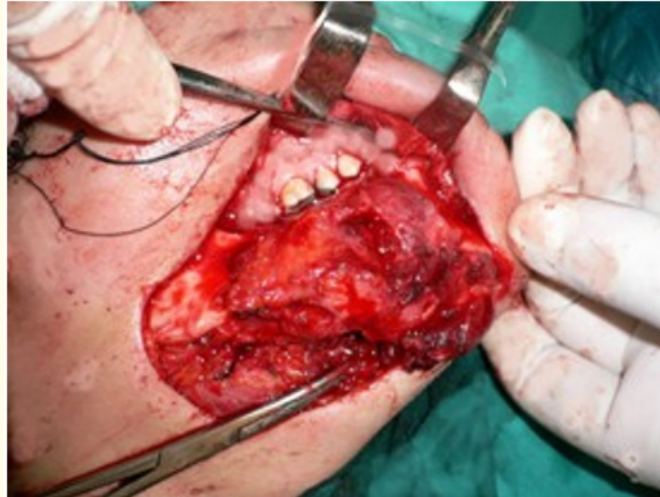
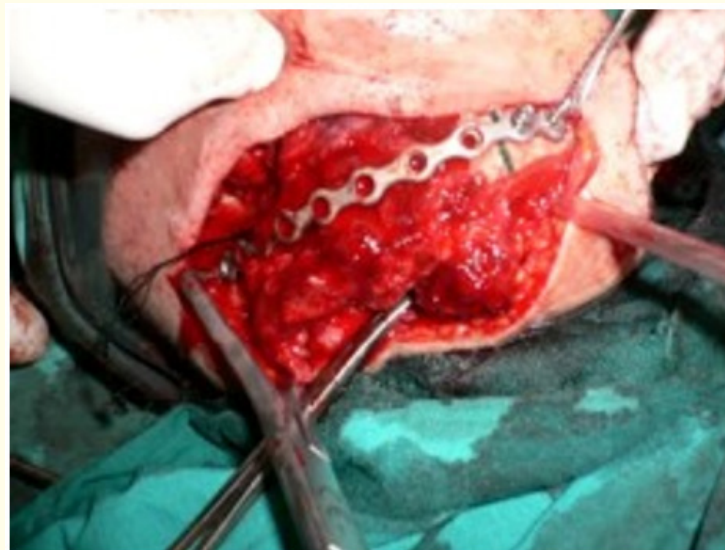
Figure 21

The area involved by the lesion was dissected, Dissecting only the skin layers, leaving all the involved soft tissue intact to the main mass. The Facial artery ligated and cut Having The Mass ready to be separated from the surrounding anatomy (Figure 22).



*Figure 22*

Figure 22 shows all the Tissue to be removed has freed from the skin layers and the facial bundle is ligated. To keep what will be saved from the jaw and the dental arch in good relation with the upper jaw and, Before the mass was separated; A constructive plate was placed in the desirable place. And fixed with screws (Figure 23).



*Figure 23*

Now the plate is removed to ease the cuts and then separation of the lesion (Figure 24).

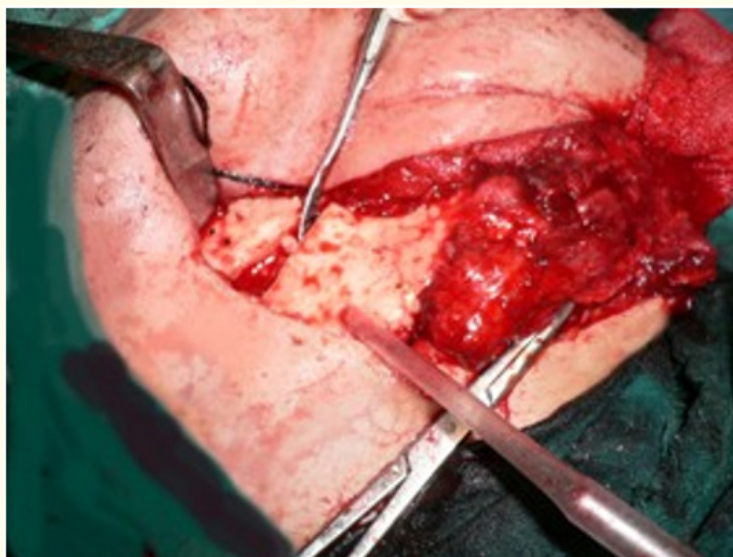


Figure 24

Notes the posterior cut. line in the ramous. The tip of the suction is pointing to the INF bundle. Then The anterior cut line is shown on figure 25.

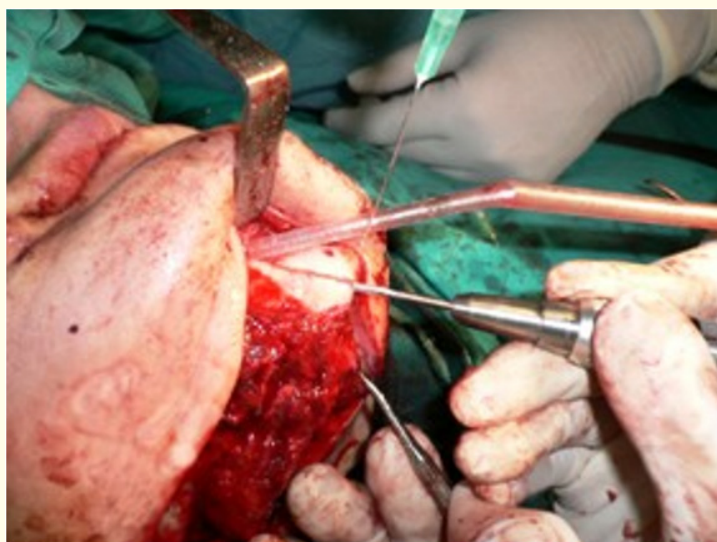


Figure 25

Now the lesion and the surrounding tissue are separated, the lesion and the surroundings are out (Figure 26-28).

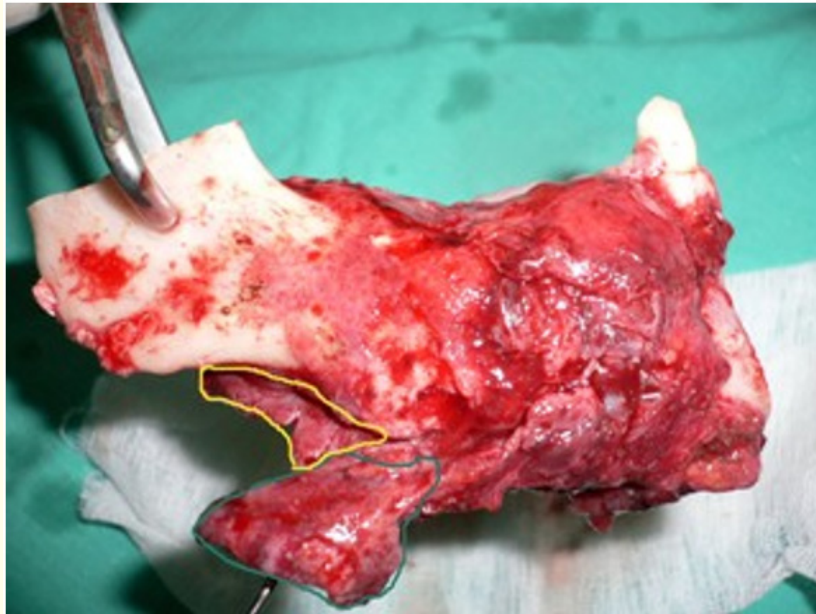


Figure 26

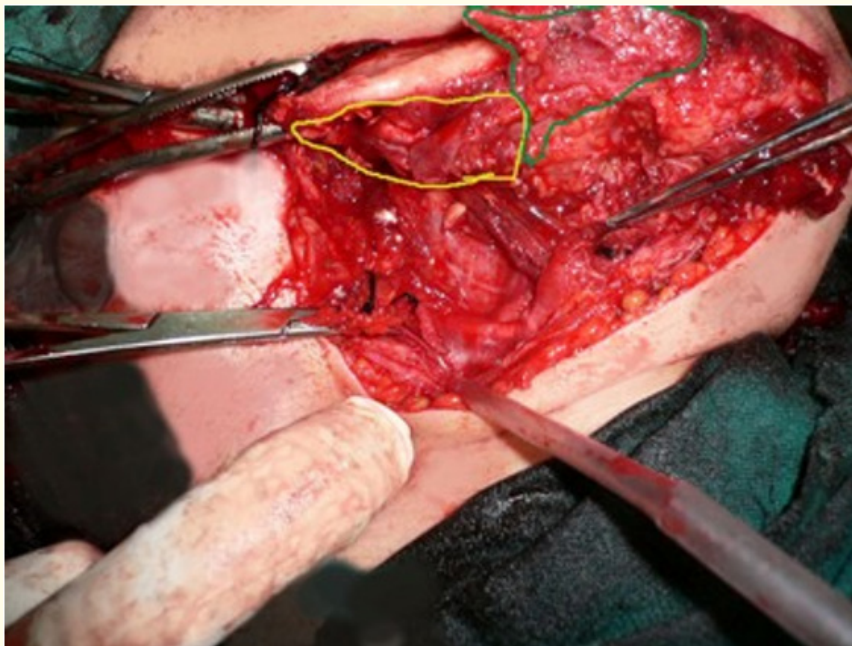


Figure 27

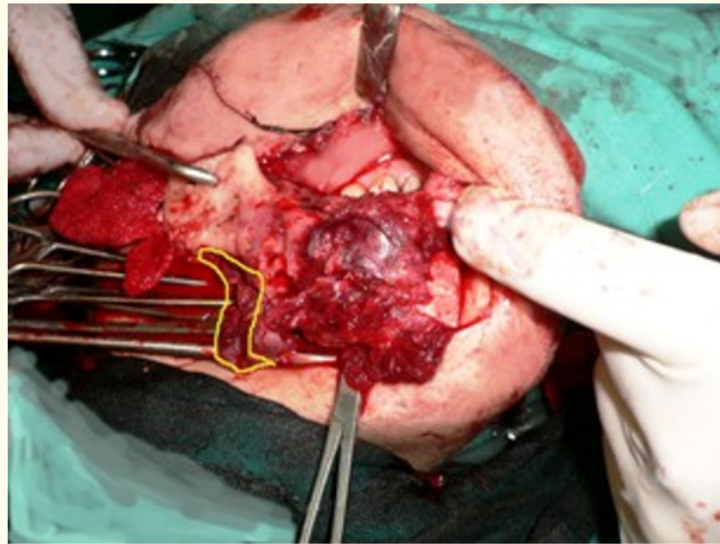


Figure 28

The Yellow line shows the part of the internal pterygoid removed.

The green line shows the masseter muscle that removed. The whole mass is lifted up.

The plate is back in its place (Figure 29).

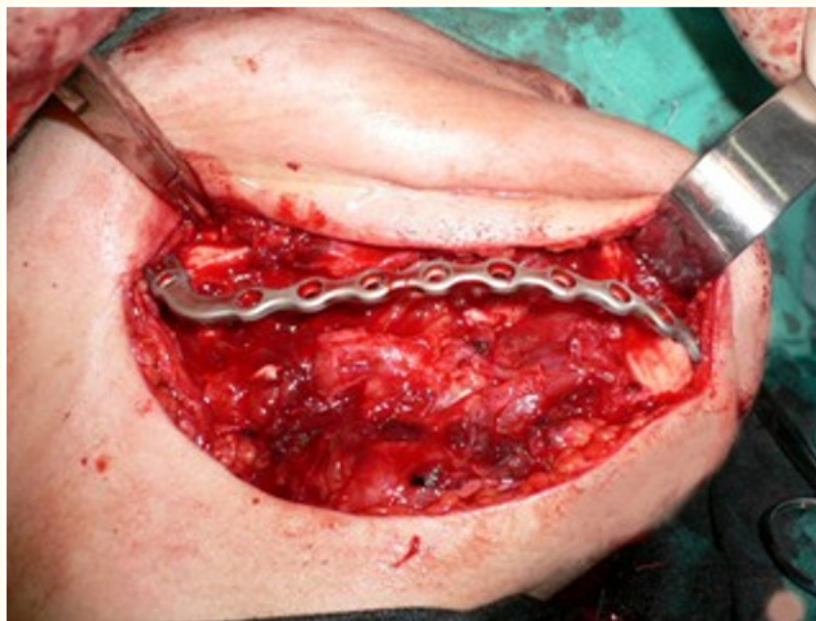
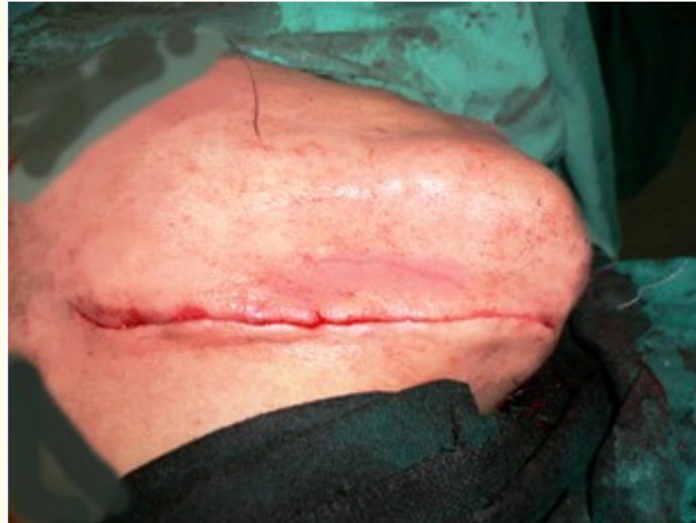
Figure 29

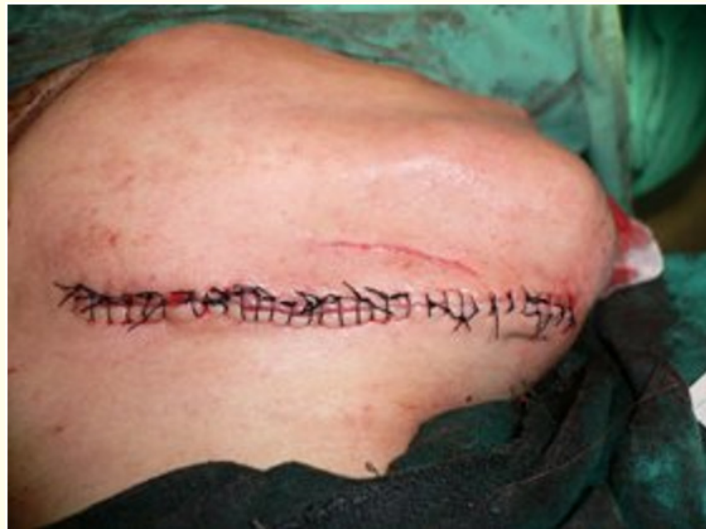

This was done to keep with the continuation of the jaw and to keep the relation between the two jaws in normal relation.

The wound is closed in layers (Figure 30 and 31).



*Figure 30*



*Figure 31*

After removal of the intra max fixation, she was send back to the therapist to continue on her x-ray radiation.

The Follow up: Two years later: She has developed another mass. It was chondrosarcoma Away from the first mass, That might be kind of a side effect of radiation.

## Discussion

Although osteosarcoma is one of the most frequent bone malignancies, head and neck OS is very rare. Facial OS incidence is estimated between 8 and 10% of OS cases [13]. Maxilla and mandible is the main site of facial OS. In various articles mean age of patients with jaw OS was reported at about 40 [13]. Our two cases the age were 12y and 26y of age.

Jaw OS has a better survival rate in comparison with other OS diseases and has less metastasis and lymph node involvement [11]. In the introduced case there was no evidence of metastasis or invasion. But she died one year after disease diagnosis due to resistance and having a progressive form of OS.

Differential diagnoses of OS include chondrosarcoma, rhabdomyosarcoma, Ewing sarcoma, bone metastasis, and osteomyelitis [12]. Our patient was initially diagnosed as cellulitis due to her past history of an upper respiratory tract infection. After further investigations, her primary radiologic study was suggestive for rhabdomyosarcoma. Finally, osteosarcoma was confirmed with a CT scan and histopathological findings.

## Conclusion

Treatments for A child diagnosed with osteosarcoma today will receive generally the same treatment as a child diagnosed 30 years ago.

For a Dentist and Maxillo-Facial surgeon, whenever he is not sure about the cause of pain and swelling he is facing, should not limit his diagnosis to a dental reason, and should go for farther Investigation, in our two cases the patients were neglected for sometime because of a false Diagnosis.

## Bibliography

1. Nthumba PM. "Osteosarcoma of the jaws: a review of literature and a case report on synchronous multicentric osteosarcomas". *World Journal of Surgical Oncology* 10 (2012): 240.
2. Azizi T, et al. "Gnathic osteosarcomas: a 10-year multi-center demographic study". *Indian Journal of Cancer* 46.3 (2009): 231-233.
3. August M., et al. "Osteogenic sarcoma of the jaws: factors influencing prognosis". *International Journal of Oral and Maxillofacial Surgery* 26.3 (1997): 198-204.
4. Russ JE and Jesse RH. "Management of osteosarcoma of the maxilla and mandible". *American Journal of Surgery* 140.4 (1980): 572-576.
5. Regezi JA., et al. "Osteosarcomas and chondrosarcomas of the jaws: immunohistochemical correlations". *Oral Surgery, Oral Medicine, Oral Pathology* 64.3 (1987): 302-307.
6. Nissanka EH., et al. "Clinicopathological analysis of osteosarcoma of jaw bones". *Oral Diseases* 13.1 (2007): 82-87.
7. Patel SG., et al. "Improved outcomes in patients with osteogenic sarcoma of the head and neck". *Cancer* 95.7 (2002): 1495-1503.
8. Mardinger O., et al. "Osteosarcoma of the jaw: the Chaim Sheba Medical Center experience". *Oral Surgery, Oral Medicine, Oral Pathology, Oral Radiology, and Endodontology* 91.4 (2001): 445-451.
9. Saeter G., et al. "Extremity and non-extremity high-grade osteosarcoma-the Norwegian Radium Hospital experience during the modern chemotherapy era". *Acta Oncologica* 35.8 (1996): 129-134.
10. Colville RJ., et al. "Multidisciplinary management of head and neck sarcomas". *Head Neck* 27.9 (2005): 814-824.

11. Feng T, *et al.* "Stathmin is key in reversion of doxorubicin resistance by arsenic trioxide in osteosarcoma cells". *Molecular Medicine Reports* 10.6 (2014): 2985-2992.
12. Etzold A, *et al.* "Further evidence for pathogenicity of the TP53 tetramerization domain mutation p.Arg342Pro in Li-Fraumeni syndrome". *Familial Cancer* 14.1 (2015): 161-165.
13. Gadwal SR, *et al.* "Primary osteosarcoma of the head and neck in pediatric patients: a clinicopathologic study of 22 cases with a review of the literature". *Cancer* 91.3 (2001): 598-605.

**Volume 18 Issue 7 July 2019**

**©All rights reserved by Abdul I Touleimat and Nabila B Kabani.**