

## **An Impacted Tooth Culprit for Unavoidable Catastrophe - Dentigerous Cyst**

**Prachi Fatangare\*, Harish Saluja, Seemit Shah and Anuj Dadhich**

*Department of Oral and Maxillofacial Surgery, Pravara Institute of Medical Sciences, India*

**\*Corresponding Author:** Prachi Fatangare, Department of Oral and Maxillofacial Surgery, Pravara Institute of Medical Sciences, India.

**Received:** May 16, 2019; **Published:** June 20, 2019

### **Abstract**

Dentigerous cysts are common lesions of the head and neck region. After radicular cysts, it is the second most common odontogenic cysts. It accounts for approximately 24% of all true cysts in the jaws. They are defined as pathologic epithelium-lined cavities that surround the crown of an unerupted tooth at the level of the cemento-enamel junction [1]. Their frequency in the general population has been estimated at 1.44 cysts for every 100 unerupted teeth. The mean age of occurrence for dentigerous cyst is second and third decade [4].

This case report illustrates the efficacy of simplified surgical treatment for a massive dentigerous cyst in the young patient.

**Keywords:** *Odontogenic Cyst; Dentigerous Cyst; Massive Dentigerous Cyst*

### **Introduction**

The dentigerous cyst, also called a follicular or coronodontal cyst, is the second most common odontogenic cyst of the mandible. The third molar is the tooth that is involved most frequently and the posterior area of the mandible is the most common site of dentigerous cysts. It is commonly found in children and adolescents with the highest incidence in the second and third decade [3]. Though various theories have been proposed to explain its origin, the cause of dentigerous cyst remains debatable.

The enamel organ surrounds the primordial dental pulp in the early developmental stages of tooth. The outer layer forms the outer enamel epithelium and inner side is lined by the stellate reticulum. The inner enamel epithelium made up of the ameloblasts forms the inner surface which is in contact with the pulp. This ameloblasts are responsible for the production and mineralization of the enamel. After formation of coronal enamel, the enamel organ shuts down leading to atrophy of stellate reticulum followed by collapsing of outer enamel epithelium onto the inner enamel epithelium. This results into the formation of reduced enamel epithelium.

A small ring persists near the junction of the crown and root to form a part of the gingival attachment during the tooth eruption leading to formation of tissue collar around the neck of tooth. If the eruption of tooth fails, the tooth and its surrounding tissues may lie dormant in the bone. Sometimes, the sac expands due to pulling of fluid and development of osmotic gradient, as cells from the inner enamel epithelium desquamate into the lumen of the sac. The pressure exerted causes atrophy of surrounding bone further leading to mobility of adjacent teeth and weakening of jaw leading to pathologic fracture. It may also result in external resorption of the roots of adjacent tooth [5].

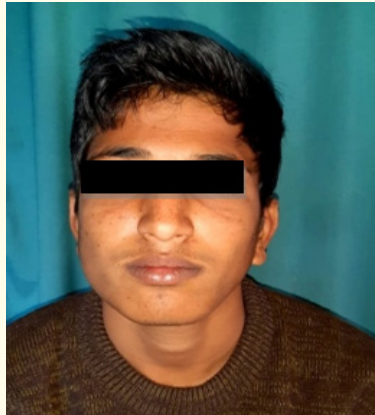Radiographic appearance is suggestive of a unilocular radiolucent lesion with well-defined sclerotic margins associated with crown of the unerupted tooth/impacted tooth. The differential diagnosis on the basis of radiologic appearance showing pericoronal radiolucency includes dentigerous cyst, odontogenic adenomatoid tumor, odontogenic keratocyst, ameloblastoma, calcifying odontogenic cyst and ameloblastic fibroma [3].

In this article we report a challenging case of massive dentigerous cyst which was successfully treated with conservative therapy.

### **Case Report**

A 16-year-old male presented to the Department of Oral and maxillofacial Surgery with a chief complaint of enlargement of the right retromolar and angle region of mandible since 9 months. The patient had no history of any parafunctional habits. On extraoral examination facial asymmetry with diffuse swelling in the region of the right mandibular body was seen. It was firm and tender on

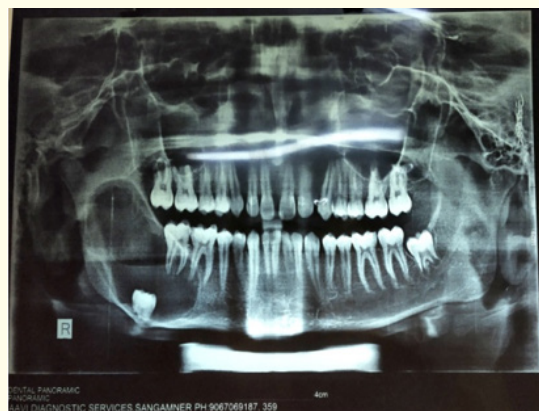
palpation (Figure 1A). Intraoral examination revealed enlargement of the buccal cortical plate at the angle region of the mandible, without mucosal discoloration which was firm and tender. Overlying skin was pinchable with no rise in local temperature and no secondary changes were evident. The patient did not complain of paraesthesia indicating normal functioning of cranial nerves V and VII.



**Figure 1A:** Showing extraoral swelling over right side of mandible.

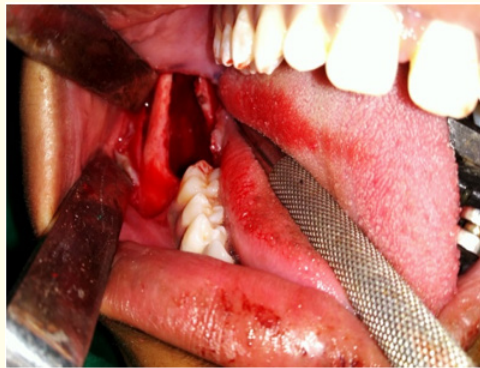History, physical examination, and imaging were not suggestive of any syndromic or systemic involvement. On the basis of clinical and radiographic characteristic, a tentative diagnosis of dentigerous cyst was made. Prior to definitive treatment, needle aspiration (yielding straw-colored fluid) and incisional biopsy was performed. Final histopathological diagnosis revealed the lesion as dentigerous cyst.

Orthopantomogram (Figure 1B) showed an expansile radiolucent lesion involving the right body and the ramus measuring approximately 4.0 cm × 5 cm in size. The impacted lower third molar was displaced and lying in close proximity to the inferior border of mandible. Anterior extension of the lesion was upto the distal root of 1<sup>st</sup> molar. Simple enucleation procedure was planned considering the age of the patient, site of the lesion, as well as the high regenerative capacity of the musculo periosteal capsule of the growing child.

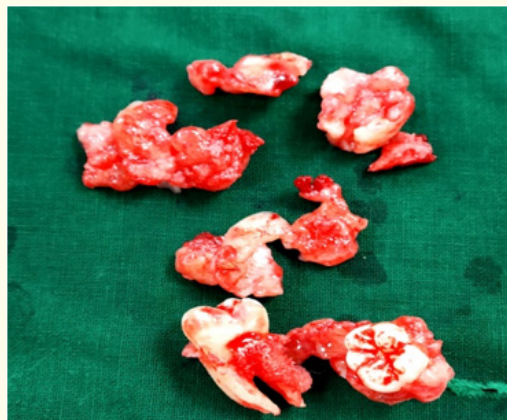

**Figure 1B:** OPG showing extensive dentigerous cyst.

Under general anesthesia, an intraoral incision was placed along the anterior border of the ramus and lateral surface of the mandible were denuded (Figure 1C). The lesion was enucleated in total along with the extraction of third molar and second molar (Figure 1D). Wire eyelets were placed on both sides for postoperative intermaxillary fixation to prevent pathologic fracture. Suturing was carried out in layers to ensure water tight closure. Intermaxillary fixation (IMF) was done on the first postoperative day for 1 week. There were no postoperative complications. Patient was discharged on the 7th postoperative day and was recalled for regular follow up at the interval of 2 weeks.



**Figure 1C:** Intra-oral exposure of cystic lesion.



**Figure 1D:** Enucleated specimen.

## Discussion

Dentigerous cysts are odontogenic cysts arising from the reduced enamel epithelium after the formation of tooth crown. Most common teeth associated with dentigerous cyst are lower third molar and upper canines.

Three different theories have been proposed to explain etiology of the dentigerous cyst [3].

The first theory advocated that dentigerous cyst is the result of accumulation of fluid between the reduced enamel epithelium and the crown of the tooth germ. This fluid accumulation is the result of pressure exerted on the tooth follicle by the erupting tooth, leading to exit of serum exudates from the surrounding capillaries.

The second theory proposes that, the immature permanent tooth encounters a radicular cyst, along its path of eruption originating from its primary predecessor. Since radicular cysts is hardly associated with primary teeth, this is the least accepted hypothesis.

According to the third theory, accumulation of fluid caused by inflammation of the periapical tissues due to a periapical infection originating from the primary predecessor tooth, results in formation of the dentigerous cyst.

Bloch in his hypothesis suggested that the involvement of the follicle of unerupted permanent successor by the periapical inflammation from an overlying necrotic deciduous predecessor results in accumulation of inflammatory exudates, thus presiding the formation of dentigerous cyst [3].

According to Toller, after the impeded eruption, breakdown of proliferating cells of follicle takes place. He further stated that rather than the cyst dimensions and amount of available space within the dental arch, the dentigerous cyst seems to be more influenced by its angulations and position inside the alveolar bone [3].

Motamedi and Talesh, suggested the treatment modalities of dentigerous cyst on the basis of age of the patient, size of the cyst, location of the cyst, dentition affected and relationship with vital structures [3].

Two treatment options are considered:

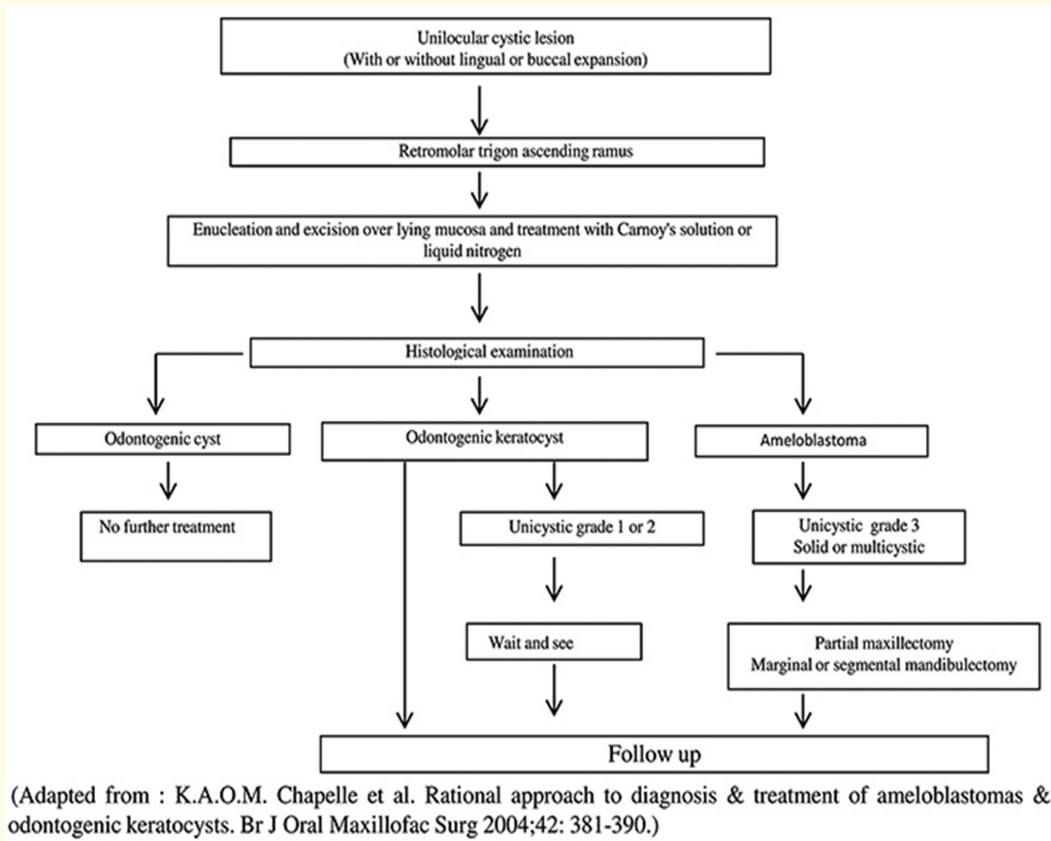
1. Enucleation
2. Marsupialization

The most widely accepted procedure is enucleation of the cyst. Marsupialisation is usually preferred in case of large dentigerous cysts because of its massive size having the potential of causing pathologic fracture and injury to the vital anatomic structures during cyst removal [2]. However, the pathological tissue remains in situ and cannot be histopathologically examined. Whereas in case of enucleation, the cystic lining tissue removed by creating the bony window can be sent for further pathologic investigation [1].

In our case, we preferred enucleation rather than a radical procedure, though it is usually recommended in large cysts. Since the patient being a growing child, a radical treatment might have caused in severe mutilation. Hence conservative treatment modality is advisable in such scenarios.

However, the fate of organized blood clot due to possibility of getting infected which may further lead to unwanted consequences of local inflammation and also the process of osteogenesis in large cystic cavity is questionable, hence many authors contradict practicing enucleation for large cyst.

Chapelle., *et al.* [9], in their case series study mentioned a decision tree for treating large unilocular cysts of the jaws, which includes enucleation of all the unilocular cysts irrespective of its size followed by chemical cauterization. Taking biopsy prior to surgery was deferred since the wound at the biopsy site may retard the clean first hand surgical procedure with respect to the tissue planes and wound infection [2].



Figure

## Conclusion

In our case we experienced that enucleation alone has proved to be successful method for cyst removal. However, the treatment chosen largely depends on the size of the cyst, location, age of the patient, proximity or involvement of the vital structure and also on the surgeon expertise as even the best technique fails if done incorrectly.

## Bibliography

1. Hécio Henrique Araújo de Morai., *et al.* "Bilateral mandibular dentigerous cysts: a case report". *Revista Gaúcha de Odontologia* 62.3 (2014): 299-304.
2. Arakeri G., *et al.* "A massive dentigerous cyst of the mandible in a young patient: a case report". *Plastic and Aesthetic Research* 2 (2015): 294-298.
3. Aggarwal P., *et al.* "Dentigerous Cyst of Mandible". *International Journal of Head and Neck Surgery* 4.2 (2013): 95-97.
4. Sonal Grover., *et al.* "Dentigerous Cyst in a 51-year Old Male -a Case Report". *International Journal of Contemporary Pathology* 1.1 (2015).
5. Fraser A Hale. "Dentigerous Cysts An Avoidable Catastrophe". The CUSP (2007).
6. U Koçer., *et al.* "Giant dentigerous cyst occupying the right hemimandible". *The Canadian Journal of Plastic Surgery* 10.4 (2002): 171-174.
7. Singh S and Singh M. "Dentigerous cyst - A case Report". *Journal of Indian Society of Pedodontics and Preventive Dentistry* 19.3 (2001): 123-126.
8. Anjana G., *et al.* "Management of Dentigerous cyst - A two year review". *International Journal of clinical Paediatric Dentistry* 4.2 (2011): 147-151.
9. Chapelle KA., *et al.* "Rational approach to diagnosis and treatment of ameloblastomas and odontogenic keratocysts". *British Journal of Oral and Maxillofacial Surgery* 42.5 (2004): 381-390.

**Volume 18 Issue 7 July 2019**

©All rights reserved by Prachi Fatangare., *et al.*