

Construction of Planas Direct Tracks by the Indirect Method with the Willis Compass

Silvana Silveira^{1*} and Patricia Valério²

¹Specialist in Functional Jaw Orthopedics, Member of the Scientific Committee of the Brazilian Academy of Functional Maxillofacial Orthopedics, Brazil and Professor of improvement Course of Functional Jaw Orthopedics of Portuguese Cabinet of Dental Medicine, Portugal

²Post Doctor Researcher at Biological Science Institute, Federal University of Minas Gerais, Brazil and Professor of Specialization Course of Functional Jaw Orthopedics, FAOA, Brazil and Scientific Coordinator at Wilma Simões European Institute, Portugal

***Corresponding Author:** Silvana Silveira, Specialist in Functional Jaw Orthopedics, Member of the Scientific Committee of the Brazilian Academy of Functional Maxillofacial Orthopedics, Brazil and Professor of improvement Course of Functional Jaw Orthopedics of Portuguese Cabinet of Dental Medicine, Portugal.

Received: May 27, 2019; **Published:** June 20, 2019

Abstract

This study proposes a new way of doing the Planas Direct Tracks by indirect method. Our purpose is a technical simplification, making it more accessible to public health services and general dentists. The measurement of the vertical dimension and the construction of slopes of Planas Direct Tracks, using Willis's compass and the transfer of Camper Plane to work models using the Calteux and Bakker rule allow us to reduce, complexity of the equipment needed and the cost and time required to build the tracks.

Keywords: Planas Direct Track; Willis Compass; Calteux and Bakker Device; Camper Plane; Planas Development Laws

Abbreviations

PDT: Planas Direct Tracks; VD: Vertical Dimension; PMFA: Planas` Masticatory Functional Angle; TPC: Therapeutic Posture Change; JFO: Jaw Functional Orthopedics

Introduction

The fundamentals of biology, growth and development supported by current research dictate that most of the malocclusions and facial deformities begin mild in early stages of growth and become severe as age advances. The capability of cells, tissues and organs to adapt through normal growth processes is greatest, early in development and diminishes as maturation progresses [1].

The adequate period for interventions on early age, is a relatively short stage of occlusion development, on average lasting between the ages of 3 and 6 years. Although very young, by the end of this period the child already presents approximately 75% to 80% of the adult's sagittal dental archs dimensions [2].

The Planas Direct Tracks (PDT) technique is an effective way to correct dental or functional alterations in children during deciduous dentition and the beginning of mixed dentition, normalizing dental occlusion, mandibular posture, condylar position, and masticatory function [3]. Neuroclusal Rehabilitation is, as it is defined, the study of the etiologies which influence the functional structures, resulting in morphological alterations in the stomatognathic system [4].

The PDT consists in placing the composite at occlusal surface of certain deciduous teeth. The tracks must be “constructed” with inclination, height and specific design, defined through diagnosis, in such a way as to cause changes in mandibular positioning and dynamics, balancing the vertical dimension (VD) by addition of composite and previous selective grinding, according to the type of malocclusion [5].

Planas P [6], postulated in accordance with the second law of minimum vertical dimension: as centric occlusion position coincides with the maximum intercuspation we are facing a functional occlusion. Very often it can happen an interferent contact during closing trajectory, impairing the achievement of centric occlusion coinciding with maximum intercuspation. It will cause a mandible displacement in different directions depending on the contact area, in order to find the maximum intercuspation. It will always be at the expense of diminishing the vertical dimension, and this will be called functional occlusion. The working side of the patient will always be the side of the minimum vertical dimension (VD).

Planas P [7], determined as Planas` Masticatory Functional Angle (PMFA) the trajectory performed by the mandible during lateral movements, starting with a functional occlusion and sliding teeth slow and relaxed to right and left. Starting from the maximum intercuspation position, any movement of the jaw promotes an increase of the VD. According to the law of minimum vertical dimension, there is a physiological tendency to shift the jaw to the side of minimum VD to execute the functions. It means that the patient will be always tends to use more the side that increase less the vertical dimension during lateral movements.

According to this principle, the PDT would be indicated for different situations, like: to release the mandibular movements (as in the deep bites); stimulate the posterior/anterior and transverse mandibular and maxillary growth; to stimulate the dentoalveolar transverse growth of the jaws [8].

Objectives of the Study

The objective of this work is to propose an indirect method of confection of PDT, that respects all the principles and fundamentals of this therapy, however with an easier construction and accessibility.

The camper plane

Petrus Camper [9] studied the profile of the human being and established on the lateral norm of skulls, the Camper Plane or Naso-Auricular Plane. This plane in the bony head runs from the extreme of the anterior nasal spine to the upper portion of the porio. This craniometric point is located on the upper edge of the external auditory canal orifice, situated above the median vertical to that orifice. In the live person, the porio can be guessed by the tragus that lies a little ahead of the external auditory canal orifice and the anterior nasal spine replaced by the lateral nose wing.

Balters W [9] said that the orientation of the occlusal plane on the skull must be parallel to the Camper Plane. If there are anomalies of coordination and correlation of dental arches, we must use the Camper Plane as a reference, and proposes the transfer of the Camper Plane to the maxilla teeth on the upper occlusal surface, using the device created by Bakker and Calteux.

Materials and Methods

The parallelism between the Camper`s Plane and the occlusal plane must be considered, and it is of fundamental importance to transfer this data to the practice of building the PDT. With the clinical and laboratory technique presented below, it is easy and accurate to make working models that position the teeth and their bone bases in correct relation to the craniofacial structures [9].

Materials used: Calteux and Bakker occlusal plane device; wax No. 7 or heavy silicone, lamp, alcohol and lighter; gypsum trimmer; plaster moldings of the upper and lower arches for trimming. Next, we will establish the clinical and laboratorial steps to take the Camper Plane according to the mentioned principles.

- Use a preheated wax blade on the 7 (or heavy silicone in the shape of the upper arch) that should be folded as an accordion.
- First, adapt the wax roller (or silicone) to the upper arch (Figure 1).

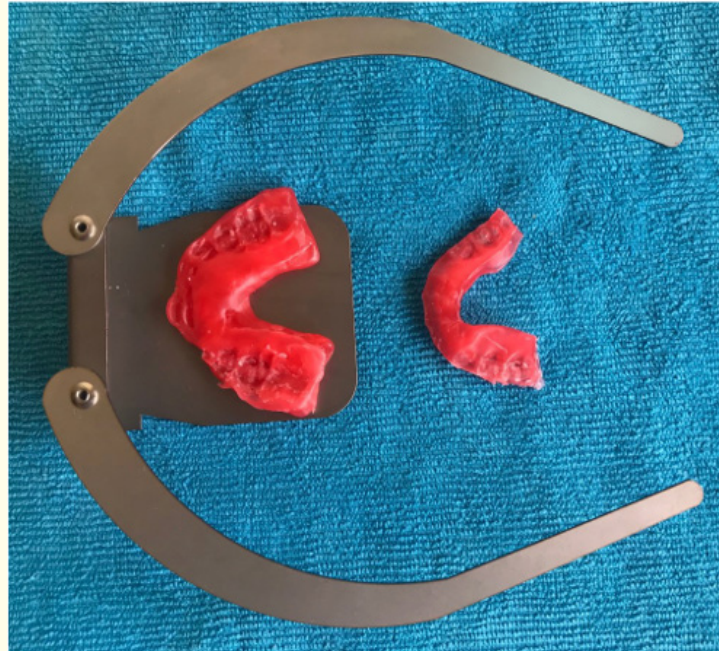


Figure 1: Adapt the wax roller (or silicone) to the upper arch.

- Carry the device (Camper Plane protractor) by matching it to the anterior/inferior portion of the nose wing and right and left auric Tragus (Figures 2 and 3).

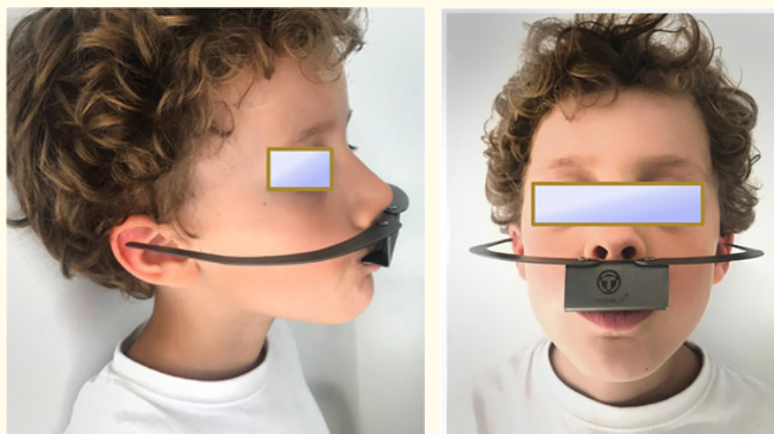


Figure 2 and 3: Carry the device (Camper Plane protractor).

- Carefully observe the orientation of the protractor on both sides of the patient.
- Remove the set (wax bite and protractor from Camper Plane) from the patient’s mouth and evaluate whether the wax recorded the dental impression on one side and formed a stable plane on the other.

Under a flat surface support, the upper model on the wax bite with the device that generate the parallelism with Camper Plane and use the paralelometer to mark a line that will guide the cutting of the upper base of the superior model (Figure 4).




Figure 4: The paralelometer to mark a line that will guide the cutting of the upper base of the superior model.

Model Cut-out

With the maximum intercuspation wax bite interposed between the upper and lower models, support the superior base of the superior model on the bench to delineate the lower base of the inferior model also parallel to the Camper Plane and thus perform its trimming (Figure 5).



Figure 5: Delineate the lower base of the inferior model.

Thus, we will have the upper and lower model with the respective bases parallel to the Camper Plane (Figure 6).

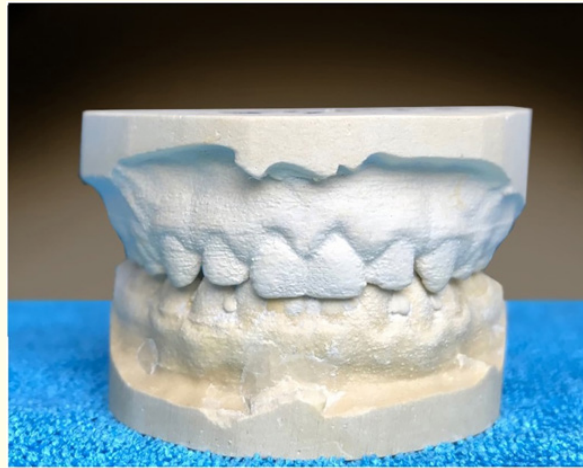

Figure 6: The upper and lower model with the respective bases parallel to the Camper Plane.

The Willis Compass

Willis FM [10] developed a compass, in the shape of the letter “L” with the larger rod millimeter and a slider that, by means of an adjustable screw fixed to the larger rod in the desired distance.

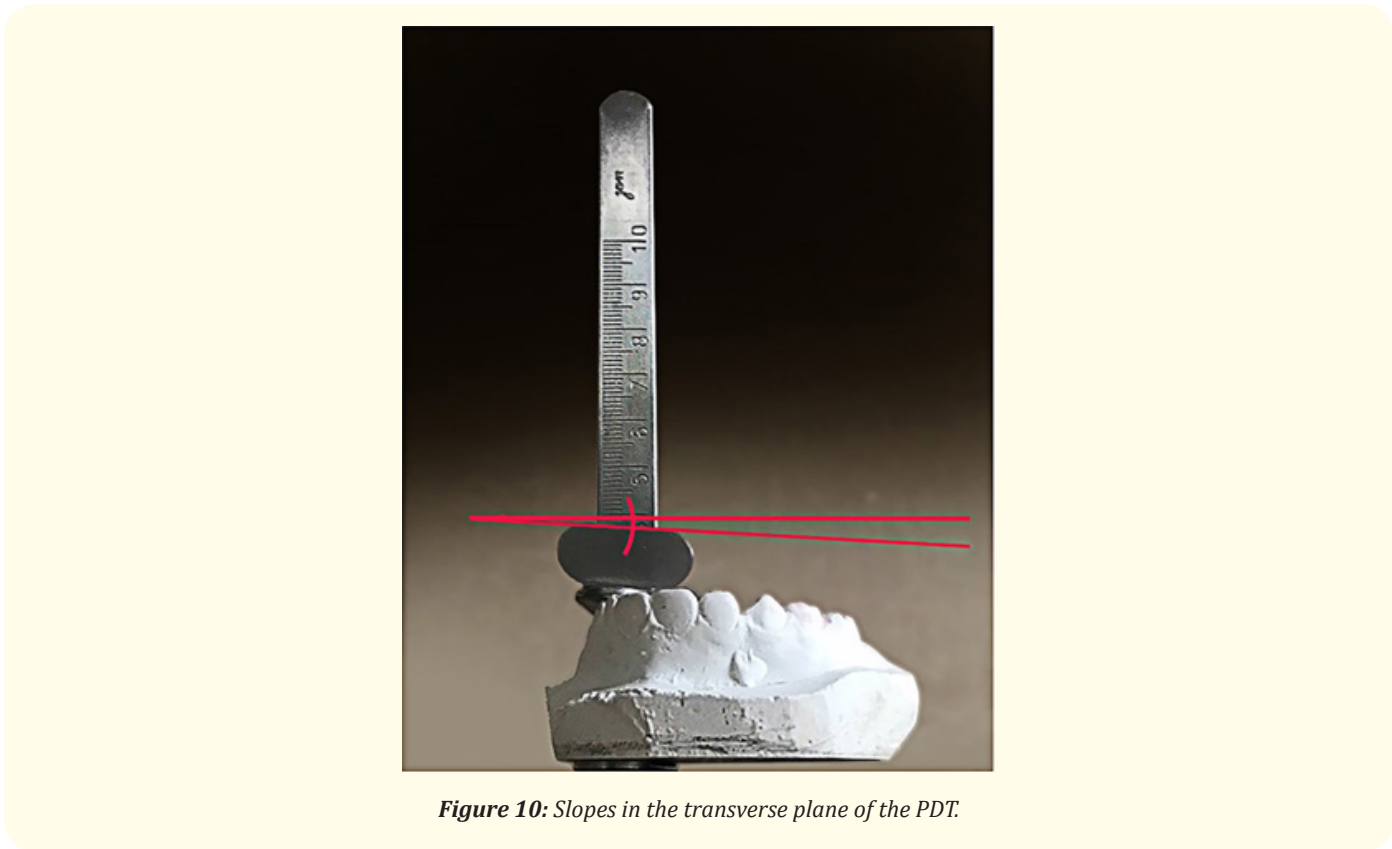
Although our objective is not to use the “Metric System” proposed by Willis F. M, the instrument he designed allows us to determine: the right and left vertical dimension, measuring the distance between the Camper Plane and the occlusal plane, and build the specific inclinations of the PDT planes for each type of malocclusion. It is simple, accurate and individualized.

In the sagittal direction the PDT should be parallel to Camper Plane for all types of malocclusion, which is easily achieved by placing the Willis Compass moving ruler on the basis of the superior working model (which is referenced to the Camper Plane) and the fixed base of the ruler, previously isolated with Vaseline on the occlusal surface of the teeth that received the composite resin for the construction of the PDT (Figure 7).



Figure 7: Willis Compass ruler on the basis of the superior working model.

In cases of unilateral or bilateral crossbites, Brodie and Sim say it is necessary to make certain slopes in the transverse plane of the PDT, so it is recommended to make small bilateral grooves in the movable ruler of the Willis Compass in order to enable such inclinations, as shown in the figures (Figures 8-10).



Demonstration of the construction of the PDT (by the indirect method with Willis Compass) from a clinical case.

Case Report

Female patient. Age: 5 years old and 7 months. Diagnosis of deep bite, with limitation of right and left laterality (Figures 11-13). With the superior and inferior models properly cut parallel to the Camper’s Plane, we will begin the construction of the PDT.

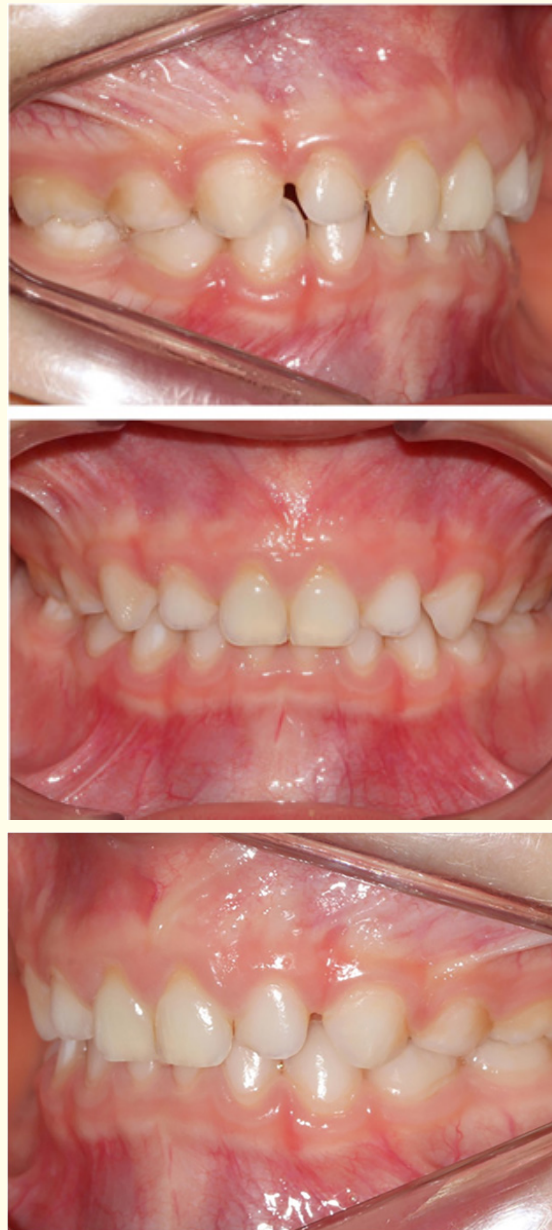

Figure 11-13: EL 5 years old and 7 months.

1. Determine the Therapeutic Posture Change (TPC) needed for the case and mark the reference lines: TPC of the mandible is one of the fundamental principles of Jaw Functional Orthopedics (JFO). It is fundamental to determine the ideal therapeutic position and it will be determined by a good diagnosis generating a correct treatment planning. As it's shown in the following images (Figure 14 to 18).

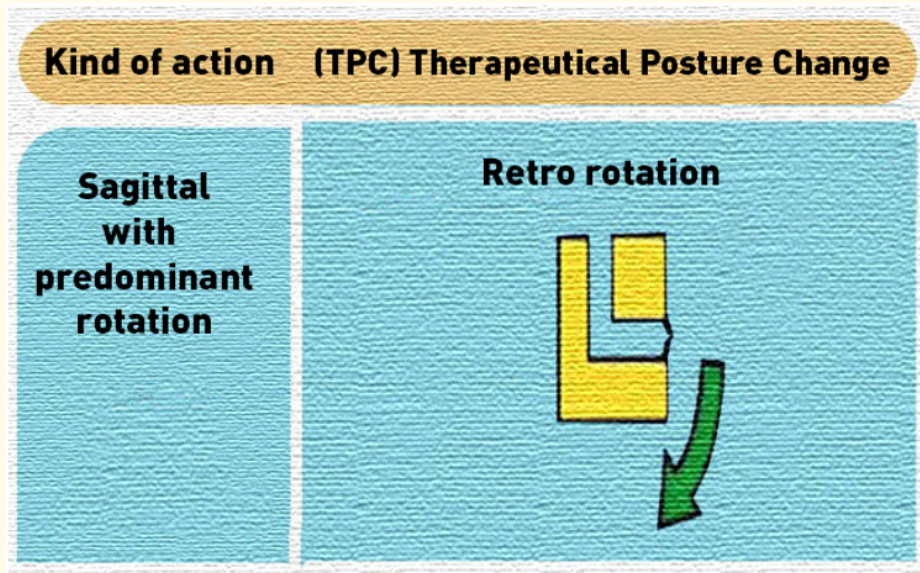


Figure 14: For the case described (deep bite), the TPC was chosen in retro-rotation.

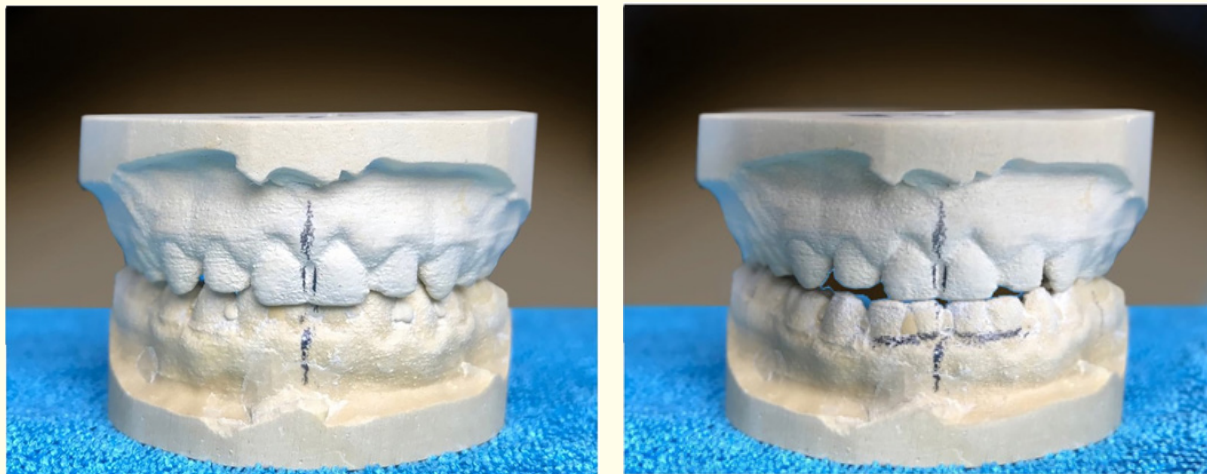


Figure 15 and 16: Therapeutic Posture Change (TPC) marks.




Figure 17 and 18: Therapeutic Posture Change (TPC) measurement.

2. Check the equivalence of the vertical dimension of the right and left side of the models after the TPC with the help of the Willis Compass. Melt the wax that is in the interocclusal space (Figures 19 and 20).

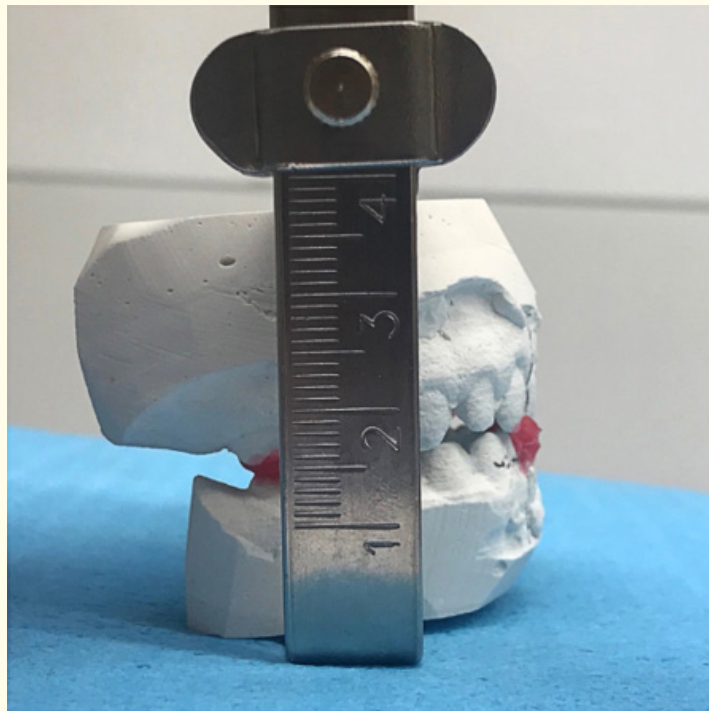


Figure 19: Right checking the equivalence of the vertical dimension.

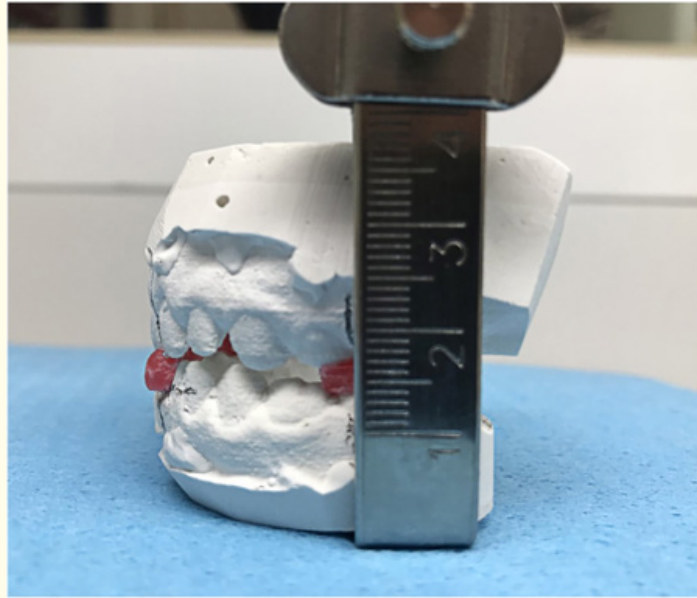


Figure 20: Left checking the equivalence of the vertical dimension.

3. Make grooves in the lower model to fix acrylic columns and isolate from the gypsum's collar distal to the last upper molar (Figure 21).

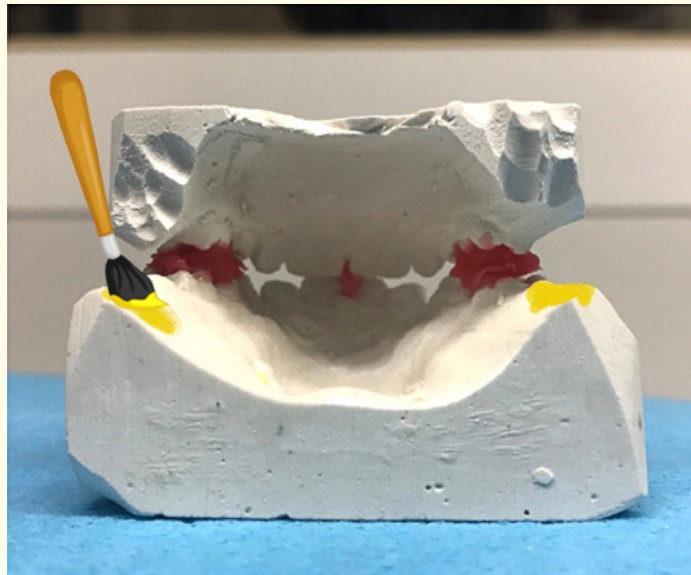


Figure 21: Grooves in the lower model and isolate from the gypsum's collar distal to the last upper molar.

4. Making the acrylic columns and anterior stop (Figure 22-24).

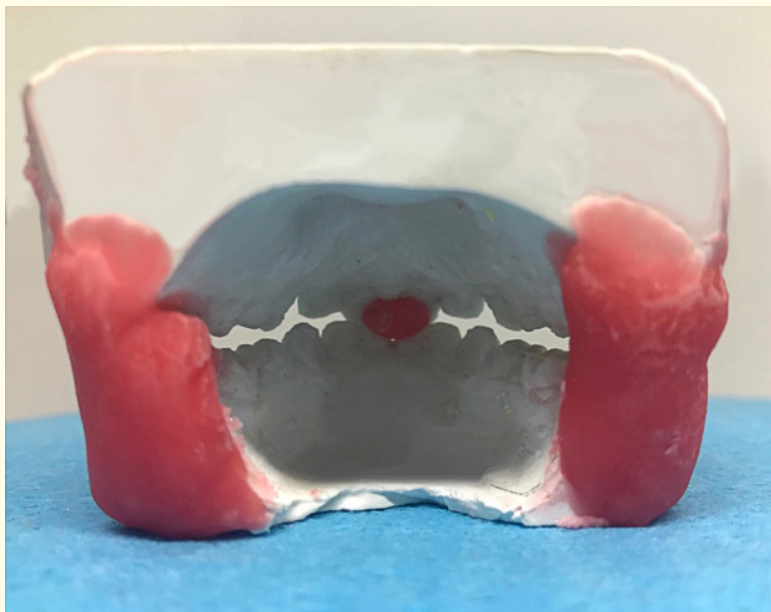


Figure 22: Acrylic columns, posterior view.

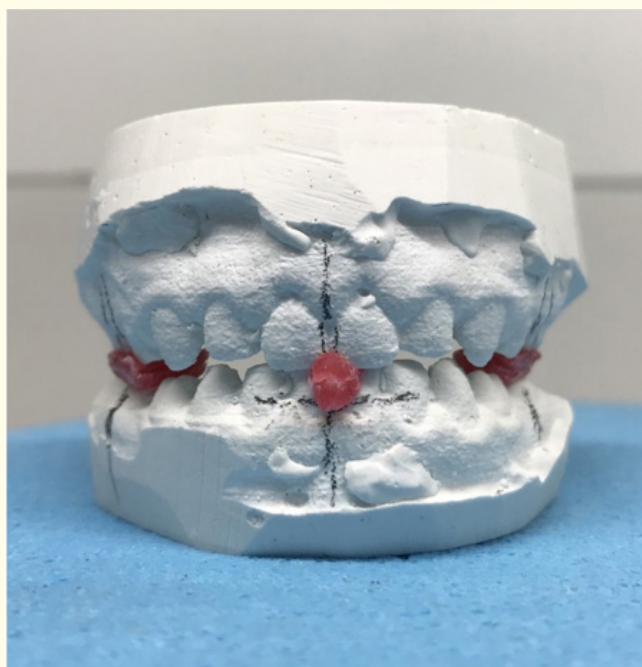

Figure 23: Anterior stop.

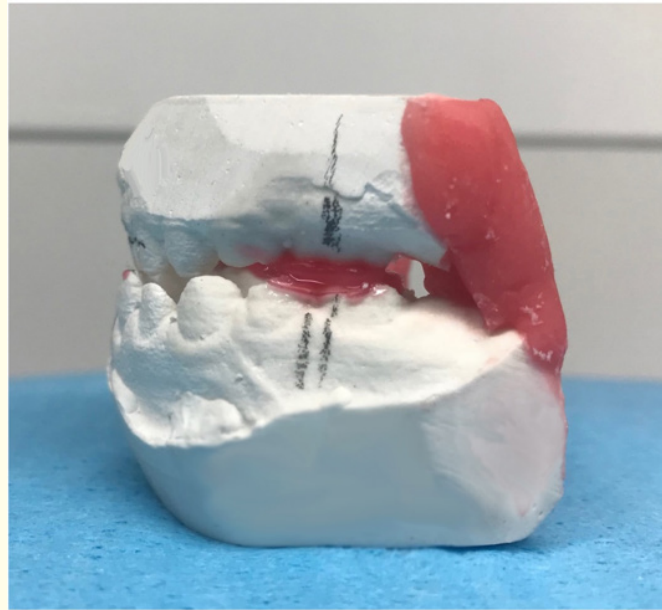


Figure 24: Acrylic columns, lateral view.

5. With TPC, there will be an inter-occlusal space in which the track should be placed. Make the transfer of the Camper Plane to this space. The models should be supported under a flat surface and with the graphite tip of the parallelogram pointing to half the largest inter-occlusal space between the arches that will receive the PDT. Move the parallelogram by-passing this space. Such risk will give the indication of the teeth that will receive resin, and those that must undergo selective grinding, which must be done on the models and in the mouth before the placement of the PDT (Figure 25 and 26).



Figure 25: The transfer of the Camper Plane to an inter-occlusal space, right side.

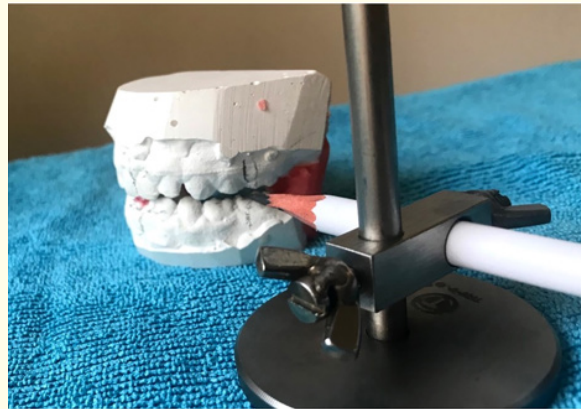

Figure 26: The transfer of the Camper Plane to an inter-occlusal space, left side.

6. The upper PDT is first constructed by placing composite resin in the occlusal of the upper teeth selected to receive it. Use the Willis Compass to obtain the parallelism with the Camper Plane in the transverse and sagittal direction. Inclinations are recommended for cases of deep bite (Figure 27 and 28).




Figure 27: PDT is first constructed by placing composite resin in the occlusal of the upper teeth selected.

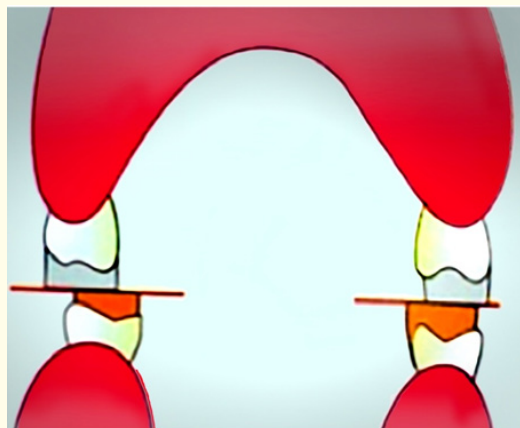


Figure 28: Maria Regina Brandão Apud: Pereira M. B. B. Manual of Functional Jaw Orthopedics. Rio de Janeiro [13].

7. Once the superior composite has been polymerized, place an adhesive tape on PDT surface, brushing its outer surface with liquid vaseline, and place composite resin on the lower teeth occlusal surface. After it, occluding the models through the acrylic columns and the previous stop (Figure 29 and 30).

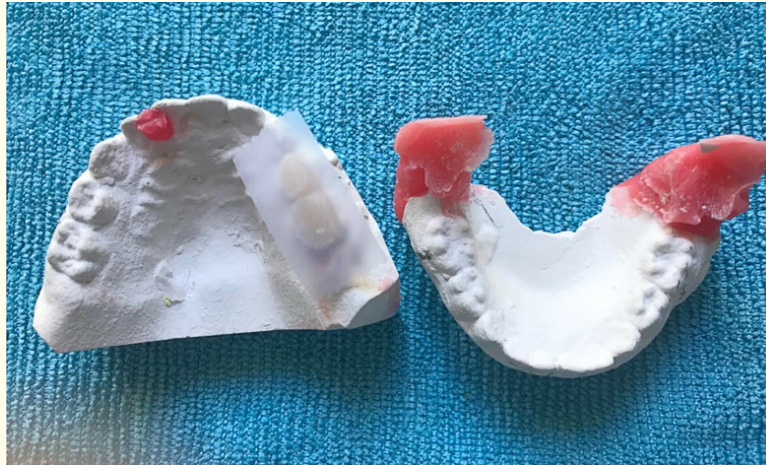

Figure 29: Adhesive tape on PDT surface.




Figure 30: Placing composite resin on the lower occlusal surface.

8. Polymerize, remove the tape and start the finishing, and make partial trays of vinyl or polypropylene of 0.3 or 0.5 mm (Figures 31).

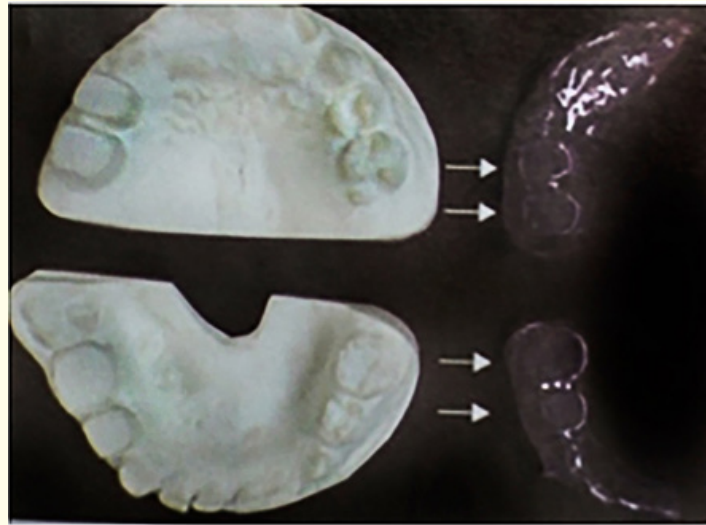


Figure 31: Maria Regina Brandão Apud: Pereira M. B. B. *Manual of Functional Jaw Orthopedics*. Rio de Janeiro [13].

Discussion

The technological development led to the optimization and application of computerized diagnostic systems able to provide us with important diagnostic data, as well as the optimization in the construction of PDT.

Planas P [6] developed the Planas Symptomologic Diagnostic Method that produces plaster models whose bases are precisely oriented in the three planes of the space (median sagittal, Camper horizontal, frontal). The Planas Symptomologic Diagnosis establishes a relationship between the occlusal plane and the Camper Plane, soft tissue relationship, mandibular and mandibular position deviation, as well as deviation of the dental and mandibular arches, thus enabling a three-dimensional analysis.

The great excellence of these means of diagnostics has already been proven in several studies, however the use of Gnathostatic models for the construction of PDT, as well as the construction of PDT in a virtual, digitized form sometimes face problems. Due to their complexity, cost and need for high-tech/or equipment that are not always accessible in public health services and universities or even because of the difficulty of acquiring the equipment in some countries, the PDT therapeutic faces difficulties to be implemented in many countries. This work tries to bring a more simple but effective way of doing it.

The malocclusions constitute a focus of discussions in public health. For this reason, it is necessary to incorporate procedures for its correction that are low cost, easy to perform and that can be performed in the health services [4].

We adopted recommended criteria for selecting the ideal method to determine the VD: accuracy and reliability of the measurement, adaptation to the technique, type and complexity of the measurement equipment, cost and time required to perform the technique and verify that the use of the Willis Compass to make the PDT respond to the parameters of requirement of the technique [11].

PDT can be built directly in the mouth, but this requires a highly skilled and experienced operator, as well as a high level of patient cooperation. If selective grinding is required, it should be performed on the casts before the tracks are constructed and then reproduced in the mouth [12].

In the clinical case presented, the PDT provided an increase of the VD, allowing lateral movements during chewing and more space for the tongue and for eruption of the first permanent molars in the vertical direction (Figure 32-34).

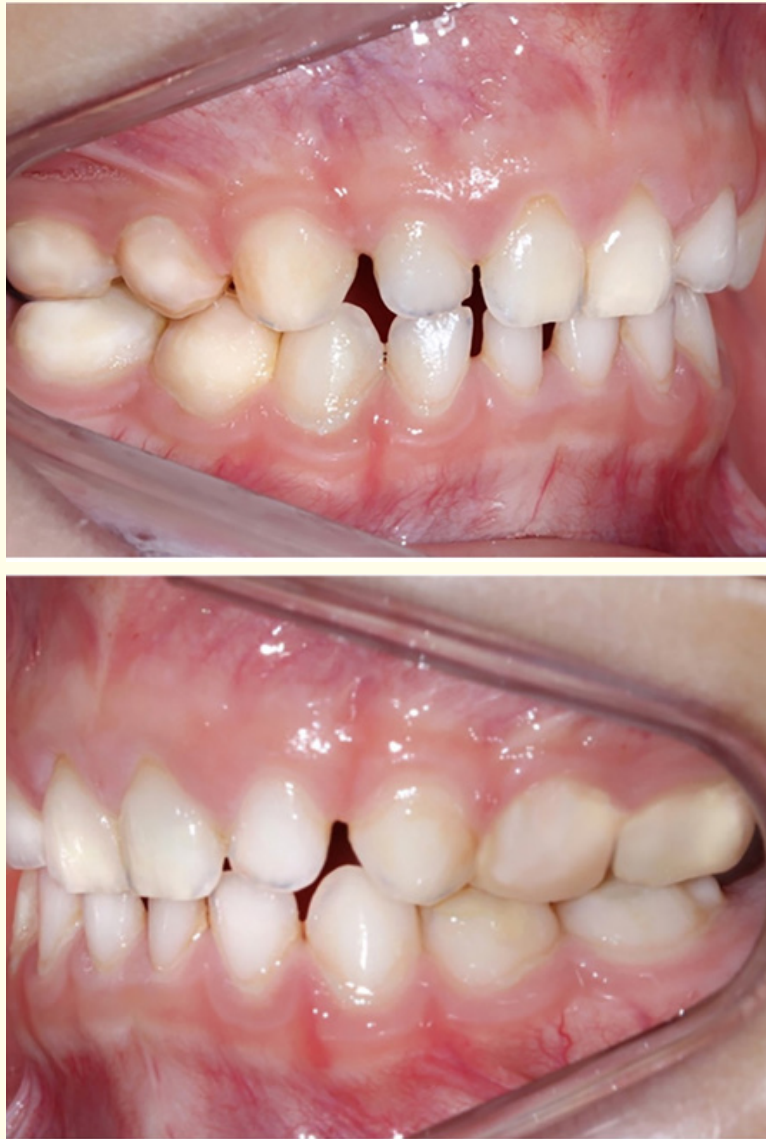

Figure 32-34: EL 6 years old.

Petrovic's analysis shows a rotational group R2DOB with growth potential= 3, where there is a small difference in the growth potential of the maxilla and the mandible. The prognosis is moderately favorable, since that a change in Mandibular Growth Rotation is made, making it posterior and thus reducing the discrepancy between the maxilla and the mandible.

Conclusion

The described method is recommended as an alternative way to determine the VD and the Camper Plane with accuracy and reliability of measurement, reduction of the complexity of the necessary equipment, as well as the cost and time required to make the PDT.

The use of Calteux and Bakker device and Willis Compass makes the PDT building more accessible and faster. Since in cases of deep bite, the VD is smaller in the posterior region (Figure 35 and 36) however after the construction of the PDT, we can “reverse” this height and the VD becomes smaller in the anterior region, thus favoring the anterior positioning of the mandible and the function, as shown in figures 37.

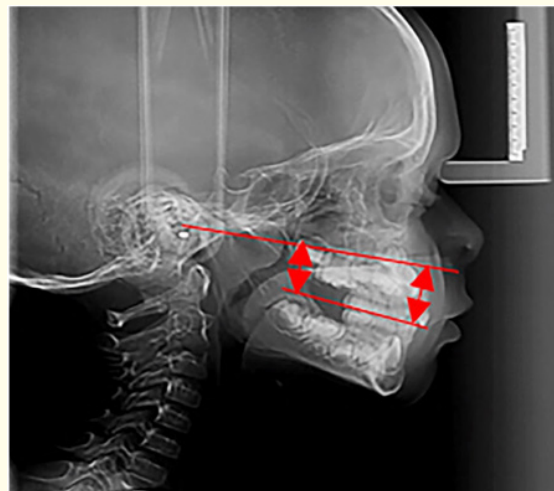


Figure 35: VD is smaller in the posterior region.

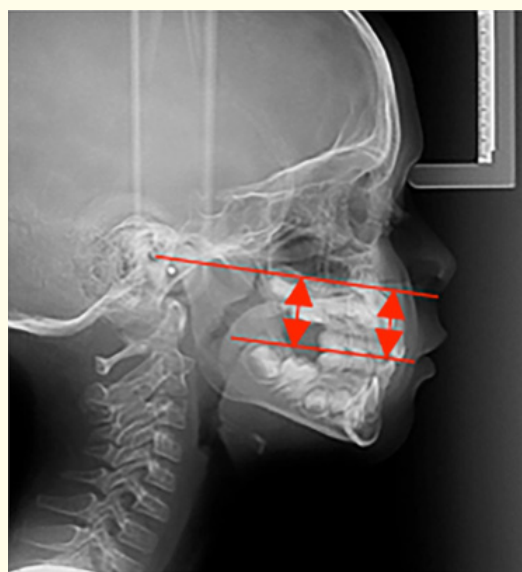


Figure 36: VD is smaller in the anterior region.



Figure 37: After the construction of the PDT, we can “reverse” this height and the VD becomes smaller in the anterior region.

The PDT therapy consists in balancing the PFMA, which were achieved in the case demonstrated using this method (Figure 38 and 39).

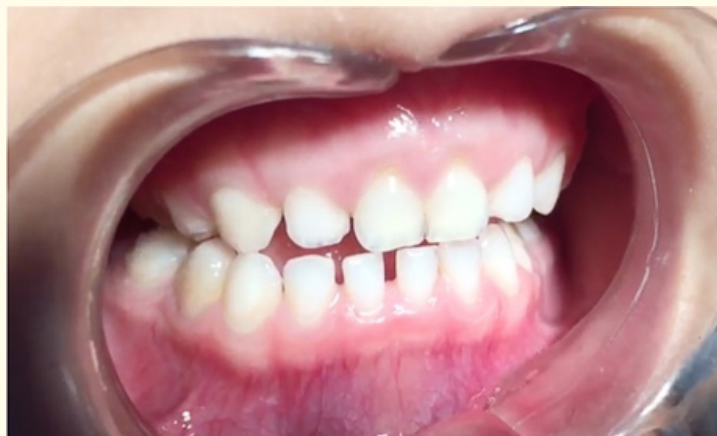

Figure 38: Right planas' masticatory functional angle.

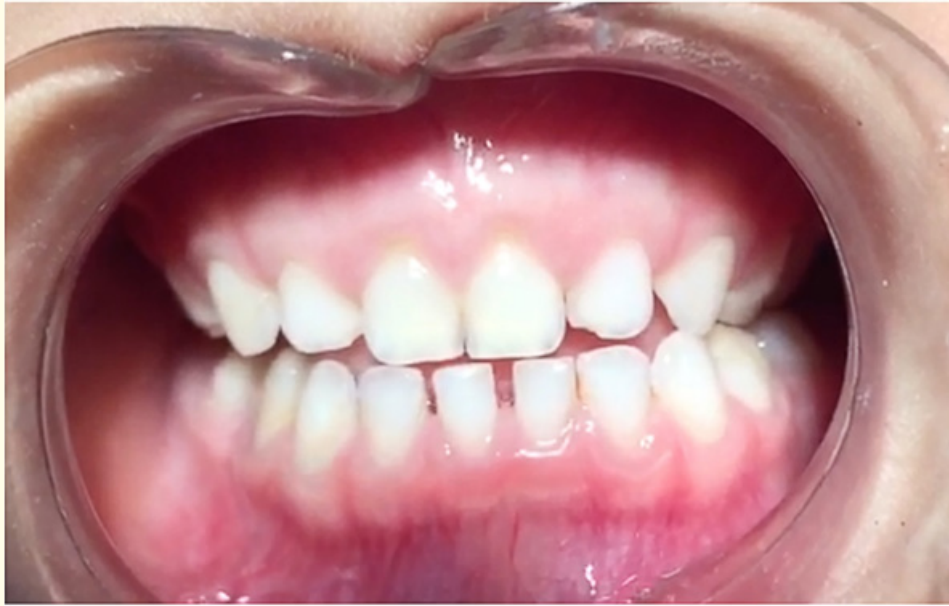

Figure 39: Left planas' masticatory functional angle.

Bibliography

1. Vora Ketan S., et al. "An Innovative Approach for Correction of Pseudo Class III Malocclusion with The Use of Planas Direct Tracks". *APOS Trends in Orthodontics* 3.6 (2013): 190-196.
2. Chibinski AC and GD Czulniak. "Evaluation of Treatment for Functional Posterior Crossbite of The Deciduous Dentition Using Planas' Direct Tracks". *Indian Journal of Dental Research* 22.5 (2011): 654-658.
3. Santos RR., et al. "Early Correction of Malocclusion Using Planas Direct Tracks". *Case Reports in Dentistry* (2013): 395784.
4. Garbin AJI., et al. "Planas Direct Tracks for The Treatment of Posterior Crossbite". *Revista Cubana de Estomatología* 51.1 (2014): 113-120.
5. Simões WA. "Selective Grinding and Planas Direct Tracks as a Source of Prevention". *The Journal of Pedodontics* 5.4 (1981): 298-314.
6. Pereira MBB. *Manual de Ortopedia Funcional dos Maxilares*. Rio de Janeiro: Santos (2017).
7. Planas P. "Reabilitação Neuroclusal". Rio de Janeiro: Medsi (1988): 17-18.
8. Rossi, Leandro B., et al. "Correction of Functional Anterior Crossbite with Planas Direct Tracks: A Case Report". *FOL – Faculdade de Odontologia de Lins/Unimep* 22.2 (2012): 45-50.
9. Gallão S., et al. "Plano de Camper". *Revista Clínica de Ortodontia Dental Press* 3.5 (2004): 20-28.
10. Willis FM. "Esthetics of Full Denture Construction". *The Journal of The American Dental Association* 17.4 (1930): 636-642.

11. Johnson A., *et al.* "The Determination of Freeway Space Using Two Different Methods". *Journal of Oral Rehabilitation* 29.10 (2002): 1010-1013.
12. Ramirez-Yañez GO. "Planas Direct Tracks for Early Crossbite Correction". *Journal of Clinical Orthodontics* 37.6 (2003): 294-298.
13. Maria Regina Brandão Apud: Pereira M. B. B. *Manual of Functional Jaw Orthopedics*. Rio de Janeiro: Santos (2017): 284-289.

Volume 18 Issue 7 July 2019

©All rights reserved by Silvana Silveira and Patricia Valério.