

Multidisciplinary Treatment of Dental Fusion

Nur Ozel^{1*} and Alev Aksoy²

¹Izmir Educational Dental Hospital, Konak, Izmir, Turkey

²Department of Orthodontics, Faculty of Dentistry, Süleyman Demirel University, Isparta, Turkey

*Corresponding Author: Nur Ozelm, Izmir Educational Dental Hospital, Konak, Izmir, Turkey.

Received: April 22, 2019; Published: June 21, 2019

Abstract

Fusion, a rare anomaly of the hard dental tissues, can cause clinical problems connected to look, spacing and periodontal problems. It is an anomaly in proportion, form, and structure of teeth. Fused teeth can have unattached pulp, one pulp chamber and two pulpal canals or large twin crown with one pulpal canal.

In this article, we report a rare case of a maxillary central incisor fused to a supernumerary tooth showing labial and palatal talon cusps. A 11-year-old Turkish boy was referred to our clinic with complaint of unaesthetic smile. He was rehabilitated successfully via a multidisciplinary approach involving orthodontic, nonsurgical endodontic, and nonrestorative crown treatments. After a 26-month treatment period, the patient's macroesthetics and microesthetics were improved.

Keywords: Fusion; Macrodontia; Talon Cusp; Maxilla; Double Teeth; Anomaly

Introduction

Developmental dental disorders can be because of anomalies in the separation of the dental lamina and the tooth germs (anomalies in number, size, shape) or to abnormalities in the formation of the dental hard tissues (abnormalities in structure). In some, in both stages of separation are deviating. developmental dental disorders are not only congenital, but they may also cause of hereditary transfer, immune deficiency or idiopathic disease. The terms "twin crown", "double shape", "attached teeth" or "fused teeth" are often used to explain germination and fusion that are main developmental anomalies of teeth [1,10,11].

Conventional terminology sorts out fusion as a conjugation of two independently explicating tooth germs typically conducting to one less tooth normal in the impacted arch. Radiographically the adjacency of two root canals and one or two roots may be understandable. In cases where there is conjugation of a normal tooth germs to a supernumerary tooth germ, the number of teeth is also ordinary and distinction from germination may be very hard. In geminated teeth, division is generally unfinished and consequences in a wider tooth crown that has a sole root, sole canal. In geminated teeth, separation is generally immature and consequences in a wide tooth crown that has a sole root and a sole pulp canal [2].

The term "Talon cusp" was excepted due to its close similarity to an eagle's talon. this status has a preference for permanent maxillary lateral (55%) and central (33%), following mandibular canines (6%), and maxillary canines (4%). It has a frequency ratio of 0.06% in Mexican, 7.7% in North Indian, 0.17% in American and 2.5% in Hungarian kids. Talon cusp is creation of normal enamel and dentin comprising differing enlargement of pulp tissue it can happen alone or in connected with dens invaginatus in a few cases. Clinical administration of this progressive anomaly differing from patient to patient. Ordinarily, it is asymptomatic; however, some patients might have aesthetic and functional problems of occlusal interference and deposition of local factors which can consequence in the progressive of caries and periodontitis. the abrasion of cusp can reveal the pulp horn; therefore, prophylactic enameloplasty can be needed. Also, desensitiz-

ing agent along with coordinated clinical and radiographic follow-up might be useful. The existence of multiple talon cusps on maxillary central incisors is an enormously seldom phenomenon. Besides it, in this case had talon cusps in maxillary anterior teeth and impacted supernumerary teeth [3]. Dental fusion is usually asymptomatic and does not need any treatment. However, there could be inadequate aesthetics, periodontal injure or caries heading up to pulp necrosis [4].

The aim of this clinical case report was to describe one of the developmental disorders and present the non-extraction orthodontic treatment of a fused maxillary central incisor with labial and palatal talon cusps in the mixed dentition by using a multidisciplinary approach.

Case Report

Diagnosis and Etiology

A 11 year old male patient was referred to our clinic with complaint of unaesthetic smile (Figure 1). He had a normal right incisor but left bigger than the right one was diagnosed by periapical radiograph as a dental fusion (Figure 2). He and his parents did not detail about any medical history. He was in the mixed dentition. The non-extraction treatment was arranged. Pendulum appliance and cervical headgear were applied simultaneously for left dental anomaly to gain space (Figure 3). When premolars erupted, fixed appliances were performed. Extraoral evaluation presented that he had an orthognathic face on frontal view. The upper midline of the maxillary teeth is relative to the face. Even so, a lower dental midline diverged to the right in connection to the facial midline. On lateral view he presented an orthognathic profile.

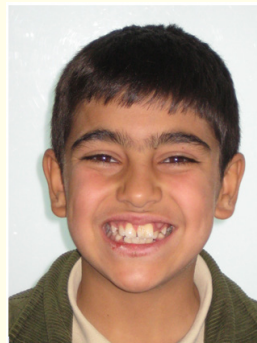

Figure 1

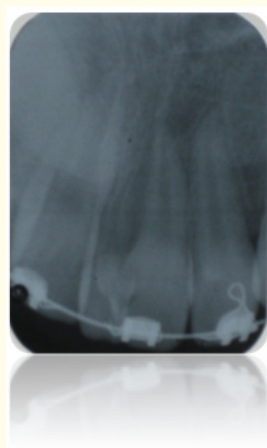

Figure 2

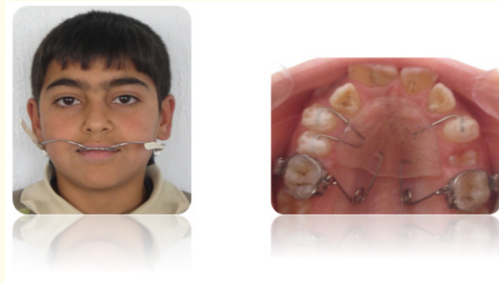


Figure 3

Intraoral exploration presented an Angle Class I relationship on the right side and an Angle Class I relationship on the left side (Figure 4). Both the right and left canines presented an Angle Class III relationship. The right and left canine was not erupted, and the upper dental midline was diverged 1 mm to the patient’s right. The upper right and left central incisor was winged and the upper left central incisor was fused to a supernumerary tooth performing a large mesiodistal proportion. The oral hygiene condition was moderate. Periapical radiography showed no root anomalies (Figure 2).

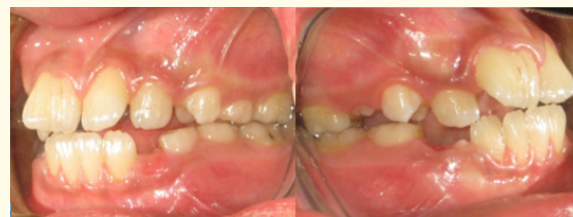

Figure 4

The pretreatment cephalometric tracing estimation revealed an ANB angle of 30, showed a Class I skeletal relationship. Maxillary (U1-SN: 112,30) and mandibular incisor inclinations (IMPA, L1-MP: 96,30) were within normal limits. A normal growth pattern was seen (Table 1).

Analysis	Pretreatment	Posttreatment
Skeletal		
SNA (°)	86,4	87
SNB (°)	83,4	83
ANB (°)	3	4
SN-GoGn (°)	33,5	35,5
Wits (mm)	1,8	1,6
Dental		
Interincisal angle (°)	117,8	121,2
IMPA (L1-MP) (°)	96,3	98,7
U1-SN (°)	112,3	114
Soft Tissue		
Upper Lip to S-line (mm)	0 mm	1 mm
Upper lip to E-line (mm)	-1 mm	0 mm
Lower Lip to E-line (mm)	1,5 mm	1 mm

Table 1: Pretreatment and post-treatment cephalometric measurements.

Treatment objectives

The treatment aims for this patient were to accomplish a stable occlusion, to rehabilitate esthetics and function in the anterior region, and to rectify the molar and canine relationships. A multidisciplinary treatment approach was supported by an orthodontist, an endodontist, a periodontist, and a prosthodontist. The orthodontist had to collaborate with the other specialists to establish a balanced facial profile and occlusion within normal limits.

Figure 5 pretreatment and post-treatment lateral cephalometric radiographs.

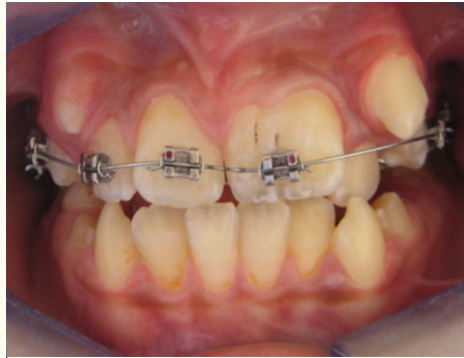

Figure 5

Initially, the treatment sorted out using fixed orthodontic appliances with pendulum appliances and cervical headgear, followed by to obtain enough space for two canines. The correspondence of upper and lower dental midlines would be accomplished by grinding of the macrodontic incisor through mesial side. The endodontist purposed to get rid of the complication of pulpal reactions during the prosthodontic preparation and restoration of the tooth, however the periodontist aimed to sustain periodontal health during the treatment and to reform the gingival contour around the macrodontic central incisor, but oral hygiene was still moderate.

Treatment alternatives

The first alternative comprised of extracting the macrodontic maxillary left central incisor, aligning the teeth via orthodontic treatment, implant placement for the maxillary left central incisor. The first alternative was not chosen because of the patient's young age, since the patient would have to stay a long time until implant implement [4].

The second alternative composed of extracting the fused maxillary left central incisor, aligning the teeth orthodontically, and arranging a crown and bridge work for the maxillary left central incisor. This chance of resorption in the alveolar bone related to extraction and the continuing dental progress in the young patient [5].

The third alternative was first to implement hemisection of the fused left incisor, with root canal treatment. This alternative was not preferred due to the macrodontic tooth was vital and asymptomatic.

The fourth alternative was to not extract the left central incisor because of its anatomic size and an acceptable size to accomplish orthodontic treatment including the movement of the first molar teeth with pendulum appliances and cervical headgear to gain a straight movement. This alternative was preferred for the young patient in order to evade a dental implant or a fixed crown and bridge restoration in the maxillary anterior region. The patient and his parents gave permission for the treatment programme and publication of the case report.

Treatment progress

First of all, periodontist gave education to control oral hygiene. After a adequate hygiene goal, the patient was sent back to the clinic of orthodontics., After the labial talon cusp was gradually ground to have a flat labial surface, the fixed appliances were placed.

American Orthodontics 0.018-inch (Sheboygan, WI, USA) roth brackets were used for this patient. The pendulum appliances and cervical headgear were applied simultaneously for left dental anomaly to gain space. After full eruption of the premolars and solving crowding, we decided to start the fixed treatment. The fix braces were initially bonded on the maxillary teeth. Firstly a 0.014-inch NiTi arch wire was inserted to initiate tooth movement, leveling, and transverse arch form progress (Figure 5). Two months after the first appointment, Mandibular arch was placed braces. A 0.014-inch NiTi arch wire was placed to mandibular arch.

After 3 months of treatment, a 0.016-inch NiTi wire was used as a second arch wire in both the upper and lower jaws for ongoing alignment. Two months later, a 0.016 × 0.016-inch NiTi wire was placed in both the jaws to start working on torque, root angulations, and controlling rotation, to achieve transverse arch form progress. Some other 3 months, a 0.016 × 0.022-inch NiTi arch wire was performed in the upper and lower arches to prepare for the insertion of the running stainless steel (SS) wire.

After 16 months of treatment, a 0.017 × 0.025-inch SS wire was inserted in the maxillary arch. A 0.019 × 0.025-inch SS wire was used to the mandibular arch to sustain whole interarch relationship. 5/16-inch, 6 oz elastics were used.

The patient used the elastics for 6 months. Solving the crowding, correction of the Class II relationship, and gaining enough space for left incisor, had been succeeded after 26 months. The periodontist reformed the gingival tissue to achieve an interdental papilla but his oral hygiene was still not enough. We first micro ground the mesial side of the left incisor and a composite laminate was performed esthetically. We preferred a laminate restoration, in spite of harmless treatment.

During the preparation of macrodontic tooth, the pulp chamber was invulnerable, no complication occurred.

After retaining the maxillary and mandibular teeth, a vacuum-formed retainer (VFR) was used to support the retention in the jaws.

Results

The post-treatment facial photographs indicated an esthetic smile and face. We succeeded macroesthetics and microesthetics (Figure 6). A adequate overjet and overbite relationship were acquired. The dental Class II relationship was corrected and a constant occlusion was gained (Figure 7). The midline disparity was still showed. Adequate incisal and canine relationship was succeeded. The gingival tissue on all sides of the fused tooth was still not healthy because of his oral hygiene habits. No indication of root resorption was showed. Maxillary retention was and mandibular retention was achieved with a VFR. Facial and dental esthetics of the young patient was sustained throughout 1-year retention period (Figure 8). The patient stayed stable throughout the post-treatment period.

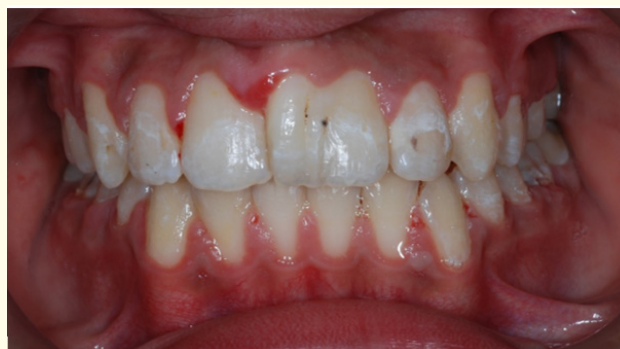

Figure 6

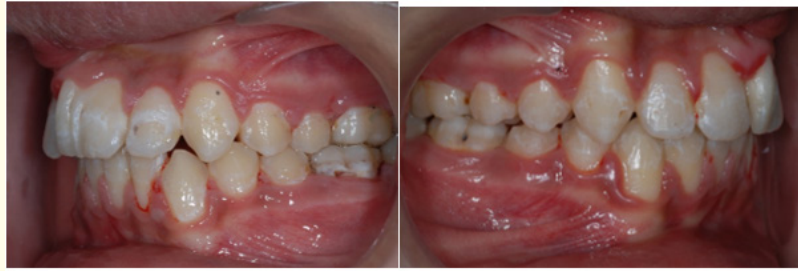

Figure 7

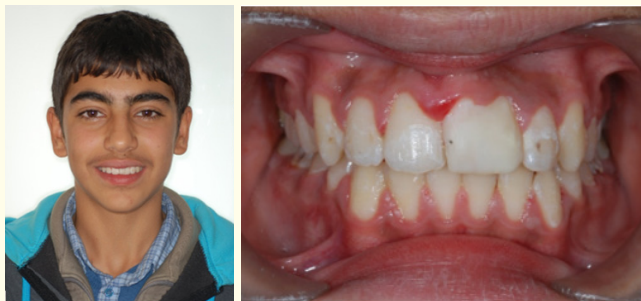

Figure 8

Discussion

Developmental anomalies nearly often happen in the maxillary incisor region and induce esthetic and dental problems [6,7]. Classifying them as anomalies can be harder. Fused teeth are usually described to as macrodontia, megadontia, or double teeth [8]. These dental anomalies happen at unlike ratio in diverse populations. In the Turkish society, the frequency of fusion was found to be 0.23% and maxillary lateral incisors were the most common influenced teeth [1].

To our cognition, this case report is the initiate on a permanent maxillary “double-tooth” with labial and palatal talon cusps that has been treated with non-extraction. Double teeth generally are asymptomatic but are potentially disputable due to their mesiodistal proportion is larger than that of normal incisors. Due to the composite structures of fused teeth, a multidisciplinary approach is generally needed for their renewal.

The 11-year-old patient had fused tooth in the left maxillary anterior region, upper and lower crowding, and a dental Class I relationship. If the fused tooth had endodontic and prosthodontic treatment, for gaining the space would have been essential. After considering the esthetic importance of the anterior region and the patient’s age must be considered when deciding on any treatment option [9].

Cautious clinical and radiographic evaluations could be performed for optimum treatment management.

Conclusion

Dental anomalies, such as fusion may induce functional and esthetic problems. A multidisciplinary treatment planning, comprising orthodontics, periodontics, endodontics, and prosthodontics, could be used to reach a pleasing aesthetic and functional consequence. In this case, proper clinical and radiographic multidisciplinary examinations, a correct diagnosis, intraoral rehabilitation in conjunction with the improvement of facial esthetics and key features for a successful treatment were contributed extremely to the self-confidence of the young patient.

Acknowledgements

The authors thank, Dr. Yildirim Erdogan, Dr. Gulin Yilmaz, and Dr. Sule Bulut Burhanoglu for their priceless help with the endodontic, periodontal, and prosthetic approaches in this case.

Bibliography

1. S Turkaslan., *et al.* "Esthetic rehabilitation of bilateral geminated teeth: a case report". *European Journal of Dentistry* 1.3 (2007): 188-191.
2. Guimarães Cabral LA., *et al.* "Double teeth in primary dentition: Report of two clinical cases". *Medicina Oral Patologia Oral y Cirugia Bucal* 13.1 (2008): E77-E80.
3. Suresh KV., *et al.* "Multiple talon cusps on maxillary central incisor: A case report". *Journal of Dental Research, Dental Clinics, Dental Prospects* 11.2 (2017): 127-130.
4. Thilander B., *et al.* "Orthodontic aspects of the use of oral implants in adolescents: a 10-year follow-up study". *European Journal of Orthodontics* 23.6 (2001): 715-731.
5. Misawa M., *et al.* "The alveolar process following single-tooth extraction: a study of maxillary incisor and premolar sites in man". *Clinical Oral Implants Research* 27.7 (2016): 884-889.
6. Aguilo L., *et al.* "Primary double teeth. A retrospective clinical study of their morphological characteristics and associated anomalies". *International Journal of Paediatric Dentistry* 9.3 (1999): 175-183.
7. Blank BS., *et al.* "A fused central incisor. Periodontal considerations in comprehensive treatment". *Journal of Periodontology* 56.1 (1985): 21-24.
8. Neves AA., *et al.* "Bilateral connotation of permanent mandibular incisors: A case report". *International Journal of Paediatric Dentistry* 12.1 (2002): 61-65.
9. Vinaya Kumar Kulkarni., *et al.* "Endodontic treatment and esthetic management of a primary double tooth with direct composite using silicone buildup guide". *Contemporary Clinical Dentistry* 3.1 (2012): S92-S95.
10. Ravi Prakash Sasankoti Mohan., *et al.* "Double tooth in mandibular incisor region: a case report". *BMJ Case Reports* (2013): bcr2012008647.
11. Saxena A., *et al.* "Bilateral fusion of permanent mandibular incisors: A case report". *Journal of Indian Society of Pedodontics and Preventive Dentistry* 26.1 (2008): 32-33.

Volume 18 Issue 7 July 2019

©All rights reserved by Nur Ozel and Alev Aksoy.