

The Orthodontic Patient: Examination and Diagnosis

Ramy Ishaq*

Assistant Professor of Orthodontics, University of Science and Technology, Sanaa, Yemen

***Corresponding Author:** Ramy Ishaq, Assistant Professor of Orthodontics, University of Science and Technology, Sanaa, Yemen.

Received: March 18, 2019; **Published:** April 26, 2019

Abstract

Successful orthodontic treatment begins with the correct diagnosis, which involves patient interview, examination and the collection of appropriate records. A systematic and organized approach to diagnosis ensures that the clinician would not over-ride any of the diagnostic items that include patient questionnaire/interview, clinical examination that includes an extra-oral and intra-oral parts. In this article, diagnostic process is presented with all the features that have direct impact on treatment planning of every specific patient. The importance of every aspect is highlighted. At the end of this process, the orthodontist should have a comprehensive database for each patient. From this database, from which the problem list, treatment objectives are created. The appropriate treatment plan can then be formulated accordingly.

Keywords: *Orthodontic Diagnosis; Extra-Oral; Intra-Oral*

Introduction

Orthodontic diagnosis deals with the recognition of what is identified as malocclusion. It involves the collection of patient data in a systemic manner to help in identify the nature and cause of the problem [1].

Successful orthodontic treatment begins with the correct diagnosis. Diagnosis includes patient interview, examination and the collection of appropriate records. At the end of this process, the orthodontist should have a comprehensive database for each patient. From this database, a problem list is created which is converted into treatment objectives. The appropriate treatment plan can then be formulated based on the treatment objectives [2].

Patient questionnaire/interview

Case history involves eliciting and recording relevant information form the patient and parent to aid in overall diagnosis of the case. This part includes:

- A. Personal details
- B. History of chief complaint
- C. Medical history
- D. Dental history
- E. Family history
- F. Habits history
- G. Temporomandibular joint problems
- H. Oral hygiene level

Personal details

Name, age, sex address and occupation are recorded in the patient's file. Personal details are necessary for identification and communication with the patient. The age is essential in the file. The date of birth is more preferred. The gender of the patient is also required as treatment planning is influenced by the gender of the patient. In addition, growth in male and females have different timelines and that influences treatment decision making [3].

Chief complaint

The chief complaint of the patient should be recorded in his or her own words. This helps the clinician identify the priorities and desires of the patient. Most patients seek orthodontic care for reasons which may aesthetic or functional impairment [4].

When patients inquire about whether they need orthodontic treatment, a series of leading questions should be asked, beginning with, "Do you think you need braces?" If the answer is yes, one might next inquire "What bothers you more about your teeth, your bite or your appearance?" and "What do you want treatment to do for you?" The answer to that and follow-up questions will clarify what is most important to the patient. The dentist or orthodontist may or may not agree with the patient's assessment; that judgment comes later. At this stage, the objective is to find out what is important to the patient [5].

Patient interaction in planning

Treatment planning is an interactive process. No longer can the doctor decide, in a paternalistic way, what is best for a patient. Both ethically and practically, patients must be involved in the decision-making process. Ethically, patients have the right to control what happens to them in treatment. It is something done for them, not to them [5].

It can also be the case that the patient has no concern regarding their dentition, and it is the parent or dentist who has requested the consultation. In this case, acceptance of orthodontic treatment more difficult to obtain [6].

Four factors are considered important for the success or failure of orthodontic treatment:

- (1) **Motivation:** The patient must be interested to correct the malocclusion and aware of the problem related to their appearance.
- (2) **Mobility:** Teeth may have progressive mobility and continuous migrations.
- (3) **Limitations:** Health of the oral tissues must be good and at least three quarters of the teeth's roots should be surrounded by alveolar bone, and no evident root resorption.
- (4) **Cooperation:** The patient should follow the guidelines for appliance care and oral hygiene with removable and fixed appliances. He should also commit to appointment keeping during treatment [7].

It is important to consider the type of complaint of the patient and whether its correction falls within the scope of orthodontic treatment. For example, a patient with a gummy smile might seek orthodontic care to enhance aesthetics. It must here be noted that the correction of the problem might require the interaction of orthodontic treatment with other disciplines that include orthognathic surgery.

Medical history

All medical conditions should be accurately understood before any treatment is planned and this may involve seeking guidance from the patient's physician.

Patients should be well informed of all the options and made aware that any orthodontic treatment has been planned with their best interests at heart. It should be highlighted they are not being penalized for their medical condition. The importance of excellent oral hygiene should be emphasized to all patients considering a course of orthodontics [8].

Orthodontic treatment is an elective procedure and clinicians should consider all the treatment options to ensure a satisfactory risk-benefit ratio for each patient. Comprehensive treatment may not always benefit the patient. Treatment should where appropriate be postponed until the medical problem is in remission or the side effects of the drug therapy are minimized [8].

Some medical conditions are known to have an interaction with orthodontic treatment. It is important that the dental practitioner is aware of the medical conditions that have manifestations in the oral cavity as well as conditions that may have an impact on orthodontic treatment.

Medications that are prescribed for patients may also have an influence on the oral, gingival and periodontal health and an interaction with orthodontic tooth movement.

Awareness should also be amended by updated information from appropriate resources. Please refer to the reading list at the end of this chapter that may serve as a reference for the interaction of medical disorders and medications with orthodontic treatment.

The medical history of the orthodontic is taken once at the beginning of treatment and should be regularly updated every 3 months. This is because orthodontic treatment extends for an average of 18 - 36 months. Changes in the medical condition or medication uptake may arise during this time [8].

Dental history

The dental history helps in assessing the patients and parents' attitude towards dental health. It also reveals the nature of previous exposure and attitude of the patient towards dentistry [9].

Patients being considered for orthodontic treatment should be in good dental health and under the care of a general dental practitioner (GDP) [10]. The orthodontist and GDP need to work as a team in:

- Achieving a high standard of oral hygiene to make possible the acceptance to orthodontic treatment.
- Treating any dental pathology, orthodontic treatment cannot be carried out in the presence of active dental disease.
- Extracting teeth as part of orthodontic treatment plan.
- coordinating any restorative work that may be required, before or after orthodontic treatment (particularly in cases of tooth agenesis or trauma).
- Assessing the occlusal impact of early tooth loss due to caries or trauma.

Family history

This part of the history is concerned with conditions that may have an inherited pattern. Examples of such cases include:

- In a patient with Class III malocclusion, it would be useful to inquire about the facial pattern of relatives in the family to confirm the skeletal nature of the problem and to predict the severity and prognosis of the treatment [11].
- Class II Division 2 malocclusion tends to run in families indicating a genetic contribution to this malocclusion.
- Palatally impacted canines are another example of genetic aetiology. In a patient with delayed eruption of the canines a family history of impactions may be a primary indication of impaction prior to radiographic examination [12].
- Congenitally missing teeth have also a pattern of inheritance especially missing upper lateral incisors [13].

Habits history

Habits are known to be an etiological factor in malocclusion [14]. The presence of a habit may also predispose to higher risk of root resorption during orthodontic treatment [15]. Information regarding the presence of any habits must be included the history questionnaire.

Temporomandibular joint problems

The patient may be asked about the history of any joint problems. A patient reporting a history of pain, sounds or limitation may be indicative of tendency to develop Temporomandibular Disorders (TMD) [16]. It may be required that TMD problems are managed before the start of orthodontic treatment.

Oral hygiene

The patient should be asked about the level of awareness of oral hygiene practice. Questions may be placed in the questionnaire or asked directly to the patient include:

- How often do you brush your teeth?
- Do your gums bleed when you brush your teeth?
- What type of tooth brush do you use?

Based on the answers provided, it may be required to further motivate the patient in preparation for orthodontic treatment.

Clinical examination

The clinical examination includes extra oral and intra oral examination.

Extra-oral examination

The key to the extra-oral assessment is to recognize the normal proportions of the face to differentiate between normal and abnormal facial pattern.

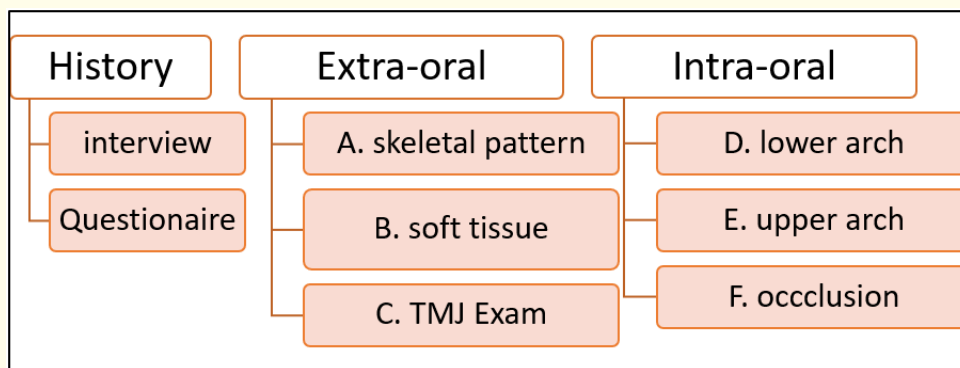


Figure 1: Flowchart showing the main items in the process of diagnosis.

The patient must be properly seated during examination such that his head is in the natural head posture (NHP). NHP is the position that the patient naturally carries their head and is therefore the most relevant for assessing skeletal relationships and facial deformity. It is determined physiologically rather than anatomically and varies between individuals.

How is the patient instructed to maintain the head at the NHP?

The patient is asked to:

- Sit upright
- Keep the muscles of the neck relaxed.
- Look straight ahead to a point at eye level in the middle distance. This can be a point on the wall in front of them, or a mirror so that they look into their own eyes.

Ideally NHP should also be used when taking a lateral skull radiograph, allowing the clinical examination to be related more accurately to the cephalometric data.

Skeletal pattern

The skeletal pattern is relative position of the maxilla and mandible. It should be assessed in three dimensions:

- Anterior posterior (A-P)
- Vertical (V)
- Transverse (T).

AP skeletal pattern

The AP relationship include assessment of relationships of the:

- Maxilla to the cranial base
- Mandible to the cranial base
- Maxilla and mandible to each other.

Assessment of the facial profile is based on connecting 3 points on the soft tissue profile (Figure 2). These are:

- **Nasion:** The point where the nasal bones and frontal bone join.
- **Point A:** The highest point on the upper lip where it meets the base of the nose.
- **Pogonion:** Most anterior point on the chin.

As seen in figure 2, these points are connected and depending upon their alignment the profile can be:

- **Slightly convex (class I) profile:** Normally, the maxilla is ahead of mandible by about 2 - 3 mm. the profile is slightly convex.
- **Convex (class II) profile:** Point A is ahead or the pogonion point is placed behind, then the profile said to be convex.
- **Concave (class III) profile:** If the A point is placed behind or the pogonion is placed forward, the profile is said to be concave.

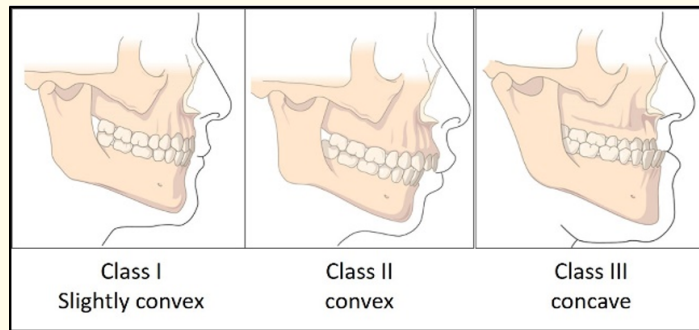


Figure 2: Class I, II and III profile.

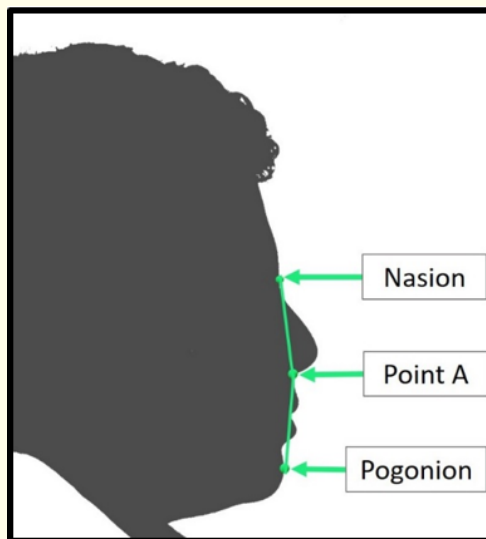


Figure 3: Facial profile 3 soft tissue points required for profile assessment.

Clinical significance

It has a large influence on the relationship of the maxillary and mandibular dentition. Helps in diagnosing gross deviations in the maxillo-mandibular relationship.

Vertical skeletal pattern

The vertical skeletal pattern is evaluated by the lower anterior face height and the mandibular plane inclination.

Lower anterior face height (LAFH)

The LAFH is evaluated in the frontal view. The face can be grossly divided into 3 equal thirds. The LAFH extends from the base of the nose to the lower border of the chin. The LAFH can be further subdivided into an upper third for the upper lip and the lower 2/3rds for the lower lip and chin as seen in the figure below.

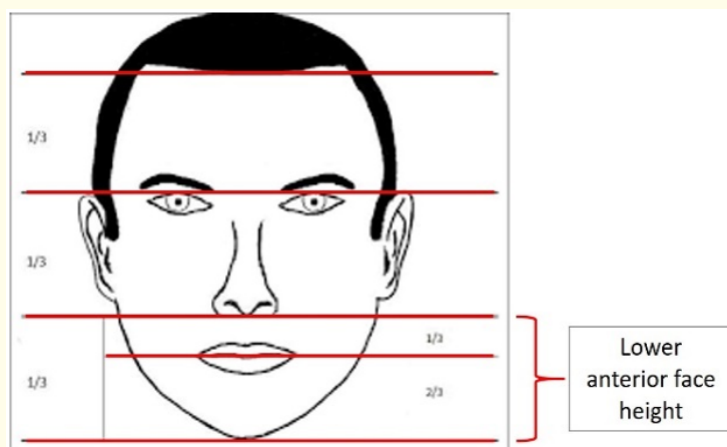


Figure 4: Facial thirds in frontal view.

The LAFH may be

- **Normal:** The facial 1/3rds are equal.
- **Long LAFH:** The LAFH is increased compared to the upper and middle 1/3rds.
- **Short:** The LAFH is decreased compared to the upper and middle 1/3rds.

Inclination of lower border of mandible or mandibular plane angle (MPA)

The MPA is assessed in the profile view. It is evaluated by drawing an imaginary line along the lower border of the body of the mandible. The MPA may be

- **Normal:** This is when the inclination is balanced. It is estimated to be normal if an imaginary line along the lower border intersects with a true horizontal in the occipital region (Figure 5).
- **Flat:** The lower border is flatter and it relatively parallel to the true horizontal.
- **Steep:** The lower border inclined steeply, and it intersects the true horizontal more anteriorly.

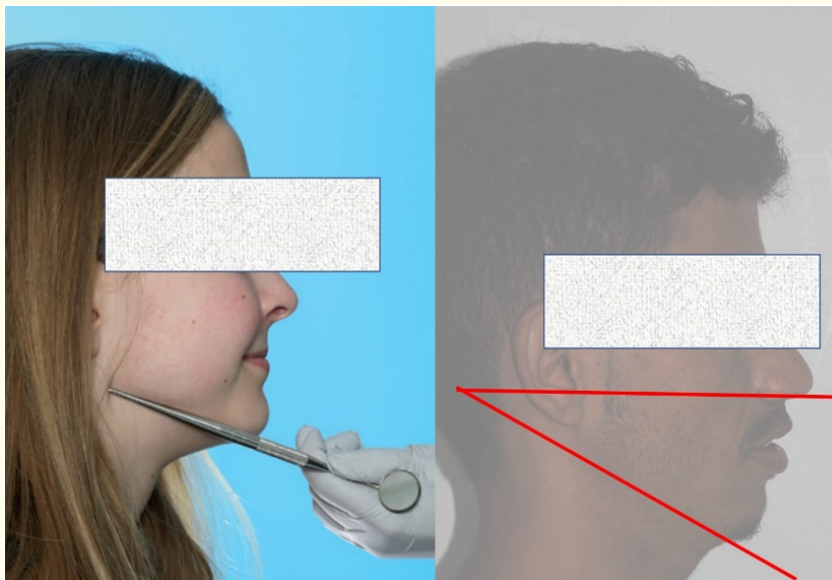

Figure 5: Normal mandibular plane inclination. The line of the plane intersects a true horizontal line behind the ear. The MPA can be visualized clinically by placing a mirror handle or another instrument along the border of the mandible. For this patient, the mandibular plane angle is normal.

Clinical significance

Short anterior facial height may be associated with deep overbites and long anterior face heights with open bites are difficult to correct with orthodontics alone. The inclination of the MPA is a result of the result of rotation of the mandible during growth. If the rotation is greater or lesser than average it results in unbalanced vertical facial proportions. The greater the skeletal difference the more likely it is that the patient will need a combination of orthodontics and orthognathic surgery to correct the occlusion and the underlying skeletal discrepancy. The contribution of skeletal growth to the malocclusion makes treatment more difficult and complex.

Transverse skeletal pattern

The transverse skeletal pattern is examined in the frontal view. The following are observed

- Facial symmetry
- Alignment of dental midline with facial midline.

Facial symmetry

The transverse proportions of the face should divide approximately into fifths (Figure 6). No face is truly symmetrical; however, any significant facial asymmetry and the level at which it occurs should be noted. The face should be normally symmetric if divided into equal halves by the facial midline. This midline is the presence of asymmetry requires further investigation. It is important to differentiate between true and false asymmetry. True asymmetry is caused by asymmetrical growth of the mandible leading to chin deviation to one side. False asymmetry is caused by functional shift caused by relative constriction of the upper arch and shifting of the mandible to one to establish proper intercuspation on one side and a cross-bite on the other side.



Figure 6: The face is divided into five equal parts.

Alignment of dental midline with facial midline

The upper dental midline should be evaluated in the extra oral examination and any deviation from the facial midline should be noted and included into the problem list.

Soft tissue

The soft tissue examination includes assessment of

- Naso labial angle
- Upper lip
- Lower lip
- Upper-lower lip relationship
- Mento-labial sulcus
- Chin button

Nasolabial angle

The nasolabial angle (NLA) is the angle between 2 lines one tangent to the upper lip and the other to the base of the nose. Normally the angle is between 90 - 120°.

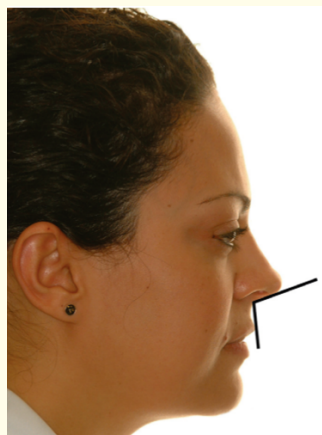

Figure 7: Normal Nasolabial angle.

Increased NLA is indicative of upper lip retrusion or nasal tip elevation termed upturned nose. This should be noted in the patient's problem list as it influences the treatment planning process.

Decreased NLA may be caused by a downturned nose or upper lip protrusion and should also be noted in the patient's problem list.

Upper lip

The upper lip is part of the soft tissue which requires special attention and falls within the scope of orthodontic treatment goals.

Normally the upper lip is

- Vertically covering the upper labial segment
- Antero-posteriorly in line with a true vertical line dropped from point Nasion.

Abnormal criteria of the upper lip include:

- Short upper lip. A short upper lip is anatomically different from a vertically normal one. The incisor display at rest may be increased.
- Protruded lip may be caused by protruded maxillary teeth.
- Retruded lip may be caused by retruded maxilla or retruded maxillary teeth.

Lower lip

The lower lip is normal when it is

- Anteroposteriorly behind the lower lip by 2 - 3 mm.
- Vertically covering the incisal 1/3rd of the upper incisors.

Abnormal lower lip is

- **Protruded:** A protruded lower lip is an indication of skeletal imbalance due to protruded mandible or caused by protruded lower incisors
- **Retruded:** A retruded lower lip is an indication of skeletal imbalance caused by mandibular retrognathia (Class II skeletal relationship). If the lower lip is markedly retruded it may be positioned behind the upper incisors and termed lower lip trap (Figure 8).
- **High position:** The vertical position of the lower lip may be high and may cause retroclination of the upper incisors (Class II division 2 malocclusion).

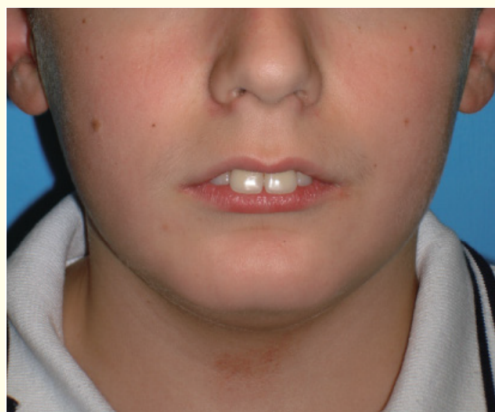

Figure 8: Lower lip trap, where the lower lip sits behind the upper incisors, can lead to upper incisor proclination and sometimes retroclination of the lower incisors.

Upper-lower lip relationship

The lips may be described as:

- **Competent:** A lip seal is produced with minimal muscular effort when the mandible is in the rest position.
- **Potentially competent:** The upper incisors position prevents a comfortable lip seal from being obtained.
- **Incompetent:** Excessive muscular activity is required to produce a lip seal. Signs of excessive activity include puckering of the skin overlying the chin, due to mentalis contraction, and flattening of the mento-labial sulcus when the lips are held together. If the interlabial gap at rest is > 4 mm the lips are considered incompetent.

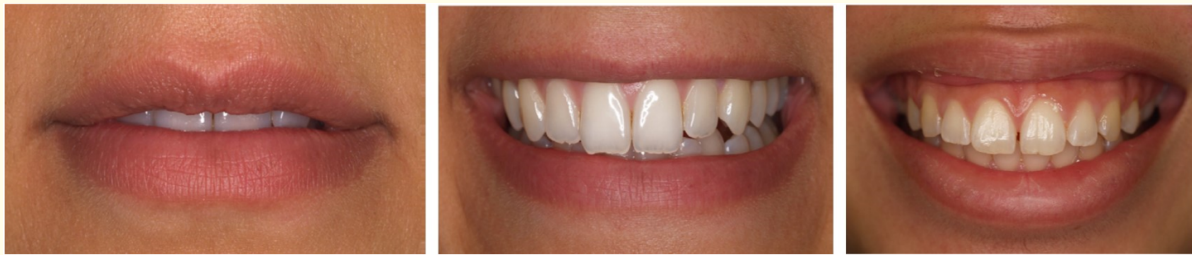

Figure 9: Normal upper incisor shown at rest (left) and on smiling (middle). Increased upper incisor shown on smiling (right).

Mento-labial sulcus

The mento-labial sulcus (MLS) is the area between the lower lip and the chin. Normally it is gently curved. Abnormal MLS is described as either

- **Deep:** Caused by an everted lower lip and commonly seen in class II malocclusion.
- **Flat:** Caused by excessive muscular activity to achieve lip competence or due to prognathic mandible in class III malocclusion.

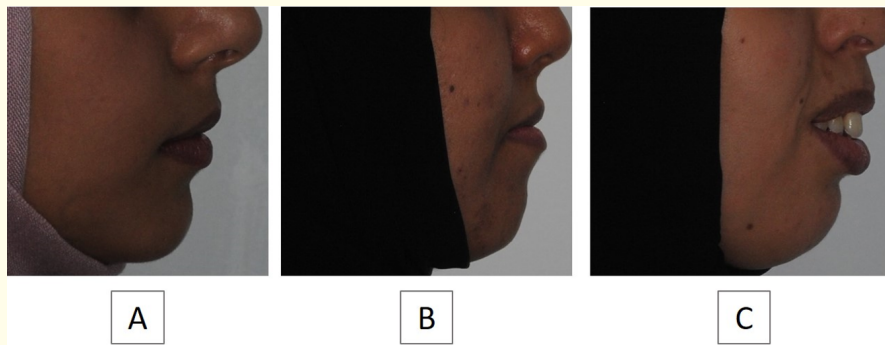


Figure 10: Mentolabial sulcus A: normal B: flat C: Deep.

Chin button

The chin contributes to the profile of the face. A chin may be normal, prominent and retruded.

Intra-oral examination

The intra oral examination is performed with the patient seated on the dental chair. Information may be collected directly on the chair or from intra oral photographs. The intra oral examination includes:

- Evaluation of dental health
- Detection of pathological problems
- Examination of the lower arch
- Examination of the upper arch
- Examination of the occlusion

Evaluation of dental health

Even individuals with severe malocclusions should not have active orthodontic treatment in the presence of dental disease. Orthodontic appliances accumulate plaque and if the patient has a poor diet and tooth brushing then irreversible damage can result. The oral hygiene of the patient should be assessed for compatibility with orthodontic appliances. If plaque accumulation is noted in different areas this should be noted and the patient should be provided with information that would increase the awareness and stress on the importance of maintaining a high level of OH during orthodontic treatment.

Detection of pathological problems

The presence of any pathological problems including caries and periodontal disease should be noted in the patient examination sheet. The patient should be instructed to visit the GDP for control and elimination of any current problems before orthodontic treatment is started.

Examination of the lower arch

The lower arch evaluation includes:

- **Arch form:** The arch form of the patient should be recorded as ovoid, tapered or square shaped. The original archform of the patient should be maintained except for cases with constriction of the arch.
- **Arch symmetry:** The symmetry of the arch should be noted. Symmetrical arches have the canines located at almost equidistant points from the midline of the arch. Any asymmetry should be noted and included into the problem list.
- **Labial segment:** The labial segment teeth should be checked for the presence of crowding, spacing, rotations and displacements and missing teeth. The inclination of the teeth should also be noted as normal, proclined and retroclined and any deviations from normal should be noted down for correction.
- **Canines:** The canines should be also checked for any displacements, rotations and abnormal inclinations. Presence should also be noted.
- **Buccal segment:** The premolars and molars are also examined for any deviations from normal such as presence/absence, alignment, rotations.

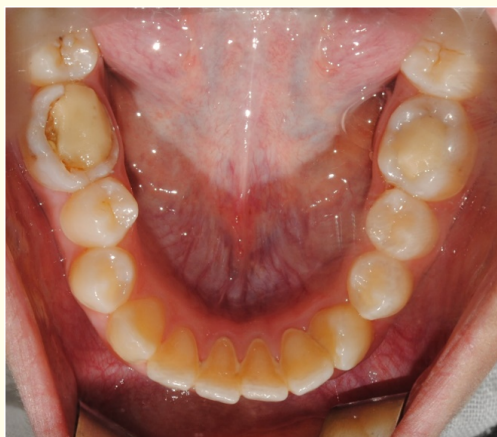

Figure 11: Mentolabial sulcus A: normal B: flat C: Deep.

Examination of the upper arch

The upper arch is examined in a similar way to the lower arch.

- **Arch form:** The arch form of the patient should be recorded as ovoid, tapered or square shaped. The original archform of the patient should be maintained except for cases with constriction of the arch. Tapered archform caused by incisors may be noted in the problem list for correction.
- **Arch symmetry:** The symmetry of the arch should be noted. Symmetrical arches have the canines located at almost equidistant points from the midline of the arch. Any asymmetry should be noted and included into the problem list.
- **Labial segment:** The labial segment teeth should be checked for the presence of crowding, spacing, rotations and displacements and missing teeth. The inclination of the teeth should also be noted as normal, proclined and retroclined and any deviations from normal should be noted down for correction.
- **Canines:** The canines should be also checked for any displacements, rotations and abnormal inclinations. Presence should also be noted.
- **Buccal segment:** The premolars and molars are also examined for any deviations from normal such as presence/absence, alignment, rotations.

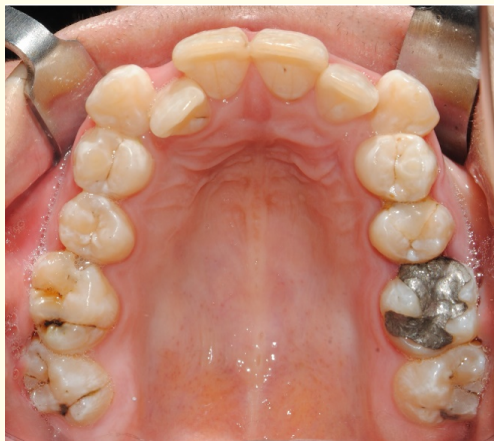

Figure 12: Intra-oral view of the upper arch. Evaluation of the labial segment, canines and buccal segment is conducted on this view.

Examination of occlusion

The upper and lower arch relationships in occlusion are assessed in three planes.

Anteroposterior

- Molar relationship of the right and left sides is noted as Class I, II or III. Achieving a Class I molar relationship is sometimes not included into the treatment objectives. More importantly, the occlusion should be planned for proper interdigitation.
- Canine relationship of the right and left sides is noted as Class I, II or III. Achieving a Class I canine relationship is vital to orthodontic correction as it is the basis of achieving a Class I incisor relationship.
- Incisor relationship is noted as Class I, II or III. The incisor relationship is more useful during orthodontic diagnosis and treatment planning.
- Overjet should be noted as normal (2 - 4 mm), decreased or increased.

Vertical

- Overbite should be noted as normal (3 - 5 mm), decreased, open bite or increased. Achieving a normal overbite is an important objective of orthodontic treatment.

Transverse

- Midline of the upper and lower arches is examined for any deviations from each other and from the facial midline.
- Transverse buccal segment relationship is noted as either normal. Presence of posterior crossbite (unilateral or bilateral) is noted for correction.

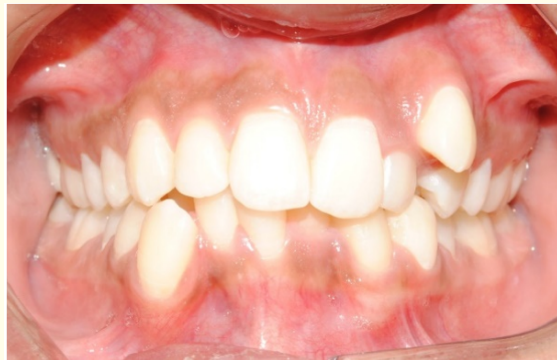

Figure 13: Intra-oral view of the occlusion Frontal view.

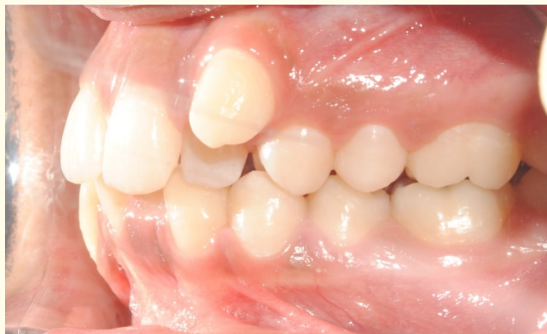

Figure 14: Intra-oral view of the occlusion. left side.

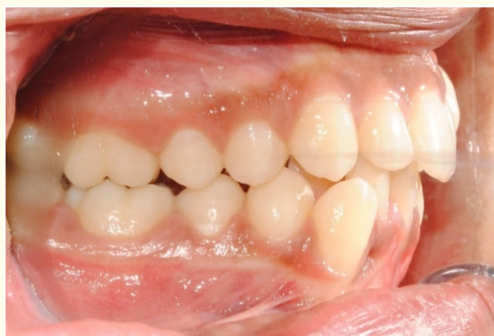

Figure 15: Intra-oral view of the occlusion. Right side.

Conclusion

The patient assessment forms the essential basis of orthodontic treatment. It is taken in steps starting from a history/questionnaire and proceeding to a clinical examination that includes extra-oral and intra-oral examination. The extra-oral examination is carried out first as this can fundamentally influence the treatment options. The skeletal pattern, soft tissue form and the presence or absence of habits must all be considered. The intra-oral assessment examines the oral health, individual tooth positions and inter-occlusal relationships. When this has been completed in conjunction with the extra-oral examination, a treatment plan can then be formulated [17].

Bibliography

1. Littlewood SJ. "Introduction to orthodontic assessment". In: *An Introduction to Orthodontics Fourth Edition*. Oxford University Press (2013): 54.
2. Cobourne MT and DiBiase AT. "Handbook of Orthodontics". Edinburgh: Mosby/Elsevier (2009).
3. Tapasya Juneja GS. "Case History". In: *Textbook of Orthodontics Second Edi*. Jitendar P Vij (2007): 66-68.
4. Bhalajhi SI., *et al.* "Orthodontics: The art and science". Sixth edition. Arya (Medi) Publication (2015).
5. William R Proffit., *et al.* "Patient Interaction in Planning". In: *Contemporary Orthodontics Elsevier Ltd* (2019): 138.
6. Cobourne MT and DiBiase A. "Patient's complaint and motivation". In: *Handbook of Orthodontics Second Edi*. Elsevier Inc (2016): 163.
7. de Souza RA., *et al.* "Expectations of orthodontic treatment in adults: the conduct in orthodontist/patient relationship". *Dental Press Journal of Orthodontics* 18.2 (2013): 88-94.
8. Patel A., *et al.* "Medical disorders and orthodontics". *Journal of Orthodontics* 36.1 (2009): 1-21.
9. Singh G. "Textbook of Orthodontics". Second edition. (Singh G, ed.). Unipress Publishing (2007).
10. Cobourne MT and DiBiase A. "Dental History". In: Elsevier Ltd, ed. *Handbook of Orthodontics Second Edition*. Elsevier Ltd (2016): 163.
11. Gurkeerat Singh. "Family history". In: *Textbook of Orthodontics Second Edition* (2007): 67.
12. Peck S., *et al.* "The palatally displaced canine as a dental anomaly of genetic origin". *Angle Orthodontist* 64.4 (1994): 249-256.
13. Cobourne MT. "Familial human hypodontia-is it all in the genes?" *British Dental Journal* 203.4 (2007): 203-208.
14. Góis EGO., *et al.* "Influence of nonnutritive sucking habits, breathing pattern and adenoid size on the development of malocclusion". *Angle Orthodontist* 78.4 (2008): 647-654.
15. Suárez Calleja C. "Risk factors for root resorption in the orthodontic treatment" (2015).
16. Luther F., *et al.* "Orthodontics for treating temporomandibular joint (TMJ) disorders". *Cochrane Database of Systematic Reviews* 7 (2010): CD006541.
17. Roberts-Harry D and Sandy J. "Orthodontics. Part 2: Patient assessment and examination I". *British Dental Journal* 195.9 (2003): 489-493.

Volume 18 Issue 5 May 2019

©All rights reserved by Ramy Ishaq.