

## Periapical Cyst: Report of Cases

**Cabrera Edgar<sup>1\*</sup>, Rodriguez Manuel<sup>2</sup>, Villarroel Mariana<sup>3</sup>, Sabater Alejandra<sup>4</sup>, Chacón Liseth<sup>5</sup> and Salazar Valentina<sup>6</sup>**

<sup>1</sup>Specialist in Oral and Maxillofacial Surgery, Practice of Exclusive Dedication to Maxillofacial Surgery and Oral Implantology, Venezuela-Spain

<sup>2</sup>Specialist in Endodontics, Practice of Exclusive Dedication to Endodontic Microscopy, Venezuela-Spain

<sup>3</sup>Specialist in Pathological Anatomy and Chief of the Postgraduate Course, Universidad Central de Venezuela, Caracas, Venezuela

<sup>4</sup>Fifth Year Student of Dentistry at Santa Maria University, Assistant Team Maxillofacial Surgery Dr. Cabrera, Caracas-Venezuela

<sup>5</sup>Resident of First Year of Postgraduate Course in Maxillofacial Surgery of General Hospital of the East Domingo Luciani, Caracas-Venezuela

<sup>6</sup>Specialist in Dental Prosthesis, Practice of Exclusive Dedication to Oral Rehabilitation, Caracas, Venezuela

**\*Corresponding Author:** Edgar Cabrera, Specialist in Oral and Maxillofacial Surgery, Practice of Exclusive Dedication to Maxillofacial Surgery and Oral Implantology, Venezuela-Spain.

**Received:** November 13, 2018 **Published:** February 25, 2019

### Abstract

There is a persistent controversy in our specialized dental practice as to how to treat patients that have been diagnosed with periapical lesions, specifically in timing between the different specialties (Endodontics, Periodontics, Oral and Maxillofacial Surgery, Oral Pathology). The tri-dimensional image review is an indisputable tool to establish the therapy routine, the point of discussion lies in which procedure we should follow if we do not refer back the periapical image on time, if the symptoms persists after finishing the endodontic treatment, the reappearance of fistulas, the best way to treat these lesions from a surgical point of view, giving comfort to the endodontist and avoiding a periodontal sequel, the right management of the cavities (sequels resulting on the enucleation and bone curettage), the use of GBR combine with A-PRF (Choukroun advance PRF) [platelet-rich fibrin] and what type of biomaterial we should use or if we could solve it in one surgical time. Generally, the endodontic-surgery interaction has presented itself as a challenge in these patients, doing interdisciplinary treatment approaches specifically in each area to solve it. Knowing that the surgical treatment in teeth with periapical pathology tries to achieve the best possible access to the bone injury to remove a little part of the root's apex. We have to have a clear intraoperative vision of the eliminated portion to localize the root canal and prepare the cavity to seal it. The periapical granulomatous tissue has to be examined to get a histopathological diagnosis.

The diagnostic method has been defined and the efficacy of the digital tri-dimensional review has been proved, but have we analyzed what the evolution dynamic of these lesions to cysts is? Or should we settle with knowing that the periapical cysts are lesions that might appear from an apical granuloma of a necrotic tooth where the Malassez's epithelial rest stimulates and with time the hydrostatic pressure theory installs creating a round capsule that holds a purulent fluid which causes bone erosion and breaks the less thick bone cortical and forms a fistula in attached gingiva.

**Keywords:** Oral Rehabilitation; Cyst; Periapical; PRF (Platelet Rich Fibrin); MTA (Mineral Trioxide Aggregate); GBR (Guided Bone Regeneration)

### Introduction

The periapical lesions are the consequence of a necrotic pulp that at the same time are the result of an extensive not treated cavity. They are the most frequently found pathology on the alveolar bone and it affects soft and hard tissue. The cysts are pathological cavities with liquid, semiliquid, solid or gaseous content that are covered with epithelium on the inside and connective tissue on the outside.

The periapical cyst is an inflammatory cyst that comes from the epithelial rest of the periodontal ligament. It develops from an existent apical granuloma that begins, establishes and maintains by the products of decomposing necrotic pulp tissue. Various authors have established that approximately half of the periapical lesions are radicular cysts, around 15% of the periapical lesions are cystic and 9% of them are real cysts that decreases the probability of solving them with conventional endodontic treatment. The periapical cyst is known as a cystic lesion of inflammatory origin, they are the most frequent dental cysts with 70 - 75% of the cases and appear between the 3<sup>rd</sup> and 4<sup>th</sup> decade of life, directly related with alveolar and dental traumatism and not treated cavities. They lean to appear in women more than men and specifically in the anterior region of the maxilla [1].

The presence of epithelium clothing the cavity that develops on the inside of the maxilla is fundamental for its constitution, its origin may result from rests of dental lamina, enamel reduced epithelium or the Malassez rests [2]. There are two popular theories on the formation [3]: one the nutritional deficiency (practically discarded) and one of the abscess. This theory propose that when the abscessed cavity is formed in the connective tissue the epithelial cells proliferate and cover the pre-existent cavity because of their tendency of covering the exposed surface with connective tissue so the rest of the epithelial cells go back into growth phase by stimulation from the cytokines and the growth factor in the inflammatory environment. Every one of this epithelial cell proliferate to create epithelial cells chains polarizing with strange rests creating the cysts. Once the cyst is constituted, its growth depends on the activity of its components, hydrostatic pressure gradient, and the biochemical action of substances that contribute to the bone resorption. The cystic components that creates the most pressure are glycosaminoglycans from the connective tissue and the epithelium (hyaluronic acid, chondroitin sulfate and heparan sulfate) and the ones that causes bone resorption are the prostaglandins, interleukins and the arachidonic acid metabolism mediated by the cyclooxygenase as the leukotrienes [4-6].

As to the clinical periods that most of patients go through there are mainly 3 stages [2]:

- o **Latency or latent period:** patient experience discomfort or soft pain that stops with NSAIDs medication and clinically it manifests with pain to vertical percussion.
- o **Exteriorization:** there is evidence of vestibular edema that might show abnormality or facial asymmetry, with growth of the cortical bone that crackles. It comes along with moderate to severe pain.
- o **Fistula:** the pain, signs and symptoms mentioned on the previous period exacerbate and conclude with the appearance of a fistula that comes from the growth of the vestibular cortical that breaks the mucous membrane.

### Objectives of the Study

- o Report the interdisciplinary management of three surgical cases histopathologically diagnosed as periapical cysts in different stages of evolution.
- o Describe the selected techniques with their different timings by specialty in each case according to the establishment of the therapeutical routine.
- o Detail the selection plan of the surgical approaches and the treatment plan to get a functional rehabilitation.

### Patients and Methods

#### Descriptive field research. Report of 3 Clinical Cases

52 years old male comes to consult presenting acute pain in upper left side maxilla with intermittent periods of evolution where he was self-medicated with antibiotics. Intraoral examination: there is a vestibular fistula in the upper maxilla with a soft consistency lump 3 x 3 x 2 cm, depressible, painful when touched located in hard palate. On the tri-dimensional image a big sized apical image is seen invading anatomic structures (nostril and palatine vault). Immediately an emergency treatment was made, proceeding to puncture, extraction of 1.1 dental unit, surgical drainage and antibiotic therapy. After 6 weeks in a second surgical procedure we continue to endodontically retreat dental units 1.2 to 1.3 and in the operating room under intravenous sedation we performed through a Keen's type approach on the vestibular furrow a peri-radicular surgery, apical one-third preparation and sealing with MTA. We enucleated the lesion including all the granulomatous tissue that was communicated with the ipsilateral nostril, peripheral bone curettage and sent sample for pathological

study. At the same time we decided to do a GBR (lyophilized bone graft DFDBA+ retromolar trigone autologous) combined with Choukroun's APRF-IPRF protocol to regenerate the bone defect, close the oro-nasal communication and implant installation. The bimaxillary implant-supported rehabilitation was concluded after 4 months. The patient shows no symptoms and comes to post-surgical evaluation 3 years after the surgical procedure and is evaluated clinically and with tri-dimensional images showing a good healing process and tissue stability.

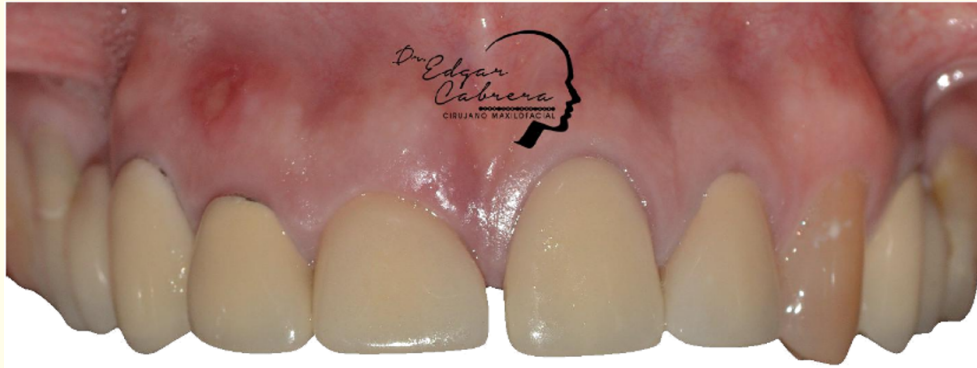

Figure 1: Initial registration.

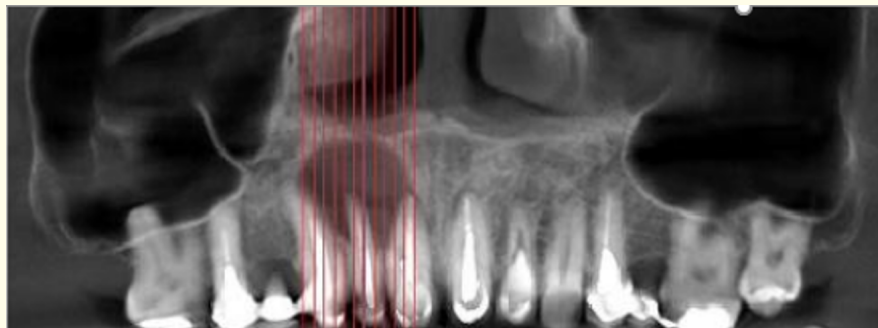
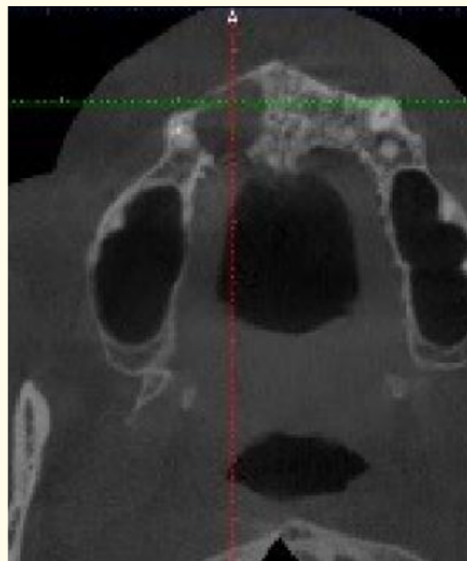


Figure 2 and 3 : Initial registration.

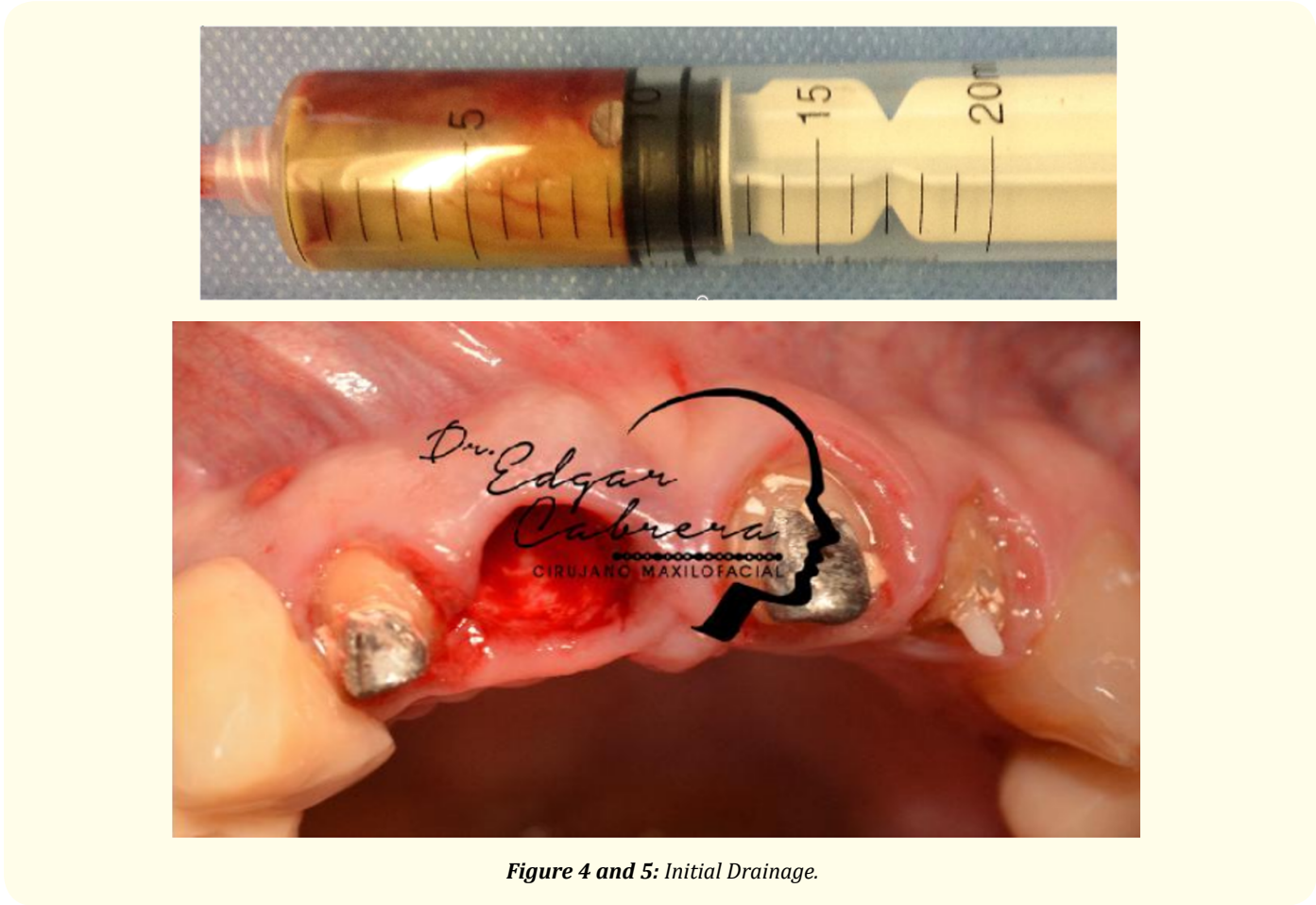

Figure 4 and 5: Initial Drainage.

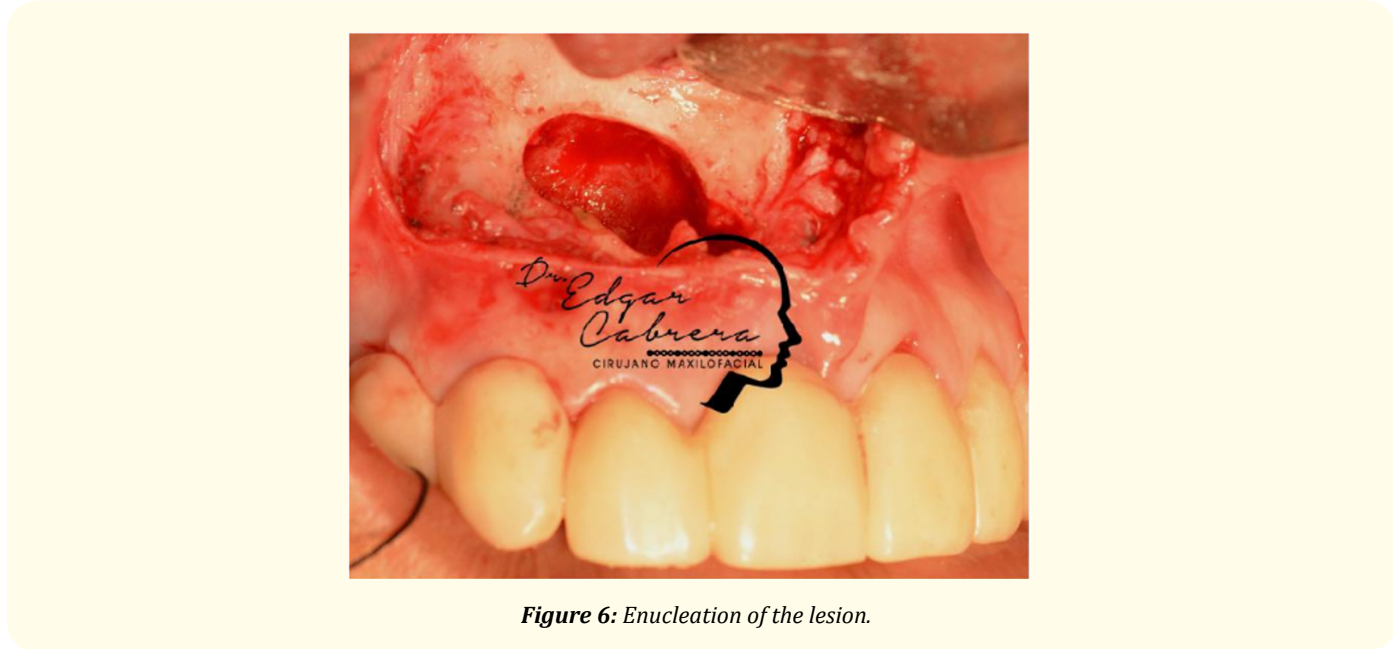
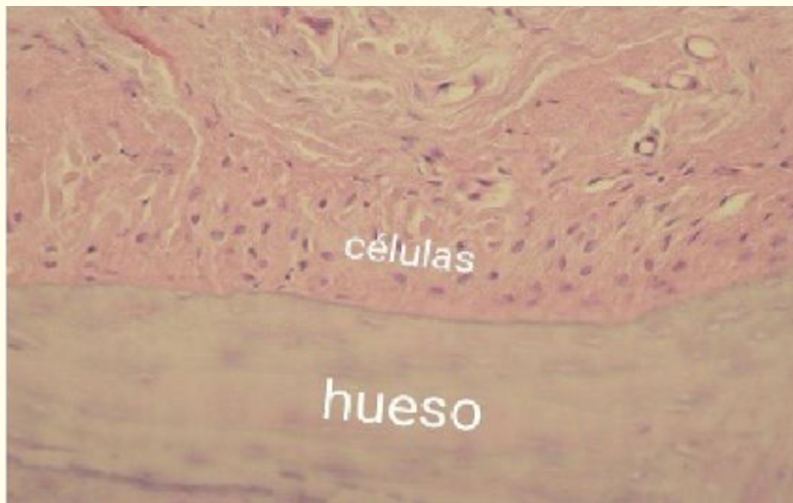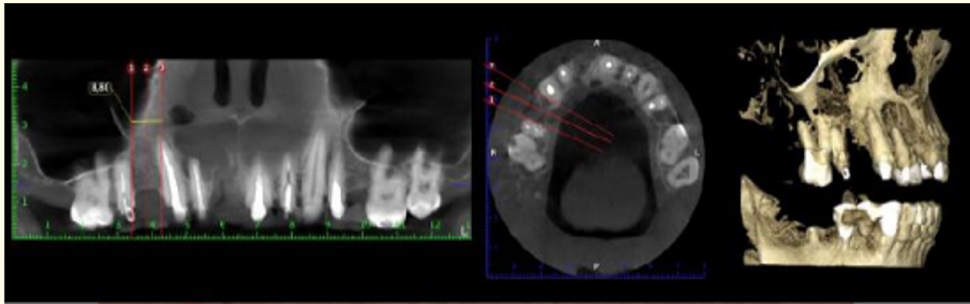

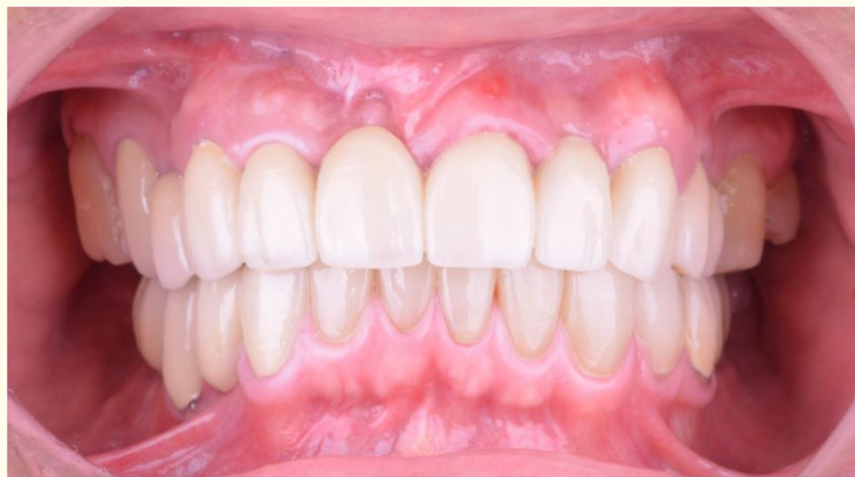
Figure 6: Enucleation of the lesion.





**Figure 7 and 8:** Tomography Cone Beam Control. Microphotography of anatomopathology study.



**Figure 9:** Final record. Implant-supported rehabilitation.

24 years old male comes to consult with clinical crown loss in various teeth, active fistulas with purulent content. In the image evaluation we see: multiple root fragments of 23 - 24 dental units with associated big sized apical images invading vital anatomical structures (maxillary sinus). Intraoral examination: we see a left side upper maxilla vestibular fistula with active drainage of green-yellow purulent content joined by a soft tissue lump 2 x 2 x 3 cm soft consistency, depressible and painful when touched located at the alveolar crest 24 dental unit. Endodontic treatments with microscope were made in 22 and 25, surgical drainage, puncture and antibiotic therapy. Under sedation and local anesthesia: we planned of doing surgical extractions of 23 - 24 dental units with lesion's enucleation + pathological study through a intrasulcar approach with distal papilla preservation and double incision, we made a variation of the bone curettage surgical technique because we decided to use a 5 mm drill to get more precision and to totally include every part of the lesion, then we put 6 6 A-PRF clots to get better healing process of the bone defect. The patient has not shown any symptoms and he comes to post-surgical evaluation.

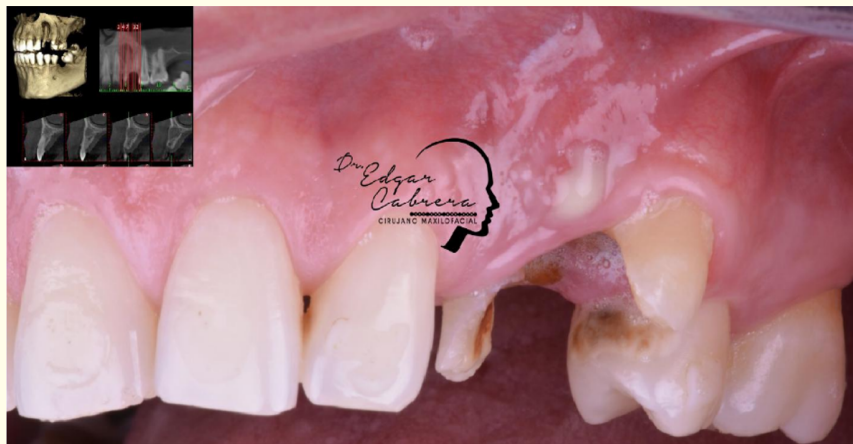

Figure 10: Initial registration.

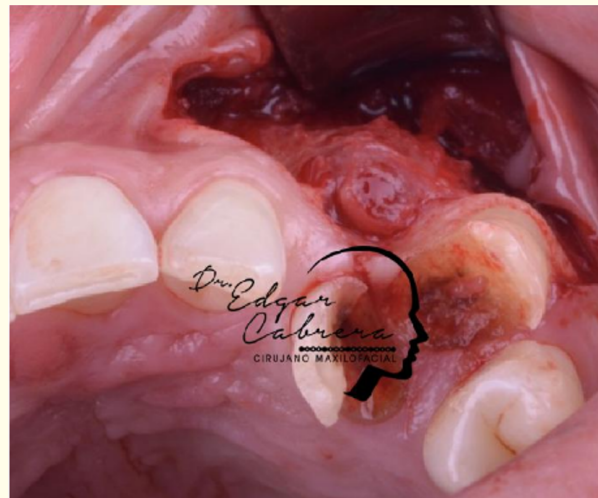
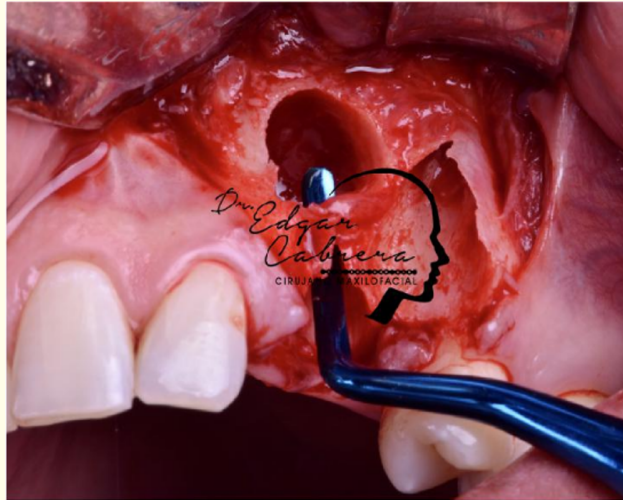
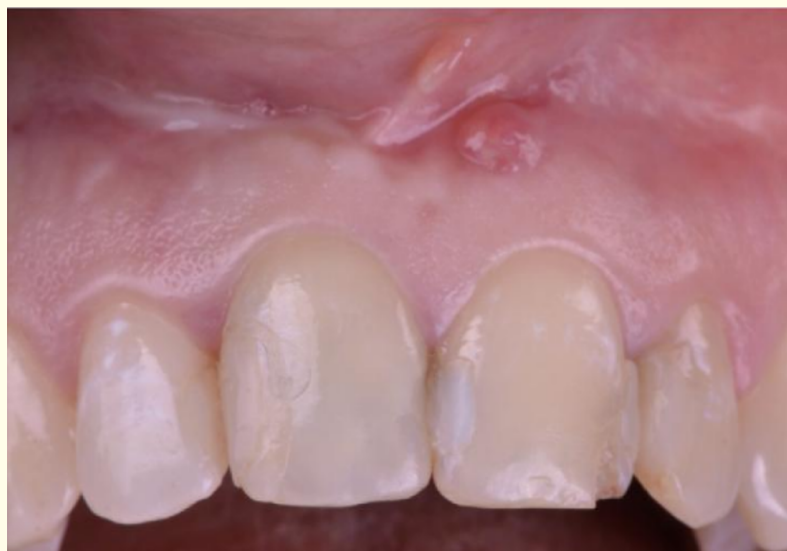

Figure 11: Intraoperative occlusal view.

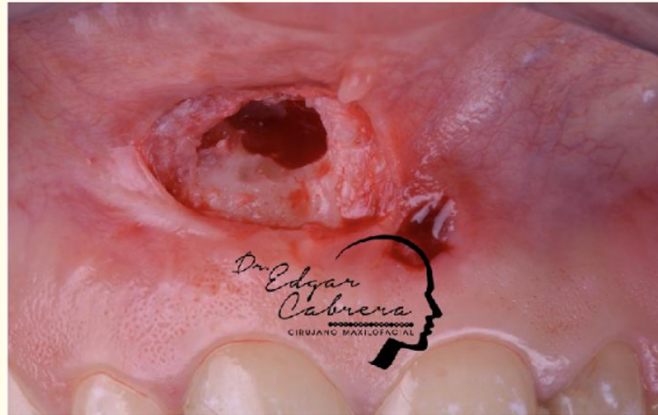


**Figure 12:** Approach Modification Surgical technique.

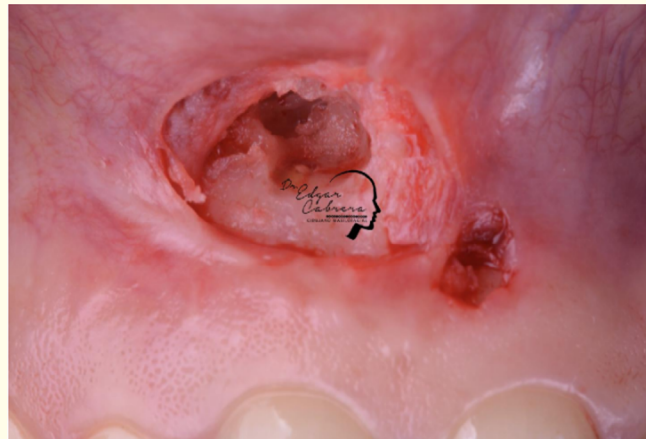
27 years old female comes to consult with acute pain in upper maxillary and right nostril with intermittent periods of evolution where the patient was self-medicated with antibiotics. Intraoral examination: we see a vestibular fistula with a soft consistency lump 2 x 2 x 2 cm, depressible, painful when touched located at the bottom of the vestibular furrow. In the tri-dimensional study we see a big sized apical image invading anatomical structures (nostril and palatine vault). We proceed to do a fistulectomy and antibiotic therapy. In a second surgical procedure we did endodontic treatment to the 1.1 dental unit, vestibular approach through the drainage zone, apical preparation, sealing with MTA, enucleation, bone curettage of granulomatous tissue, pathological study and GBR combines with A-PRF, I-PRF.



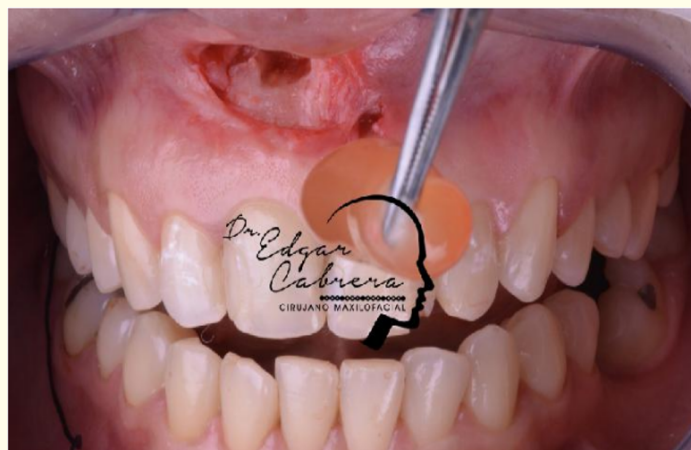**Figure 13:** Initial registration.



**Figure 14:** Approach through the initial defect.

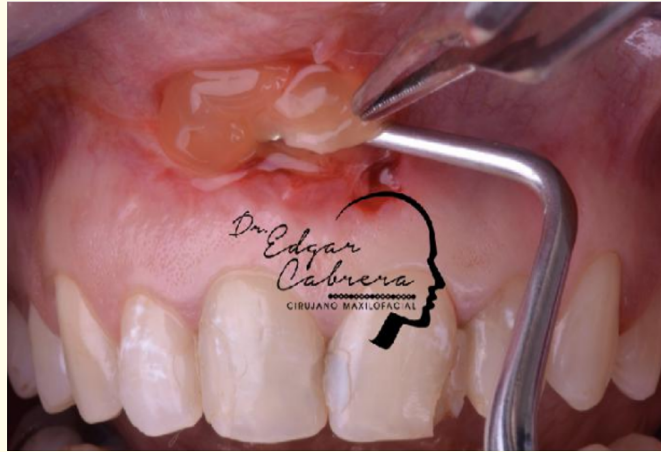

**Figure 15:** Approach Enucleation - Apical third location.

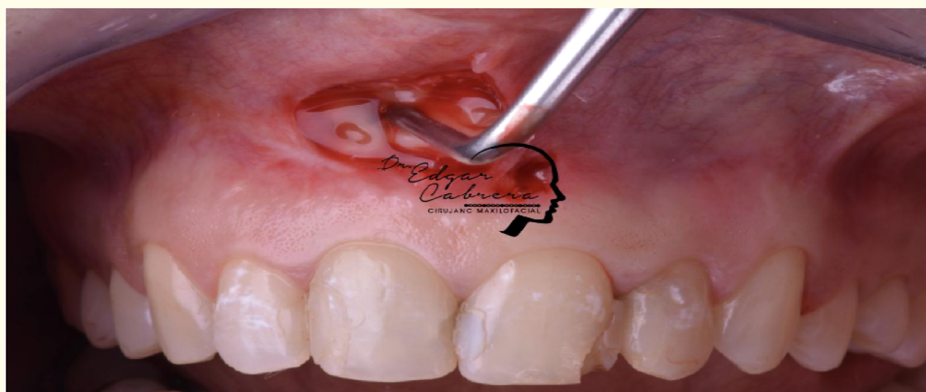

**Figure 16:** Management of the APRF towards the surgical bed.

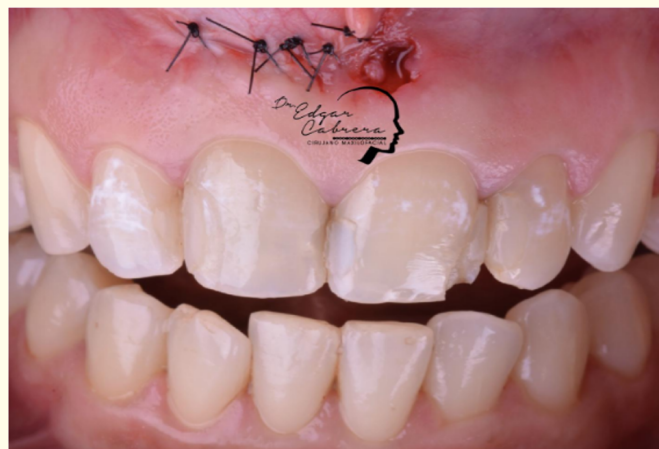



**Figure 17:** Positioning of the APRF clot in the surgical bed.



**Figure 18:** Stabilization of the APRF clot in the surgical bed.



**Figure 19:** Suture and permeabilization route.

## Results

After 8 weeks on the evaluation CT we see a bone density increase indicating a good prognosis in the regeneration (try to achieve a complete restitution of every tissue and anatomic structures that were affected) allowing to begin the implant rehabilitation phase. It is very important to prove and deeply analyze the pathological studies that through the definite diagnosis on three of our cases. Periapical Cyst. This histopathological studies revealed cystic lesions outlined by odontogenic epithelium stratified squamous non-keratinised. The epithelium has variable thickness and it is completely lost in some areas leaving the connective tissue exposed. Underneath the epithelium we can see the conjunctive wall formed by collagen fibers mixed with fibroblasts and numerous blood vessels outlined by normal aspect endothelium and erythrocytes on the inside and an inflammatory lymphoplasmacytic infiltrate.

## Discussion

### Handling the root's apex

The purpose of the peri-radicular surgery is double [7]: the first one is to eliminate the etiologic factor and the second is to prevent contamination after eliminating the etiologic factor.

Frequently the etiologic factor is multifactorial even though in most of the cases there is some way of bacterial participation inside the apex third of the root canal, that is why we have to remove the root apex. This procedure guarantees the optimum environment to the injury's healing. Also we have to remember the second purpose, prevent the recurrence, so we have to seal de root apex from any irritant that might be inside the root canal system avoiding the peri-radicular tissue's contamination.

In the apex removal the main objective is to eliminate the sick tissue and in second place give enough room for evaluate and treat the apex. We have to remember that approximately 75% of teeth have root canal variations (accessory and laterals) in the apex 3 mm that is why we take that measure as reference for the removal [9]. The access and the visibility will determine the extension of the removal, however we have to make sure we protect the tooth and support structures [8]. The endodontic microscopes reduce the need of removing too much structure to get the right visualization and access [10-12].

One of the aspects we have to pay attention to when we are creating the access is the removal's level, from a biological perspective the better way to remove de apex is perpendicular to the tooth's axis because if we increase the degree we will also increase the number of dentinal tubules that communicate the peri-radicular zone and the root canal system. The more efficient drills to do it are the carbide and the ultrafine diamond. When removing the apex we can improve the root's surface by eliminating the smear layer, allowing the mechanic adhesion and cellular mechanisms for growth. Studies have shown that this happens using EDTA o citric acid, however it is not recommended to put EDTA when using MTA because it might interfere with MTA's hard tissue making effect.

As the last step before putting any sealing material we have to prepare the cavity on the root's apex because it is a crucial step to achieve the apical seal. The objective is to make a cavity on the dried apex which dimensions are enough to apply the filling material. The ideal preparation is through the tooth's longitudinal axis until a 3 mm depth. This is possible with the ultrasound tips specifically designed for this. Being the fractures the most frequent complication, decreasing the ultrasound power may reduce the risk. Also we have to realize the heat generation of this tips, that is why they should always be used with irrigation. Having the cavity we proceed to our last step which is putting the filling material. This material has to seal the inside of the root canal system avoiding the exit of bacteria and their products to the peri-radicular tissue around it. Also it has to be biocompatible and dimensionally stable through time. It has to be capable of inducing the periodontal ligament regeneration, specifically the cementogenesis. Many materials as gutta-percha, polycarboxylate cements, silver cones, amalgam, cavit, zinc phosphate cement that have been proposed. However the most studied and used are zinc oxide-eugenol ce-

ments, glass ionomer cements, synthetic composite resin, hybrid resin-ionomer and MTA. This last one is developed specifically to seal the root's apex. Last studies have shown that it is better in biocompatibility and sealing compared to other materials used. From a biological perspective of the peri-radicular tissue regeneration, MTA and retoplast seems to have advantages over the other materials. The biggest disadvantage is its complex application and manipulation. The Choukroun's platelet rich fibrin (APRF) developed in France by Choukroun (2001) is a second generation platelet concentrate widely used to accelerate the healing process in hard and soft tissue. Its advantages over the platelet rich plasma (PRF) include the easy preparation not requiring anticlotting [13]. It is a new regeneration material that contains a big amount of growth factors, leucocytes, and cytokines all in one fibrin membrane for healing and immunity [14].

At the beginning the fibrinogen concentrates in the upper part of the tube until the thrombin's effect transforms it into a fibrin net. The result is a fibrin clot that contains platelets located at the tube's half between the red cells at the bottom and the acellular plasma on top. This clot is taken out of the tube and the red cells are thrown away. The clot is placed in the PRF box and it is covered. This produces a low cost autologous fibrin membrane in approximately one minute. The liquid rets located at the bottom of the box can be used to hydrate graft's materials [13]. For the preparation to be clinically used, the blood extraction and its centrifugation have to be immediate before the clotting cascade begins.

The PRF has platelets, leucocytes, cytokines and stem cells inside of one fibrin matrix. The leucocytes may influence on the growth factors, the immune regulation, infectious activities and healing process [15-17]. It has been proved that after centrifugation 97% of platelets and 50% of leucocytes concentrates in the A-PRF. They showed the slow releasing of growth factors from platelets, transforming beta 1 growth factor, vascular endothelial growth factor and glycoproteins as fibronectin and vitronectine especially during the first 7 days. Zumstein, *et al.* [18] saw that this releasing continued for a maximum of 28 days and it can be a useful complement on the tissue repair. Because of this advantages IPRF can be used alone as the only biomaterial or combined with bone substitutes to accelerate the bone regeneration.

Recent studies have shown a new protocol to obtain PRF where the centrifugation process has been changed to improve the tissue regeneration obtaining A-PRF. The new protocol consists in centrifuging blood for a longer time and less revolutions (1300 rpm-8 minutes) this way the expression of the growth factors increases. In the oral and maxillofacial surgical field the actual tendency is to look for the biggest amount of monocytes in the fibrin matrix, because it stimulates the bone creating cells in few days.

## **Conclusion**

The most important condition managing and solving this cases is the interdisciplinary work, highlighting the input and synergy that every specialty has maintaining a "Reverse Protocol" jointed work philosophy. The longevity functional rehabilitation that maintains the aesthetic and function is the result of establishing an appropriate diagnosis, using the tri-dimensional image resources, selection and individualization of every case's surgical technique, histopathological reviews of every sample, integration of regeneration protocols at the same surgical time (avoiding healing process and fibrosis), making prosthetic and rehabilitation systems that guarantee the result's stability and the series control that patients with cystic lesions have to have. Selecting a surgical method depends on the image evaluation that limits the extension and relation of the cystic lesion with vital organs (maxilla). It is interesting from a surgical point of view the fact that we could use a minimum invasive approach like Partsch or previous scars that allow access to the cyst enucleating, making a bone curettage (manually or using surgical drills), treating the apex third through an endodontic microscope, alveolar ridge regularization and the possibility of planning bone regeneration once the pathological diagnosis is confirmed. Another of the main bibliographic controversies may be the use and management of the resulting cavity with PRF's (Choukroun's protocol) advanced regeneration protocols concluding that in the management of our cases, combined or not with bone grafts, it has given us satisfactory results as to: vital structure

(oro-sinus mucous) management, bone healing, tissue's stability, decrease of intraoperative complications and the possibility of planning esthetic-functional rehabilitation in reasonable periods of time (4 month).

## Bibliography

1. Regezzi and Sciubba. "Quistes de la boca: Patología Bucal 3<sup>rd</sup> edition". Ed. Philadelphia and P A Saunders. México, Mc Graw-Hill Interamericana (1999).
2. García-Rubio A., *et al.* "Lesiones periapicales. Diagnóstico y tratamiento". *Avances en Odontoestomatología* 31.1 (2015): 31-42.
3. George T and J Huang. "Apical Cyst Theory: a Missing Link". *Dental Hypotheses* 1.2 (2010): 76-84.
4. Huh JK., *et al.* "Progression of periapical cystic lesion after incomplete endodontic treatment". *Restorative Dentistry and Endodontics* 41.2 (2016): 137-142.
5. Lin LM., *et al.* "Proliferation of Epithelial Cell Rests, Formation of Apical Cysts, and Regression of Apical Cysts after Periapical Wound Healing". *Journal of Endodontics* 33.8 (2007): 908-916.
6. Sapp JP., *et al.* "Patología Oral y Maxilofacial Contemporánea" (1999): 20-23.
7. Casstellucci A. "Avancées technologiques en chirurgie endodontique". *Realites Cliniques* 12.1 (2001): 213.
8. Rubinstein R. "Endodontic microsurgery and the surgical operating microscope". *Compendium* 18.7 (1997): 659.
9. Mounce R. "Surgical operating microscopes in endodontics: the quantum leap". *Dentistry Today* 12.8 (1993): 79.
10. Dohan D., *et al.* "Platelet -rich fibrin (PRF): A second generation platelet concentrate. Part IV Clinical effects on tissue healing". *Oral Surgery, Oral Medicine, Oral Pathology and Oral Radiology* 101E (2006): 56-60.
11. Dohan D., *et al.* "Platelet-rich fibrin (PRF): A second generation platelet concentrate. Part III Leucocyte activation: A New feature for platelet concentrates". *Oral Surgery, Oral Medicine, Oral Pathology and Oral Radiology* 101E (2006): 51-55.
12. Friedman S., *et al.* "Treatment results of apical surgery in premolar and molar teeth". *Journal of Endodontics* 17 (1991): 30.
13. Toffler M., *et al.* "Introducing Choukroun's platelet rich fibrin (PRF) to the reconstructive surgery milieu". *Journal of Implant and Advanced Clinical Dentistry* 1.6 (2009): 21-30.
14. Montanari M., *et al.* "A new biological approach to guided bone and tissue regeneration". *British Medical Journal* 9.2 (2013): 1-3.
15. Leigha R. "Potential of platelet rich fibrin in regenerative periodontal therapy: literature review". *The Canadian Journal of Dental Hygiene* 47.1 (2013): 33-37.
16. Dohan D., *et al.* "Do the fibrin architecture and leukocyte content influence the growth factor release of platelet concentrates? An evidence-based answer comparing a pure platelet-rich plasma (P-PRP) gel and a leukocyte and platelet-rich fibrin (L-PRF)". *Current Pharmaceutical Biotechnology* 13.7 (2012): 1145-1152.
17. Dohan D., *et al.* "Slow release of growth factors and thrombospondin-1 in Choukroun's platelet-rich fibrin (PRF): a gold standard to achieve for all surgical platelet concentrates technologies". *Growth Factors* 27.1 (2009): 63-69.
18. Zumstein A., *et al.* "Leukocyte- and platelet-rich fibrin (L-PRF) for long-term delivery of growth factor in rotator cuff repair: review, preliminary results and future directions". *Current Pharmaceutical Biotechnology* 13.7 (2012): 1196-1206.

**Volume 18 Issue 3 March 2019**

©All rights reserved by Cabrera Edgar, *et al.*