

## Ankylosing Spondylitis as Etiologic Factor in Condylar Resorption: Comprehensive Review and Case Report

Diego Fernando López<sup>1\*</sup>, Juliana Ruiz Botero<sup>2</sup> and Maria Angelica Castro<sup>3</sup>

<sup>1</sup>Assistant Professor, Department of Orthodontics, Universidad del Valle, Cali, Colombia

<sup>2</sup>Orthodontist, Universidad del Valle, Cali, Colombia

<sup>3</sup>Resident 2<sup>nd</sup> Year in Orthodontics, Universidad del Valle, Cali, Colombia

\*Corresponding Author: Diego Fernando López, Assistant Professor, Department of Orthodontics, Universidad del Valle, Cali, Colombia.

Received: September 21, 2018; Published: October 23, 2018

### Abstract

Ankylosing spondylitis is an autoimmune chronic inflammatory disorder that produces different degree of fibrosis and ossification in skeletal joints. When the Temporomandibular joint is the most affected joint, it is called temporomandibular ankylosis. This is associated with limiting opening of the mouth, open bite, masticatory, speaking and oral hygiene difficulties. The objective of this comprehensive review and case report is to present an update of condylar resorption as possible consequence of an osteoarthritic inflammatory disorder (OIDs), and to describe the multidisciplinary treatment of a patient, by combined pharmacologic and orthodontic approaches. The patient was a 28-year-old woman, presenting anterior open bite, mandibular retrognathism and TMJ articular symptoms. The pharmacologic treatment was initiated with Enbrel (Etanercept®), a TNF- $\alpha$  antagonist. Later on, it was changed to Abatacept (ORENCIA®), 125 mg/mL, subcutaneous prefilled syringes, as immunomodulator. The aim of the orthodontic treatment was to modify the occlusal plane by intruding the maxillary posterior teeth to produce anterior rotation of the mandible, thus correcting the open bite and improving occlusal stability. The treatment outcome was considered functionally and esthetically satisfactory and stable.

**Keywords:** Ankylosing Spondylitis; Mandibular Condyle Resorption; Temporomandibular Joint Disorders

### Introduction

The temporomandibular joint (TMJ) is one of the most complex articulations of the human body. Its proper function is very important for the harmony and equilibrium of the masticatory system [1]. The normal function of TMJ must: 1) Be able to perform painless articular movements; 2) Appropriately distribute functional loads throughout articular components; 3) Provide articular stability during its function; 4) Provide mandibular support during occlusion [2]. In order to accomplish these four tasks, the right physiological interaction between TMJ cartilage, fibrocartilage and connective tissue during functional demands and remodeling processes [3].

TMJ remodeling may be dysfunctional if there are condylar volume reductions, reduced ramus height, progressive mandibular revascularization with increased osteoclastic activity in adults or diminished growth rate in young subjects. The dysfunctional remodeling is frequently due to a local or systemic factor that reduces the adaptive capacity, or any excessive or sustained physical stress that exceeds the normal articular adaptive ability [2,3].

The effects of dysfunctional TMJ remodeling could be expressed in adults by a progressive mandibular backward position due to a degenerative process of the condyle known as idiopathic condylar resorption (ICR) [4] or progressive condylar resorption (PCR); these

are aggressive pathological conditions that may develop, mostly in adolescent or young adult women, when individual adaptive ability is reduced or overcome by mechanical parafunctional forces [5].

The clinical signs and symptoms of CR may appear in two forms: 1) Bilateral CR including loss of height and condylar volume, progressive mandibular backward position, unstable occlusal and skeletal muscular relations, bilateral Angle Class II, anterior open bite, divergency of the maxillo-mandibular plane, mandibular ramus shortening, diminished oropharynx airway dimensions and pro-inclination of lower incisors [6]; or 2) Unilateral condylar resorption causing reduction in posterior facial height, dental and skeletal Class II in the affected side, difference in height of mandibular ridge, tipped occlusal plane and midline deviation toward the resorptive condyle, cross-bite in the affected side and loss of contralateral occlusal contact, articular dysfunction and pain [5-7].

Radiographic findings in advanced CR cases include: loss of height and condylar volume, with thinning, shortening and flattening of the upper and/or anterior condyle curvature [8], and divergency of condylar position respect to the mandibular ramus axis [9,10]. In superimposed lateral cephalometric views taken during imaging follow-up, Articulare appears mesially displaced, showing a posterior mandibular rotation and two distinct occlusal planes are observed with an increment of maxilla-mandibular divergence [5]. In CBCT images an external cortical layer loss, as well as erosions, sclerosis, flattening and subcortical cysts are observed [11]. In magnetic resonance images loss of cartilaginous integrity of the condylar head surface, disk position alterations, TMJ inflammation and medullary edema are observed [11,12].

The etiology of CR is related to different local factors, including osteoarthritis, reactive arthritis, avascular necrosis, infection and trauma, systemic diseases of connective tissue or auto-immune diseases such as rheumatoid arthritis, psoriatic arthritis, scleroderma, systemic erythematosus lupus, Sjögren syndrome and ankylosing spondylitis, among others [6]. Endocrine factors are also frequently related to PCR, among them estrogens act as mediators of bone and cartilage metabolism and the presence of increased number of their receptors as a response to exaggerated mechanical charges over the TMJ. The biochemical changes mediated by sexual hormones may be responsible of synovial tissue hyperplasia that increases the production of toxic substrates that affect the articular disk supporting ligaments. If consequently the disk is anteriorly displaced, the mandibular condyle is exposed to substrates that initiate resorption. Estrogens and their receptors are considered as a possible explanation of the higher frequency of PCR in women than in men [6,13].

Another documented etiology for PCR is an orthognathic surgery to treat skeletal open bite Class II malocclusions. The mandibular advancement procedure facilitated by bilateral sagittal osteotomies and counterclockwise rotation of the maxilla-mandibular complex may induce the soft tissue stretching and increases muscle tension in the suprahyoid zone, thus developing a force in posterior-inferior direction over the distal mandibular segment, that places an excessive load over the condyle anterior-superior zone. Therefore, a change in the position of the condyle in relation to the articular disk and capsule is a major potential factor, as well as an increased load over the TMJ due to the change in the associated muscular dynamics [2,8].

Bone loss in the condyle induces a common resorptive mechanism: osteoblasts activated by cytokines promote recruitment and activation of osteoclasts that secrete enzymes responsible for the breakdown of hydroxyapatite and bone collagen [14]. The CR pathogenesis is related to pro-inflammatory cytokines signalization, particularly the tumor necrosis factor- $\alpha$  (TNF- $\alpha$ ), interleukin 6 (IL-6) and receptor-activator of nuclear kappa  $\beta$ -ligand (RANK-L). Pro-inflammatory cytokines are produced by different kinds of cells present in the TMJ, including osteoblasts and synoviocytes. They act together with metalloproteinases (MMPs) which are endopeptides able to breakdown the extracellular matrix collagen and elastin of bone and cartilage articular components [14-17].

Under normal conditions, the MMPs activity is regulated by inhibitors of metalloproteinases (TIMPs) [17]. Therefore, active CR only occurs when there is a disequilibrium on the activity of MMPs and TIMPs, favoring the tissue breakdown by MMPs [18,19], located in the TMJ disk because it is not formed by hyaline cartilage but by fibrocartilage with a higher content in aggregated proteoglycans and fibers of collagen types 1 and 2 [19].

Among OIDs ankylosing spondylitis (AS), an autoimmune disease, now better named as spondylarthroses that also include reactive arthritis, psoriatic arthritis, Crohn's disease and juvenile-onset spondylarthrosis [20,21], is characterized by a bony or fibrous adhesion of TMJ components limiting mouth opening, masticatory, speaking and oral hygiene difficulties [22]. TMJ is involved in 3% - 20.5% of the patients initially diagnosed by a rheumatology test and the most common manifestation in them is inflammatory CR, while TMJ ankyloses is reported in fewer cases without a reported prevalence [23].

AS in general affects more men than women (ratio 2:1) [21], but probably the temporomandibular form is more frequent in women than in men as is well documented for other TMJ disorders. The prevalence of AS is reported between 0.1 and 1.4% depending of the population studied and is more frequently diagnosed in the third decade of life.

AS etiology is unknown but clearly related to genetic factors. The genetic risk factor explains > 90% of the prevalence and some genes common to other auto-immune diseases have been identified [21]. The most recent reviews of AS are focused on the role of Human leukocyte antigen B27 (HLA-B27), a molecule that is part of the major histocompatibility complex and it is encoded on chromosome 6p. Other molecules deeply studied are the endoplasmic reticulum aminopeptidase 1 (ERAP1) and interleukin 23R (IL - 23R) [21,22]. The genetic basis of AS was reviewed by Tsui, *et al* [23]. Studies regarding the pathogenesis of AS document the role of IL - 1 $\beta$  in the initiation of the inflammatory cascade, as well as the role of TNF -  $\alpha$  and MMPs [23-25].

The diagnostic of AS is based in the modified New York criteria that include clinical and radiographic evidences [26]. Posnick and Fantuzzo [27] consider the following diagnostic factors of risk for temporomandibular AS: women, age range of 15 - 35 years, previous trauma, parafunction, TMJ limited movements, anatomic changes in the mandibular condyle head, reduced condylar height, loss of posterior facial height, mandibular backward position, anterior open bite and skeletal and dental Class II.

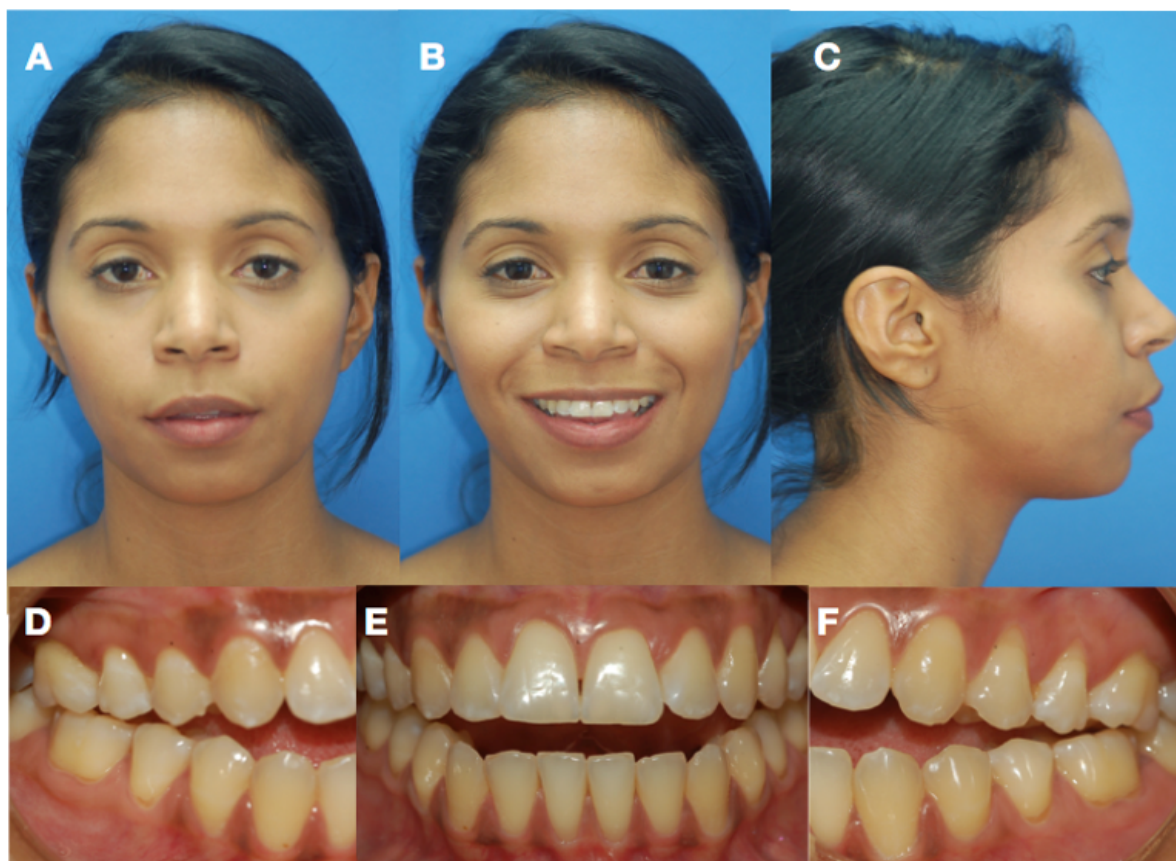
Regarding the medical treatment of AS there has been a recent comprehensive review published [26-31]. In general terms, the pharmacological treatment of AS is centered in the use of inhibitors or blockers of TNF- $\alpha$ , such as Remicade<sup>®</sup>, Etanercept<sup>®</sup> and Humira<sup>®</sup>, that control inflammation and improve the clinical condition of the patients [26]. The long-term use of anti-inflammatory corticoids is not recommended [29].

The purpose of the above comprehensive review of literature was to put in context a clinical case of CR, diagnosed as temporomandibular AS that was conservatively treated.

### Clinical Case

The patient was a 28 year old woman, consulting for anterior open bite and progressive mandibular retro-positioning and presenting articular symptoms.

Clinically, an anterior open bite measuring 7 mm was identified with fulcrum on the molars only. A moderate profile convexity was the other major finding. Other minor malocclusion traits were of lesser impact (Figure 1).



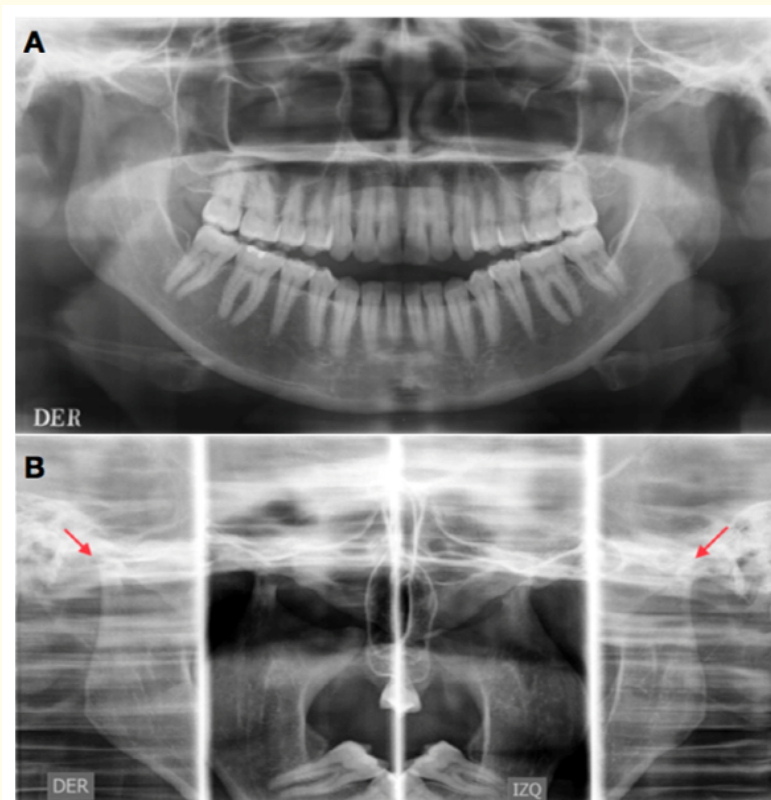
**Figure 1:** Initial photos, showing moderate convex profile and 7 mm anterior open bite with fulcrum in molars. Extra-oral: A) Frontal view, B) Smile frontal view, C) Right profile. Intraoral: D) Right occlusion, E) Frontal occlusion, F) Left occlusion.



**Radiographic analysis**

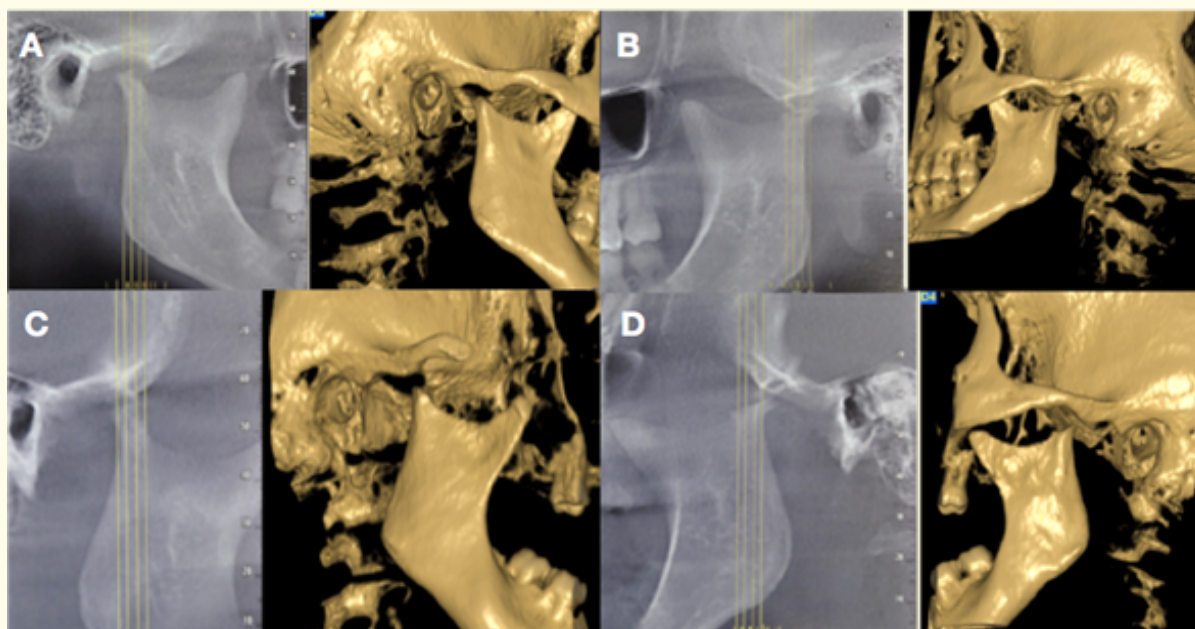
Lateral cranial radiograph shows a dolichofacial pattern, skeletal Class II related to mandibular retrognathism and presence of two divergent occlusal planes with a maxilla-mandibular open angle and negative overbite.

Panoramic radiography suggested loss of bone cortical continuity at condylar level, together with reduced condylar height and volume. In the TMJ radiographs taken at open/closed-mouth it is notorious the condylar cortical bone breakdown (Figure 2).



**Figure 2:** A- Panoramic radiography; B- TMJ open/closed-mouth radiographs the arrows indicate areas of condylar breakdown.

The tomographic 3-D reconstruction of hard tissues permitted the quantification of condylar height and volume deficiency (Figure 3).

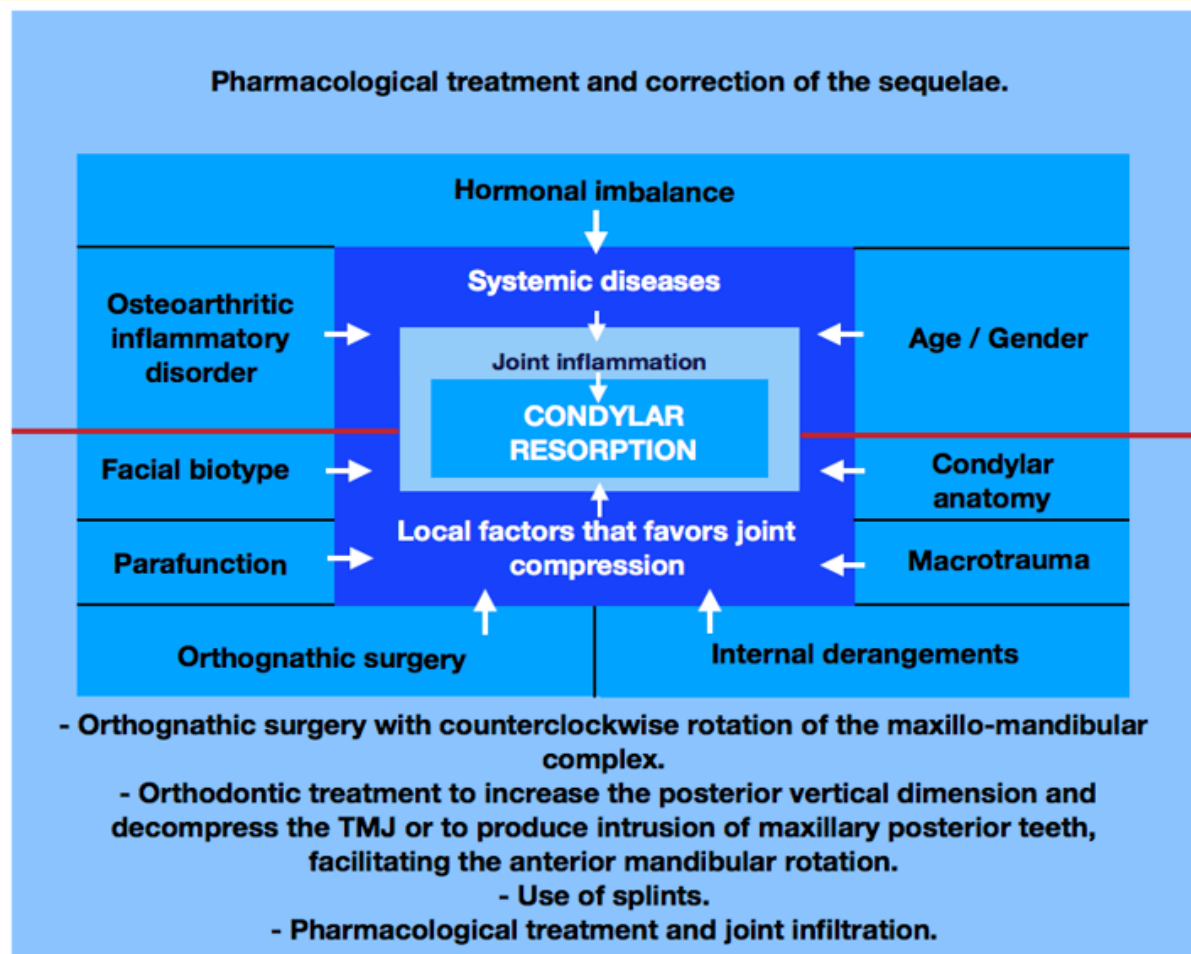


**Figure 3:** Tomographic 3-D reconstruction of hard tissues.  
A- Right TMJ closed mouth, B- Left TMJ closed mouth, C- Right TMJ open mouth, D- Left TMJ closed mouth.

## Diagnosis

The maxillofacial diagnostic of the patient was progressive bilateral condylar resorption with articular symptoms and secondary Class II open bite malocclusion development. The medical rheumatologic diagnostic was ankylosing spondylitis (chronic inflammatory pathology related to a condylar resorption process).

According to the 2 pathways of joint inflammation that promotes condylar resorption and their possible treatments, the following scheme was proposed (Figure 4).



**Figure 4:** Pathways of joint inflammation that promotes condylar resorption, modified from Arnett and Gunson. Risk Factors in the initiation of condylar resorption. *Semin Orthod* 2013; 19:81-88.

The systemic pathway is represented by OIDs, connective tissue diseases, hormonal imbalance (estrogens, prolactin and corticosteroids) [6,13] and other factors such as age and sex, affecting mainly women in the development of joint problems [5]. Similarly local factors that produce condylar compression, such as the facial biotype, condylar anatomy, internal articular derangements [5,9], macrotrauma, parafunction, and orthognathic surgery for mandibular advancement [2,8], can be interrelated, be codependent and co-exist, even when the main etiological factor is indeed the systemic disease.

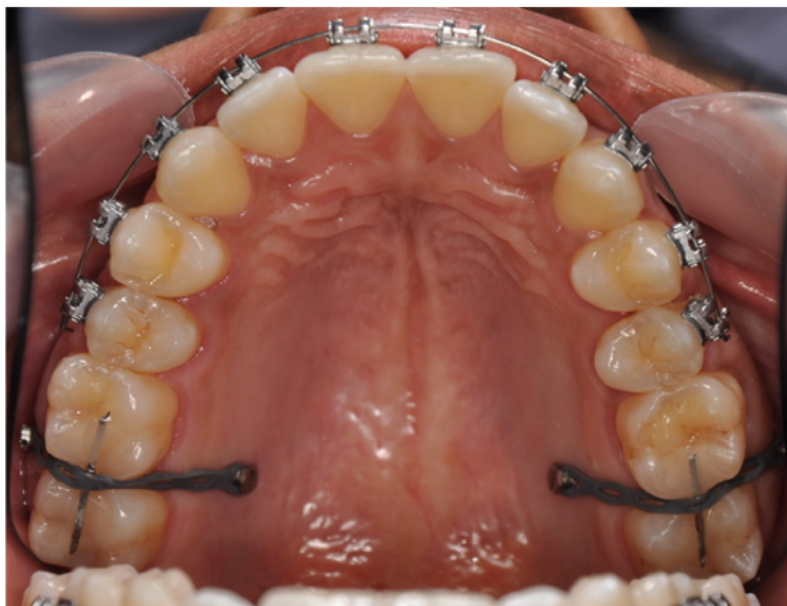Finally, the treatment for the systemic factors consists of pharmacological prescriptions [31] and the correction of the anatomical sequelae to reinstate patient’s quality of life through an adequate joint, muscular and occlusal function. For the local factors, surgical treatment with counterclockwise rotation of the maxillo-mandibular complex [27] and orthodontic treatment to increase the mandibular ramus posterior vertical dimension in cases where it is combined with orthognathic surgery or to produce intrusion of maxillary posterior teeth, facilitating the anterior mandibular rotation and the correction of the open bite for an adequate occlusal stability. These options are usually combined with the use of splints, pharmacological treatment and joint infiltration.

**Based on this comprehensive review the provided treatment was**

**Medical Treatment:** The pharmacologic treatment was initiated with Enbrel (Etanercept®), a TNF-α antagonist. Later on, it was changed to Abatacept (ORENCIA®), 125 mg/mL, subcutaneous prefilled syringes, as immunomodulator.

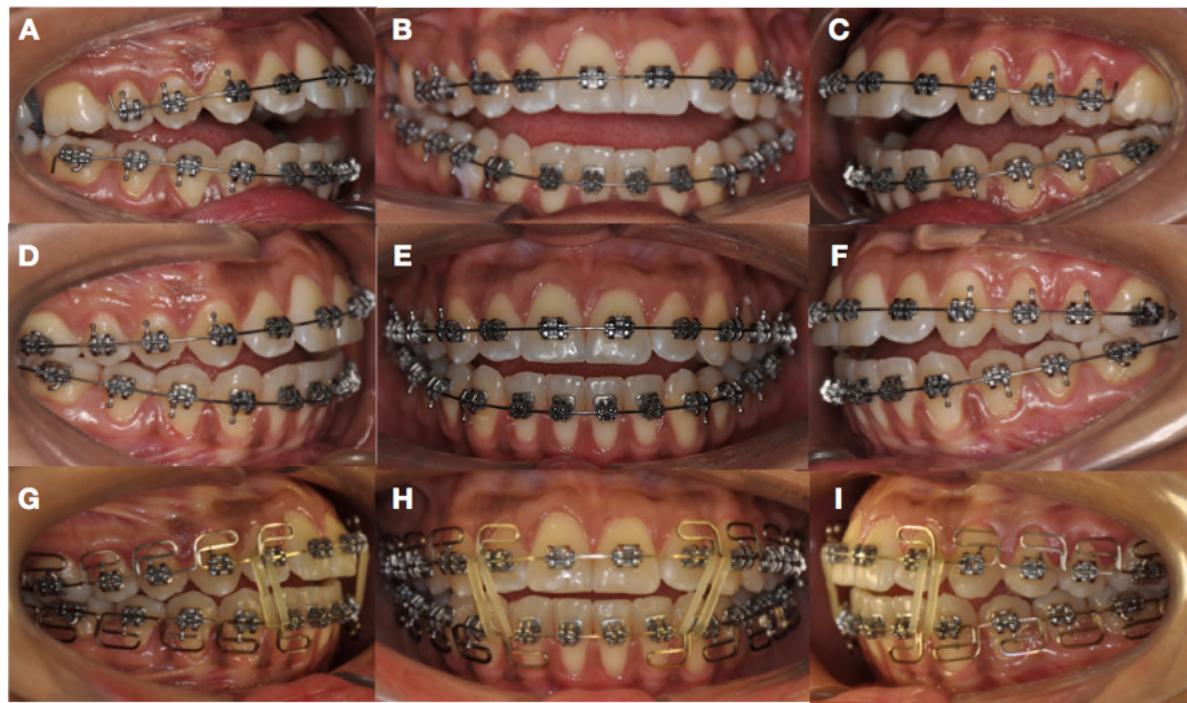
**Orthodontic Treatment:** The aim of the orthodontic treatment was to modify the occlusal plane by intruding the maxillary posterior teeth to produce anterior rotation of the mandible, thus correcting the open bite and improving occlusal stability.

Self-ligating SmartClip SL3, 3M Unitek brackets were bonded and temporary anchorage devices (TADs) were placed in the upper arch in the attached gingiva area between right and left first and second molar, in vestibular and palatal bone surfaces, to facilitate intrusive mechanics in the posterior sector with occlusal bar made with stainless steel .019” × .025” and a Power Chain, Ormco (Figure 5 and Figure 6A, 6B, 6C).



**Figure 5:** Initial treatment with SmartClip SL3, 3M Unitek brackets; upper vestibular and palatal TADs for intrusive mechanics with occlusal bar and Power Chain.

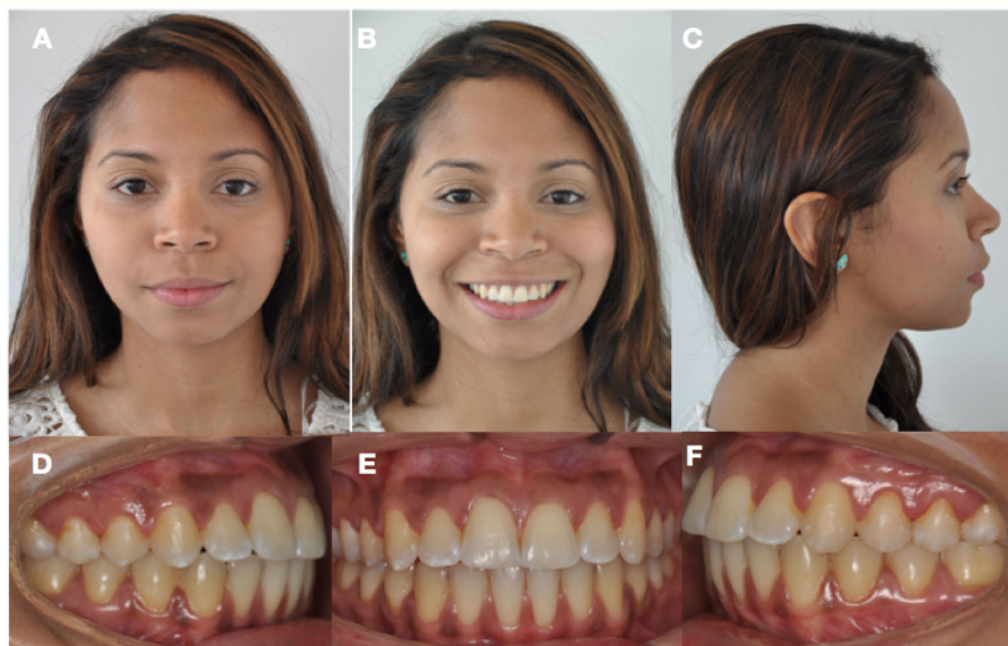




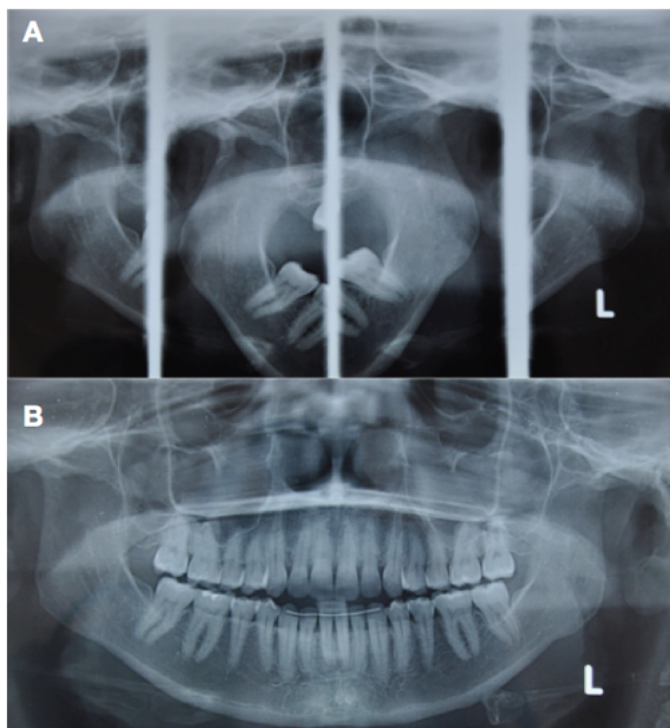
**Figure 6:** Initial treatment with SmartClip SL3, 3M Unitek brackets A- Right view, B- Frontal view, C- Left view. Treatment Progress, anterior open bite 2 mm; D-Right view, E- Frontal view, F- Left view. Dento-alveolar Compensation with multiloop arches for anterior teeth extrusion, open bite and occlusal correction G- Right view, H- Frontal view, I- Left view.

The reduction of anterior open bite is observed in figures 6D-6F. When it was only 2 mm, it was decided to perform dento-alveolar compensation with multiloop arches of blue Elgiloy, .019" × .025" and bilateral vertical elastics of 3/16" and 6.5 ounces for anterior teeth extrusion, occlusal plane modification and open bite correction (Figures 6G-6I).

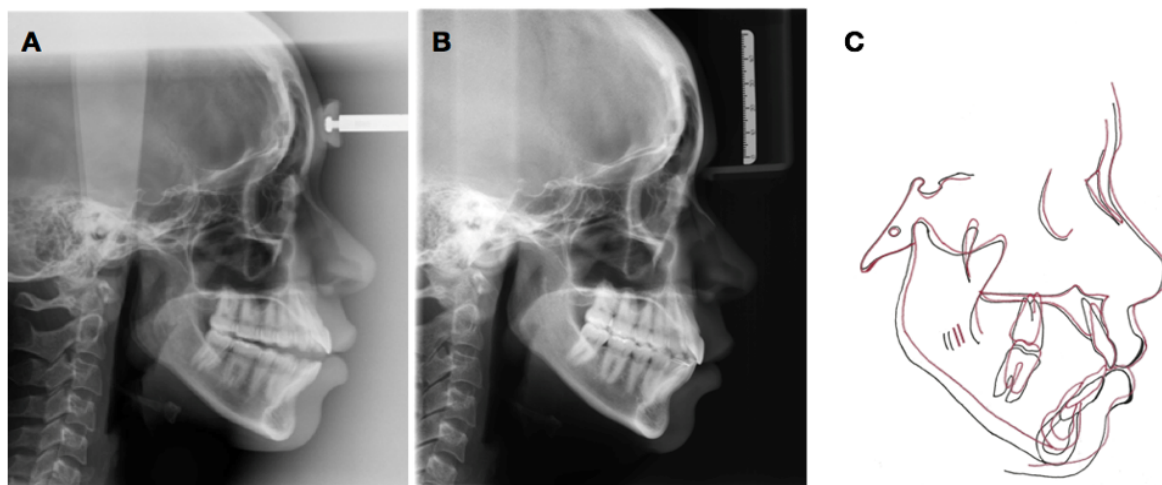
The orthodontic treatment was finished, with the open bite eliminated (Figure 7). Radiographic control did not show progression of the condylar resorption (Figure 8). Treatment outcomes were contrasted through superimposition of the initial and final lateral radiographs (Figure 9).



**Figure 7:** Treatment result with anterior open bite correction. Extraoral: A) Frontal view, B) Smile frontal view, C) Right profile. Intraoral: D) Right occlusion, E) Frontal occlusion, F) Left occlusion.



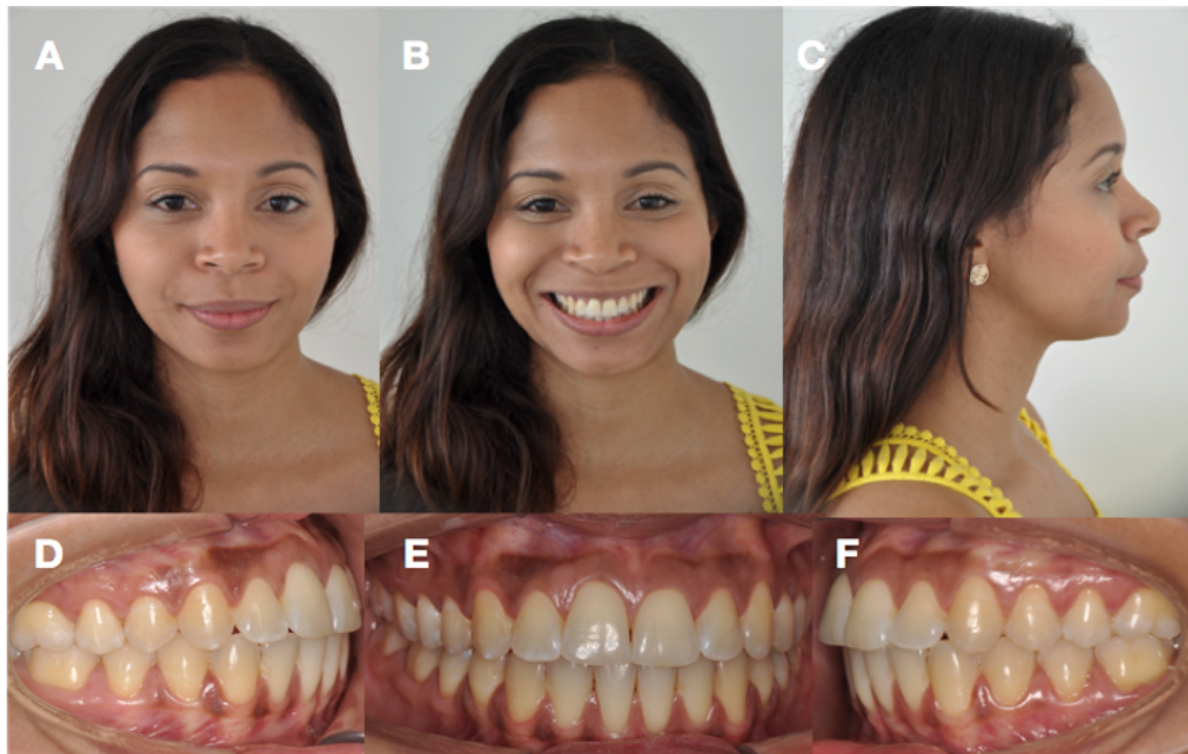**Figure 8:** A- Final right and left TMJ open/closed mouth radiographics. B- Panoramic Radiograph.



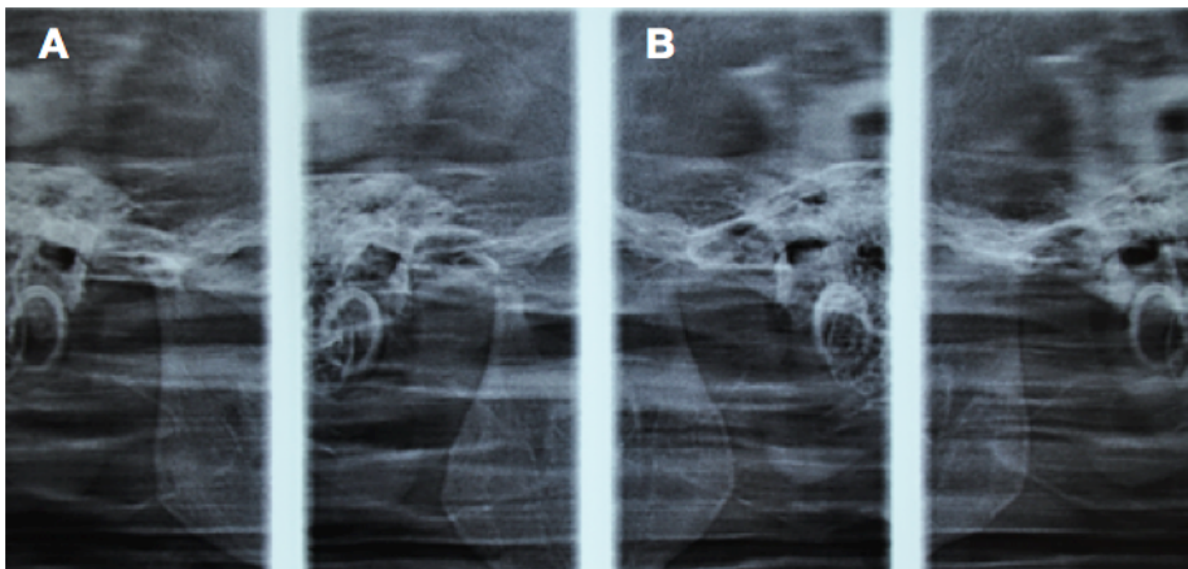
**Figure 9:** A- Initial lateral radiograph, B- Final lateral radiograph, C- Overlapping. Black tracing lines represent pre-treatment while red tracing lines represent post-treatment.



The occlusion was stabilized with retainers. At the two-year control the occlusion stability was documented and in follow-up open/closed mouth radiographs no further condylar changes were observed; therefore, no bilateral condylar resorption progression took place (Figure 10 and 11).



**Figure 10:** Control after two years of retention, the outcome was stable. Extraoral: A) Frontal view, B) Smile frontal view, C) Right profile. Intraoral: D) Right occlusion, E) Frontal occlusion, D) Left occlusion.



**Figure 11:** Open/closed mouth final Radiographs. A) Right TMJ, B) Left TMJ.

## Discussion

The case presented shows that TMJ, although it has a great adaptive ability to functional demands, may suffer structural changes as a result of a disbalance between pro-inflammatory chemical mediators and auto-immune modulators. Pro-inflammatory cytokines are released from articular cells and accumulated in capsular spaces, being able to affect bone and cartilage integrity in chronic inflammatory auto-immune disorders such as ankylosing spondylitis.

In the initial stage of TMJ AS histologic studies find hyperplasia of synovial tissue accompanied by cell proliferation, infiltration of plasmatic cells and histiocytes, fibrosis and bone and/or cartilage metaplasia. All of them are characteristic signs of chronic inflammatory processes that are responsible for the first erosive articular changes, such as reduction of articular space. In more advanced stages fibrous adhesions are generated leading to bone ankyloses of the articular components [32].

Some CR cases, such as the one hereby reported, may be successfully treated with orthodontics without orthognathic surgery. Conservative or minimally invasive treatments are recommended when the facial features of the patient allow the correction of malocclusion by orthodontic mechanics. Early diagnostic is also necessary to succeed with this approach, but unfortunately most patients receive a late diagnostic, about 5 - 6 years after the onset of AS [21].

Cases at high risk to develop CR are those with traumatic or genetic antecedents, or systemic pathologies, but in absence of degenerative articular change, may be treated by pharmacological therapy [31]. Alternative therapies include the use of vitamin D, calcium, 17- $\beta$ -estradiol, glucosamine sulfate and chondroitin-sulfate considered as promoters of chondrocyte regeneration and inhibitors of enzymes such as collagenase and phospholipase A2 [31]. Minimally invasive procedures such as intra-articular infiltration of autologous growth factors obtained from plasma-rich platelets, hyaluronic acid and botulinic toxin A if there is an associated spasm [31].

If condylar volume reduction and facial deformity are severe, the surgical reconstruction is necessary. The surgical protocol includes elimination of the bilaminar tissue around the condyle, mobilization, reposition and stabilization of the condylar disc with anchorage and artificial ligaments [13,28]. Orthognathic surgery is indicated in the event of esthetic or functional severe situations, to obtain counterclockwise mandibular rotation [32]. Best surgical outcomes are achieved when the orthognathic procedure is performed within the first four years of the onset [33]. In presence of active disease, some years should be allowed to pass before performing a second orthognathic surgery [8,13,28].

If the integrity of the disc is compromised, it is recommended to eliminate tissue and replace it by autologous graft. If the condyle is not functional, it has been suggested to perform a condylectomy and replace with sternum-clavicular or costochondral tissue [34]. Another option of the complete articular replacement by alloplastic tissues, as suggested by Wolford [33]. to treat cases when the TMJ is dysfunctional. In severe micrognathism cases it is recommended the mandibular distraction osteogenesis, to allow the soft tissue and muscle progressive adaptation to great mandibular advancements [35].

The orthodontic approach in the present case was the modification of the occlusal plane using TADs placed between the upper molar's roots to facilitate their intrusion [37] and then using multiloop arches to stabilize occlusion and maintain the mandible in advanced position as indicated by Sato, *et al.* [37] to promote secondary condylar growth assisted by the neuromuscular function obtained in the new mandibular position, occlusally stabilized. The occlusal treatment frequently includes the additional prescription of splints [5,28].

## Conclusions

The present case illustrates the multidisciplinary approach to treat Condylar Resorption of an AS case. For a successful and predictable outcome, the clinician should understand the etiopathology of the disease and the early diagnostic and detection of the progression are important to avoid sequelae. A systemic control is necessary as well to prevent the progression of this kind of disease. In this specific patient, the progression of condylar resorption was stabilized by pharmacologic treatment, while the occlusion was at the same time improved by a minimally invasive orthodontic treatment to obtain the required mandibular counterclockwise rotation to reduce the skeletal open bite and provide a better facial convexity.

## Bibliography

1. Merigue LF, *et al.* "Tomographic evaluation of the temporomandibular joint in malocclusion subjects: condylar morphology and position". *Brazilian Oral Research* 30 (2016): e17.
2. GW Arnett, *et al.* "Progressive mandibular retrusion- idiopathic condylar resorption. Part I". *American Journal of Orthodontics and Dentofacial Orthopedics* 110 (1996): 8-15.
3. Schenk RK, *et al.* "Articular cartilage morphology". In: Kuettner J, Schleyerbach R, Hascall VC, eds. *Articular cartilage biochemistry* New York: Raven Press (1986): 3-22.
4. Arnett GW and Tamborello JA. "Progressive class II development-female idiopathic condylar resorption". In: West RA, edition *Oral maxillofacial clinics of North America* (1990): 699-716.
5. Handelman CS and Greene CS. "Progressive/Idiopathic Condylar Resorption: An Orthodontic Perspective". *Seminars in Orthodontics* 19.2 (2013): 55-70.
6. Wolford L. "Idiopathic condylar resorption of the temporomandibular joint in teenage girls". *Baylor University Medical Center Proceedings* 14 (2001): 246-252
7. Young A. "Idiopathic condylar resorption: The current understanding in diagnosis and treatment". *The Journal of the Indian Prosthodontic Society* 17 (2017): 128-135.
8. Hoppenreijts TJM, *et al.* "Long-term evaluation of patients with progressive condylar resorption following orthognathic surgery". *International Journal of Oral and Maxillofacial Surgery* 28.6 (1999): 411-418.
9. Hwang SJ, *et al.* "Non-surgical risk factors for condylar resorption after orthognathic surgery". *Journal of Cranio-Maxillofacial Surgery* 32.2 (2004): 103-111.
10. Hoppenreijts TJM, *et al.* "Evaluation of Condylar Resorption Before and After Orthognathic Surgery". *Seminar on Orthodics* 19.2 (2013): 106-115.
11. Hatcher DC. "Progressive Condylar Resorption: Pathologic Processes and Imaging Considerations". *Seminar on Orthodics* 19.2 (2013): 97-105.
12. Laskin Daniel M, *et al.* "Temporomandibular Disorders: An Evidence-Based Approach to Diagnosis and Treatment". Chicago, Quintessence (2006): 105-123.
13. Wolford L and Cardenas L. "Idiopathic condylar resorption: Diagnosis, treatment protocol, and outcomes". *International Journal of Oral and Maxillofacial Surgery* 116 (1999): 667-677.
14. Arnett and Gunson. "Risk Factors in the initiation of condylar resorption". *Seminar on Orthodontics* 19 (2013): 81-88.
15. Michael J, *et al.* "Pathophysiology and Pharmacologic Control of Osseous Mandibular Condylar Resorption". *Journal of Oral and Maxillofacial Surgery* 70 (2012): 1918-1934
16. Sato J, *et al.* "Expression of interleukin 8 in synovial tissues in patients with internal derangement of the temporomandibular joint and its relationship with clinical variables". *Oral Surgery, Oral Medicine, Oral Pathology, and Oral Radiology* 103 (2007): 467
17. Alstergren P and Kopp S. "Insufficient endogenous control of tumor necrosis factor-alpha contributes to temporomandibular joint pain and tissue destruction in rheumatoid arthritis". *Journal of Rheumatology* 33 (2006): 1734-1739.



18. Hamada Y, *et al.* "Inflammatory cytokines correlated with clinical outcome of temporomandibular joint irrigation in patients with chronic closed lock". *Oral Surgery, Oral Medicine, Oral Pathology, and Oral Radiology* 102 (2006): 596- 601.
19. Milner JM, *et al.* "Metalloproteinase and inhibitor expression profiling of resorbing cartilage reveals pro-collagenase activation as a critical step for collagenolysis". *Arthritis Research and Therapy* 8 (2006): R142.
20. Sandler RD and Dunkley L. "Osteoarthritis and the inflammatory arthritides, Surgery (2017).
21. Zambrano JF, *et al.* "Ankylosing Spondylitis: From cells to genes". *International Journal Inflammation* (2013).
22. Spornlak-Tutak K, *et al.* "Management of temporomandibular ankyloses - compromise or individualization - a literature review". *Medical Science Monitor* 17.5 (2011): RA111-RA116.
23. Tsui F, *et al.* "The genetic basis of ankylosing spondylitis: new insights into disease pathogenesis". *The Application of Clinical Genetics* 7 (2014): 105-115.
24. Rezaeiemanesh A, *et al.* "Immune cells involved in the pathogenesis of ankylosing spondylitis". *Biomedicine and Pharmacotherapy* 100 (2018): 198-204.
25. Jiang-Ming Li, *et al.* "Ankylosing spondylitis associated with bilateral ankylosis of the temporomandibular joint". *Oral Surgery, Oral Medicine, Oral Pathology, and Oral Radiology* 116 (2013): e478-e484.
26. Moon KH and Kim YT. "Medical treatment of ankylosing Spondylitis". *Hip Pelvis* 26.3 (2014):129-135.
27. Posnick J and Fantuzzo J. "Idiopathic Condylar Resorption: Current Clinical Perspectives". *Journal of Oral and Maxillofacial Surgery* 65 (2007): 1617-1623.
28. Chooryung J, *et al.* "Total alloplastic temporomandibular joint reconstruction combined with orthodontic treatment in a patient with idiopathic condylar resorption". *International Journal of Oral and Maxillofacial Surgery* 140 (2011): 404-417.
29. Muhammad A, *et al.* "Treatment of Ankylosing Spondylitis: A Critical Appraisal of Nonsteroidal Anti-Inflammatory Drugs and Corticosteroids". *American Journal of Medical Sciences* 343.5 (2012): 350-352.
30. Maksymowych WP. "Disease modification in ankylosing spondylitis". *Nature Reviews Rheumatology* 6 (2010): 75-81.
31. Gunson MJ, *et al.* "Pathophysiology and pharmacologic control of osseous mandibular condylar resorption". *Journal of Oral and Maxillofacial Surgery* 70.8 (2012): 1918-1934.
32. Hwang SJ, *et al.* "The role of posteriorly inclined condylar neck in condylar resorption after orthognathic surgery". *Journal of Cranio-Maxillofacial Surgery* 28 (2000): 85-90.
33. Wolford LM. "Concomitant temporomandibular joint and orthognathic surgery". *Journal of Oral and Maxillofacial Surgery* 61 (2003): 1198-1204.
34. Huang YL, *et al.* "Diagnosis and management of condylar resorption". *Journal of Oral and Maxillofacial Surgery* 55 (1997): 114-119.
35. Schendel SA, *et al.* "Idiopathic Condylar Resorption and Micrognathia: The Case for Distraction Osteogenesis". *Journal of Oral and Maxillofacial Surgery* 65.8 (2007): 1610-1606.

36. ND Kravitz, *et al.* "The use of temporary anchorage devices for molar intrusion". *JADA* 138.1 (2007): 56-64.
37. Hwang do Ho, *et al.* "Occlusal plane and mandibular posture in hyperdivergent type of malocclusion in mixed dentition subjects". *Bulletin of Kanagawa Dental College* 30 (2002): 87-92.

**Volume 17 Issue 11 November 2018**

**©All rights reserved by Diego Fernando López, *et al.***