

## Radio-Clinical Aspect of Arteriovenous Malformation of Mandible: A Case Report and Literature Review

Zineb Assakhi<sup>2\*</sup>, Nadia Moussali<sup>1,2</sup>, Naima El Benna<sup>1,2</sup>, Mohamed Benchad<sup>3</sup> and Faiçal Slimani<sup>1,3</sup>

<sup>1</sup>Faculty of Medicine and Pharmacy, University Hassan II Casablanca, Casablanca, Morocco

<sup>2</sup>Department of Radiology, 20 August 1953 Hospital, University Hospital Center Ibn Rushd of Casablanca, Casablanca, Morocco

<sup>3</sup>Department of Stomatology, Oral and Maxillofacial Surgery, 20 August 1953 Hospital, University Hospital Center Ibn Rushd of Casablanca, Casablanca, Morocco

**\*Corresponding Author:** Zineb Assakhi, Department of Radiology, 20 August 1953 Hospital, University Hospital Center Ibn Rushd of Casablanca, Casablanca, Morocco.

**Received:** August 14, 2018; **Published:** October 31, 2018

### Abstract

Arteriovenous malformations (AMVs) of the oral and maxillofacial region are rare but potentially fatal due to their hemorrhagic risk.

We report the case of an 11-year-old girl; admitted to the maxillofacial surgery department for suspicion of cellulitis secondary to a dental abscess.

An orthopantomogram was performed showing a radiolucency suggesting an aneurysmal bone cyst or an ameloblastoma. The diagnosis of mandibular arteriovenous malformation was finally retained after performing a facial computed tomography (CT) angiography.

The study of this entity is important for both clinicians (dentists and maxillofacial surgeons) and radiologists to make the right diagnosis, establish relationships with surrounding structures and avoid life threatening complications (cataclysmic hemorrhage).

**Keywords:** Arteriovenous Malformation; Mandibular; Radiolucent Lytic Lesion; Computed Tomography Angiography; Treatment

### Abbreviations

AMV: Arteriovenous Malformation; CT: Computed Tomography; ISSVA: International Society for the Study of Vascular Anomalies; MRI: Magnetic Resonance Imaging; OPG: Orthopantomogram; NCCT: Non-Contrast Computed Tomography; MRA: Magnetic Resonance Angiography

### Introduction

Arteriovenous malformations (AVMs) occur as a result of errors in vascular morphogenesis present at birth [1,2]. Although rare, AVM are common in the head-and-neck area (51%) with a slight female predominance [3].

The radiology allows to orient towards the diagnosis and specifies the degree of local extension.

### Etiopathogeny

According to Mulliken and Young, two types of vascular lesions can be recognized, which depend on the intrinsic properties of endovascular cells, namely haemangiomas and vascular malformations [4]. This classification was reviewed in 1996 and again in 2014 by the International Society for the Study of Vascular Anomalies (ISSVA), including new anomalies.

Indeed, arteriovenous malformations (AVMs) are arteriovenous shunts with low flow at the beginning of their evolution, which can accelerate suddenly with the hormonal changes (puberty, pill, pregnancy...) or a traumatism and become symptomatic [5].

**Clinically**

The patient may present mandibular swelling, facial asymmetry or deformity, gingival bleeding, dental loosening, malocclusion and unfortunately sometimes a haemorrhagic shock following a simple extraction of teeth [6-8].

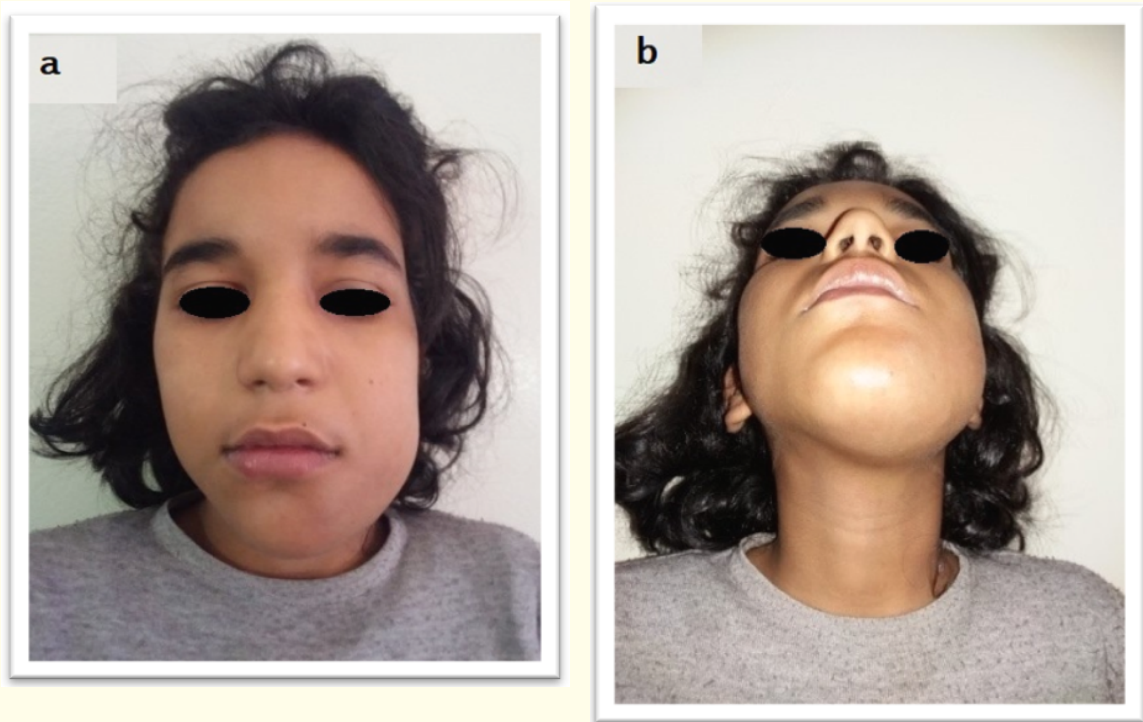
Near the alveolar bone; they are often manifested by pericorony bleeding, moving teeth, and sometimes a disruption of oral occlusion. The central lesions are painful and produce an alteration of the facial morphology, sometimes with “thrill”, breathing and neuro-sensory deficits [9].

**Imaging**

The radiographic appearances of these lesions are variable, with no pathognomonic features, ranging from a small radiolucency, soap bubble appearance or obvious osseous erosion of the alveolus with floating teeth. Computed tomography (CT) scan and magnetic resonance imaging (MRI) are more helpful, they can show the shape of the AVM, the extension of the lesion into the bone (lytic expansion), soft tissue and major vessels [10,11].

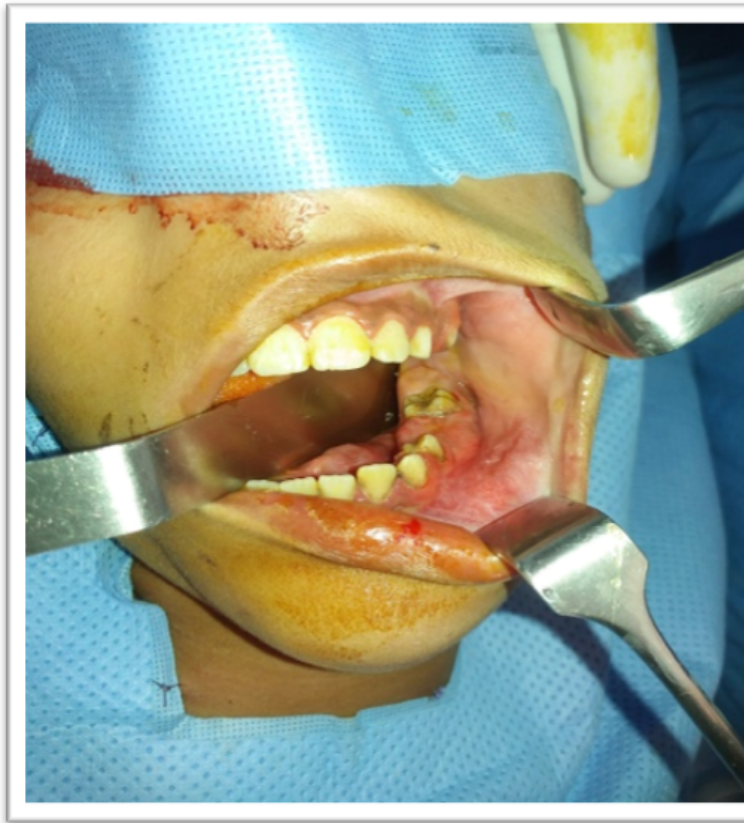**Case Report**

We report the case of an 11-year-old girl with no history of previous medications, bleeding diathesis or hospitalization, who consulted at the maxillofacial surgery department for a left mandibular swelling that had been evolving for two months (Figure 1).



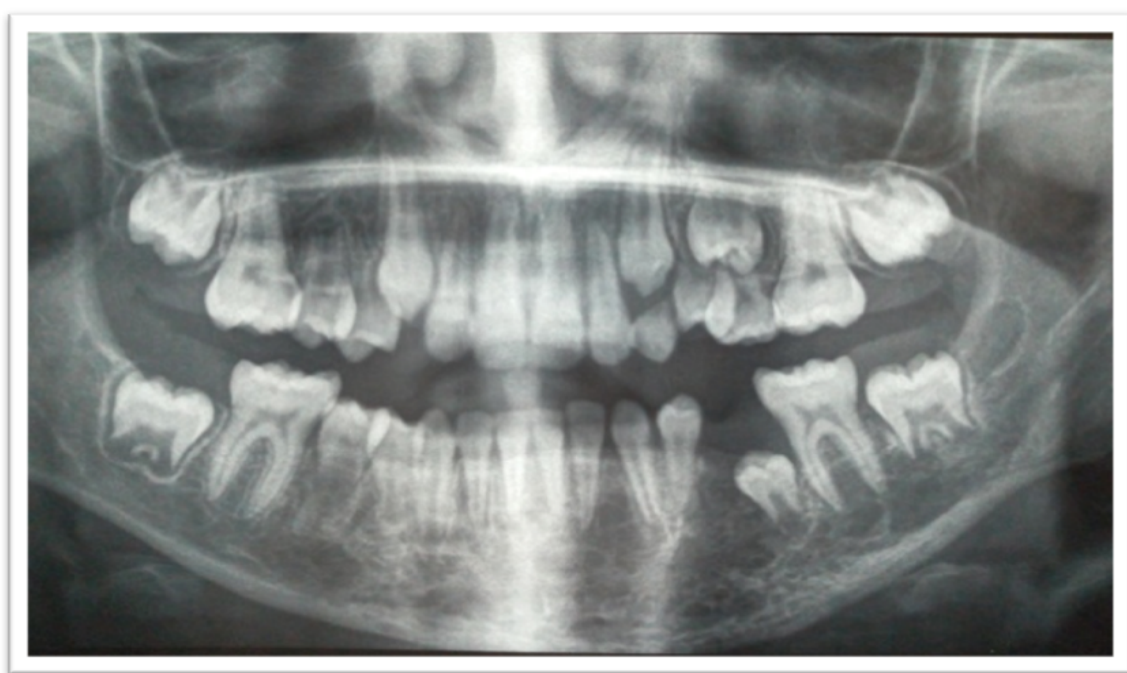**Figure 1:** a and b: Left mandibular swelling that had been evolving for two months.

Physical examination noted facial asymmetry with a left mandibular swelling and multiple caries, especially in front of the tooth 34 where we noted an inflammatory mucosa (Figure 2).



**Figure 2:** An inflammatory mucosa in front of the tooth 34 with multiple caries.

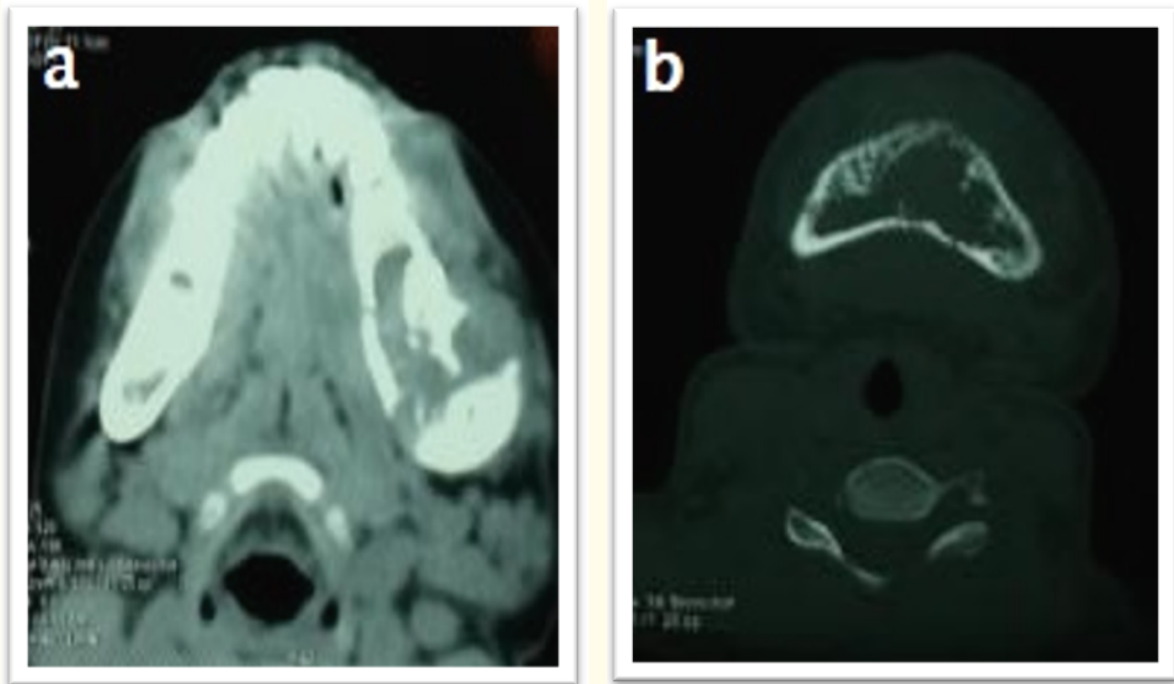
An orthopantomogram (OPG) was performed and revealed an extensive radiolucency in the left mandible involving the molar area (Figure 3); suggesting an aneurysmal bone cyst or ameloblastoma.



**Figure 3:** Orthopantomogram (OPG) = an extensive radiolucency in the left mandible involving the molar area.

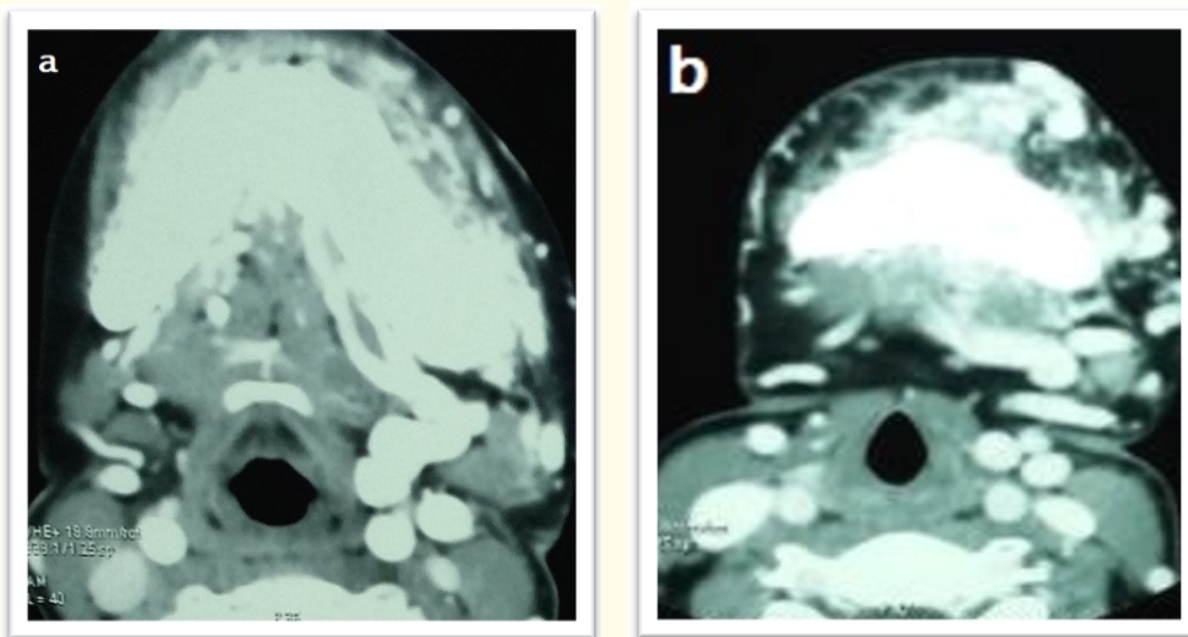
An non-contrast CT (NCCT) was then performed, followed by contrast study and CT angiography.

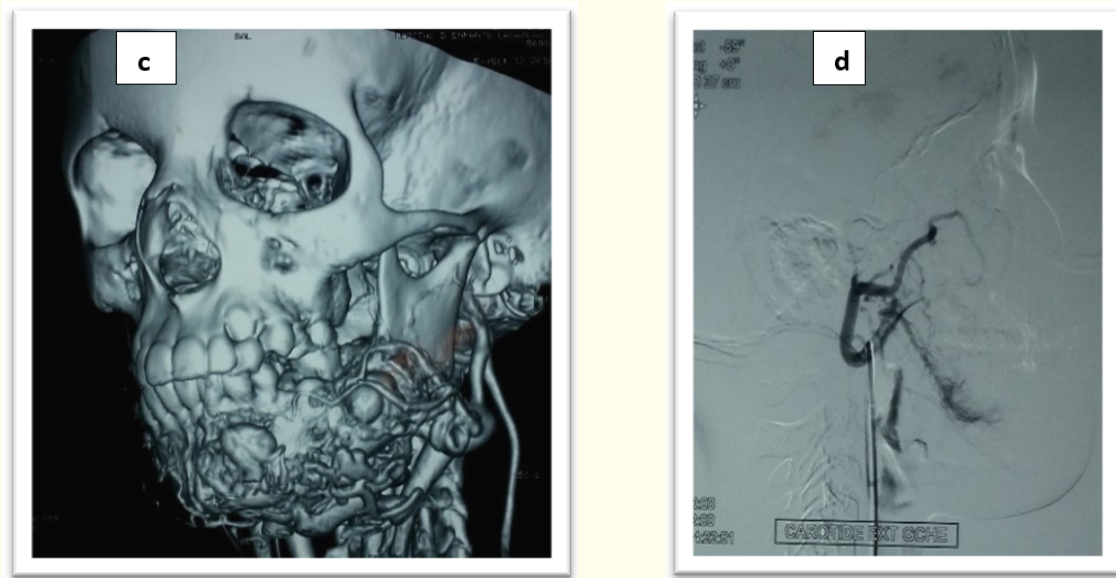
The NCCT showed a large expansible intraosseous lesion of the left mandible with cortical thinning (Figure 4) enhancing after contrast product injection with abnormal tortuous vessels feeding the lesion.



**Figure 4:** a and b: The NCCT = a large expansible lytic lesion with cortical thinning and destruction involving the left mandible.

On CT angiography, multiple serpiginous vascular structures of arterial appearance were seen, originating from left external carotid artery with venous drainage, extending to the left jaw, mandibular and parotid regions (Figure 5).





**Figure 5:** a, b and c: CT angiography showed an enhancing lesion with abnormal tuft of tortuous, dilated feeding vessels at the site of lesion originating from left external carotid artery. c: 3D VR reconstructions. d: Arteriography of the left external carotid artery.

We retained the diagnosis of mandibular AVM.

An embolization was performed and the patient underwent surgical intervention with no short or long-term complications.

## Discussion

AVMs are extremely rare entities with life threatening risk due to a massive bleeding during a simple tooth extraction or biopsy. Although rare, 50% of all intraosseous AVMs occur in the neck and head region [8].

Patients usually present non-specific symptoms including pain, audible bruit (thrill), dental loosening, spontaneous gingival bleeding or after a brush, swelling of soft tissues that can cause a facial deformity; change in skin or intra-oral mucosal discoloration (our case) and dysesthesia of the lower lip or chin [12,13].

Radiological exploration based on multiples modalities (CT scan, Doppler ultrasound, arteriography and MRI) has a major place. It can describe the characteristics of the AVM in terms of size and shape, flow velocity and direction and precise the relationship between the AVM and surrounding structures [14].

Panoramic radiograph cannot distinguish AVMs from others differential diagnosis such as ameloblastoma, odontogenic cyst or metastatic malignant tumors [8] hence the interest and the need of other investigations to make the diagnosis.

Contrast-enhanced CT can be useful in assessing the diagnosis. Although it can establish a vascular map and information about bone changes around the lesion, it will expose the patient (children in most cases) to ionizing radiation with limited information about blood flow [14]. That is why angiography remains the gold standard for determination of location and flow characteristics of vascular lesions, vessels supplying blood to the lesion, the relative venous outflow characteristics and the presence or absence of arteriovenous shunts [3].

Superselective arteriography remains an essential tool for diagnosis and planning of treatment [11].

Treatment depends on the stage of evolution [15]. Asymptomatic quiescent forms are to be respected and are closely monitored. On the other hand, invasive treatment (surgery +/- interventional radiology) can only be considered if it is curative. Superselective angiographic embolization is the first line of treatment to reduce a possible massive bleeding at the time of surgery.

### Conclusion

AVM is a radio-clinical emergency given its haemorrhagic risk during a simple tooth extraction or biopsy. A panoramic radiograph showing a lytic lesion in a child with history of gingival bleeding with or without other symptoms should raise a suspicion of mandibular AVM.

The radiologist must confirm the diagnosis; establish the AVM relationship with vessels and with surrounding structures.

CT scanning and MRI are sufficient in most cases but angiography remains the gold standard when determining the location and flow characteristics of a vascular lesion.

### Declarations of Interest

None.

### Bibliography

1. Waner M and Suen JY. "Management of congenital vascular lesions of the head and neck". *Oncology (Williston Park)* 9.10 (1995): 989-994.
2. Higuera S., et al. "Management of hemangioma and pediatric vascular malformations". *Journal of Craniofacial Surgery* 17.4 (2006): 783-789.
3. Nekooei S., et al. "Embolisation of arteriovenous malformation of the maxilla". *Dentomaxillofacial Radiology* 35.6 (2006): 451-455.
4. Mulliken J and Glowacki J. "Hemangiomas and vascular malformations in infants and children: a classification based on endothelial characteristics". *Plastic and Reconstructive Surgery* 69.3 (1982): 412-422.
5. Dounia Kamal., et al. "Malformation artérioveineuse mandibulaire : à propos d'un cas et revue de la littérature". *Actual Odonto-Stomatology* 271 (2015): 22-24.
6. Rodesch G., et al. "Arteriovenous malformations of the dental arcades: The place of endovascular therapy: Results in 12 cases are presented". *Journal of Craniofacial Surgery* 26.5 (1998): 306-313.
7. Han MH., et al. "Craniofacial arteriovenous malformation: Preoperative embolization with direct puncture and injection of n-butyl Cyanoacrylate". *Radiology* 211.3 (1999): 661-666.
8. Mohammadi H., et al. "Arteriovenous malformation of the mandible: Report of a case with a note on the differential diagnosis". *Oral Surgery, Oral Medicine, Oral Pathology, and Endodontology* 84.3 (1997): 286-289.
9. Gaétan Noreau., et al. "Malformation artérioveineuse de la mandibule: Revue de littérature et présentation de cas". *Journal of the Canadian Dental Association* 67.11 (2001): 646-651.
10. Sakkas N., et al. "Arteriovenous malformation of the mandible: a life-threatening situation". *Annals of Hematology* 86.6 (2007): 409-413.

11. Amit Nandan Dhar Dwivedi, *et al.* "Mandibular arteriovenous malformation: A rare life-threatening condition depicted on multidetector CT angiography". *Journal of Oral and Maxillofacial Pathology* 18.1 (2014): 111-113.
12. R Spreafico, *et al.* "Arterio-venous malformation of the mandible. Case report and review of literature". *Acta Otorhinolaryngologica Italica* 36.4 (2016): 333-336.
13. Fan X, *et al.* "Direct-puncture embolization of intraosseous arteriovenous malformation of jaws". *Journal of Oral and Maxillofacial Surgery* 60.8 (2002): 890-897.
14. Hyodoh H, *et al.* "Peripheral vascular malformations: Imaging, treatment approaches, and therapeutic issues". *Radiographics* 25.1 (2005): S159-S171.
15. Moure C, *et al.* "Classification des tumeurs et malformations vasculaires: fondement de la classification et intérêt clinique". *Revue de Stomatologie Chirurgie Maxillo-faciale et de Chirurgie Orale* 108.3 (2007): 201-209.

**Volume 17 Issue 11 November 2018**

©All rights reserved by Zineb Assakhi, *et al.*