

## Facial Infection due to Cosmetic Filler Injection: Literature Review and Case Report

Hamed H Al-Bargi<sup>1\*</sup> and Shuhrah Ali Alshehri<sup>2</sup>

<sup>1</sup>Consultant Oral and Maxillofacial Surgeon, Dr. Soleman Fakeeh and Hospital and Alqathi Specialist Hospital Oral and Maxillofacial Surgery Division, Jeddah, Saudi Arabia

<sup>2</sup>King Fahad Military Hospital, Jeddah Dental Department, Jeddah, Saudi Arabia

**\*Corresponding Author:** Hamed H Al-Bargi, Consultant Oral and Maxillofacial Surgeon, Dr. Soleman Fakeeh and Hospital and Alqathi Specialist Hospital Oral and Maxillofacial Surgery Division, Jeddah, Saudi Arabia.

**Received:** May 07, 2018; **Published:** July 31, 2018

### Abstract

**Background:** The increasing demands for facial region rejuvenation of the facial appearance have brought up great deal of using injectable fillers into the facial region rather than undergoing surgical intervention.

Patients are seeking more durable less adverse reactive and better cosmetics resulted into a competition for producing whole wide range of cosmetic materials trying to fulfill these desirable features. Even though the risks and complications are present whenever these materials used. The most important point is explaining to the patient all the risks and complications that possible to occur.

**Objective:** To review the types and the adverse reaction to various commonly used cosmetic injectable fillers. A case report of infection developed after injection of facial fillers and surgical intervention will be presented as an example.

**Conclusion:** Clinician should have a sound knowledge of techniques, types, and adverse reaction to approach optimal cosmetic result with minimal incidence of complications.

**Keywords:** Facial Infection; Cosmetic Filler Injection

### Introduction

Facial appearance will be affected by the aging process which presented as folds, lines, ferrous and wrinkles. These facial changes can be augmented by several factors such as ultraviolet radiation, nicotine, stress, alcohol, sleep disturbances, nutrition and genetics.

Human skin has three layers epidermis dermis and subcutaneous fat. Epidermis is the outer most layers, serves as major barrier. Cells at this layer are in a constant state of cell renewal which slows with ageing. Dermis composed of fibers and ground substances. Fibers found there are type I collagen which makes up 80% of total skin collagen, type III collagen makes up about 15% of total collagen, Elastic fibers makes up about 3% of dermis by dry weight. By aging collagen frame work weakens and elasticity of the skin will be lost. Ground substance which is composed largely by hyaluronic acid (HA). HA is a polysaccharide which is capable of retaining water and filling interstitial spaces. By aging HA will be decreased in its production and its molecular weight which result in lower water holding capacity. The third layer of the skin is subcutaneous fat which lies underneath the epidermis and gives contour to the skin and provides volume. The amount of this fat will be reduced by the aging process. Management of these facial signs can range from: over the counter creams, laser therapy, chemical peels, cosmetic fillers to surgical face lift or even a combination of these modalities.

Cosmetic fillers provide an intermediate solution between over the counter creams and traditional surgery. Most commonly used fillers are:

**Bovine Collagen:** Animal derivative injectable filler. It is available as zyderm I, zyderm II and zyplast. Zyderm I is 3.5% collagen by weight suspended in phosphate buffer physiologic saline. It is injected into the superficial papillary dermis and it needs to be overcorrected by 100% to compensate for the loss of saline. Zyderm II is 6.5% collagen by weight. It is injected into the mid dermis and needs to be overcorrected by 50%. Zyplast is 3.5% collagen cross linked by glutaraldehyde to elongate the duration of correction by inhibition of degradation by collagenase and it's injected into the deep dermis and it doesn't need any overcorrection. Two skin testes should be done two weeks apart from each other to detect any hypersensitivity reactions. The presence of lidocaine will improve the comfort of the injection. The duration of the correction is less than 6 months.

**Human collagen:** It is available as cosmoderm I, II and cosmoplast. They are purified collagen from human fibroblast cell lines. They have less immunological adverse reactions than bovine collagen in patients who had negative skin test. They don't require pretreatment skin test. The longevity is similar to bovine collagen.

**Cymetra:** Cymetra is the injectable form of micronized alloderm, decellularized processed dermal allograft. Major histocompatibility complexes I, II are removed which eliminates the immune response. No pretreatment skin test is required. It is supplied in an antibiotic supplemented media.

**Hyaluronic Acid:** Hyaluronic acid (HA) has a viscoelastic and space filling properties. Its chemical structure is uniformed throughout all the species. It has hydrophilic nature which attracts and contains water. Another unique characteristic of hyaluronic acid is isovolumic degradation which means that the volume of the gel remains unchanged until the degradation of the last molecule of HA. There are four FDA approved hyaluronic acid skin fillers: hyalaform, hyalaform plus, captique and restylane. The longevity of HA products may last up to 9 months.

**Poly-L-lactic:** Poly-L-lactic is composed of biodegradable micro particles of poly L lactic acid that are suspended in sodium carboxy methyl cellulose gel. It is available as Sculptra. Sculptra must be reconstituted 2 hours before use. The effects typically last 1 to 2 years. Although some European reports show up to five years success between injections. The potential for long term tissue reaction is likely much higher than for most other injectable fillers.

**Articoll:** Articoll is a permanent injectable filler that is composed of polymethylmethacrylate microspheres that are suspended in transport solution of 3.5% bovine collagen and 0.3% lidocaine. In a study by Lemperle, *et al.* of 118 treated with Articoll, 90% were satisfied with their treatment, and 64% reported lasting results at 2 years follow up. As non-biological filler the success of articoll depends on the amount of connective tissue reaction that mounts in response to the microspheres. Skin test is required because of the presence of bovine collagen. Results in some patient up to 10 years according to European experience.

**Radiesse:** Radiesse is primary component is calcium hydroxyapatite spheres suspended in an aqueous based gel carrier. It acts to augment volume by function as a scaffold for collagen ingrowth in soft tissue. The duration of its clinical affect has been reported to be approximately 2 years, yet it's not approved by the FDA, although clinical trial are ongoing. Radiesse is a radiopaque and may interfere with facial radiographs.

### Adverse reactions

Most of the adverse reactions due to injection of cosmetic filler are mild and transient. However, some may reach to a significant level which is the demands for intervention by either medications or surgeries or even both is required.

The adverse reactions can be divided into adverse reaction due to tissue response (inflammation, hypersensitivity and granulomatous reaction) and adverse reactions due to improper technique (infection, nodules and vascular injury).

As a result of the injury to the skin tissues, caused by injection procedures, the tissues will appear swollen, red and tender shortly post injection. These symptoms are usually mild and transient with an average duration of 4 days. The intensity of this inflammatory reaction is determined by the amount of tissue injury and the biocompatibility of the injected products. However, bruising is more frequent in patient taking aspirin or other Non-Steroidal Anti-Inflammatory agents within 4 days before injection.

Very rarely an immediate hypersensitivity reaction can occur as result of exaggerated immune response to a foreign body. Histamine will be released causing permeability, erythema, edema, pain and itching. Cases of sever anaphylactic shock has occasionally been reported. Sometimes these immune reactions delayed and known under the term of delayed hyper sensitivity reaction. Some precautions can help to minimize the incidence of such reactions. Selection of autologous tissue, skin testing for bovine collagen materials and avoidance of the fillers that contain local anesthetics and antibiotics known to cause hypersensitivity reactions to some individual.

Subclinical granulomatous inflammation is a normal tissue response to injected materials. This inflammation is a form of chronic inflammatory reaction to isolate and prevent the migration of bodies that cannot immediately be removed by enzymatic degradation or phagocytosis. Granulomas that are visible and clinically significant represent an extreme and rare manifestation of granulomatous inflammation. Granulomas occur less frequently with resorbable implants compared with more permanent products. The rate of clinically detectable granulomas is reported to vary between 0.01 and 0.1% with injected product such as collagen, HA and particulate injectables. Histological examination is required to diagnose granuloma, in addition it identifies the type of the implant causing the foreign body reaction.

There is a risk of infection with all surgical procedures. Common skin and soft tissue pathogen such as streptococcus aureus, are usually associated with early infection which can be treated successfully by short course antibiotics. It is presented clinically as single or multiple erythematous and/or fluctuant nodules. Presence of mycobacterium strongly suggests atypical or late infection that occurs 2 weeks post injection. Clinically, it is manifested as firm mildly tender mass or nodules with or without fluids. Systemic reactions (fever, leukocytosis, malaise, suppurative or purulent exudates) presence of microorganisms in the biopsy or the swap can act as diagnostic tool to confirm the infection. A recent report has linked an outbreak of *Mycobacterium abscessus* infection after soft tissue augmentation with HA derivatives. Although still uncommon, mycobacterium wound infection are being reported with greater frequency after cosmetic surgery.

Some adverse reaction may develop due to poor technique. Uneven distribution of the product can lead to non-erythematous lumps and nodules post injection. Local necrosis at the site of injection caused by vascular interruption has been noted. Also, partial vision loss has been reported due to occlusion of retinal artery. While making an injection the depth, site and the degree of corrections should be considered according to the material used [1-14].

### Case Report

Fifty-two years old Saudi female presented with right facial swelling that had been presented for three days (Figure 1).

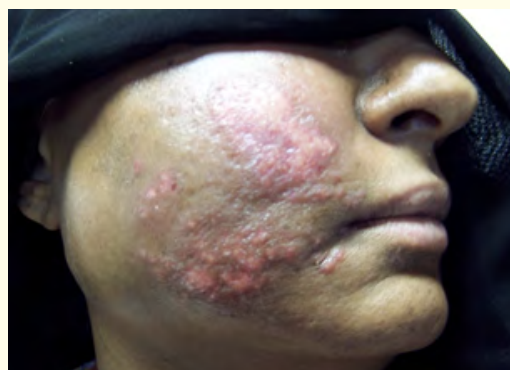

Figure 1

Eight months ago, she had been treated with injection of filler material twice with two weeks intervals for the correction of facial wrinkles. One-week post injection the patient experienced small palpable nodules that were not obvious clinically at the injection site, with no tenderness, no itching, no discomfort, and no esthetic impairments.

Three days before her visit to our clinic, she developed sever right facial swelling along the previous injected site tender fluctuant swelling. Physical examination revealed diffuse right facial swelling, tender, of skin colored with no discharge. Extraorally extended from right infra-orbital margin superiorly to corner of the mouth inferiorly and from lateral nasal surface anteriorly to the right periauricular area posteriorly. Intraorally, fluctuant soft maxillary vestibule occupying swelling of mucosal colored no discharge or bleeding teeth are in normal condition.

The findings of the CT scan shows the evidence of edematous soft tissue plans of the facial muscle at the right side of the face have a heterogeneous soft tissue component with rim enhancement is noted (Figure 2). The ft tissue plan at this region is affected. Evidence of bulky masseter muscle is seen at both sides. Evidence of cervical lymph node at this region. As a conclusion the picture is impressive of inflammatory process of the facial muscle at right side however lymphoma is to be considered.

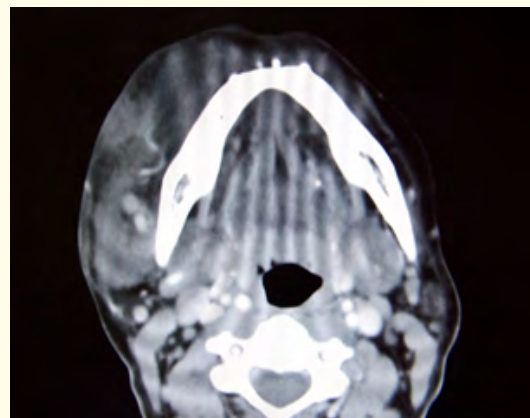


Figure 2

Anther CT was performed and two days after and they compared with the pervious CT. There was still swelling with heterogeneous enhancement areas and contain multiple pockets low attenuation of different size at the right the rest for the examination is more or less the same (Figure 3).

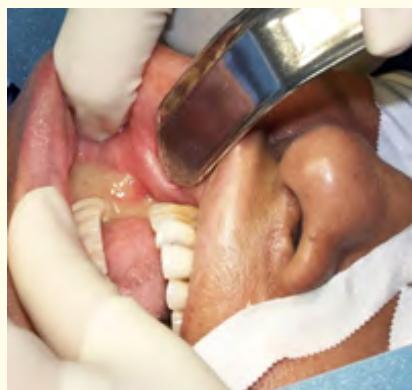

Figure 3

The swab shows many Neutrophils, no bacteria, no growth after three days culture. The patient was treated with incision and drainage and intravenous antibiotic for one week from the day of diagnosis (Figure 4). After one week the lesion had almost reduced and the patient experienced satisfaction with this result.

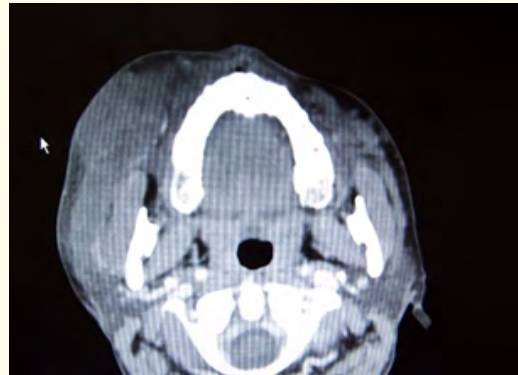


Figure 4

### Discussion

Injection of foreign body such as silicon into subcutaneous tissue evokes a host tissue response, described by Otis Allen: at first day neutrophils and small round cells predominate; at second day monocyte predominate at seven days early formation of foreign body giant cells occur; at two weeks cellular response remains mild; at four weeks monocytes differentiate into epithelioid cells and fibroblast appear; at six weeks foreign body giant cells appear and collagen deposition is increased; at 8 weeks the chronic inflammatory cells are dispersed along with heavy collagen deposition; and at six months stable giant cells and low grade cellular response is present along with more dense and reduced number of collagen and the conversion of fibroblast into fibrocytes.

### Conclusion

As there is no ideal filler material that satisfy all the desirable biological, clinical and esthetic outcome, we recommend that clinician should have a sound knowledge of techniques, types, and adverse reactions to approach optimal cosmetic result with minimal incidence of complications. Also, documentations of adverse reactions must be considered and reported. Long term evaluation of most of these material is still lacking which brought up the need for more clinical trials.

### Bibliography

1. US Census Bureau, international database. Table 094 mid-year population by age and sex (2005).
2. Lowe NJ. "Temporary dermal fillers-European experiences". In: Lowe NJ, editor. Textbook of facial rejuvenation. London: Martin Dunitz/Taylor and Francis (2002): 177-188.
3. Klein AW. "Collagen substances". *Facial Plastic Surgery Clinics of North America* 9.2 (2001): 205-218.
4. DeLustro F, et al. "A comparative study of the biologic and immunologic response to medical devices derived from dermal collagen". *Journal of Biomedical Materials Research* 20.1 (1986): 109-120.
5. De Lustro F, et al. "Reaction to injectable collagen in human subjects". *Journal of Dermatologic Surgery and Oncology* 14.1 (1998): 49-55.
6. Guyton AD and Hall JE. "Textbook of medical physiology". Philadelphia: W.B. Saunders (1996).

7. Pollack SV. "Some new injectable dermal filler materials: Hylaform®, Restylane® and Artecoll®". *Journal of Cutaneous Medicine and Surgery* 3.4 (1999): S27-S35.
8. Castrow FF II and Krull EA. "Injectable collagen implant-update". *Journal of the American Academy of Dermatology* 9.6 (1983): 224-228.
9. Piaquadio DJ, et al. "Hylan B gel (Hylaform®) as a soft tissue augmentation material". In: Klein AW, editor. *Tissue augmentation in clinical practice: procedures and techniques*. New York: Marcel Dekker (1998): 269-291.
10. Friedman PM, et al. "Safety data of injectable nonanimal stabilized hyaluronic acid gel for soft tissue augmentation". *Dermatologic Surgery* 28 (2002): 491-494.
11. Amard P, et al. "The effects of polylactic acid (PLA) (New-Fill) as therapy for lipoatrophy of the face [abstract]". 2<sup>nd</sup> International Workshop on Adverse Drug Reactions and Lipodystrophy in HIV Toronto (2000).
12. Lemperle G, et al. "Soft tissue augmentation with Artecoll®: 10-year history, indications, techniques, and complications". *Dermatologic Surgery* 29.6 (2003): 573-587.
13. Bergerat-Galley B, et al. "The value of new filler material in cosmetic and cosmetic surgery: Dermalive® and DermaDeep®". *Aesthetic Plastic Surgery* 25.4 (2001): 249-255.
14. Mullins RJ, et al. "Allergic reactions to oral, surgical and topical bovine collagen. Anaphylactic risk for surgeons". *Australian and New Zealand Journal of Ophthalmology* 24 (1996): 257-260.

**Volume 17 Issue 8 August 2018**

**© All rights reserved by Hamed H Al-Bargi and Shuhrah Ali Alshehri.**