

Review of Impacted Incisor-Canine and their Management in Children with Report of Three Cases

Bimal Chandra Kirtaniya^{1*}, Adreet Hazra², Saurav Kumar³ and Swathi Murmu³

¹*Professor and Head of the Department, Department of Pediatric Dentistry, Hazaribag College of Dental Sciences and Hospital, Demotand, Hazaribag, Jharkhand, India*

²*Postgraduate Students, Department of Periodontics, Hazaribag College of Dental Sciences and Hospital, Demotand, Hazaribag, Jharkhand, India*

^{3,4}*Postgraduate students, Department of Pedodontics, Hazaribag College of Dental Sciences and Hospital, Demotand, Hazaribag, Jharkhand, India*

***Corresponding Author:** Bimal Chandra Kirtaniya, Professor and Head of the Department, Department of Pediatric Dentistry, Hazaribag College of Dental Sciences and Hospital, Demotand, Hazaribag, Jharkhand, India

Received: May 18, 2018; **Published:** June 27, 2018

Abstract

Impacted maxillary permanent canines are the second most frequently impacted tooth in the oral cavity after third molars and a significant number of incisors impaction are also reported in the literature. The causes for impaction may be systemic or local depending upon how many teeth are involved. Usually, impactions with multiple teeth are associated with systemic causes whereas single or two teeth impaction are involved with local causes. Clinical and radiographic assessment will determine the various treatment options for such impacted tooth to be exposed for orthodontic traction or surgically removed. In the mixed dentition, retained primary tooth and supernumerary tooth should be removed for self-correction of these impacted teeth. When the impacted permanent canine and incisor are favorable for orthodontic correction, surgical removal of such tooth should be avoided in children for esthetic, function, speech and better maintenance of the dental arch. The purpose of this paper is to discuss the various etiological factors, diagnosis, treatment options, prognosis of impacted incisor-canine and to discuss the various treatment procedures with report of 3 cases. All the three cases are successfully brought into the oral cavity treated with various methods of treatment.

Keywords: *Impacted; Supernumerary; Orthodontic Traction; Surgical Exposure*

Introduction

Impacted teeth are those with a delayed eruption time or that are not completely erupted and will not erupt into the oral cavity based on clinical and radiographic assessment (Figure 1, 7 and 16). Impacted incisor (Figure 1, 7) and canine (Figure 16) in the mixed dentition or in the permanent dentition have been of interest to pedodontist and orthodontist. The permanent maxillary canine is the second most frequently impacted tooth in the oral cavity after third molar. The review of literature suggested that the mandibular second premolar is the third most common impacted tooth [1] and impaction of a primary tooth is rare. When there is impaction takes place in the primary dentition, it is almost always a mandibular primary molar. The impaction of permanent incisors in the maxilla (Figure 1,7) are frequently encountered in the practice of pediatric dentistry as the parents are often anxious and complain of missing front teeth of their kids and seek early treatment. The alignment of an unerupted incisor and canine may necessitate complicated treatment plan. In 2006, Sarah Pitt., et al. developed a "Treatment Difficulty Index" for unerupted maxillary canine which will help for case selection and treatment planning [2].

Prevalence: The impaction of incisor and canine are more in the maxilla than in the mandible and most of the canine impactions are unilateral than bilateral. The prevalence of permanent canine impaction (Figure 16) in general population is about 1% to 2% [3,4]. Among the permanent maxillary canine impaction 85% are palatal impaction (Figure 16-22) and 15% are labial impaction. The palatally impacted permanent canines rarely erupt without complex surgical and orthodontic treatment (Figure 16-22). This is because of dense palatal bone, thicker palatal mucosa and horizontal positioning of the tooth (Figure 16, 18). The palatally impacted or ectopic erupting maxillary canines occur twice as often in females than males. It is highly associated with familial history and is 5 times more common in Caucasians

than Asians. The prevalence of impacted maxillary incisor is less frequent than the impacted maxillary canine but a significant percentage of impacted incisors are reported in the literature (Figure 1-15).

Etiology

The systemic factors such as endocrine deficiency (hypothyroidism, hypopituitarism), rickets (vitamin D deficiency), febrile disease, Down syndrome, Gardner syndrome, cleidocranial dysplasia and irradiation may cause generalized impaction of teeth. In our experience two cases of delayed eruption of primary teeth were found in two children due to thyroid hormone deficiency and another case of vitamin D deficiency caused delayed eruption of permanent teeth [5]. Both genetic and local factors are associated with canine impaction [6,7] but incisor impactions are mostly associated with local causes. The local factors most commonly involved with the impaction of incisor and canine may be one or a combination of the followings:

1. Discrepancy in the tooth size and arch length ratio
2. Local trauma to the teeth or trauma to the jaws [8]
3. Presence of supernumerary tooth [9,10]
4. Long path of eruption as in the case of canines
5. Prolonged retention (Figure 7) or early loss of deciduous teeth
6. Abnormal position of the tooth bud and its eruption path (Figure 7, 8)
7. Thick fibrous mucosa developed above the erupting tooth
8. Absence of lateral incisors
9. Ankylosis of primary or permanent tooth
10. Dilacerations of the root or crown
11. The presence of alveolar cleft
12. The presence of odontomas
13. Cystic or neoplastic formation and
14. Transposition of teeth

Diagnosis

The final diagnosis is based on history of the patient, clinical findings of the impacted tooth (inspection, palpation etc.) and radiographic investigations. Early detection of impacted canines and incisors may reduce the treatment time, complexity, complications and cost. The eruption date and sequence of eruption of permanent teeth should be carefully monitored in children for ectopic eruption or impaction of teeth [11]. The patient should be examined at around 7 years of age to determine the potential for incisor impaction (eruption date for maxillary central incisor is 7 - 8 years) and for canine impaction the age is around 10 years (eruption date for maxillary canine is 11 - 12 years) [12].

Inspection

The inspection includes over retained primary incisor (Figure 7) and canine, delayed eruption of their permanent successors, asymmetry in exfoliation of primary tooth (Figure 7) and eruption of contra-lateral tooth (Figure 1, 2). Deviation of eruption sequence should be carefully noted for example both the maxillary lateral incisors erupted but one central incisor (Figure 1, 2). Impacted maxillary central incisor may cause mesial inclination of the crown of lateral incisor (Figure 1, 2) and when both the central incisors are impacted due to the presence of supernumerary tooth or teeth, there may be severe space deficiency [8]. On the other hand, impacted canine may show exaggerated distally tipped crown of lateral incisor (Figure 16); although it is a common phenomenon in the "Ugly duckling" stage of tooth development in the mixed dentition. This is because the erupting cuspid is exerting force on the distal surface of the root of lateral incisor causing its crown to flare distally. There may be rotation of lateral incisor due to presence of impacted canine. In this condition the impacted canine is placed mesially and palatally. The buccally directed force of impacted canine causes the root of lateral incisor to tip labially and the crown tip palatally producing a retro-inclined lateral incisor. The inspection should also assess the space availability in the dental arch for accommodation of the impacted incisor or canine.

Palpation

With the index fingers of both hands, buccal and lingual mucosa is palpated to assess the position of the erupting canine and incisor. The canine bulge is palpable from 1 to 1.5 years before they emerge. The absence of canine bulge after 10 years of age is a good indication that the tooth is displaced from its normal position. Therefore, ectopic eruption [11] or impaction of this tooth is suspected. A bilateral asymmetry in canine bulge in patient older than 10 years of age indicates that one canine is going to be impacted or erupting ectopically. The impacted incisor may show the presence of a retained primary tooth (Figure 7) or there may be presence of a supernumerary tooth (Figure 3) and absence of its bulge at 7 years of age as the eruption date of maxillary central incisors are around 7 - 8 years [12].

Radiographs

These include panoramic radiographs (Figure 17, 18), intra-oral periapical radiographs (Figure 7, 8) preferably with buccal object technique and a 60% maxillary occlusal film (Figure 19, 20). These radiographs will help to diagnose an impacted tooth to be located either palatally or buccally or other conditions of the impacted tooth and conditions of the adjoining teeth. The radiographs should diagnose the angle of inclination of the impacted tooth with the midline of maxilla, its depth into the bone, relation of the impacted tooth with the adjoining teeth and root resorption of neighboring teeth if any. A lateral cephalometric radiograph will help to assess the antero-posterior position of the displaced incisor tooth, its depth into the alveolus as well as its inclination and vertical location into the bone. The computed tomography (CT) and CBCT have proved to be more accurate in terms of locating the impacted cuspid and incisor in 3 dimensions, its anatomical structures, relationship with other teeth and for diagnosing root resorption of the adjacent teeth.

In 2000, Stivator N and Mandall AN conducted a radiographic study of impacted canine and found that palatally impacted canines are favorable for surgical exposure and orthodontic alignment (Figure 17-22) whereas those situated in the line of arch, high into the palate are surgically removed [13]. As the canine angulation to the midline increased, the canine was more likely to be surgically removed. In our experience with children we did a number of cases where the canines were unfavorable (Figure 17-22) for surgical exposure and orthodontic alignment [14] but the results were excellent. This was possible in children because the developing child has got growth potential, there is less calcified bone, more blood supply to the area and remodeling of bone was also more in these children unlike in adults [1].

It has been also reported that higher above the occlusal plane (deep into the bone), the canine is placed, poorer is the prognosis for orthodontic alignment. Mc Sherry [15] described this as 'the vertical rule of thirds'. A fair prognosis would be predicted for the impacted canine with its cusp tip lay at a level of half the root length of the adjacent incisor and a poor prognosis would be for it when the canine tip lay against the apical third of the adjacent incisor root. However, the best prognosis would be for the impacted canine when its cusp tip lies at the cervical third of the adjacent incisor's root. The present case of canine impaction was un-favorable which was placed palatally at the apical third of the lateral incisor that was successfully brought down into the occlusion (Figure 17-22) and aligned well.

Treatment Plan

The treatment plan of an impacted incisor and canine is basically determined by its position whether it is favorable or un-favorable into the bone. In general, the un-favorable canines and incisors are advised for surgical removal and those favorable incisors and canines are surgically exposure followed by orthodontic traction. The overall treatment options for impacted incisor-canine are as follows:

1. Interceptive removal of the retained deciduous canine or incisor [16,17].
2. Surgical exposure of the impacted tooth and orthodontic alignment [18].
3. Surgical exposure and periodic evaluation for natural eruption [19].
4. Surgical removal of the supernumerary and exposure of the impacted tooth [9,10].
5. Auto transplantation of the tooth.
6. Surgical removal of the impacted tooth followed by prosthetic replacement.
7. No treatment, but periodic evaluation for pathologic changes.

The most popular treatment options are surgical exposure and orthodontic alignment (48.9%) and surgical removal (51.1%) according to Stivator N and Mandall AN [13]. The interceptive removal of retained primary tooth (Figure 7, 8) or surgical removal of supernumerary tooth (Figure 3, 4) will cause spontaneous eruption of the impacted permanent tooth or teeth in some cases (when these impacted teeth are placed superficially) [9,10]. If the impacted tooth is deeply placed into the bone, it needs complex surgery and orthodontic traction. In recent years there is an increased trend for surgical exposure and orthodontic traction for such impacted tooth or teeth because the parents do not want to lose a permanent tooth so early age of their children.

The interceptive treatment can resolve the problem or improve the eruption status of the impacted tooth considerably (Figure 7, 8). If eruption of permanent tooth is delayed due to the presence of primary tooth, they should be extracted immediately (Figure 7, 8). Selective extraction of some primary tooth may guide the eruption of permanent tooth in occlusion. In Class I non-crowded situations where the permanent maxillary canines or incisors are impacted or erupting buccally or palatally, the preventive treatment of choice is extraction of retained primary tooth or teeth. A careful follow up to monitor the eruption of permanent tooth for about one year is a must before proceeding for surgical exposure and orthodontic traction. Power and Short in 1993 showed that interceptive extraction of primary canine completely resolves permanent canine impaction in 62% cases and in another 17% cases there was some improvement in terms of more favorable canine positioning [20]. The similar findings were observed by Ericson and Kuroi in 1988 who found that in 78% cases of palatally erupting canine normalizes within 12 months after extraction of the primary canine [17]. However, extraction of primary canine and incisor does not guarantee for complete correction or elimination of the problem (Figure 7, 8). If there is no radiographic evidence of improvement seen after one year, more aggressive treatment is to be given for the impacted tooth.

In this present paper, one impacted incisor had a retained primary tooth (case 2) which was extracted immediately and the eruption of the succeeding permanent tooth was carefully observed for more than one year (Figure 7, 8). The impacted tooth moved towards the occlusal plane but it failed to erupt into the mouth completely due to its ectopic eruption path (Figure 7-13). The other impacted incisor was having an un-erupted supernumerary tooth (case 1) which was surgically removed in the mixed dentition period (Figure 3, 4). Both these teeth required surgical exposure and orthodontic traction to bring them down into the occlusion. In a review article in 2016, Kirtaniya., et al. had shown spontaneous eruption of the permanent tooth after removal of the supernumerary tooth but no improvement was seen in this present cases [9]. Therefore, we had to change the treatment plan according to the need of the patient. Both the incisors have successfully brought into the occlusion after surgical exposure and orthodontic traction (Figure 1-15).

However, there are some other factors which will also determine the treatment options. These are as follows:

1. **Age of the patient:** The upper age of the patient should be 16 years according to Mc Sherry, 1996; but other authors recommended that the upper age can be 20 years. In a nutshell, younger the patient better is the prognosis for the impacted tooth to be brought into the occlusion. In this present investigation, all the patients were children and the age was below 13 years made us easy for their eruption into the oral cavity.
2. The radiographic position of the impacted tooth should be assessed carefully for favorable or unfavorable position of the tooth which we have discussed earlier.
3. The space available for alignment of the impacted tooth should be analyzed properly. In 85% of subject with palatal impaction of canine there is adequate space present in the dental arch [21]. However, in crowded arch where there is space deficiency, the canine is more likely to erupt in buccal position. In such condition, one may go for expansion of the dental arch or a sound premolar has to be extracted for accommodation of the impacted canine. In a rare case report, Kirtaniya., et al. in 2017 had shown arch expansion for accommodation of two impacted incisors after surgical removal of the supernumerary teeth [10]. In this present investigation also we expanded the arch for accommodation of the impacted incisor (Figure 1-6) and canine (Figure 16-22) which were brought down into the occlusion.
4. Whether first premolar can replace the canine or not? Sometimes, the first premolars erupt in the place of canines and get aligned well in the dental arch. In such circumstances some parents are not willing to extract the premolar tooth for alignment of the impacted canine. They are willing to go for surgical extraction of the impacted tooth or they want to wait and watch for any pathological changes develop with the impacted tooth.
5. The condition of the primary canine to be assessed for its retention or removal. If the primary canine is sound and there is no root resorption seen through radiograph, it can be retained in the mouth and composite build up or crown can be given for esthetic reason.
6. Patients motivation for orthodontic appliances is another factor that has to be assessed properly because many children do not want to wear orthodontic appliances for a long period of time.
7. Medical contra-indication for surgery.
8. General dental health and oral hygiene of the patient.
9. Congenitally missing tooth or tooth loss as a result of trauma.

In this paper two impacted incisors and one impacted canine were surgically exposed and orthodontic traction was given for their alignment. The surgical exposure, orthodontic traction, retention and follow up of all patients were carried out in the department of pediatric dentistry by Kirtaniya., et al. All the teeth have successfully erupted into the oral cavity. The surgical exposure of the impacted tooth and orthodontic traction for the three cases are described as below.

Case 1: Shalini, a 9 years and 6 months old girl was complaining of missing upper right central incisor (Figure 1, 2). Her left upper permanent central incisor was erupted as well as both the lateral incisors (Figure 1-6). The crown of upper right lateral incisor was tipped mesially causing loss of space for eruption of right central incisor. On radiographic examination, an unerupted supernumerary tooth was noticed (Figure 3) which was surgically removed in the mixed dentition period (Figure 4). After one year of surgery, the impacted incisor failed to erupt and then we planned to expose the impacted incisor for orthodontic traction. In this case we planned to perform open flap technique for orthodontic traction under local anesthesia in the department of Pediatric dentistry. We removed some oral mucosa and a sufficient amount of bone from the labial surface of the impacted incisor to expose it. A flat Begg's bracket was bonded on the impacted tooth for orthodontic traction. There was severe loss of space in this present case for which we had to regain some lost space before we proceeded for surgical exposure and orthodontic traction of the impacted incisor. The impacted tooth has erupted into the oral cavity and aligned well into the dental arch (Figure 1-6).

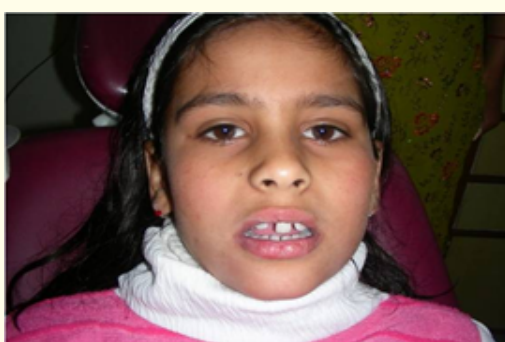

Figure 1

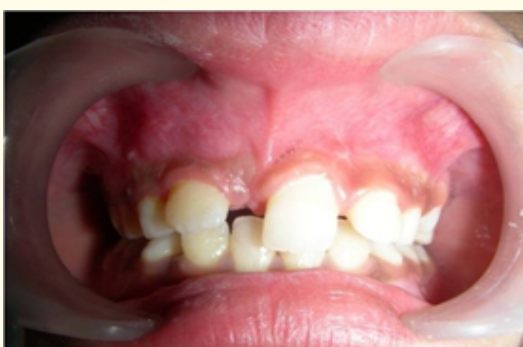

Figure 2

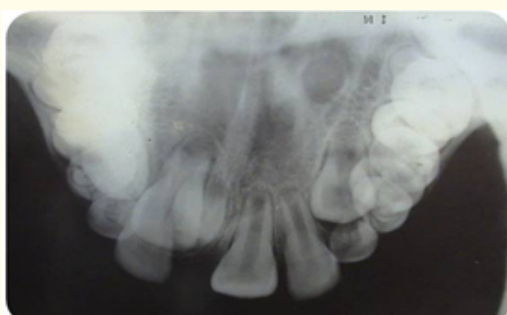

Figure 3

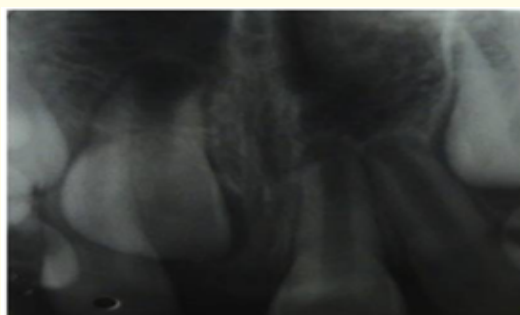


Figure 4

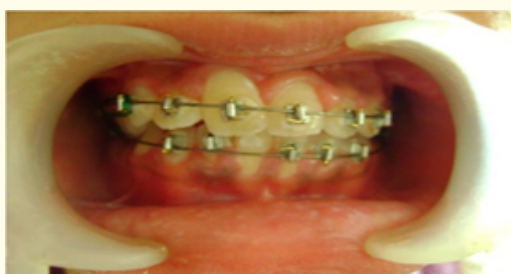

Figure 5

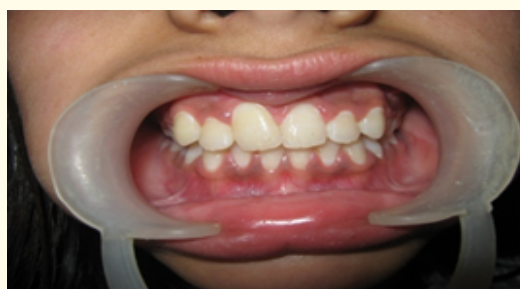

Figure 6

Case 2: Chaman Lal, a 10 years old boy was complaining of not falling his upper left deciduous central incisor (Figure 7). The maxillary right permanent central incisor and both the permanent lateral incisors were erupted (Figure 9, 10). On routine radiographic examination the impacted permanent incisor was located high into the maxilla (Figure 7, 8) and its eruption path was ectopic. There was a retained primary incisor in this present case which was extracted immediately (Figure 7, 8). We observed eruption of the impacted permanent incisor for more than one year after extraction of the deciduous tooth but it failed to do so. In this case there was abundance of space present in the dental arch for accommodation of the impacted incisor. The surgical procedure was carried out in the department of Pediatric dentistry under local anesthesia but a closed flap technique was followed for this case (Figure 11, 12). After removal of sufficient amount of bone from the labial surface of the impacted incisor, a flat Begg's bracket was bonded on it (Figure 11) and a sufficient amount of e-chain was attached to it (Figure 11, 12) for orthodontic traction. The tooth was successfully brought into the dental arch (Figure 7-15) after one year of orthodontic treatment.

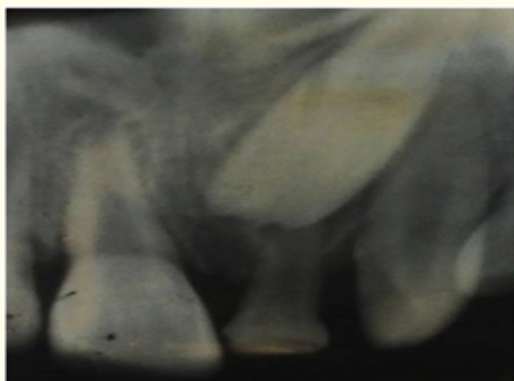


Figure 7

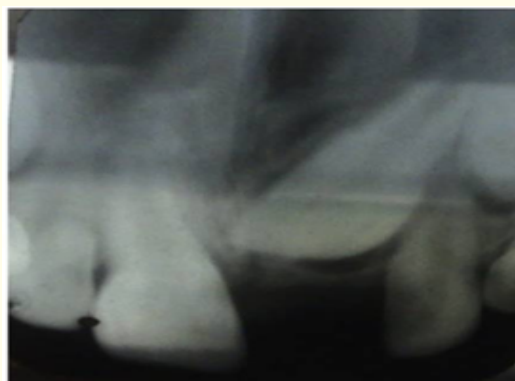


Figure 8

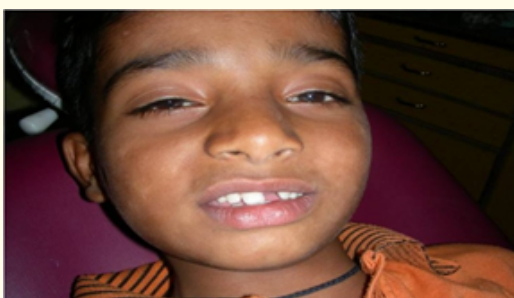

Figure 9

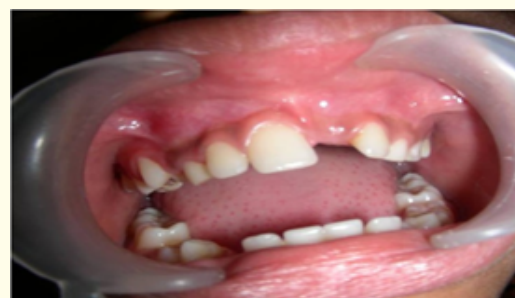

Figure 10

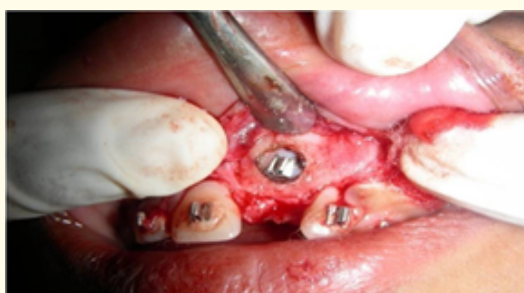

Figure 11

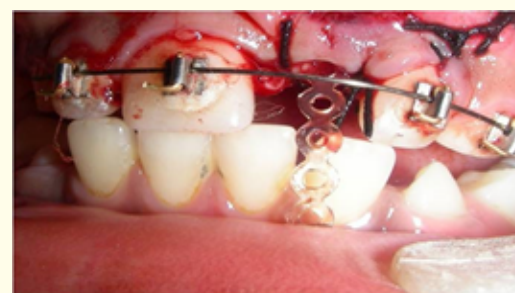

Figure 12

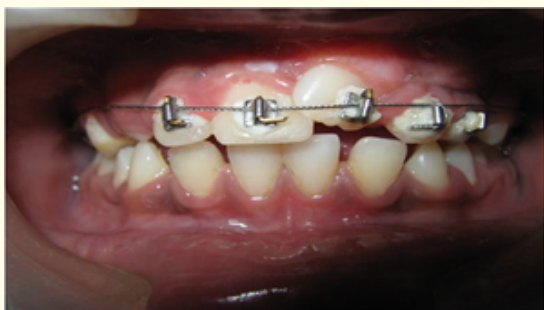

Figure 13

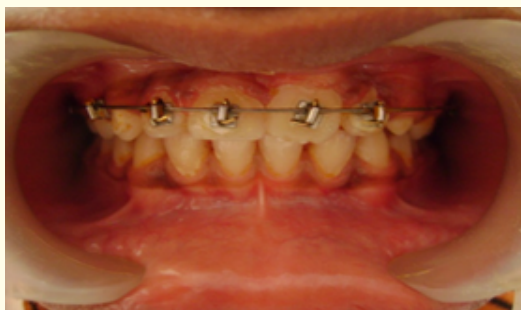

Figure 14

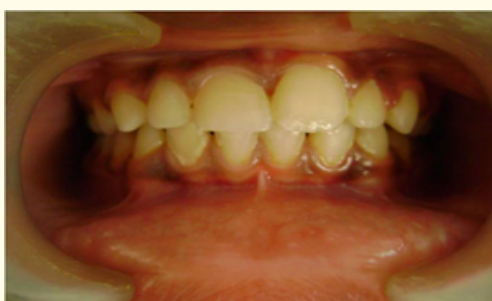

Figure 15

Case 3: Rahul, a 13 year old boy was complaining of missing upper right canine. He had a trauma and lost his upper right central incisor (Figure 16). The crown of right lateral incisor was distally tipped causing space loss for the canine (Figure 16). There was mesial inclination of the crown of first premolar as well. Therefore, almost all the canine space was lost (Figure 16, 18) due to tooth migration. In this case also we had to regain some lost space for accommodation of the impacted canine before surgical procedure and orthodontic traction was carried out (Figure 20). After achieving adequate anesthesia, a full thickness of palatal mucoperiosteal flap was raised from the left permanent first molar on one side to the right permanent first molar on the other side. We removed a sufficient amount of bone from the palatal side of the impacted canine to expose it and a curved Begg's bracket was bonded on it. A sufficient length of E-chain was attached with the bracket for orthodontic traction (Figure 20) and the flap was then closed with sutures. We applied mild orthodontic force (50 to 60 grams) for traction of the impacted tooth. In the long run, the elastic chain was re-inforced with thread elastic and later on NiTi wire was used. Once the tooth had erupted and bonding could have been done, the palatal bracket was replaced by a labial bracket (Figure 21). The impacted canine was brought into the oral cavity and aligned well in the dental arch. A removable partial denture prosthesis was given in place of the lost incisor (11) as a retainer till permanent prosthesis would be given (Figure 16-22).

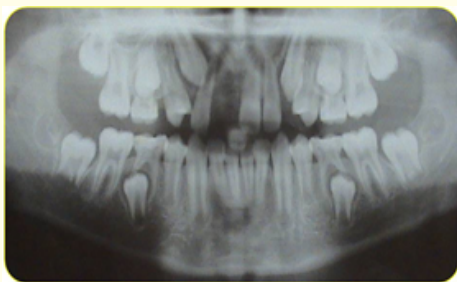


Figure 16

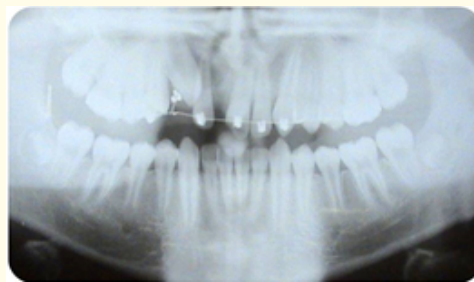


Figure 17

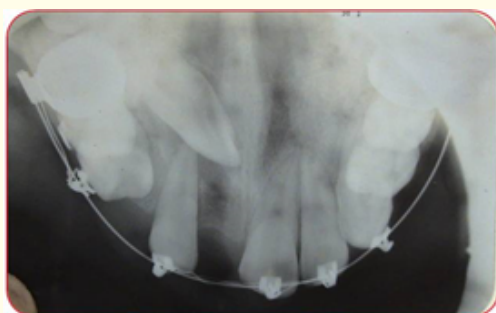

Figure 18

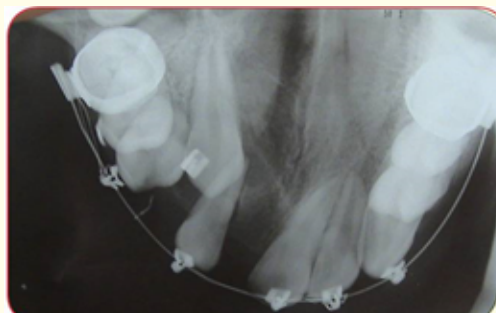

Figure 19

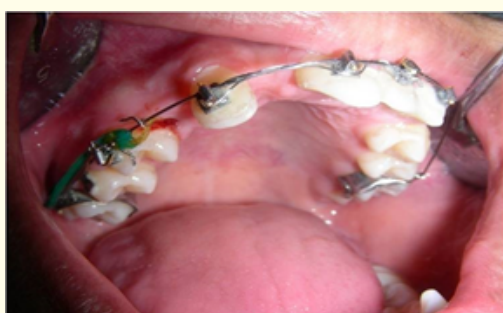

Figure 20

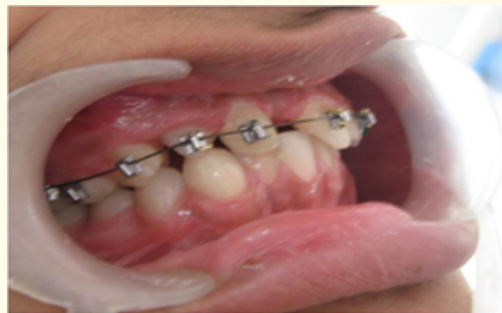

Figure 21

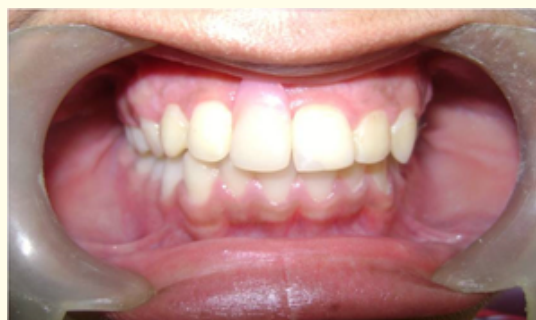

Figure 22

Discussion

The supernumerary tooth usually occurs in the anterior region of the maxilla and its prevalence is about 1% to 3% in the white people. These are extra teeth commonly found in the permanent dentition than the primary teeth. There are four types of supernumerary teeth found in children namely conical, a tooth like (resembling a lateral incisor or a premolar), tuberculate and odontomas [22]. In this present investigation a tooth-alike supernumerary was present in relation to the impacted incisor (Figure 1-6). The supernumerary tooth may cause many problems to the permanent tooth for example it may cause impaction of an incisor (Figure 3) or it may cause deflected path of eruption of the permanent tooth or other complications. In our review of literature it is suggested that about 56 - 60 percent of supernumerary teeth cause impaction of permanent incisor [23]. Sometimes, a mid-line diastema in the maxilla is the result of an impacted mesiodens. Therefore, they should be extracted to prevent impaction of incisor tooth or creation of malocclusion or other complications [9,10]. After surgical removal of the supernumerary tooth, sufficient time must be given for bone formation and also to allow the impacted tooth to erupt spontaneously.

The timing of supernumerary tooth extraction has been a controversial issue, but most authors use extraction during the early mixed dentition period (Figure 3, 4). Late intervention may cause decrease arch space [10] and decreases the possibility of spontaneous eruption of the impacted permanent tooth. In such cases complex surgical exposure and orthodontic traction is required. In this present case the supernumerary tooth was removed in the early mixed dentition period and the permanent tooth failed to erupt even after 1 year of surgery led us to go for surgical exposure and orthodontic traction of the impacted tooth (Figure 1-6). The other case of impacted incisor (case 2) had a retained primary tooth due to its ectopic eruption path [11] led us for surgical exposure and orthodontic traction for it (Figure 7-15). The impacted incisors of case 1 and case 2 will not erupt spontaneously as there was space loss for case 1 and ectopic eruption path [11] was seen in case 2 (Figure 7). Both the teeth have aligned well into the dental arch although we performed two different types of surgery for these impacted teeth and both these types of operations are successful to us (Figure 1-15).

We performed open window technique for the case 1 and closed flap technique for the other two cases (case 2 and 3) as it is easy and convenient to control tooth movement under the flap. There are some advantages and disadvantages in both types of operations [24]. In case of open window technique, there are chances of loss of attached gingiva around the tooth to be moved and there may be damage to the attachment apparatus. The esthetic will be better in case of closed flap technique than the open window surgery as there will be formation of good amount of attached gingiva [25,26]. Vermette, *et al.* in 1995 also suggested that open flap technique have more unesthetic sequelae than closed flap technique [24]. However, if the attachment apparatus is lost during the course of orthodontic traction, we may have to do another operation for bonding a bracket (or an attachment) on the impacted tooth in closed flap technique which did not happen in these present investigations (Figure 1-22). When the impacted tooth is superficially placed one may consider for open flap technique and when it is deeply placed into the bone, closed method is better. We do not recommend excessive cutting of bone which may produce defect in the alveolus and/or in the oral mucosa. Therefore, bone cutting should be minimum to expose the impacted tooth either from labial side (Figure 11-12) or from palatal side (Figure 16-22) to receive an attachment apparatus.

An unerupted or impacted canine may be displaced from its correct position in three dimensions: horizontally, vertically or buccopalatally. The labially impacted canines are usually vertical whereas the palatally impacted canines are mostly horizontal (Figure 17,19). In many instances it is necessary to extract a sound premolar in order to provide sufficient space for canine alignment. In this present case of canine impaction (case 3), there was severe space loss seen due to distal inclination of lateral incisor and mesial inclination of the first premolar of the impacted side (Figure 16, 18). We had not extracted first premolar but created space for accommodation of the impacted permanent canine in the dental arch because the boy had already lost one central incisor earlier in an accident. The impacted canine was unfavorable and placed palatally near the apex of the adjacent lateral incisor [15] (Figure 16, 18) which was successfully brought into the occlusion after two years. The prolong duration of treatment in case 3 was because of distance the tooth has to travel from intra-osseous state into the oral cavity but we brought it down into the occlusion successfully (Figure 16-22). This may be possible in children as there is more growth potential, more vascularity, less calcified bone and remodeling of bone is more in young patients than adults. Kokich in 2010 also having similar view with our observations and stated that in children or adolescent patients, the management of palatally impacted canines can be predictable, stable and good esthetics can be achieved [27].

In 2004, Kokich discussed the various complications associated with surgical exposure of impacted canines and described that if correct surgical procedures are applied for exposure of impacted canine, it becomes easy for the orthodontist to bring the tooth into the oral cavity and esthetics will be also good [28]. We are in agreement with his observation and follow the standard protocol for surgical exposure. The advantage of raising a palatal flap for case 3 for surgical exposure and orthodontic traction is that it is thick where the impacted tooth will remain under the flap during the entire course of orthodontic traction unlike labial flap which may become perforated during orthodontic traction [29] and there may be development of other complications. Chawla and Kapur in 2009 reported a case of incisor impaction where the authors planned for an open window of surgical exposure and orthodontic traction for the impacted tooth [30]. The authors claimed that there was no problem for orthodontic alignment of the impacted tooth but there was development of gingival growth

around the same tooth during the course of orthodontic traction for which they have to perform another operation. As we have already discussed above about the various advantages and disadvantages of two types of operations, we can claim that closed flap technique is better.

In this paper we have successfully preserved the various impacted teeth affected by various pathological conditions and brought them down into the occlusion. All the teeth are maintaining vitality and there was no external root resorption seen in any tooth of the 3 cases. There may be bone loss around adjacent lateral incisor or premolar or canine according to Mathews and Kokich [31,32] which did not happen in these present investigations. In 1994, Woloshyn., et al. conducted a retrospective study of pulpal and periodontal reactions to orthodontic alignment of impacted canines and found that 40 percent of the previously impacted canines exhibited some sorts of relapse [33]. In our present investigation there was no relapse seen even after 10 years and the dento-alveolar growth of all patients were good. This is possible in children because of more growth potential and also we applied light force of 50 - 60 gm for extrusion of tooth to bring the impacted tooth down into the occlusion. The use of light force will also help in appearance of good gingival contour at the end of orthodontic treatment. In 2016 Kirtaniya., et al. have shown closed eruption technique for a palatally impacted maxillary canine with formation of excellent gingival contour after completion of orthodontic treatment [14].

The maxillary incisors and canines are the most prominent tooth in the anterior part of the mouth which helps in aesthetic, phonetic and they also help in developing the self-esteem of the growing children. Missing of such teeth may be the target for teasing by other children which will have adverse effect on psychological development to them. The pedodontist must diagnose the condition as early as possible and solve the problems soon to minimize the psychological trauma to the growing children. This is very much important to the growing children for his chewing, esthetic, speech and for better maintenance of the dental arch during the most active period of growth and development. Surgically removal of impacted incisor and canine should be avoided in children as there is growth potential present in these patients [1,27]. We the pediatric dentist can do various types of preventive and interceptive procedures (extraction of retained primary tooth, surgical removal of supernumerary tooth, placemen of space maintainer or regainer for loss of space etc.) during the mixed dentition period to prevent impaction of permanent tooth or teeth in children and adolescent. Whenever needed, a minor orthodontic treatment can be done to align these malposed impacted teeth to bring them down into the dental arch as we have done it for several cases in many years of practice of pediatric dentistry. It needs lots of hard work, patient's co-operation, scientific innovation to bring an impacted tooth into the oral cavity but we have saved the million dollar canine smile for the unfortunate boy who lost a maxillary central incisor in an accident.

Conclusion

The management of impacted incisor and canine necessitate proper diagnosis and treatment plan for their eruption. Timely extraction of deciduous tooth and surgical removal of supernumerary tooth may help for spontaneous eruption of the impacted tooth or it may improve the condition. A thorough clinical and radiographic knowledge is essential before surgical exposure and orthodontic traction is to be given for an impacted tooth which has to be brought down into the oral cavity. If indicated, impacted canines and incisors should be preserved in all circumstances and not surgically removed in children as we have done it for several cases.

Acknowledgement

We are very much thankful to all children who have come regularly for correction of their teeth and for post-operative check-up.

Bibliography

1. McNamara C and McNamara TG. "Mandibular premolar impaction: 2 case reports". *Journal of the Canadian Dental Association* 71.11 (2005): 859-863.
2. Pitt S., et al. "Treatment difficulty for unerupted maxillary canines". *The European Journal of Orthodontics* 28.2 (2006): 141-144.
3. Bass TB. "Observation on the misplaced upper canine tooth". *Dental Practitioner and Dental Record* 18.1 (1967): 25-33.
4. Rayne J. "The unerupted maxillary canine". *Dental Practitioner and Dental Record* 19.6 (1969): 194-204.
5. Gupta S., et al. "Delayed Teeth Eruption a Mirror to Systemic deficiency of Vitamin D". *Indian Journal of Dental Sciences* 7 (2015): 56-59.
6. Peck S., et al. "The palatally displaced canine as a dental anomaly of genetic origin". *Angle Orthodontist* 64.4 (1994): 249-256.

7. Chaushu S, et al. "Dental morphologic characteristics of normal versus delayed developing dentitions with palatally displaced canines". *American Journal of Orthodontics and Dentofacial Orthopedics* 121.4 (2002): 339-346.
8. Chaushu S, et al. "Maxillary incisor impaction and its relationship to canine displacement". *American Journal of Orthodontics and Dentofacial Orthopedics* 124.2 (2003): 144-150.
9. Kirtaniya BC, et al. "Review of Supernumerary teeth and their Management in Children". *International Journal of Oral Health and Medical Research* 3.2 (2016): 32-37.
10. Kirtaniya BC, et al. "Tuberculate Supernumerary Teeth And Its Management-A Rare Case Report". *Journal of Dental Health, Oral Disorders and Therapy* 7.2 (2017): 00233.
11. Kirtaniya BC, et al. "Ectopic Eruption of Teeth and their Management in Children: Review of Literature and Case Reports". *EC Dental Science* 17.4 (2018): 409-418.
12. McDonald Avery Dean. *Dentistry for the Child and Adolescent*. Local, systemic and congenital factors that influence tooth eruption (2004): 175-202.
13. Stivator N and Mandall NA. "Radiographic factors affecting the management impacted upper canines". *Journal of Orthodontics* 27.2 (2000): 169-173.
14. Kirtaniya BC, et al. "Surgical Exposure and Orthodontic Positioning of a Palatally Impacted Maxillary Canine". *International Journal of Oral Health and Medical Research* 3.4 (2016): 60-65.
15. McSherry PF. "The assessment of and treatment options for the buried maxillary canine". *Dental Update* 23.1 (1996): 7-10.
16. Ericson S and Kuro J. "Radiographic Examination of ectopically erupting maxillary canines". *American Journal of Orthodontics and Dentofacial Orthopedics* 91.6 (1987): 483-492.
17. Ericson S and Kuro J. "Early treatment of palatally erupting canines by extraction of primary canines". *European Journal of Orthodontics* 10.4 (1988): 283-295.
18. Bishara SE. "Impacted maxillary canine: a review". *American Journal of Orthodontics and Dentofacial Orthopedics* 101.2 (1992): 159-171.
19. Ohman I and Ohman A. "The eruption tendency and changes of the direction of impacted teeth following surgical exposure". *Oral Surgery, Oral Medicine, Oral Pathology* 49.5 (1980): 383-389.
20. Power SM and Short MB. "An investigation into the response of palatally displaced canines to the removal of deciduous canines and an assessment of factors contributing to favourable eruption". *British Journal of Orthodontics* 20.3 (1993): 217-223.
21. Jacoby H. "The etiology of maxillary canine impactions". *American Journal of Orthodontics* 84.2 (1983): 125-132.
22. Howard RD. "The unerupted incisors. A study of pos-eruptive eruption history of incisors delayed in their eruption by supernumerary teeth". *Dental Practitioner and Dental Record* 17.9 (1967): 332-341.
23. Kuro J. "Early treatment of eruption disturbances". *American Journal of Orthodontics and Dentofacial Orthopedics* 121.6 (2002): 588-591.
24. Vermette M, et al. "Uncovering labially impacted teeth: apically positioned flap and closed eruption technique". *Angle Orthodontist* 65.1 (1995) 23-32.
25. Becker A, et al. "Closed eruption surgical technique for impacted maxillary incisors postorthodontic periodontal evaluation". *American Journal of Orthodontics and Dentofacial Orthopedics* 122.1 (2002): 9-14.
26. Uematsu S, et al. "Orthodontic treatment of an impacted dilacerated maxillary central incisor combined with surgical exposure and apicoectomy". *Angle Orthodontist* 74.1 (2004): 132-136.
27. Kokich VG. "Preorthodontic un-covering and autonomous eruption of palatally impacted canines". *Seminars in Orthodontics* 16 (2010): 205-211.
28. Kokich VG. "Surgical and orthodontic management of impacted maxillary canine". *American Journal of Orthodontics and Dentofacial Orthopedics* 126.3 (2004): 278-283.

29. Amit Khera, *et al.* "Orthodontic Management of impacted central incisor: A clinical challenge". *Journal of Indian Orthodontic Society* 51 (2017): 46-50.
30. Chawla HS and Kapur A. "Orthodontic management of faciolingual horizontally impacted incisor". *Journal of Indian Society of Pedodontics and Preventive Dentistry* 27.1 (2009): 65-69.
31. Mathews DP and Kokich VG. "Palatally impacted canines: The case for preorthodontic un-covering and autonomous eruption". *American Journal of Orthodontics and Dentofacial Orthopedics* 143.4 (2013): 450-458.
32. Hansson c and Rindler A. "Periodontal conditions following surgical and orthodontic treatment of palatally impacted canines: a follow up study". *Angle Orthodontist* 68.2 (1998): 167-172.
33. Woloshyn H., *et al.* "Pulpal and periodontal reactions to orthodontic alignment of impacted canine". *Angle Orthodontist* 64.4 (1994): 257-264.

Volume 17 Issue 7 July 2018

© All rights reserved by Bimal Chandra Kirtaniya., *et al.*