

The Use of Stereolithography in Surgical Implant Placement, A Case Report

Zainab H Sulaimani* and Fadia Darwiche

The North Centre of Dental Specialties, Department of Dental Implantology, Jeddah, Saudi Arabia

***Corresponding Author:** Zainab H Sulaimani, The North Centre of Dental Specialties, Department of Dental Implantology, Jeddah, Saudi Arabia.

Received: May 14, 2018; **Published:** June 27, 2018

Abstract

Rapid prototyping is a method of producing solid physical copies of human anatomy from 3D computer data. Stereolithography is the most widely known and used rapid prototyping [1,2] and the one most often technique used to generate medical models and computer-generated surgical guides for osteotomy site preparation in dental implant surgery [2,3]. SurgiGuides are the computer-designed and stereolithography-generated surgical guides used during osteotomy site preparation. Stereolithography interfaces a patient's 3D CT study with the SimPlant plan. Made of acrylic resin, SurgiGuides contain one or more steel drilling sleeves, each of a defined diameter and with minimal tolerance, to control and ensure the accuracy of each osteotomy site preparation in two planes- bucco- lingually and mesiodistally. SurgiGuide design is based on the presurgical 3D positioning of implant icons using SimPlant (Materialise) interactive software, which transfers the prosthetically driven surgical treatment plan onto the CT. SurgiGuides can be supported by bone, teeth, teeth and mucosa, mucosa, or supragingival pre-existing dental implant components and mucosa. This article presents a case for teeth and mucosa supported implant placement for mandible, and bone supported for maxilla for the aim of complete oral rehabilitation with implants.

Keywords: *Computer-Aided Design; Computer-Assisted Manufacture; Surgical Template; Guided Implant Surgery; Implants*

Introduction

With the introduction of dental computed tomography (CT) in 1987, the method by which patients were evaluated for the placement of dental implants changed dramatically [4,5]. For the first time, the dental implant surgeon was able to understand regional anatomy and its influence on surgical decision-making preoperatively. This radiographic modality was superior to all other forms of dental radiographs in both accuracy and anatomic insight. However, two significant problem needed to be addressed. First no prosthetic information was available in the CT study; second, there was no means to transfer the prosthetic information and treatment plan directly to the patient at the time of surgery, and this disconnect between diagnostics and treatment prevented broader professional acceptance. Nevertheless, as the demand for more esthetic and life like restorations increased, clinicians worldwide used surgical guides to facilitate more accurate placement of dental implants. The use of stereolithographic medical modeling coupled with three-dimensional (3D), patient-specific CT information makes it possible to fabricate bone-, tooth-, tooth and mucosa and exclusively mucosa-supported surgical guides (i.e. SurgiGuides). SurgiGuides allow osteotomy site preparation to be performed in a more precise and efficient manner and, in certain instances, with less patient discomfort than conventional implant surgery [6].

Case Report and Discussion

A 58-years-old Saudi female came to the king Fahd general Hospital in Jeddah presented with chief complaint of unesthetic appearance from old prosthetic gold crown and mobility of maxillary anterior teeth. Her medical history was good general health (ASA 1). Her dental history revealed missing maxillary and mandibular teeth due to progressive periodontitis (Figure 1).

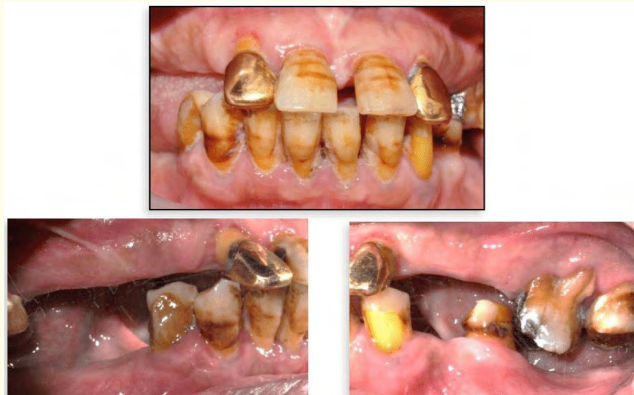

Figure 1: Pre-operative case.

After a careful evaluation of the case and the execution of diagnostic radiographic examinations (OPG and PA's) (Figure 2) Proposed treatment plan, extraction of all maxillary and mandibular hopeless teeth except teeth #33 and #43 and full mouth implant prosthetic rehabilitation of the maxillary and mandibular arches. BioHorizon® (BIOHORIZONS IMPLANT SYSTEMS INC, Alabama, United States), tapered internal implant laser-lock; for both arches, followed by the relative prosthetic rehabilitation. The patient also needed to use a temporary prosthesis throughout the treatment period for professional reasons [7,8].

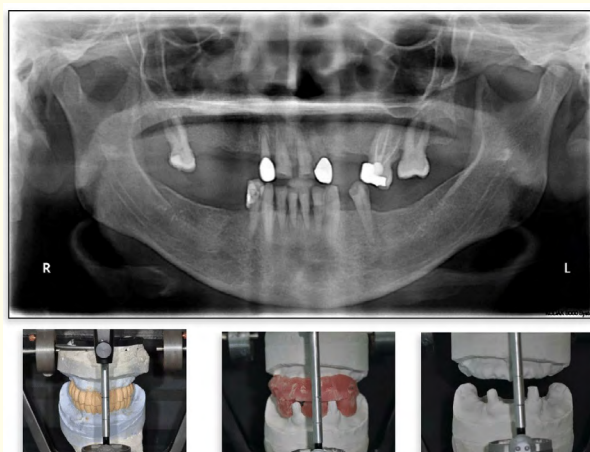


Figure 2: Diagnostic Tools.

After recording the vertical dimension of occlusion (DVO) and mounting in articulator by means of face bow and its calibration, complete removable denture for the maxillary arch and a partial removable denture for the mandibular arch was constructed [9]. These prostheses in order to recover the masticatory function and aesthetics after the extractions. By means of computed tomography, to evaluate the amount of bone remaining after the extraction of the compromised teeth and I have planned two surgical guide (Figure 3) in order to locate implant sites, to evaluate bone quality, and suitability for prosthetic rehabilitation choice for the patient. Radio-opaque markers used in the denture for computerized tomography study of the dental arch for implant placement planning was evaluated for visibility, ease of analysis in relation to the alveolar ridge crest and relative to its applicability as a radiographic guide [10].

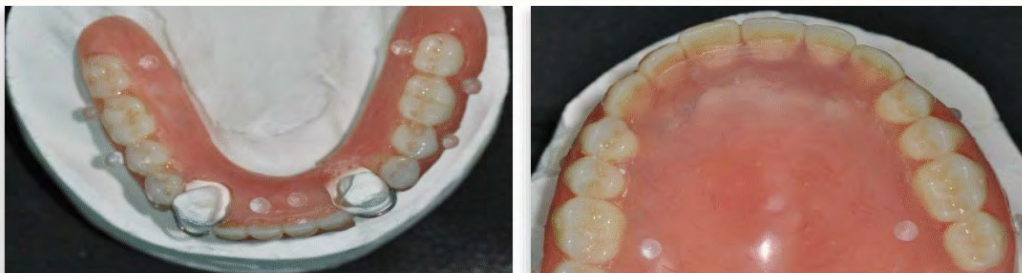

Figure 3: Scanning Appliance.

CT Scan with scanning appliance in place (Figure 4) the resulting DICOM files are processed to be converted into SimPlant format, which has been done for maxilla and mandible (Figure 5).

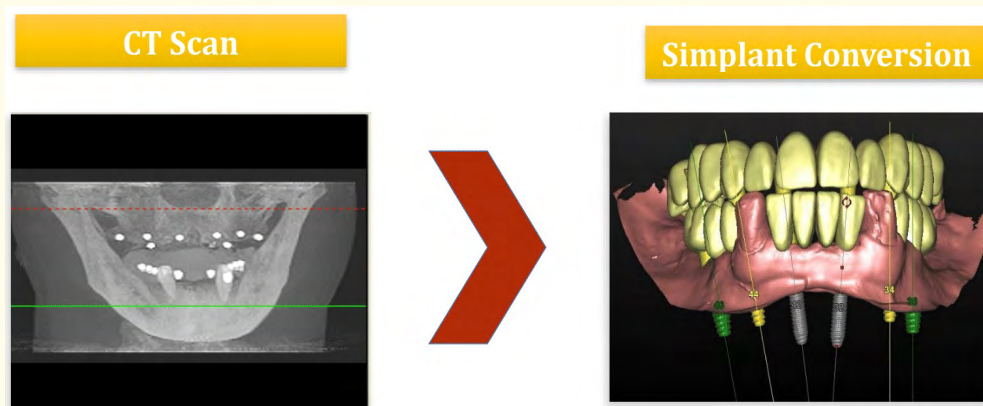


Figure 4: CT scan with appliance.

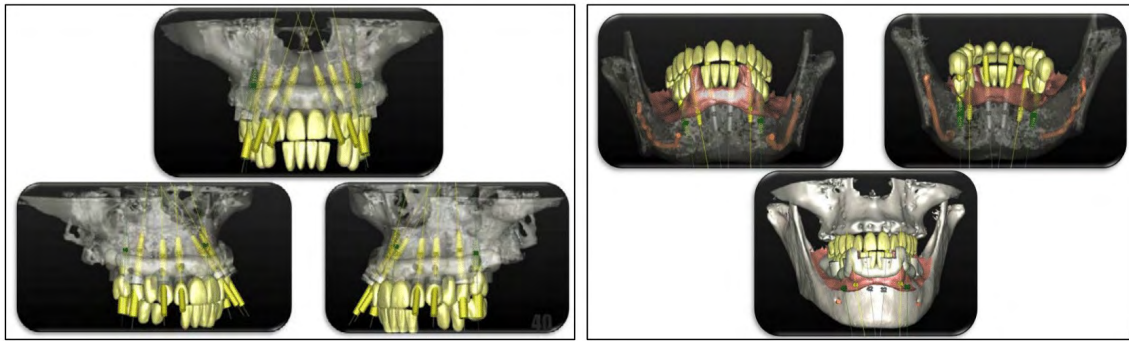


Figure 5: CT scan conversion to Simplant for maxilla and mandible.

A Surgical guide was fabricated (Figure 6). Surgery was done by placement of implants and abutments in the Maxilla with Bone-Supported Surgi Guide with 8 implants. Mandible with Teeth-and mucosa-supported Surgi Guide with 6 implants using BioHorizon® (BIOHORIZONS IMPLANT SYSTEMS INC, Alabama, United States), tapered internal implant laser-lock, for both arches (Figure 7).

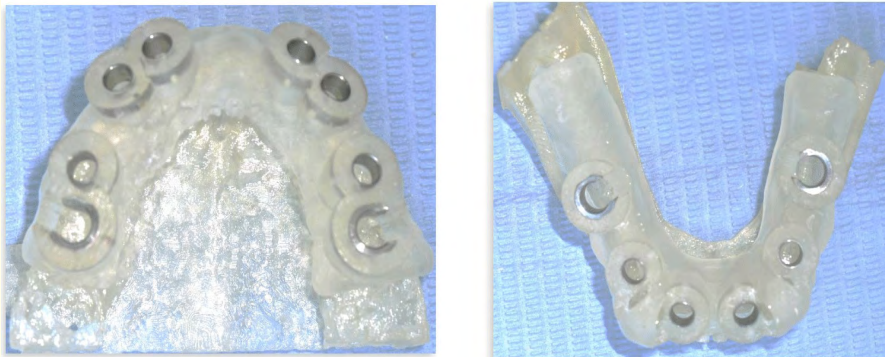

Figure 6: Maxillary and Mandibular SurgiGuide.

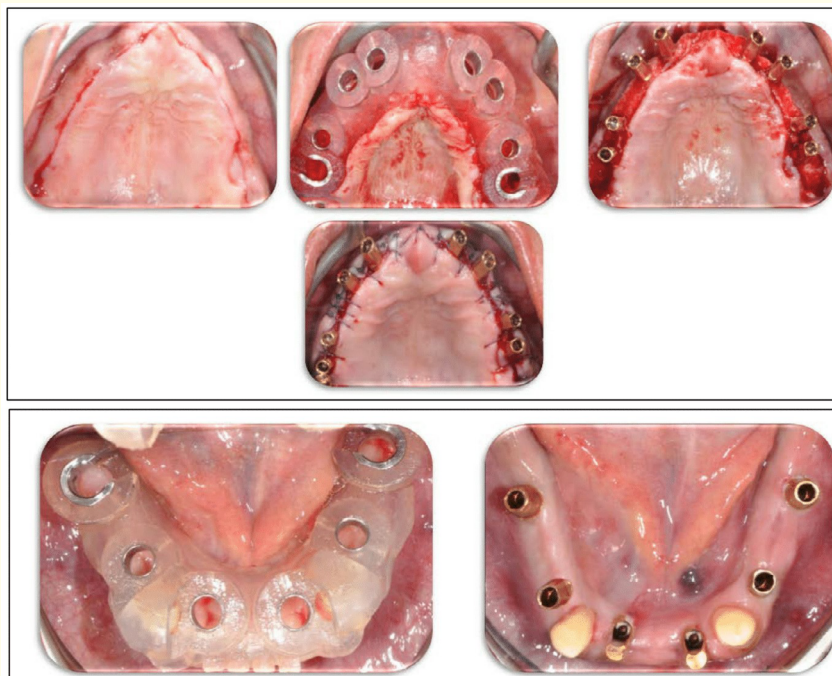

Figure 7: Surgical Procedures for Maxillary and Mandibular arches.

Immediate Non-Functional Loading and Placement of Provisional Prosthesis have been done (Figure 8). As “Five –Year Prospective Study of Immediate/Early Loading of Fixed Protheses in Completely Edentulous Jaws with a Bone quality-based implant system” the author summarized the study using a bone quality-based implant system (BioHorizons Implant System). It was concluded that no implant failure occurred and crestal bone loss values were similar to or less than value reported with two stage approach. This may be related to the number of implants, implant design, and/or the surface condition of the implant loading [11]. Followed by taking upper and lower implant level impression (Figure 9), then placement of definitive prosthesis following appropriate healing period: Early loading (Figure 10).

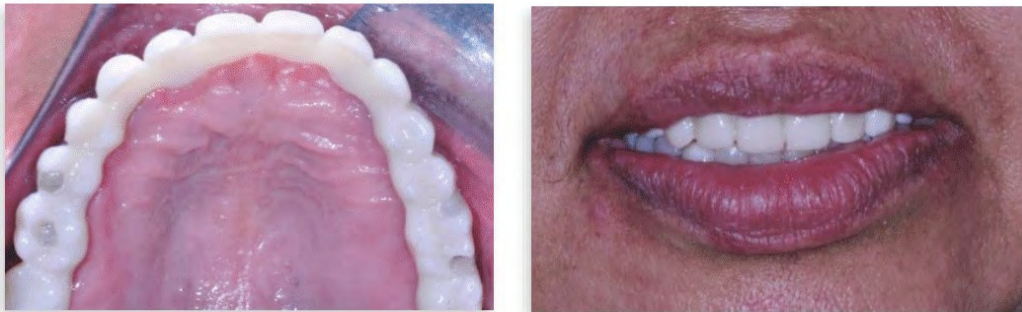

Figure 8: Immediate Provisional Loading.

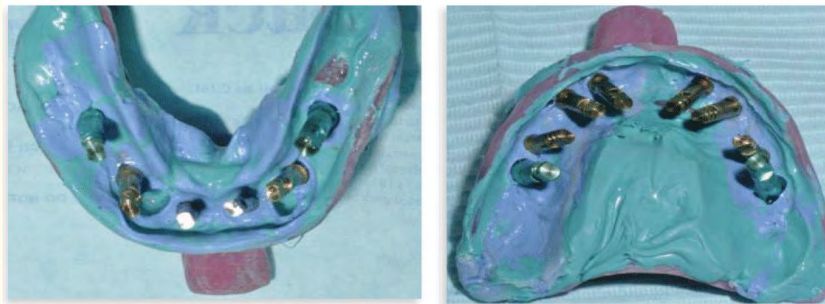


Figure 9: Upper and lower implant level impression.

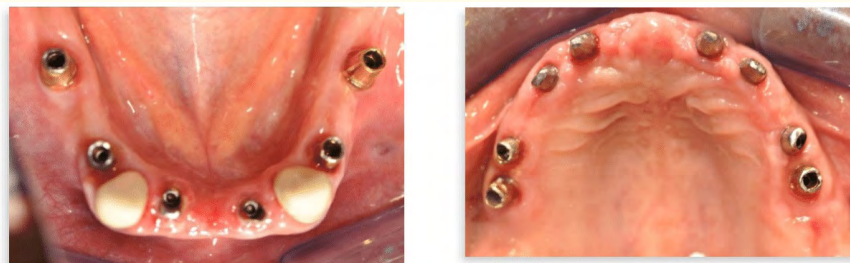

Figure 10: Abutment insertion.

After jaw relation record, and teeth try-in, metal substructure try in was done. Cement-Retained Implant Restorations were placed (as the study "Screw-Versus Cement-Retained Implant Restorations: Current Concepts" indicated that No differences were found between the two types of prosthesis in terms of implant survival or success rates. Prosthesis success rates (> 72 months), cement-retained prostheses demonstrated a 93.2% success, compared with 83.4% with screw-retained prostheses. It is generally agreed that the current trends to favor cement-retained implant restorations for their superior esthetics, occlusion, ease of fabrication, and reduced chairside time [12]. Finally; oral Hygiene instructions and night guard were given (Figure 11 and 12).

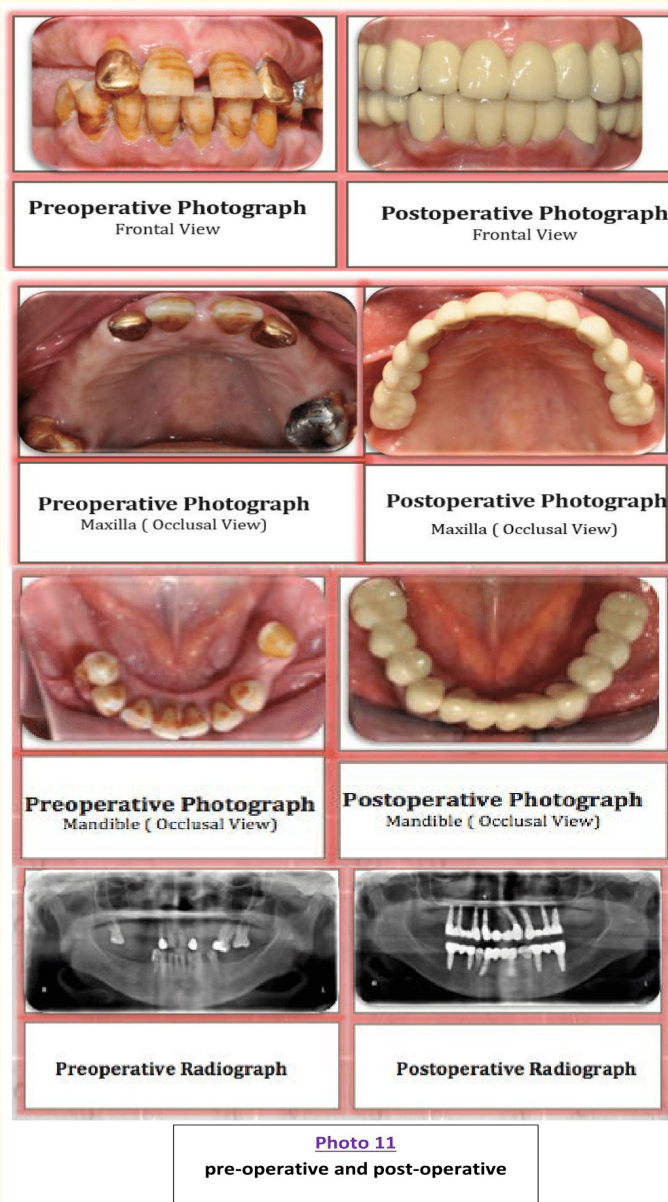


Figure 11: Pre-operative and post-operative.

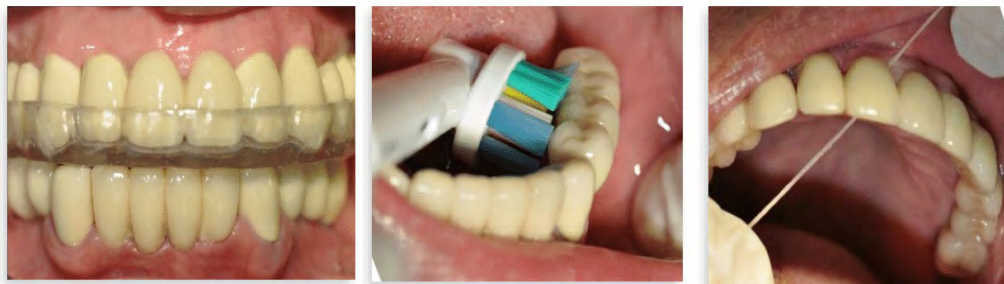

Figure 12: OHI and night guard construction.

Conclusion

The direct benefits of Stereolithography imaging to the dental implant patient include (1) a better understanding of the treatment requirements and commitment needed for successful therapy; (2) a significant reduction in surgical time and a proportional decrease in postoperative pain, discomfort, and swelling; and (3) a better understanding of anticipated outcomes and alternative types of treatment. (4) Accuracy and reliability are two of the distinguishing characteristics of the stereolithographic process.

Bibliography

1. Popat A. "Rapid prototyping and medical modeling". *Phidas Newsletter* 1 (1998): 10-12.
2. Poukens J., et al. "Study on the accuracy of stereolithographic surgical guides in dental". *Newsletter* 8: 8-14.
3. Swaelens B. "ng templates for dental implantology. *Phidas Newsletter* 3 (1999): 10-12.
4. Schwarz MS., et al. "Computer tomography Part II. Preoperative assessment of the maxilla for endosseous implant surgery". *International Journal of Oral and Maxillofacial Implants* 2.3 (1987): 143-148.
5. Schwarz MS., et al. "Computer tomography. Part I. Preoperative assessment of the mandible for endosseous implant surgery". *International Journal of Oral and Maxillofacial Implants* 2.3 (1987): 137-141.
6. Sarment D., et al. "Accuracy of implant placement with a stereolithographic surgical guide". *International Journal of Oral and Maxillofacial Implants* 18.4 (2003): 571-577.
7. Spinelli D., et al. "Full rehabilitation with nobel clinician® and procera implant bridge®: Case report". *Oral and Implantology* 6.2 (2013): 25-36.
8. Meleo D., et al. "Fixture-abutment connection surface and micro-gap measurements by 3D micro-tomographic technique analysis". *Annali dell'Istituto Superiore di Sanità*. 48.1 (2012): 53-58.
9. Stamoulis K and Hatzikyriakos AE. "A technique to obtain stable centric occlusion records using impression plaster". *Journal of Prosthodontics* 16.5 (2007): 406-408.
10. Borrow JW and Smith JP. "Stent marker materials for computerized tomograph-assisted implant planning". *International Journal of Periodontics and Restorative Dentistry* 6.1 (1996): 60-67.

11. Misch CE and Degidi M. "Five-year prospective study of immediate/early loading of fixed prostheses in completely edentulous jaws with a bone quality-based implant system". *Clinical Implant Dentistry and Related Research* 5.1 (2003): 17-28.
12. Angie Lee., *et al.* "Screw- Versus Cement-Retained Implant Restorations: Current". *Implant Dentistry* 19.1 (2010): 8-15.

Volume 17 Issue 7 July 2018

©All rights reserved by Zainab H Sulaimani and Fadia Darwiche.