

## **Dermatoglyphics: Link to Periodontal and Oral Diseases**

**Savita Sambashivaiah<sup>1</sup> and Punit Naidu<sup>2\*</sup>**

<sup>1</sup>Head of Department, Department of Periodontology, Rajarajeswari Dental College and Hospital, Bangalore, India

<sup>2</sup>Postgraduate, Department of Periodontology, Rajarajeswari Dental College and Hospital, Bangalore, India

**\*Corresponding Author:** Punit Naidu, Postgraduate, Department of Periodontology, Rajarajeswari Dental College and Hospital, Bangalore, India.

**Received:** April 10, 2018; **Published:** May 11, 2018

### **Abstract**

Dermatoglyphics is a branch of anthropology and genetics which deals with study of intricate dermal ridges covering palmar and plantar regions. These patterns remain unchanged and genetically determined because of this it is considered as a marker for identification of individual and study of population. These patterns are used for detection of intra-uterine irregularities and hence considered as a window of congenital and intrauterine abnormalities. Dermatoglyphics is used as a diagnostic tool to diagnose genetically and non-genetically determined diseases. Thus dermatoglyphics is used not only in medicine but also in dentistry especially in the field of periodontology to diagnose periodontal disease. The present review paper deals with a brief of dermatoglyphics, patterns and role in periodontal and oral diseases.

**Keywords:** *Dermatoglyphics; Palmar Patterns; Genotype; Plantar Patterns*

### **Introduction**

Dermatoglyphic analysis is used for personal identification and also in scientific research which is used as a diagnostic tool to diagnose genetic disorders, medical disorders and dental diseases. These finger print patterns are unique in every individual and remain unchanged for the lifetime [1].

Dermatoglyphics term was derived from Greek word (“derma = skin + glyphae = carve”) which are formed by epidermal ridges on the skin. Term dermatoglyphics was coined by Professor Harold Cummins in 1926. In 1936 Professor Harold Cummins reported that Down’s syndrome showed characteristic features on palmar and plantar regions and this led to impetus research on dermatoglyphics and its use in medical and dental field. Fingertip patterns which are characteristic elevated ridges are unique to every individual. Fingers, toes, palm and soles are covered with system of ridges which form a particular pattern [2].

Development of finger and palmar prints are initiated during 6 - 7<sup>th</sup> week of intra-uterine life and develop during 13 - 19<sup>th</sup> weeks of intra-uterine life. During pregnancy, disturbance in growth during intra-uterine life which can be due to the influence of hereditary or environmental factors leading to formation of abnormal dermatoglyphic patterns. This phase of development of abnormal dermatoglyphic pattern development is called “window of congenital abnormalities” which can be used as an indicator and diagnostic tool [3].

Presently, several researchers have carried out various studies and have claimed that dermatoglyphics can be used as an important diagnostic tool for diseases which have obscure etiology and pathogenesis. Several investigations have been carried out as dermatoglyphics as an indicator for diseases like Down’s syndrome, Trisomy 18, Turner’s syndrome, Klinefelter syndrome, congenital heart diseases, Rheumatoid arthritis, Alzheimer’s disease, Schizophrenia. In dentistry, dermatoglyphics has been used to diagnose dental caries, malocclusion, oral cancer, periodontal diseases, ectodermal dysplasia, and bruxism [4].

### History

Many centuries ago there are reports of use of dermatoglyphics, but there was no sophisticated systems at that time as we have today. During era of Babylonians they used fingerprints in clay to record for business transactions.

Scientifically first observation of epidermal ridges was conducted by Nehemiah Grew (1641-1712) and reported in the book "Philosophical Transactions in 1684". In 1685, Dutch physician Bidloo (1649-1713) published anatomy book illustrating the epidermal ridges of the palmar regions. Marcello Malphigi (1628-1694) contemporary of Grew, reported with a reference stating that papillary ridges are arranged themselves as patterns [4].

In 1788, German anatomist Mayer (1747 - 1801) reported that fingerprints are unique in every individual. In 1823, John Purkinje (1787 - 1869) submitted paper on fingerprint classification but importance was not given and was rejected [5]. Work of Purkinje led to further research on fingerprints and in 1858 Sir William Herschel in India, used fingerprints for personal identification [6]. In 1863, Professor Paul-Jean Coullier (1824 - 1890) demonstrated that iodine fumes can reveal fingerprints and was recorded on paper [4]. In the year 1880 Henry Faulds published paper on fingerprints [7]. In the year 1879 Alphonse Bertillon developed a system to identify the individuals by anthropometric photographs [4].

1892 Sir Francis Galton published book on fingerprints and explained the classification of fingerprints loops, whorls and arches [8]. This led to the establishment of world's first bureau on fingerprints by Juan Vucetich 1892 [4].

Sir Edward Henry (1859 - 1931) developed a new classification system which was based on direction, flow, pattern and friction ridges in fingerprints and replaced the Bertillon classification system [9].

In United States first official documentation of fingerprints for personal identification was conducted by Henry P de Forest in 1902. In the year 1926, Harold Cummins coined the term Dermatoglyphics and observed the ridge configurations which was influenced by hereditary and environmental factors. Since then dermatoglyphics was used as personal identification and also diagnostic tool for the diseases physical and mental health [2].

### Anatomy of fingerprint

Due to the frictional ridges present on the inner surface of the fingers led to the production of fingerprints. They are composed of Valleys comprising of parallel ridges and furrows. There are two epithelial layers: Epidermal (outer layer) and Dermis (inner layer). Epidermis consist of five different cell layers and also two rows of papillae pegs on dermis which plays an important role in recovery of fingerprints in deteriorating bodies. Dermis is composed of connective tissue and blood vessels [10].

### Methods of recording fingerprints

Various methods employed to record dermatoglyphics are [11]:

1. Ink method (ink of stamp pad, ink of eye liner)
2. Inkless method
3. Transparent adhesive method
4. Digital method

### Configurations of fingerprint [12]:

Ridge patterns on the phalanges of the fingertips are divided into three groups

- a) Arches
- b) Whorls
- c) Loops

**a) Arches:** Parallel ridges which traverses the pattern area and form a curve that is concave proximally. The arch pattern is subdivided into two parts:

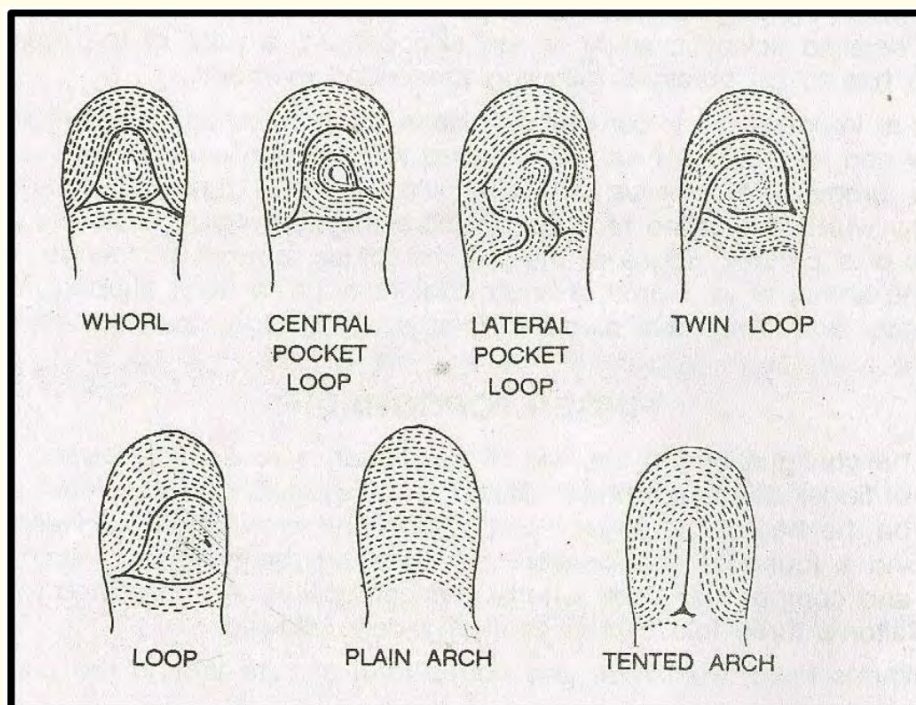
- i) **Simple arch or Plain arch:** Composed of ridges which crosses the fingertip from one side to other side without recurving.
- ii) **Tented arch:** Composed of ridges which meets at a point and their smooth sweep is interrupted. This point of confluence is called Triradius, in this ridges radiate in three different directions and located near the midline of the distal phalanx.

**b) Whorls:** these are the configurations encircled over a core. These are of following types:

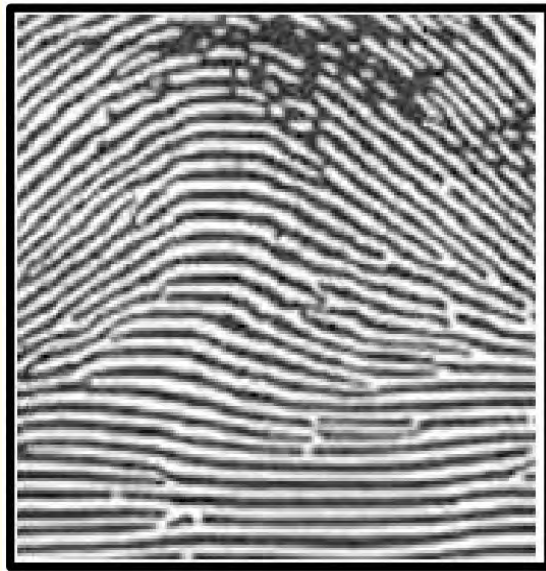
- i) **Plain or Simple or Concentric whorls:** Arranged as a succession of concentric rings or ellipses.
- ii) **Spiral whorl:** In this configuration ridges spiral around the core either clockwise direction or anticlockwise direction.
- iii) **Central pocket whorl:** In this configuration, pattern containing loop within which a smaller whorl is located. It is further classified as ulnar or radial whorl based on the side in which the outer loop is opening.
- iv) **Lateral pocket or twinned loop pattern:** In this ridges are composed of interlocking loops.
- v) **Accidental patterns:** In this patterns cannot be classified as one of the patterns which has been explained above hence also called as Complex patterns.

**c) Loops:** In this configuration, series of ridges enter the pattern area on one side of the digit recurve abruptly and leave the pattern area on the same side. It is of two types:

- a) If the loops are opening towards ulnar side, then the term called as ulnar loop
- b) If the loops are opening towards radial side, then the term called as Radial loop.



**Figure 1:** Schematic representation of the palmar patterns.



*Figure 2: Arch.*



*Figure 3: Loops.*



*Figure 4: Whorls.*

**Dermatoglyphic Landmark on fingertip patterns [12]:**

There are three basic landmark areas found on fingertip patterns which are as follows:

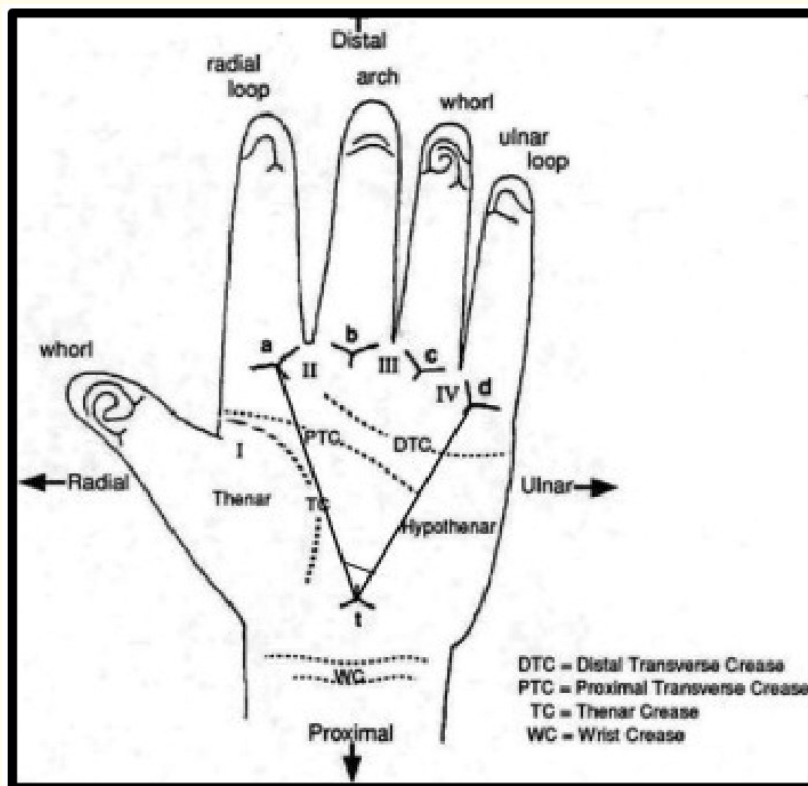
1. **Triradius:** Formed by the confluence of three ridge systems which forms an angle of approximately 120°.
2. **Core:** It forms the center of the pattern. It has various shapes, for example; in loop pattern core is represented by a rod like shape or series of two or more parallel ridges. In whorl pattern core is represented as a short ridge in the form of circle or ellipse.
3. **Radiant:** Ridges which emanate from the triradius and encloses the area. It forms the skeletal framework of the pattern.

**Palmar pattern configuration [12]**

To carry out the dermatoglyphic analysis so as to compare with various individuals the anatomical areas of the palm has been divided and categorized under thenar and hypothenar regions. Thenar region is divided into 1<sup>st</sup> digit, 2<sup>nd</sup> digit, 3<sup>rd</sup> digit, 4<sup>th</sup> digit.

**Ridge counting:** ridges are counted between two digital triradii and are most frequently obtained between triradii a,b and called as a-b ridge count.

**Atd angle:** This angle is formed by the imaginary line drawn between the digital triradius(a) to the axial triradius(t) and from axial triradius to the digital triradius(d). The more distal position of “t” the wider angle of atd.



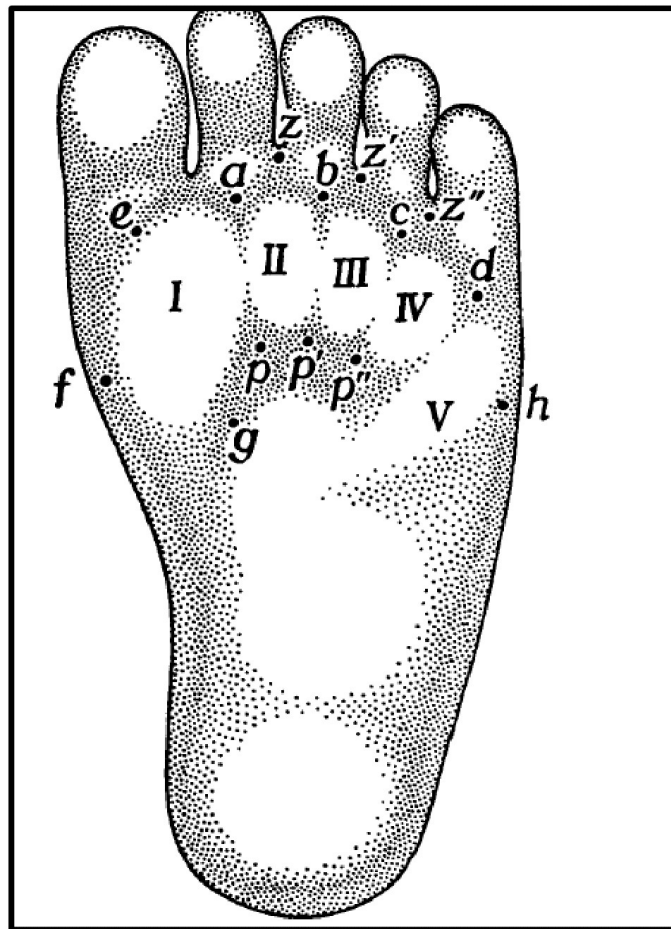
**Figure 5:** Schematic representation of anatomical landmark. Thenar region, Hypothenar region and atd angle.



**Dermatoglyphic pattern in soles [13]**

In 1969 Penrose and Loesch described a method of classification of sole configurations based on topological considerations. “The principle of topological classification is, firstly, to describe all loops, noting that a whorl always consists of two loops, and then to enumerate all the triradii, specifying the most important ones” (L.S. Penrose and D. Loesch, 1970a). The number of loops on a sole is four less than the number of triradii, including extralimital triradii, and provided that each whorl is scored as two loops. The authors limit their descriptions to the thenar distal, interdigital, and hypothenar distal areas of the sole. This is the region of greatest pattern intensity and the part most usually printed.

Each loop is classified according to the pattern area in which it occurs and according to the direction of the core, that is, distal, proximal, tibial, or fibular. The two loops composing a whorl are called distal and proximal. Distal loops are designated as I, 11, 111, IV and proximal ones I, 11, fh, IV, while fibular loops are denoted by the area number with superscript f, thus If When writing the description of a sole, loops are entered first, in numerical order, distal coming before proximal and fibular.



**Figure 6:** Diagram of sole with areas indicated as they are used in the topological classification. Approximate positions of triradii are also shown (From Penrose and Loesch, 1969. Courtesy of Human Biology).

### Role of dermatoglyphics in medical disorders [14]

Dermatoglyphics has been used as a diagnostic tool in various conditions which has hereditary basis. First reported by Cummins in 1926 use of dermatoglyphics in medicine.

It is used as a diagnostic tool in genetic disorders like Klinefelter syndrome, Noonans syndrome, Edward syndrome, Turners syndrome. Also used in diseases with genetic background for example neurological disorders – Alzheimer’s disease, cerebral palsy, schizophrenia and heart disease – congenital heart diseases, coronary heart diseases

### Role of dermatoglyphics in dentistry

Recently dermatoglyphics has been used as an indicator and tool to diagnose various dental diseases like dental caries, oral carcinomas, malocclusion, periodontal diseases, bruxism, craniofacial abnormalities like cleft lip and palate.

### Role in Periodontal diseases:

The role of dermatoglyphics in periodontal disease was first conducted by Yilmaz., *et al.* in 1993 in 70 individuals comprising of 36 early onset periodontitis cases, 20 adult periodontitis and 20 periodontally healthy patients and evaluated the quantitative and qualitative patterns of ridged skin. They confirmed the role of heredity in the etiopathogenesis of periodontal diseases [15].

In a study by Atasu., *et al.* 2005 evaluated the analysis of fingertip, palms and sole patterns of 158 subjects which encompassed 36 Juvenile Periodontitis (JP), 45 Rapidly Progressing Periodontitis (RPP), 38 Adult Periodontitis (AP) cases compared to 39 healthy controls. A decreased frequency of ulnar loops on all digits and increased frequency of i.e. “tri-radial on sole pattern was found in the JP group”. An increased frequency of radial loops on second digit triradial on the palms in RPP group whereas increased frequency of concentric whorls and ulnar loops on all digits was encountered in AP group [16].

In a study done by Devishree., *et al.* 2015 evaluating the qualitative parameters on finger tips in 15 aggressive periodontitis as compared to 15 periodontally healthy cases an increased frequency of ulnar loops was found in the test group. A similar finding was seen in the present study in chronic periodontitis group. Hence it can be assumed that increased frequency of ulnar loops is a characteristic feature of periodontal diseases, a higher level of genetic analysis is required to categorize the type of periodontitis [17].

### Role in oral carcinomas

Very few studies has been carried out on the role of dermatoglyphics in oral carcinomas. Study conducted by Venkatesh., *et al.* on palmar dermatoglyphics in patients with oral leukoplakia and oral squamous cell carcinoma and the results showed that increased frequency of arches were seen oral leukoplakia and oral squamous cell carcinoma [18].

In a study conducted by Gupta., *et al.* also showed promising results by observing an increased frequency of arches and ulnar loop patterns on fingertips with a decreased frequency of simple whorl patterns on fingertips and a decreased frequency of palmar accessory triradial on the right and left hands in oral squamous cell carcinoma patients. Significant findings in oral submucous fibrosis patients included an increase in the frequency of arches and ulnar loop pattern, decrease in the frequency of simple whorl patterns on fingertips, decrease in ATD angle on the right hand, and a decrease in the frequency of palmar accessory triradial on the right hand [19].

The study conducted by Ganvir and Gajbhiye found that whorl type of fingerprint pattern was predominant in significantly higher number of individuals of oral squamous cell carcinoma and oral submucous fibrosis groups than in the control groups, wherein individuals of the control group showed loop as the predominant fingerprint pattern [20].

### Role in dental caries

In a study conducted by Sharma., *et al.* studied dermatoglyphic interpretation of dental caries and its relation to *Streptococcus mutans* growth, which showed that the subject group had a decreased frequency of loops and high *S. mutans* growth as compared to control group [21].

A study conducted by Chinmayi, *et al.* assessed relationship between dermatoglyphics and dental caries in 76 patients and the study showed that dental caries was highest among whorl pattern followed by the central pocket loop and least among students with loop pattern [22].

### Role in bruxism

In a study conducted by Polat, *et al.* studied 38 bruxism patients and examined dermatoglyphic patterns of fingers and palm. Bruxism patients demonstrated an increase in frequency of whorls, I loops, and triradii. There was a decrease in the frequency of ulnar loops, atd angle, tri-radii than the controls. This study summarized that when combined with other clinical features in bruxism, dermatoglyphics can serve to strengthen a diagnostic impression [23].

### Role in malocclusion

Reddy, *et al.* conducted a study using dermatoglyphics to predict and compare malocclusion groups. A total of 96 subjects were divided into three malocclusion groups: Class I (control group); class II, div. 1, div. 2; and class III (experimental group) aged 12 to 14 years. The dermatoglyphic findings revealed that the craniofacial class II, div. 1, div. 2 pattern was associated with increased frequency of arches and ulnar loops and decreased frequency of whorls, whereas in class III, there was an increased frequency of arches and radial loops with decreased frequency of ulnar loops. In predicting class III malocclusion, based on the frequency of arches, the sensitivity values were found to be higher and more reliable than the sensitivity values of class II, div. 1 and div. 2 malocclusion. From their study, the authors of the present study observed that dermatoglyphics might be an appropriate marker for malocclusion [24].

### Advantages of dermatoglyphics

The major advantages of the dermatoglyphics are:

- i) They are fully developed at birth and thereafter remain unchanged for life.
- ii) Scanning or recording of their impressions can be accomplished rapidly, conveniently and without causing any trauma to the patient.

### Limitations of dermatoglyphics

- a. It is difficult for the dermatoglyphics patterns to be diagnostically useful if the patient has gross malformations of the limbs [25].
- b. There are several disadvantages for using atd angle as a parameter. The most important shortcoming is the size of atd angle, i.e., affected by the amount of spreading of the fingers when the patterns are recorded. The pressure exerted can also affect the atd angle [26].
- c. Care must be taken while recording the prints to apply the ink material in adequate amounts. A thin or thick application results in light or dark improper prints [27].

### Conclusion

Fingerprints are known very unique and cannot be altered and hence it as an excellent tool for population studies, personal identification, and morphological and genetic research. Dermatoglyphics in association with other diagnostic tools, such as clinical and radiological investigation, can be used for identification of patients with distinct groups of periodontal diseases. Health care professionals, dental professionals and researchers can adopt this approach of dermatoglyphics for an early diagnosis, treatment and better prevention of many genetic disorders and other diseases whose aetiology may be influenced directly or indirectly by genetic inheritance.

### Conflict of Interest

Nil.

### Acknowledgement

Nil.



## **Bibliography**

1. Cummins H. "Palmar and plantar epidermal ridge configuration (Dermatoglyphics) in Europeans and Americans". *American Journal of Physical Anthropology* 9.4 (1926): 471-502.
2. Henry P de Forest. "The evolution of dactylogy in United States with an historical note on the first finger print and bibliography of personal identification". Pro Internet. Association for identification, 1930 and 1931.
3. Bloterogel H and Bloterogel W. "Blutgrype and Dactylogramm: Konstitutionsmerk male der poliomyelitis". *Krapan Ztrehsf Hindrih* 56 (1934): 143-163.
4. Jeffery G Barnes. "Chapter- 1 History": in Fingerprints Sourcebooks (Rockvillie, MD: National Institute of Justice (2012).
5. Purkinje JE. "Physiological examination of visual organ and of the cutaneous system". Brilaree/vratisavial Typis Universities, 1823 (translated to English by Cummins H and Kennedy RW: American Journal of Criminal Law 31 (1940): 343-356.
6. Herschel Sir WJ. "Skin furrows of the hand". *Nature* 23 (1880): 76.
7. Faulds H. "The skin furrows of the hand". *Nature* 22 (1880): 605.
8. Galton Sir F. "Finger Prints". London: Macmillan and Co (1892).
9. Henry ER. "Classification and uses of finger prints". 7<sup>th</sup> edition. H.M stationery office: London (1934).
10. S Uma Maheshwari and E Chandra. "A review study on fingerprint classification algorithm used for fingerprint identification and recognition". *International Journal of Computer Science and Telecommunications* 3.1 (2012): 739-745.
11. Roopam K Gupta and Aruna K Gupta. "New, easy and effective method to take dermatoglyphic prints". *National Journal of Medical Research* 3.1 (2013): 45-47.
12. Moore KL, et al. "Clinically oriented anatomy". 6<sup>th</sup> edition. Ontario, Canada: Wolters Kluwer/Lippincott Williams and Wilkins (2012): 771.
13. Holt SB. "The genetics of dermal ridges". Charles C. Thomas Springfield (1968): 40-42.
14. Rott H, et al. "Dermatoglyphics in Noonan's syndrome (author's transl)". *Acta Geneticae Medicae et Gemellologiae* 24.1-2 (1975): 63-67.
15. Yilmaz S, et al. "A genetic and dermatoglyphic study on periodontitis". *Journal of Marmara University Dental Faculty* 1.4 (1993): 297-306.
16. Atasu M, et al. "Dermatoglyphic findings in periodontal diseases". *International Journal of Anthropology* 20.1-2 (2005): 63-75.
17. Devishree G and Gujjari SK. "Dermatoglyphic Patterns and Aggressive Periodontal Diseases – A Possible Link?" *IOSR Journal of Dental and Medical Sciences* 14.4 (2015): 69-72.
18. Venkatesh E, et al. "Palmar dermatoglyphics in oral leukoplakia and OSCC patients". *Journal of Indian Academy of Oral Medicine and Radiology* 20.3 (2008): 94-99.
19. Gupta A and Karjodkar FR. "Role of dermatoglyphics as an indicator of pre-cancerous and cancerous lesions of the oral cavity". *Contemporary Clinical Dentistry* 4.4 (2013): 448-453.

20. Ganvir SM and Gajbhiye NY. "Detection of genetic predisposition in oral squamous cell carcinoma (OSCC) and oral submucous fibrosis patients by qualitative analysis of finger and palm-print patterns: A dermatoglyphic study". *Clinical Cancer Investigation Journal* 3.5 (2014): 377-382.
21. Sharma A and Somani R. "Dermatoglyphic interpretation of dental caries and its correlation to salivary bacteria interactions: an in vivo study". *Journal of the Indian Society of Pedodontics and Preventive Dentistry* 27.1 (2009): 17-21.
22. Chimanyi BR, et al. "Dermatoglyphics: An indicator of dental caries in humans". *Journal of Indian Association of Public Health Dentistry* 14.3 (2016): 272-275.
23. Polat MH, et al. "The relation of bruxism and dermatoglyphics". *Journal of Clinical Pediatric Dentistry* 24.3 (2000): 191-194.
24. Reddy S, et al. "A dermatoglyphic predictive and comparative study of Class I, Class II, div.1, div.2 and Class III malocclusions". *Journal of the Indian Society of Pedodontics and Preventive Dentistry* 15.1 (1997): 13-19.
25. Preus M and Fraser F. "Dermatoglyphics and syndromes". *American Journal of Diseases of Children* 124.6 (1972): 933-943.
26. Schaumann B and Alter M. "Dermatoglyphics in medical disorders". New York (NY): Springer Verlag Publishers (1976): 27-87.
27. Priya NS, et al. "Dermatoglyphics in dentistry: an insight". *World Journal of Dentistry* 4.2 (2013): 144-147.

**Volume 17 Issue 6 June 2018**

**©All rights reserved by Savita Sambashivaiah and Punit Naidu.**