

## Comparing Sealing Capacity of MTA and Biodentine in Retrograde Obturation of Human Teeth, *In-Vitro* Study

Jesse Abreu Lemoine, DDS<sup>1</sup>; Yohan Carlos Quesada, DDS<sup>2</sup>; Thiago Costa, DDS<sup>3</sup>; Indhira Melo, DDS<sup>4</sup> and Klenise S. Paranhos, DDS, MS<sup>5</sup>\*

<sup>1</sup>4<sup>th</sup> year Dental student at New York University College of Dentistry, New York, USA

<sup>2</sup>4<sup>th</sup> year Dental student at Universidad Nacional Pedro Henriquez Ureña, New York, USA

<sup>3</sup>3<sup>th</sup> year Dental student at New York University College of Dentistry, New York, USA

<sup>4</sup>Current Resident of International Comprehensive Care Program at New York University College of Dentistry, New York, USA

<sup>5</sup>Clinical Assistance Professor of Advanced Program for International Dentists, Asham Department of Periodontology and Implant Dentistry, at New York University College of Dentistry, New York, USA

\***Corresponding Author:** Klenise Paranhos, Department of Periodontology and Implant Dentistry, New York University College of Dentistry, New York, USA.

**Received:** March 09, 2018; **Published:** April 21, 2018

### Abstract

**Objective:** The aim was to compare the sealing ability of MTA Angelus Cement to and Biodentine in retrograde obturation on endodontically treated human teeth with after apicoectomy.

**Materials and Methods:** 28 extracted human anterior teeth were treated with root canal therapy and obturated with gutta-percha. The teeth were randomly divided into 2 groups of 12 teeth each; each group to receive apicoectomy (half at 45 and half 90 resection angles) and retrograde obturation with MTA and Biodentine. 4 teeth were used as control. Each group of teeth was then placed inside Methylene Blue solution for 24 hours then removed and washed. Three circumferential cuts were made at the apex of every tooth of 1mm in thickness each, and the middle slice was evaluated with a 25x microscope to calculate the area of staining present in each sample.

**Results:** The samples where MTA was used with a 45 degrees' angle resection showed the lowest staining values with a value of 1.2% average. The samples that used MTA with a 90 degrees' resection showed the second lowest average of staining with a value of 1.93%. The samples where Biodentine was used showed higher levels of staining with the 90 degree resection showing an average of 3.36% and the 4 degree resection an average of 3.84%.

**Conclusions:** In this study, there was no statistical significance shown when comparing the sealing capacity of MTA Angelus cement to Biodentine in endodontically treated teeth after apicoectomy regardless the resection angles of 45 and 90 degrees.

**Keywords:** Apicoectomy; Endodontic; Obturation; Methylene Blue

### Introduction

In dentistry there is still no ideal restorative or obturator material in retrograde fill for Apicoectomies. Apicectomy is a treatment that involves "surgical resection of the apical third of a root together with pathological tissue surrounding it" [1]. This treatment is regularly the last option in an endo-surgical treatment, after several treatments of endodontic therapy canals have failed. After removal of the apical third of the root, the choice of a sealing material that offers a complete seal that allows the elimination of any lesion through an obstruction of the exit of bacteria and byproducts of necrotic pulp inside the canal is essential for the success [2].

Every day the materials are looking forward to improve their properties. However, endodontic and surgical procedures depend on these materials, which together with the management of the case can determine the success or failure of the endo-surgical treatment as in Apicectomy. Some of the characteristics that the filling material should have is to provide a good seal in the root canal system, show biocompatibility, enhance regeneration of periapical tissues, set irrespective of wetness, show no corrosion and electrochemical activity, be easy to handle and should have a different radiographic opacity as compared to dentin [3,4].

**Citation:** Klenise Paranhos, et al. "Comparing Sealing Capacity of MTA and Biodentine in Retrograde Obturation of Human Teeth, *In-Vitro* Study". *EC Dental Science* 17.5 (2018): 544-556.

There are several materials for retrograde obturation that has been used for years, like amalgam, zinc oxide eugenol (ZOE) cement, ethoxy benzoic acid (EBA) and Super EBA cement, glass ionomer cement, gutta-percha, composite resin, Mineral trioxide aggregate (MTA) and newly introduced material Biodentine [5,6]. This material is composed of tricalcium silicate, calcium carbonate, zirconium oxide, and a water-based liquid containing calcium chloride used as setting accelerator and water-reducing agent [5,7]. Biodentine is a fast-setting calcium silicate-based material that presents characteristics comparable to MTA [8].

### Aim of the Study

The aim of the study was to compare the sealing ability of MTA Angelus Cement and Biodentine in retrograde obturation on endodontically treated human teeth with after apicoectomy.

### Methods and Materials

#### Type of Study

The study was an experimental in vitro study where one or more treatments for a disease or process were evaluated. This type of experimental study can be considered of therapeutic type, because it evaluated how to improve a treatment for a pathology or alteration with the use of different materials and techniques of the apicoectomy surgery.

#### Universe and Sample

The entirety of the test was previously extracted human teeth and they were endodontically treated and to each of them with the same principles of opening, conductometry, biomechanical preparation and obturation required in the clinic and preclinical laboratory of the dental school Dr. René Puig Bentz in The National University Pedro Henríquez Ureña (UNPHU), Santo Domingo, Dominican Republic. In cases where the amount of the sample was not sufficient, the missing teeth would be endodontically treated by the authors with the same principles used in the preclinical of the chair of Endodontics of the dental clinic Dr. René Puig Bentz at the National University Pedro Henríquez Ureña. The samples were various groups of anterior teeth divided by the cutting angle of the bevel used in the treatment and by the obturator material used in the treatment. The ones that will give the following graph:

A total of 28 anterior teeth were obtained; (6 in each group) with endodontic treatment, with apicoectomy treatment and 4 control teeth (without apicoectomy or retrograde obturation material) were and were randomly selected. This gave a total sample of 24 teeth with 4 controls. It should be noted that these teeth were previously selected after radiographically checking that they had satisfactory endodontic treatment.

Samples were identified with an identification number/code. The numbers were assigned as follows: First letter of the coding was assigned by the type of obturator material:

- B (BioDentine)
- M (MTA)

Second number was assigned by the type of cut made:

- 45 (45° cut)
- 90 (90° cut)

The third number was assigned to each sample according to the order in which they were sealed, from 1-6 range:

- Tooth 1 = 1
- Tooth 2 = 2
- Tooth 3 = 3
- Tooth 4 = 4
- Tooth 5 = 5
- Tooth 6 = 6

Examples of coding a sample:

- M90-3 = Third tooth sealed with MTA, with 90 degree cut.
- B45-5 = Fifth tooth sealed with BioDentine with 45 degree cut.
- B90-1 = First tooth sealed with BioDentine with 90 degree cut.

Teeth Controls were identified with the letter C (identifying it as part of a control tooth) followed by a selected number in the order of their 1-4 apical resection. Example of the coding of a control sample:

- C-4 = Fourth control tooth
- C-2 = Second control tooth

This coding system was useful for identifying each sample and maintaining clinical and radiographic control over it throughout the experiment.

### Unit of Statistical Analysis Statistical analysis

Units were: Anterior human teeth (incisors and canines, upper and lower)

### Inclusion and Exclusion Criteria

#### Inclusion Criteria

Human teeth with anatomical characteristics corresponding to anterior monoradicular (central, lateral and canine) classifications, human teeth with biomechanical preparation and satisfactory endodontic obturation, healthy human teeth with intact roots permanent monoradicular human teeth, teeth Human with coronary and / or cervical fillings.

#### Exclusion criteria

Human molar teeth or bicuspid, human deciduous teeth, multiradicular human teeth, human teeth with abnormalities affecting the dentin-pulp complex such as microdontia, dens in teeth, taurodontism, macrodontia, disintegration, atresia, internal and external resorption, fusion, germination, etc. Human teeth with fused roots and human teeth with root fractures.

### Techniques and procedures for data collection and presentation

Techniques for collecting data or information were performed in several stages which are described as follows.

#### Sample collection

All teeth used in the trial were Prepared endodontically and obturated in the laboratory of the department of endodontics. The missing teeth were prepared endodontically and were filled by the study operators using the same techniques and principles of endodontics Used in the dentistry clinic of the National University Pedro Henríquez Ureña of the Dr. René Puig Bentz.

#### Endodontic Treatment

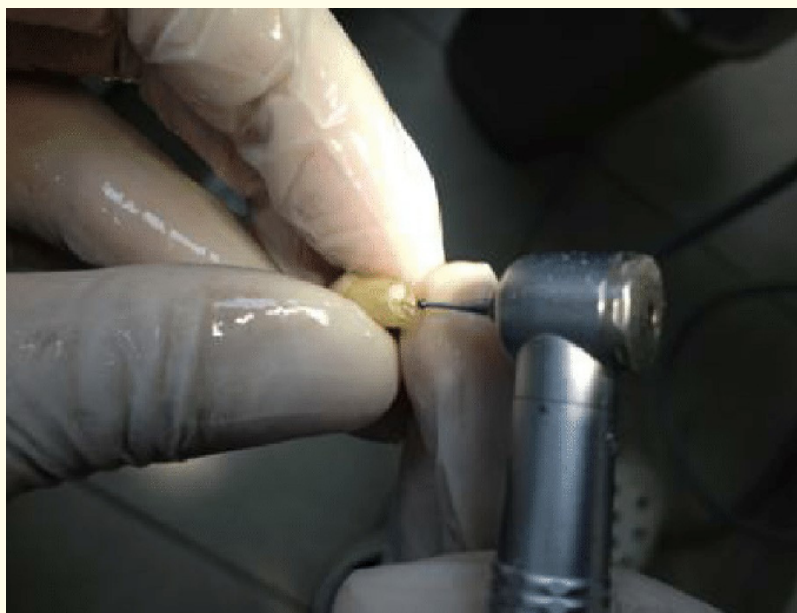
The human teeth of the sample (including the controls) were mounted in a dental model of plaster to facilitate their absolute isolation necessary x-rays were taken. Then the coronary preparation (opening) was performed, according to the tooth type and anatomy of the same. When a correct aperture was performed, the conductivity was performed (with each conduit) with Flexofile (Maillefer) files from # 15 until the required working length was reached. When establishing the proper working length of the duct, proceeding to the passage of the instrumentation. The instrumentation, also called the biomechanical preparation of the duct, was performed in a conventional manner in each duct. The used files were from # 15 to # 40, irrigating with water between each file. Water was used as the irrigating solution since the tooth is "*in vitro*" and there is no active lesion in an organism to try to combat it. At the end of the biomechanical preparation step, the "instrumentation" radiograph was taken to confirm the preparation of the duct and proceeded to the passage of the obturation.

Sealing was started by conducting the conometry, in most cases a Gutta Percha master cone of the same thickness or number of the last file used in the biomechanical preparation was taken and inserted into the conduit, the Depth of working length was obtained by feeling a "tug-back" to confirm proper apical sealing. Upon obtaining that adequate apical seal of the master cone, an x-ray was taken called "Conometry" to confirm that the cone has sealed as apical as possible or up to the CDC limit. Zinc Oxide Eugenol (Deepak) cement was

then prepared according to the manufacturer’s instructions. Next, the ZOE cement was applied to that master cone and introduced into the conduit at the same length as the previous suction. Using a spacer the lateral condensation technique was used to create spaces inside the duct and then to introduce the accessory cones of Gutta Percha. The accessory cones were about half the thickness of the master cones in each duct. The accessory cones were introduced into the spaces created by the spacer instrument, using a lateral condensation technique, always with OZE cement to ensure a good seal. This step was repeated until it became difficult to introduce more accessory cones, and this was the time to take the x-ray of “condensation” to confirm that a seal has been made free of defective spaces. This was confirmed by verifying that there are no ducted spaces between the intense radiopaque of the Gutta Percha and the slight radiopacity of the dentine of the tooth. Upon verifying that a satisfactory conduit was sealed, the “plugger” instrument was heated to cut and remove the Gutta Percha that had remained in the chamber and then that same instrument was heated and introduced as a vertical condensation to the Gutta Percha That can remain in the coronal area, to allow a good sealing of accessory or lateral ducts. The coronal opening was provisionally sealed with cotton and Cavit or IRM. At the end, the final radiograph of the endodontic treatment was taken with all well-filled tooth passages. At the end of the endodontic treatment, two layers of nail polish were applied to all of the root surfaces of the teeth. This ensured that no filtration of the staining solution occurs by means of channels such as delta apical or lateral ducts.

### Treatment of apicectomy or resection

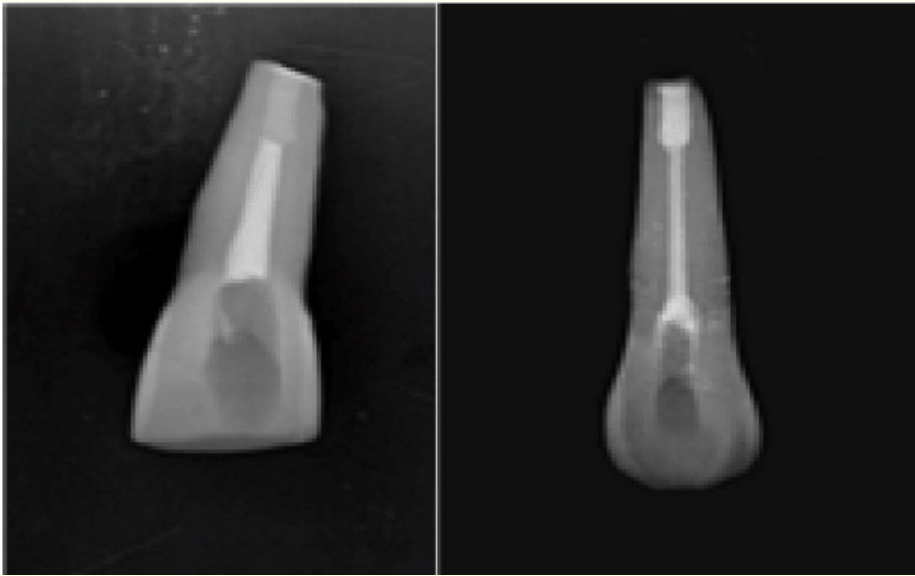
Endodontic teeth were kept at ambient temperature for at least 24 hours after sealing without any manipulation to allow cement to set without alteration that could compromise sealing. Two different techniques of resection or apicoectomy were used in the study. One technique was the resection 3 millimeters coronally of the apex, at an angle of 90 degrees with respect to the longitudinal axis of the tooth, while the other technique was resection 3 millimeters coronally of the apex with an angle of 45 degrees with respect to the longitudinal axis of the tooth. All teeth including the controls were resected. First, the teeth were separated according to the “angle of cut” group to which they belong, these groups are group “90” and group “45”. It was performed (at 90 degrees relative to the longitudinal axis of the tooth or at 45 degrees relative to the longitudinal axis of the tooth) a mark of surrounding line with a plush that indicated the cut of the apicectomy in the tooth (Figure 1). Then under continuous irrigation of water and with a high speed turbine, the root apicectomy was performed with a diamond drill # 4138.



**Figure 1:** Performing apicectomy with a carbide bur #2.

### Retrograde Preparation and Sealing

When the root resection of all teeth was performed, retrograde preparation and filling were performed. A trapezoidal preparation was made with the base towards coronal and apex towards apical (Figure 2), where the Gutta Percha obturation ends with a standard preparation depth of 3 mm. All preparations were performed under constant irrigation of water with a carbide burr # 2 (Dentsply/Maillefer). Depending on the “sealing material” group of each tooth, the corresponding retrograde obturation was performed with Aggregated Trioxide Ore or with Hydraulic Calcium Silicate, both of which were performed according to the manufacturer’s instructions.



**Figure 2:** Retrograde Obturation complete.

Two different techniques of apical resection were used, one at an angle of 90° with respect to the longitudinal axis of the tooth, the other at 45°.

### Immersion in staining solution

After the retrograde obturation was performed, the teeth remained long enough (according to the manufacturer’s instructions) without manipulation to allow a good quality setting. The teeth were then dried and introduced into the 1% methylene blue solution with pH closer to 7.4 (which most closely resembles body pH) for a period of 24 hours at room temperature. Methylene blue was used because it diffuses more easily through narrow pores than other staining solutions such as rhodamine [2]. The teeth were immersed in such a way that their coronary portion was left out of the staining solution.

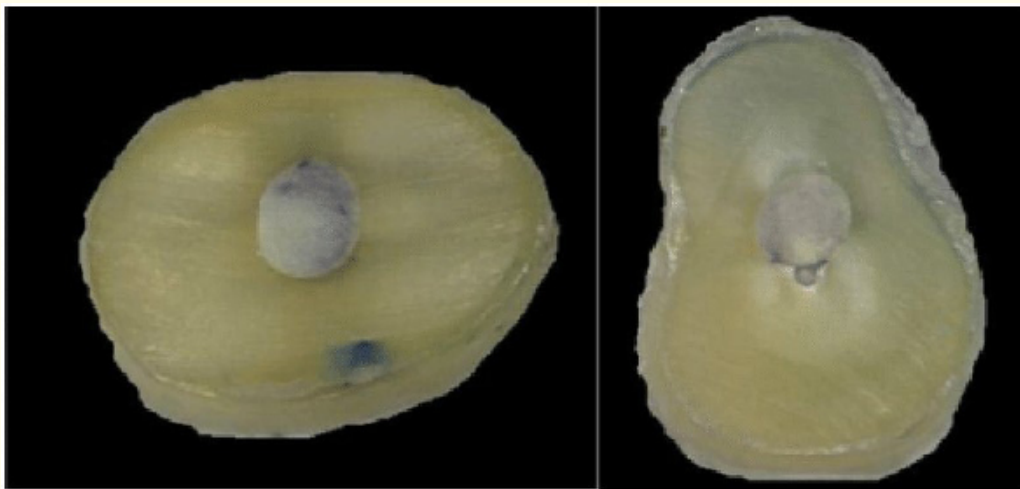
At 24 hours the teeth were washed under tap water for an hour and then proceeded to the parallel cuts to obtain the results.



**Figure 3:** Teeth immerse in staining solution.

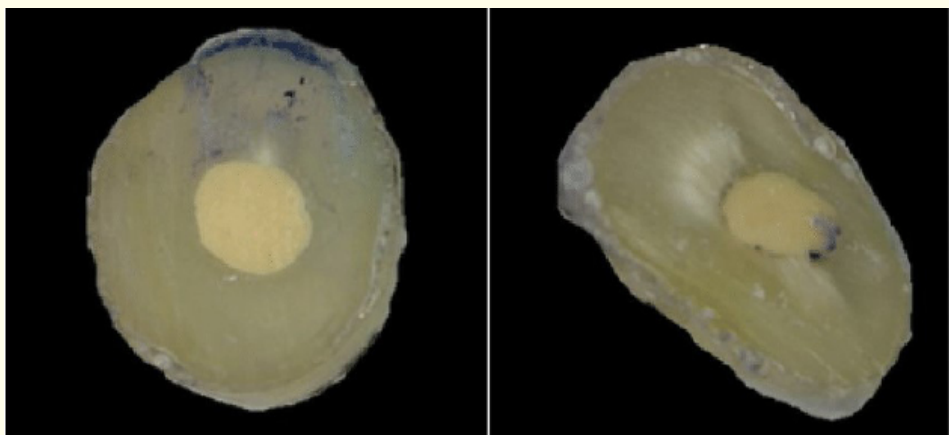
**Parallel cuts for obtaining results**

To the sectioned teeth were made 3 surrounding lines with a black plush to mark precisely the cut area. The first line was 1 mm away from the most apical portion. The second line was 2 mm away from the most apical portion and called the intermediate cut. The third line was 3 mm away from the most apical portion. These lines represented the cuts and were parallel to the apicoectomy previously performed. With the cuts marked according to the tooth group of the sample, the parallel cuts were made with a diamond disk mounted on a micromotor of low speed and under constant irrigation of water, proceeded to make a continuous and clean cut until obtaining the 3 evaluation cuts desired. This process was repeated for each tooth. The first cut also known as the most apical was discarded and was not considered in the analyzes of the results. The coronary cuts were discarded since in some there was presence of Gutta Percha which does not allow an analysis of the correct retrograde obturation material. The intermediate sections were the only ones analyzed to check whether the retrograde obturation with their respective materials and the resection technique in question were “satisfactory” or not.



MTA 90°

MTA 45°



BD 90°

BD 45°

**Figure 4:** Sectioned teeth after the staining solution.

### Microscopic Analysis of the results

Samples that were analyzed microscopically are samples from the intermediate sections. Intermediate cuts were glued to a sheet of a different color for ease of digital recognition in image processing. The intermediate sections were observed by a digital microscope at 25x amplification and the photos were digitized for computerized analysis. The computerized analyzes were performed in the software "ImageJ 1.47v".

Observing that the intermediate cuts do not contain staining, it can be inferred that the penetration of the staining was within 0 - 1 mm and was a "satisfactory" seal. Note that the intermediate cut contains a staining but less than 50% of the total area is understood to have an "acceptable" seal. When observing the intermediate cuts and noting a staining of more than 50% of the total area, it was understood that there was a penetration beyond 2 mm and the seal was "unsatisfactory".

### Calculation and analysis of results

The computerized analysis allowed the calculation of the percentage of the surface affected by the staining solution. First, the Tooth Area (AD) was calculated. The Tooth Area was calculated by eliminating any part of the image that did not belong to the sample. This was achieved with the ImageJ 1.47v program and is shown in figure 4. When the Dental Area was obtained, the Staining Area (ADT) was obtained using the ImageJ 1.47v program and with these figures (in pixels) Percentage of dental surface affected by staining. For the percentage of staining, the following formula was used:

$$\frac{ADT}{AD} \times 100 = \text{Percentage of Staining}$$

This percentage gave us a way to compare how materials and cuts helped seal the dentino-pulp complex. All area calculations were performed using pixels as the unit of measurement of the image in the ImageJ 1.47v program.

### Statistical plan of information analysis

Statistical calculations were performed such as: Frequency absolute as material type Frequency absolute as bevel type Promedium in % penetration (dyeing) as material type Promedium in% penetration (staining) in type of bevel.

### Ethical aspects involved in research

This test reports the names of commercial houses of all expendable materials used such as:

- Gutta Percha
- Mineral Trioxide Aggregate (MTA)
- Hydraulic Calcium Silicate (BioDentine®)
- 1% Methylene Blue Solution
- Zinc-Eugenol Oxide
- Nail Polish (Nikoll Fast Dry)
- Also the names of the manufacturers of expendable instruments such as:
- Diamond Flexofile (Dentsply/Maillefer)
- Carbide (Jota)

This study did not receive monetary funds from any source related to commercial houses or companies involved in the same. The essay also does not report names of students or auxiliary staff to the experiments.

**Results**

Study results are organized by first presenting the staining averages of each group of samples in tabular form. Then graphs are placed for a better visual representation of the results. The next tables represent the absolute frequencies of the types of graphs representative followed by sealing thereof. After submersion for 24 hours in methylene blue, the samples were cut and the cuts were captured in digital imaging for observation and calculations. After the staining percentages were calculated, the following results were obtained.

MTA Samples with 90° Resection	Dye Staining Percentage
MTA 45° - 1	0%
MTA 45° - 2	0.22%
MTA 45° - 3	5.44%
MTA 45° - 4	1.05%
MTA 45° - 5	0.5%
MTA 45° - 6	0%

**Table 1**

MTA Samples with 90° Resection	Dye Staining Percentage
MTA 90° - 1	4%
MTA 90° - 2	0%
MTA 90° - 3	2%
MTA 90° - 4	5.6%
MTA 90° - 5	0%
MTA 90° - 6	0%

**Table 2**

Bio Dentine Samples with 45° Resection	Dye Staining Percentage
BD 45° - 1	0%
BD 45° - 2	6.6%
BD 45° - 3	0%
BD 45° - 4 *	91%
BD 45° - 5	12.6%
BD 45° - 6	0%

**Table 3**

Bio Dentine Samples with 45° Resection	Dye Staining Percentage
BD 90° - 1	3%
BD 90° - 2	9.79%
BD 90° - 3	1.3%
BD 90° - 4	6.11%
BD 90° - 5	0%
BD 90° - 6	0%

**Table 4**



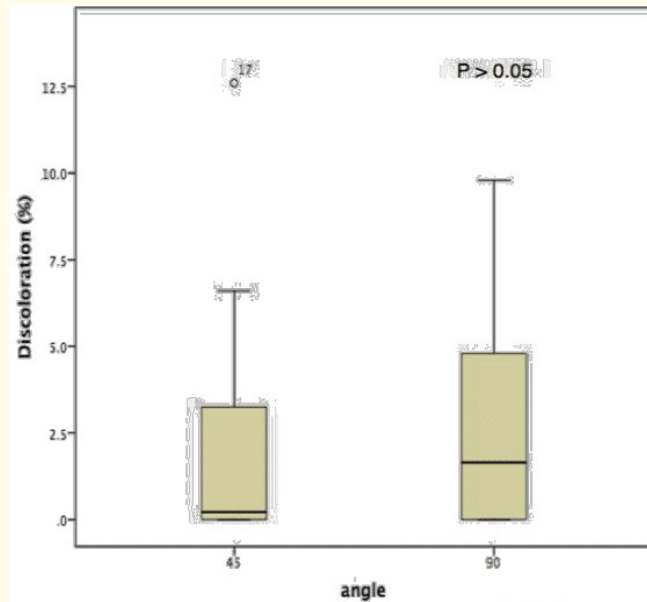


Table 5

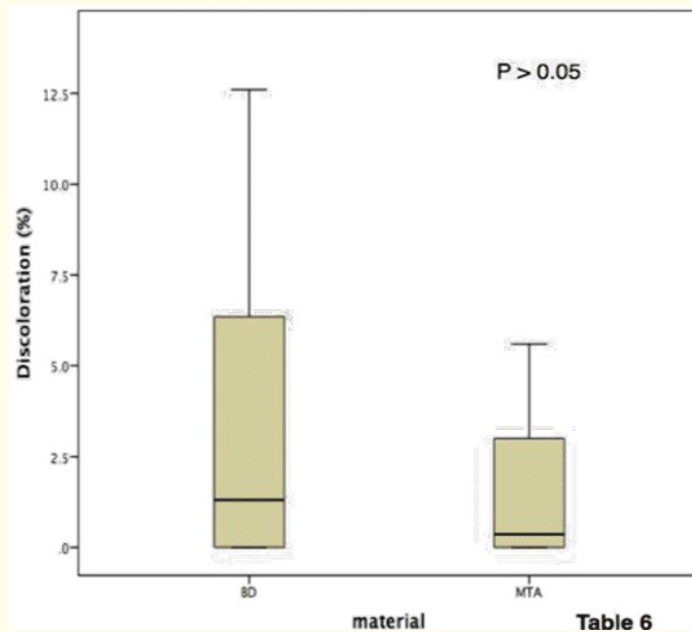


Table 6

Table 6

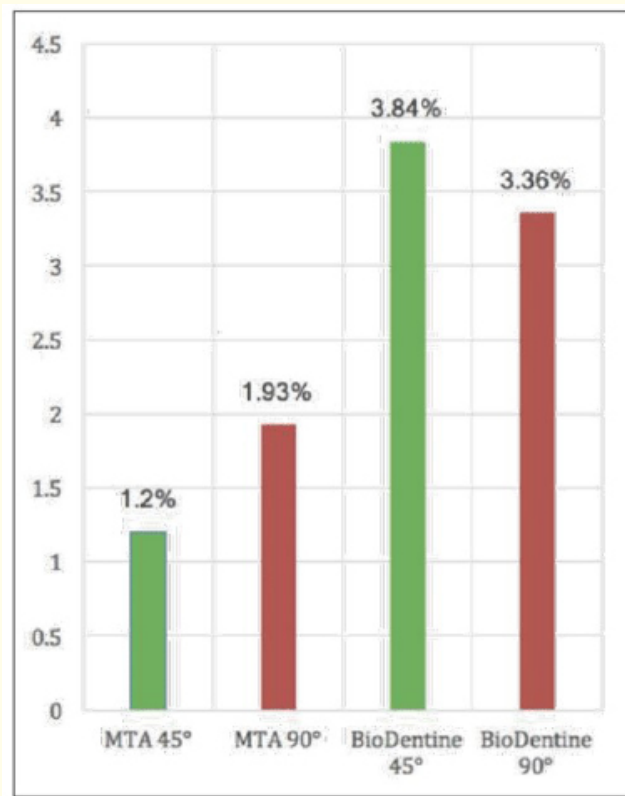


Table 7

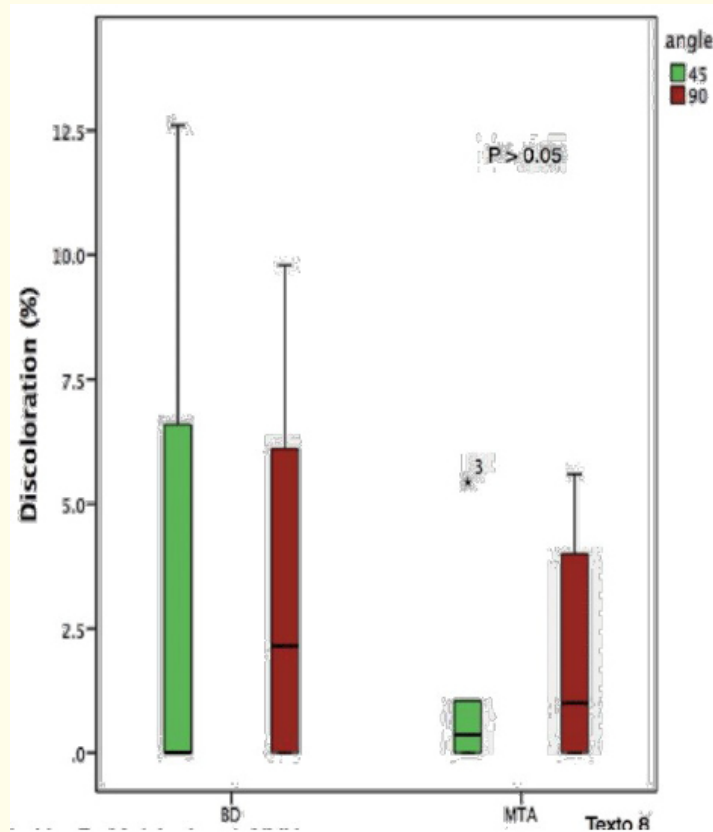


Table 8

The average of the group BioDentine 45° was exaggerated given to the sample BioDentine 45-4 that tube a value much higher than the others in 91.1%. If you delete that value that was out of the normal, together with the minimum value of the group, we will obtain this table in the form of the truncated mean (only in the group BioDentine 45°).

We can observe that by taking the truncated mean (eliminating the highest value and the smallest value of the BioDentine 45° group) that the MTA material allowed less staining of the methylene blue by offering a better seal.

Excluding the BioDentine 45-4 sample it was observed that the average percentage of staining of the cuts were close. The results say that the angles of cuts of 90 degrees allowed more staining by a figure of .25%.

## Discussion

The findings of the present study demonstrated that the MTA material exhibits staining values in less quantity and thus is the material that offers the best seal when compared to other retrograde filling materials. This is similar to the study done by the authors Post, Lima, Demarco, Xavier and Oliveira in Brazil [10] and Avila and Cortés in Chile [11] where both studies showed that the MTA gives lower penetration values in retrograde obturations. These authors compared the MTA mainly with Amalgam but resulted in values similar to the present study comparing Calcium Silicate (BioDentine).

The present study showed that performing a 90 degree cut allows less penetration of staining and therefore offers a better seal. This finding differs from the study done by the authors Post, Lima, Demarco, Xavier and Oliveira in Brazil 10 who found that there was no difference in the filtration as far as the angle of resection used. But this finding is in accordance with the study by Gilheany, Figdor and Tyas where they found that the 90 degree cut exposes fewer dentinal tubules and removes more root branches [12]. Taking into account the percentage of staining in the intermediate cut, this study Could observe that the material that gives better performance regardless of the cutting angle used was the MTA. This resembles the findings of the study by the authors Post, Lima, Demarco, Xavier and Oliveira in Brazil [3]. Some values of the present study were affected by a result that gave very out of the normal sample BioDentine 45-4. This sample caused a large increase in mean values, but did not affect the final result, in which the MTA gave better performance as retrograde filling material, taking into account the staining percentages. This indicates that the MTA material at the level of the sealing material could be more efficient than it claims to be BioDentine despite having the adhesive capacity [13] that does not have the MTA, but by a very small margin.

The BioDentine 45-4 sample gave a higher than normal staining value in relation to the other samples that were filled with the same material and at the same apical cutting angle. This could happen for a number of reasons (deficiency in retrograde obturation, presence and exposure of dentinal tubules and presence and exposure of lateral ducts), the latter being more likely because a 45-degree cut is more likely to leave exposed A lateral canal (Image 2) by its location at the root level and by its occurrence index in all permanent teeth of 50% [12,14]. The present study was limited because it did not offer different methods of preparation of the retrograde cavity. The 90 degree cut *in vivo* is mostly used with the retrograde cavity preparations with the Ultra sonic tips [15]. BioDentine sealing ability should be studied when using an ultrasonic tip for retrograde preparations. As has been done in previous studies [10]. Taking into account the results of that experiment can be reached a hypothesis, that the materials will act in the same way regardless of the technique of preparation or apical resection. The present study was also limited in the number of samples that were worked, a study with more samples can give more faithful results.

If the performance of the materials is evaluated by taking into account the absolute frequency, the materials had almost equal values. Both materials and cuts showed satisfactory sealing five times and most of the other times were sealed acceptable, i.e. both materials and cuts functioned similarly to seals which may be considered satisfactory and acceptable. This indicates that both materials work very effectively and very much the same as you see. A new hypothesis can be reached that predicts that both materials will work in a similar way regardless of the type of retrograde cavity preparation (ultrasonic tip or high speed instrument). It was expected to observe that the material that gave the best performance by its action would be BioDentine by its action of adhesion to the dentin (by means of the 54 dentin tubules), both in 45 degree cuts and 90 degree cuts. According to the findings of the study it can be said that the adhesion to the tooth structure of BioDentine is not sufficient to provide better sealing than the MTA. Despite having a mechanical retention, the MTA proved to be better material because it allowed less percentage of staining in the samples.

## Conclusion

The present investigation could evaluate that the calcium silicate (BioDentine) and its adhesive action was not a determining factor as to the quality of the seal. It was expected to observe less staining in the BioDentine sections at angles of 45 (due to exposure of the dentinal tubules), but even so, that fact did not affect the sealing ability and the exposure of the dentinal tubules were a negative factor in sealed. The present investigation could demonstrate that the best material for the sealing in retrograde obturations is the MTA independently of the apical cut angle. The angle of resection did not significantly affect the sealing of the retrograde obturation with the MTA material, this differs from the postulated in the hypothesis, H1 and H2. The findings of the present investigation demonstrated that the best combination of material and angle cut or resection in apicectomy is the 90 degree cut with the MTA material, this differs from the postulated in the hypothesis, H1 and H2, although it was observed Greater deficiency in the samples with cuts of 45 degrees in general sense, similar to that postulated in the hypothesis H3. ( I REMOVED THIS ENTIRE PARAGRAPH)

It was concluded that there was no statistical significance in the percentage of dye staining when comparing BD to MTA ( $p = 0.51$ ). It was also determined that there was no significant difference in the percentages of staining between the resection angles ( $p = 0.71$ ) when comparing both materials. This leads us to believe that when considering a material for obturation where an apical seal will be needed there is no significance when choosing between MTA and BD. This is important to consider in cases that can be sensitive to the technique or where the cost of the materials is a factor since Biodentine is less technique sensitive with a lower cost than MTA and it is shown to perform at a similar capacity. To our knowledge, there are a very limited amount studies comparing MTA to the newer Biodentine product when used for this application. It is important to continue to study Biodentine and its applications to further validate its effectiveness in apicoectomy regardless of angle resection performed and for sealing capacity in retrograde filling.

## Bibliography

1. Fragiskos F. "Oral surgery". Berlin: Springer (2007).
2. Caron Gregory, *et al* "Use of a new retrograde filling material (Biodentine) for endodontic surgery: two case reports". *International Journal of Oral Science* 6.4 (2014): 250-253.
3. Gartner AH and Dorn SO. "Advances in endodontic surgery". *Dental Clinics of North America* 36.2 (1992): 357-358.
4. Korbinian Benz, *et al*. "In vitro evaluation of apical seal of two different retrograde filling materials". *Australian Endodontic Journal* 43.1 (2017): 29-33.
5. Payal Saxena, *et al*. "Biocompatibility of root-end filling materials: recent update". *Restorative Dentistry and Endodontics* 38.3 (2013): 119-127.
6. Chong BS and Pitt Ford TR. "Root-end filling materials: rationale and tissue response". *Endodontic Topics* 11.1 (2005): 114-130.
7. Laurent P, *et al*. "Induction of specific cell responses to a Ca<sub>3</sub>SiO<sub>5</sub>-based posterior restorative material". *Dental Materials* 24.11 (2008): 1486-1494.
8. Goldberg M, *et al*. "Emerging trends in (bio)material researches". In: Goldberg M, editor. Biocompatibility or cytotoxic effects of dental composites. Oxford: Coxmoor Publishing (2009): 181-203.
9. Buckley R. "Solid State Chemistry Research Trends". Nova Publishers (2007).
10. Kirst Post L, *et al*. "Sealing Ability of MTA and Amalgam in Different Root-End Preparations and Resection Bevel Angles: An In Vitro Evaluation Using Marginal Dye Leakage". *Brazilian Dental Journal* 21.5 (2010): 416-419.

11. Pacheco Avila SA and Monardes Cortés H. "Evaluación de la microfiltración marginal en materiales de obturación retrógrada: mta, amalgama y vidrio ionomero, en raíces con apicectomía recta, en vitro". Talca: Universidad de Talca (Chile). Escuela de Odontología (2008).
12. Gilheany PA., *et al.* "Apical dentin permeability and microleakage associated with root end resection and retrograde filling". *Journal of Endodontics* 20.1 (1994): 22-26.
13. Norsk Dental Depot. "Biodentine Active Biosilicate Technology". Oslo, Noruega (2014).
14. Messing J and Stock J. "A Colour Atlas of Endodontics". Company T, editor. London: Wolfe Medical Publications (1988).
15. Kellert M., *et al.* "A modern approach to surgical endodontics: ultrasonic apical preparation". *New York State Dental Journal* 60 (1994): 25.

**Volume 17 Issue 5 May 2018**

**©All rights reserved by Klenise Paranhos, *et al.***