

## **Orthosurgical Management of Median Cleft Lip and Palate, A Multidisciplinary Approach: Case Report**

**Wisam Al Hamadi<sup>1\*</sup>, Fayed Saleh<sup>2</sup>, Mohamad Kaddouha<sup>3</sup> and Almustafa W Alhumadi<sup>3</sup>**

<sup>1</sup>Assissant Professor in Orthodontic, Dean of Faculty of Dentistry, Universty of Misan, Iraq

<sup>2</sup>Professor and Chairman, Department of Orthodontic Faculty of Dentistry, Lebanese University 1995-1999; Beirut Arab University 1999-2013, Lebanon

<sup>3</sup>Postgraduate Candidates, Department of Orthodontic, Faculty of Dentistry, Beirut Arab University, Lebanon

**\*Corresponding Author:** Wisam Al Hamadi, Assistant Professor, College of Dentistry, University of Misan, Al-Omara, Maisan, Iraq.

**Received:** January 16, 2018; **Published:** February 07, 2018

### **Abstract**

**Objective:** To present a new standard of care for a complex rare median maxillary cleft and emphasize on the principles that such cases are best treated by interdisciplinary team of specialists with experience in this field.

**Materials and Methods:** A female patient aged 9 years 6 months presented with a median cleft of lip and palate (premaxilla with four anterior teeth were lost), surgical repair was performed at an early age with visible scar. Full clinical and radiographic records were collected and initially analyzed jointly by an orthodontist, implantologist and maxillofacial surgeon. The maxilla exhibited a deficiency in three planes of space. There was an anterior and posterior cross bite with distorted occlusal plane and anterior open bite. Due to loss of basal support, the nose was severely depressed with flat alar bases (loss of nasal cartilaginous support). The clinicians agreed upon a long-term treatment planning started with orthopedic intervention, orthodontic presurgical preparation, alveolar bone grafting, maxillofacial surgery, nasal reconstruction, postsurgical orthodontic care, placement of dental implants, and prosthetic phase.

**Results:** A significant improvement in facial contour was realized. Lower anterior facial height was reduced by 8.3 mm (angular 11.3°); lips became competent at rest and teeth-to-lip relationship created a beautiful smile, alar bases favorably widened improving nasal esthetics.

**Conclusions:** Despite patient and parents' satisfaction with the outcome, the long duration of treatment (almost 13 years) for a school-aged girl, and the shuttle movement from private practice to another then to hospital were a burden on the family. This calls for establishing medical centers in Lebanon with a well-trained independent craniofacial professional team, in which all members are involved in conducting a joint evaluation (face-to-face group meeting) and negotiate a comprehensive treatment plan.

**Keywords:** Median Cleft Lip and Palate; Multidisciplinary Approach; Maxillofacial Surgery; Postsurgical Orthodontic Care; Prosthetic

### **Introduction**

The management of patients with cleft lip and palate deformities has been a real challenge to the clinicians for centuries. Most patients undergo surgery early in life; thereby the normal genetic growth potential of the nasomaxillary complex is inhibited resulting in midface retrusion and severe dentofacial deformity. Graber [1] documented three-dimensional maxillary collapse in patients with cleft lip and palate after surgery.

### Infancy lip and palate repair and maxillary growth

Several studies confirmed that the maxillary deficiency in early repaired cleft lip and palate cases is secondary to soft tissue scarring from previous surgical intervention [2-4].

Semb [5] in a cephalometric study found that repair of the alveolar cleft with a bone graft before the age of 12 years has no influence on the maxillary growth; this was again confirmed by Paulin and Thailander [6].

Shetye and Evans [7] concluded that the growth potential of the maxilla in unoperated cleft lip and palate patients is normal, while Williams, *et al.* [8], found that early surgical correction of clefts interferes with normal growth pattern and hence, midface retrusion and anterior crossbite is a common finding in patients with early repaired clefts. Recently, Yatabe, *et al.* [9] concluded that patients with complete cleft lip and palate show severe maxillary retrusion and often develop Class III skeletal pattern. Restoring normal dentoskeletal relationship may require complex presurgical orthodontic preparation to be followed by orthognathic surgery.

### Alveolar bone grafting to correct the cleft alveolus and palate

The lack of fusion between the embryonic sutures creates anatomic alteration and large bony defect in the alveolus and palate. Habbal and Reddi [10] reported that fresh autogenous bone grafts are generally accepted as the most effective method for the reconstruction of osseous defects and the stimulation of bone regeneration in the maxillofacial region.

Akadiri, *et al.* [11] advocated the iliac crest as a major cancellous bone resource for large alveolar bone grafting which has easy access, provides large quantity of bone, rich and rapid vascularization, high volume of osteogenic precursor cells, and relatively low donor site morbidity. Their technique stressed on preparing soft tissue envelope (mucoperiosteal flaps were extensively elevated to expose areas for graft augmentation) before packing and compacting the cancellous chips into the defect. Carlini, *et al.* [12] confirmed the superiority of the iliac crest donor area as the gold standard for large bony defects.

### Endosseous Implants after bone grafting

Comprehensive health care of patients with cleft lip and palate patient aims to restore normal dentofacial esthetic and function. Isono, *et al.* [13] considered that orthodontic treatment combined with alveolar bone grafting has become a well-accepted procedure. The application of endosseous implants over reconstructed bony defect for prosthetic restoration gave favorable results as reported by Verdi [14].

### Nasal reconstruction

Congenital nasomaxillary hypoplasia usually reflects an incomplete structural development of the entire nose (the nose is short, small, and retruded). Multiple nasal surgeries result in further excessive scarring at the columella-prolabial junction and lack of nasal projection [15]. Autologous rib cartilage graft usually provides maxillary augmentation and support for the nose [16]. Skin defects require tissue substitution normally provided by skin grafts. Tissue expansion was reintroduced and popularized by Rodovan [17] and offered a significant aesthetic advancement. Adamson [18] found that the expanded forehead flap prior to nasal reconstruction is relatively the most appropriate thin tissue to resurface the nose; borrowing local available tissues have the advantage of replacement of missing tissue or scar with similar tissue of the same color, thickness, texture and vascularity. The improved vascularity of the expanded tissue can increase bone graft survival rate significantly.

## Case Report

### Patient history and clinical background

Patient (Age 9 years 6 months) presented with a median cleft of lip and palate (premaxilla with four anterior teeth were lost) for whom initial surgical repair at an early age was performed. The maxilla exhibited a deficiency in three planes of space. There was an anterior and posterior crossbite with distorted occlusal plane and anterior open bite.

The patient's chief complaint was "I am unhappy with my facial appearance and I am concerned about my teeth, lips and nose, I want to look like my other friends". She had no history of significant medical problem.

**Clinical Examination**

**Extra-oral examination (Figure 1) revealed**

1. Concave facial profile due to midface retrusion.
2. Small depressed nose with flat alar bases (loss of nasal cartilaginous support).
3. Incompetent lips, thin repaired upper lip and full everted lower lip.
4. Class III Malocclusion.
5. Loss of four anterior teeth.
6. Mandibular deviation to the right 3 mm.
7. Obtuse gonial angle and backward Mandibular rotation.

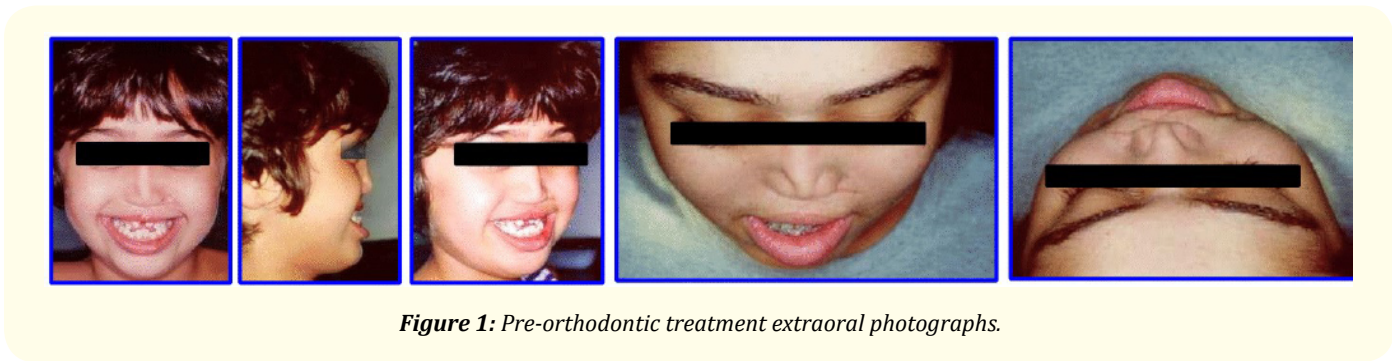


Figure 1: Pre-orthodontic treatment extraoral photographs.

**Intra-oral examination (Figure 2) revealed**

**Maxillary arch**

1. Median maxillary and palate cleft (loss of premaxilla and four anterior teeth).
2. Constricted and collapsed maxilla in 3-dimensions (contained within the mandibular arch).
3. Teeth present are: maxillary 1<sup>st</sup> permanent molars, deciduous molars and canines.
4. Parabolic anterior occlusal plane and collapsed anterior region caused evident anterior open bite of 3 mm.

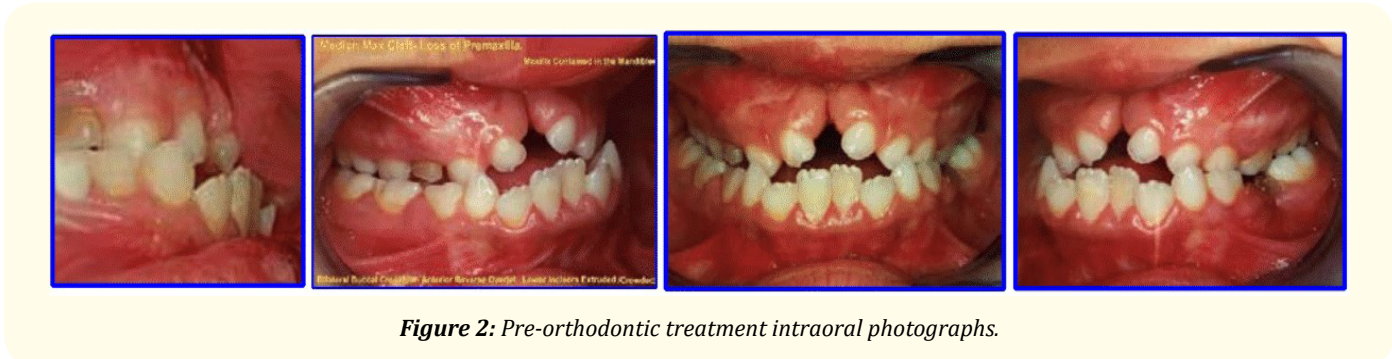

Figure 2: Pre-orthodontic treatment intraoral photographs.

**Mandibular arch**

1. Almost normal form and size mandibular arch.
2. Permanent teeth present are mandibular 1<sup>st</sup> permanent molars and four anterior teeth; deciduous canines and molars were all there.
3. Distorted occlusal plane and deep curve of Spee due to extrusion of unsupported lower central incisors.

**Interarch relationship**

1. Tendency to Class III molar relationship, anterior open bite and reverse overjet.
2. Total bilateral crossbite and slightly deviated mandibular midline to the right.
3. Lower dental midline deviation to the left 2 mm.

**Cephalometric analyses**

**Jarabak Skeletal and Legan Soft Tissue Lateral Cephalometric Analyses (Figure 3)**

Sagittally, maxilla and mandible were both retrognathic, the maxilla was severely retruded (70.9°) and the mandible slightly retruded (74.2°). Negative ANB angle of -3.3° revealed a Skeletal Class III malocclusion.

Vertically, Jarabak Analyses revealed an increased mandibular plane angle and tendency to long face with anterior open bite. Linear and angular measurements supported the clinical features and aided the formulation of a realistic treatment planning, these measures are: Increased lower anterior facial height, Increased Jarabak facial ratio, steep mandibular plane of 40.8° to S-N line (larger than normal by 8.8°) and increased lower anterior alveolar height occlusal plane to mandibular plane angle 27.4° (increased by 9.6°).

Lateral cephalometric analyses confirmed the concave feature of the face. Sub-nasion (Sn soft tissue) and soft tissue Pogonion to Glabella vertical were negative -11.5 mm and -13.7 mm respectively. Concerning lips incompetency; the upper lip was retruded 2.6 mm or -4 mm less protrusion and lower lip protruded 10.9 mm or 8.9 mm excess or everted.

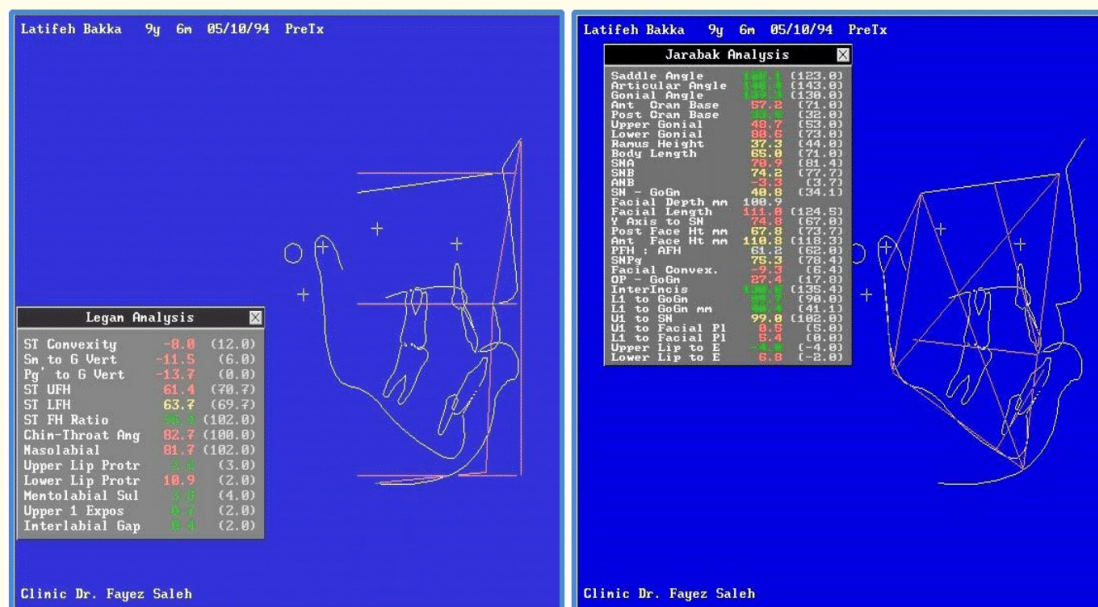


Figure 3: Legan Soft Tissue Analysis and Jarabak Lateral Cephalometric Analysis.

**Treatment Objectives**

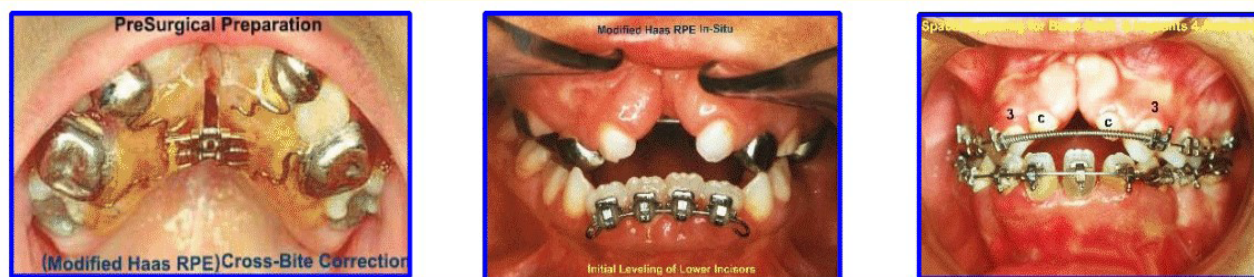
1. Facial esthetic improvement: Severe skeletal and soft tissue orofacial deformity necessitates a multidisciplinary orthosurgical treatment approach. Lip repair, nasal reconstruction and maxillary advancement (LeFort I maxillary osteotomy) were performed to correct maxillary deficiency, the cant of occlusal plane, and lip-teeth relationship.
2. Establish ideal static and functional occlusion: Improve dentoalveolar/skeletal/soft tissue relationship in 3 dimensions establishing satisfactory facial harmony and creating beautiful smile
3. Improve overall dental and periodontal health.
3. Improve oral function-quality of speech.
4. Maintain arch integrity and stabilize the treatment outcome.

**Treatment Planning**

Being a complex congenital malformation, cleft lip and palate cases require special care of highly qualified professionals from birth until adulthood.

In the present case with severe orofacial malformation, a detailed review of the problems and consultations with the medical and dental team of professionals were initiated. The orthodontist, who is responsible for the preparation and analysis of the records and data collection, organized the meetings and consultations with the maxillofacial surgeon, plastic surgeon, periodontist, oral surgeon, implantologist, prosthodontist, and general dentist. The following treatment sequence was suggested and agreed upon:

Presurgical comprehensive orthopedic/orthodontic treatment to restore the normal maxillary arch form and size, level and align maxillary and mandibular dentoalveolar arches and regain space for the lost maxillary four anterior teeth. The objective of this phase is to normalize palatal plane and create enough space in the premaxillary region to receive adequate bulk of bone graft which will carry the dental osteointegrated implants for future fixed esthetic prosthesis as shown in figure 4. The orthodontic movements were necessary to allow the surgeon to position the bony and dentoalveolar structures in the desired occlusion.

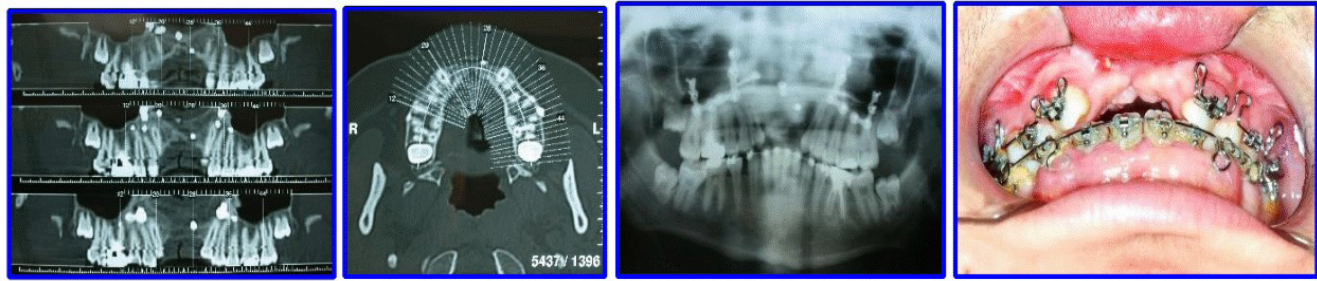


**Figure 4:** Presurgical orthopedic and orthodontic intervention.

**Surgical phase**

**Skeletal surgical correction**

Figure 5 shows the radiographic and clinical photo of the post orthopedic/orthodontic treatment progress or the surgical phase which includes LeFort I osteotomy and bone grafting: Le Fort I maxillary advancement with anterior occlusal plane correction to restore normal overbite and overjet which will facilitate lip closure and provide nasal base support.

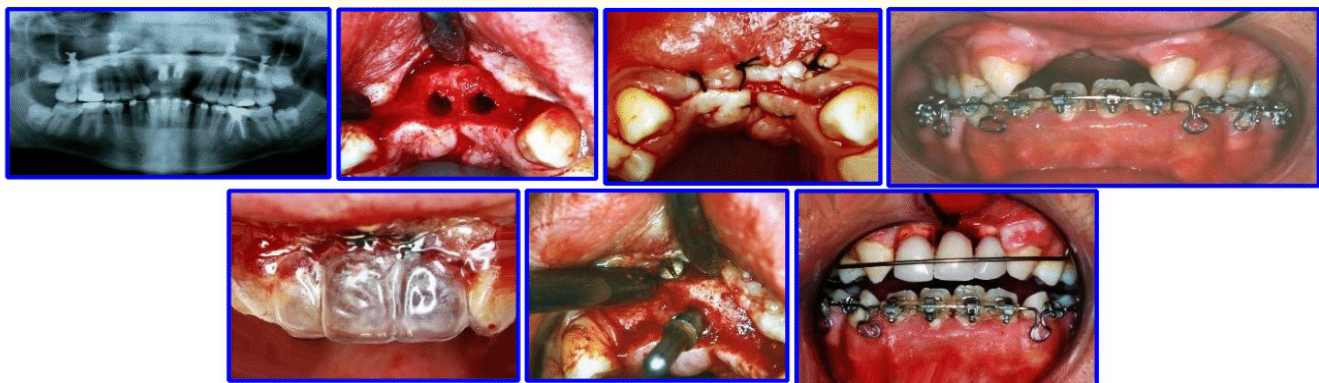

**Figure 5:** Surgical Phase: LeFort 1 Osteotomy and Bone Graft.

**Bone grafting the premaxillary defect**

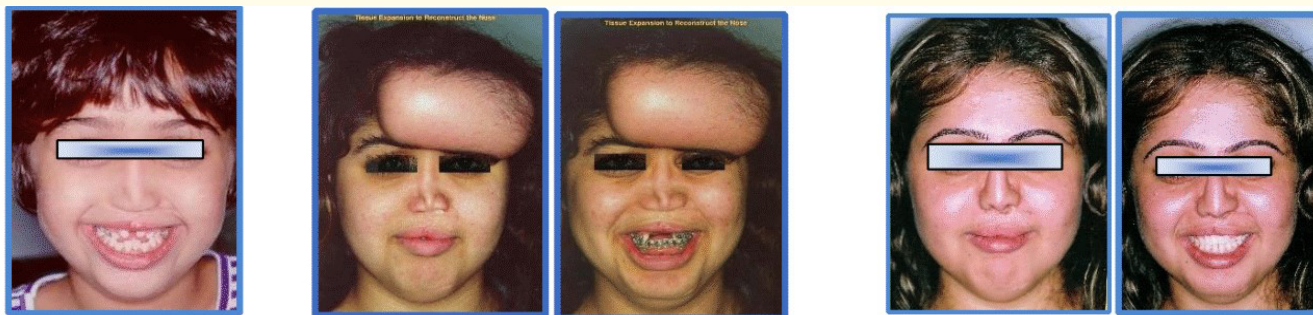
The primary purpose of the autogenous bone graft in our case is to restore the integrity of the maxillary arch and support two endosseous dental implants. Predictable enough quantities of cancellous bone from the iliac crest were used. Verdi [14] recommended the wedging of corticocancellous bone blocks into the defect. To provide the best chances of success, fresh autogenous particulate cancellous bone must be densely packed into the prepared entire cleft defect and retained by the soft tissues (Figure 5).

Two endosseous implants were successfully inserted into the bone grafted premaxillary defect giving the opportunity for the prosthodontist to construct a removable temporary prosthesis (Figure 6).



**Figure 6:** Surgical repair, Bone graft, Endosseous Implants and Temporary Bridge.

**Soft tissue repair:** Nasal Reconstruction: The repair of the incomplete structural development of the nose has already been started with establishing the bony base, premaxillary bone graft. Nasal skin defect was corrected by expanding the forehead tissues. The pedicle skin flap resurfaced the cartilage rib graft and recreated the columella and alae. This new skin/cartilage relationship improved nasal support and improved aesthetic balance (Figure 7).



**Figure 7:** Nasal reconstruction (Frontal Tissue Expansion) and post-surgical phase photographs.

**Post-surgical orthodontic care:** This phase consisted of settling and detailing of occlusion. Five weeks after surgery, the patient is asked to wear heavy inter-maxillary elastics for six weeks to stabilize the mobilized bony parts and maintain the achieved occlusal relationship. Finally, Hawley removal maxillary retainer and mandibular lingual bonded retainer were used.

**Prosthetic phase:** The development of osteointegrated implants made fixed prosthetic solution for patients with cleft lip and palate possible [19]. Temporary acrylic fixed restoration was loaded immediately after implants insertion. Finally, a permanent fixed esthetic ceramic prosthesis replaced the lost anterior teeth restoring normal overbite, overjet and upper lip support.

### Treatment Progress

The pre-surgical orthodontics care took approximately one year. Initially, orthopedic rapid palatal expansion using Haas Appliance preceded leveling and alignment to restore the normal arch form, reduce the anterior open bite and straighten the divergent occlusal planes to be corrected later by surgical procedures.

Presurgical records, computer-assisted surgical plan and model surgery facilitated counseling and discussion with the members of the interdisciplinary team for final decision.

Surgical phase involved alveolar bone grafting, a Le Fort I osteotomy. Maxillary esthetic occlusal plane was accomplished and normal exposure of maxillary incisors yielded satisfactory lip-teeth relationship. Mandibular plane anticlockwise rotation further reduced the lower anterior facial height and improved the gonial angle harmony with the anterior facial anatomy. Normal lip closure and function is most likely responsible for the stable correction of open bite.

### Results

A remarkable improvement in facial contour was realized. Lower anterior facial height was reduced by 8.3 mm (angular 11.3°); lips became competent at rest and teeth-to-lip relationship created a beautiful smile, alar bases favorably widened improving nasal esthetics. Normal skeletal and dental maxillomandibular relationship was achieved and an ideal overjet, overbite, and midline were established (Figure 8 and 9).

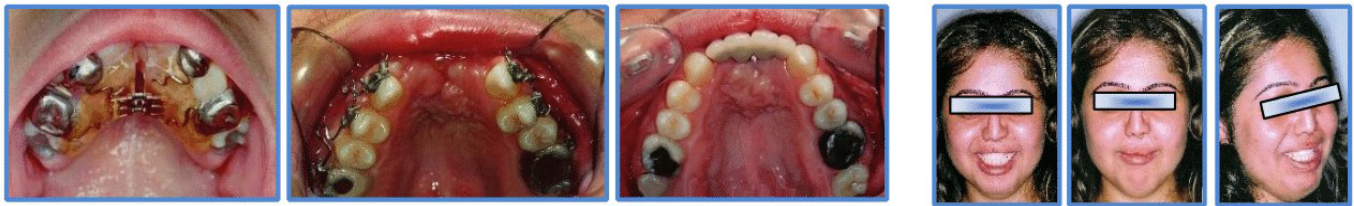

Figure 8: Finishing stage, arch integrity and facial esthetics.

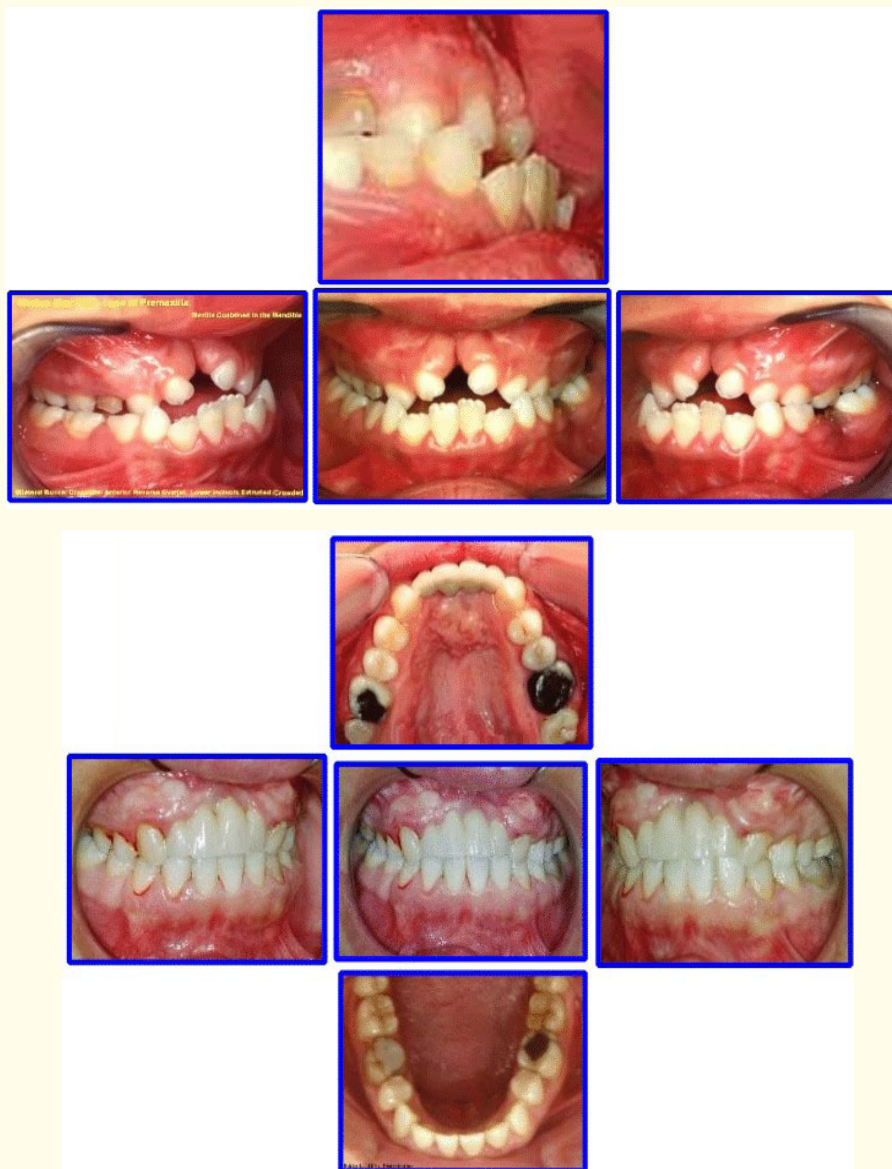

Figure 9: Pretreatment Occlusion.



Cephalometric superimposition confirmed the improvements in terms of substantial reduction in the vertical linear and angular measurements figure 10. Autorotation of the mandible advanced the Pogonion 8.0 mm which necessitated similar 9.4 mm advancement of the superior positioned maxilla to coordinate both arches and increase the nasopharyngeal vital space.

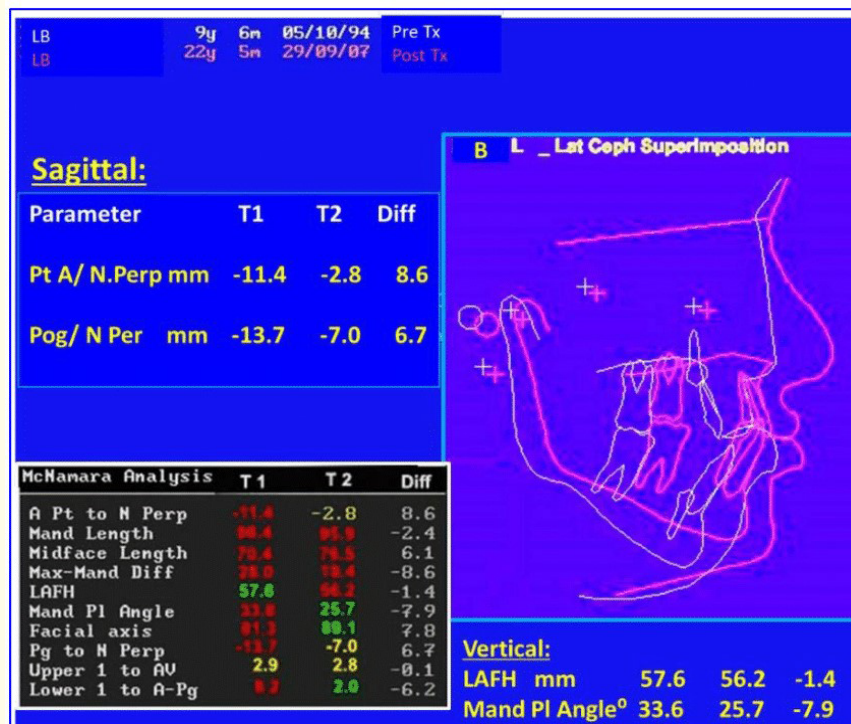


Figure 10: Lateral Cephalometric superimposition.

Figure 11 depicts the esthetic improvement of the oro-nasal features post-treatment and 3 years postretention.

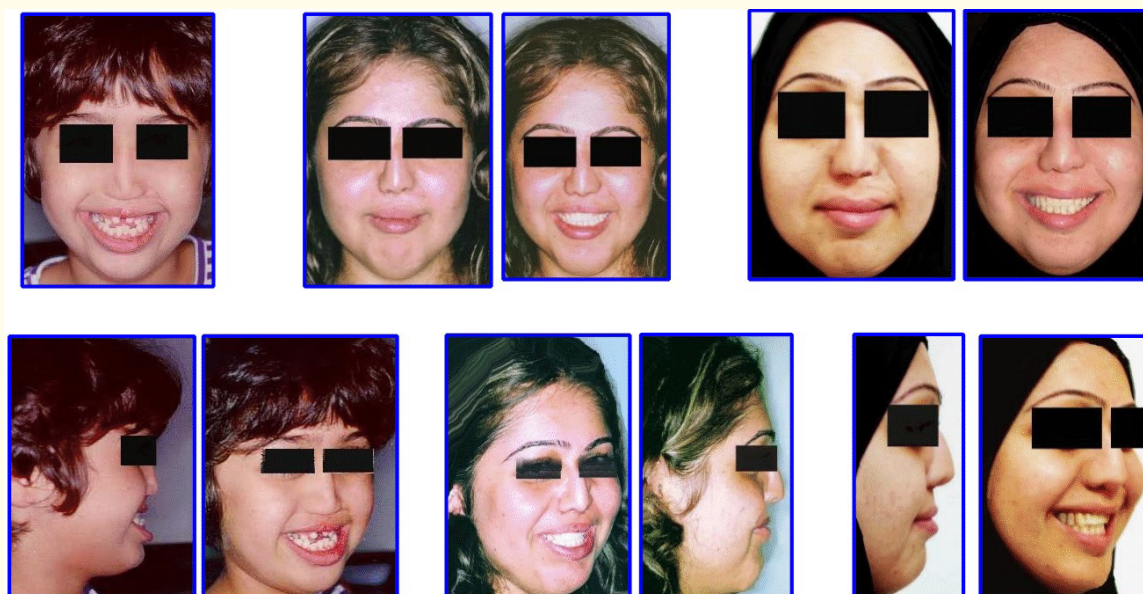

Figure 11: Frontal and Lateral Facial views, from PreTx to Post Tx to Post retention.

### Discussion

The clinical practices presented in this report reflect our current knowledge and experience. However, the performed complex orthodontic surgical procedures over a long period of time almost 13 years, for the presented case, involved orthopedic/orthodontic treatment followed by several complicated craniofacial surgeries. Minor and major orofacial surgeries comprised: Alveolar bone grafting, Le Fort I osteotomy to correct maxillary skeletal disharmony in three dimensions, lip repair, nasal reconstruction from autogenously tissue graft, and occlusal plane correction to achieve normal lip-teeth relationship and esthetic smile. Regardless of the patient and parents' satisfaction with the orthosurgical outcome, there appeared many constraints and limitations throughout the long duration of treatment; the time, financial, psychic and social stresses were only few to mention. The patient and parents' expectations and enthusiasm were faded because of the shuttle movement from a private practice to another and then to a hospital for a school-aged girl.

Although the case was classified as Class III malocclusion, angle ANB was almost normal ( $ANB = 1^\circ$ ) and the skeletal maxillomandibular sagittal relationship was orthognathic. The results of this study demonstrate that the conformity between clinical and Cephalometric diagnosis do not necessarily reflect the real dentofacial anomaly. Cephalometric measurements can be affected by the inclination and length of S-N line, by the rotation of the jaws, and by the anterior facial height abnormality. According to Linder-Aronson and Woodside (2000) [20], increased lower facial height and backward and downward mandibular rotation are responsible for masking the Class III malocclusion; and the true value of ANB angle would be revealed if the excess vertical height was reduced.

### Conclusions

The unavailability of medical centers with a well-trained independent craniofacial professional team, even in large health institutions in Lebanon, calls for developing an interdisciplinary team in which all members are involved in conducting a joint evaluation (face-to-face group meeting) and negotiate a comprehensive treatment plan.

The team approach should respond to the needs of patients and parents and meet the international standards of good quality health care. This necessitates:

1. The quality of care should be carefully monitored by the team
2. Periodic review of the treatment outcome data
3. Reporting to health care decision makers and health authorities.

### Conflict of Interest

The authors declare that there is no conflict of interest regarding the publication of this paper”.

### Bibliography

1. Graber TM. “A cephalometric analysis of the developmental pattern and facial morphology in cleft palate”. *Angle Orthodontist* 19.2 (1949): 91-100.
2. Bishara SE., *et al.* “Cephalometric comparisons of individuals from India and Mexico with unoperated cleft lip and palate”. *Cleft Palate-Craniofacial Journal* 23.2 (1986): 116-125.
3. Capelloza L., *et al.* “Craniofacial morphology of adult unoperated complete unilateral cleft lip and palate patients”. *Cleft Palate-Craniofacial Journal* 30.4 (1993): 376-381.
4. Mars M and Houston WJB. “A preliminary study of facial growth and morphology in unoperated male unilateral cleft lip and palate subjects over 13 years of age”. *Cleft Palate-Craniofacial Journal* 27.1 (1990): 7-10.
5. Semb G. “Effect of alveolar bone grafting on maxillary growth in unilateral complete cleft and palate patients”. *Cleft Palate-Craniofacial Journal* 25.3 (1988): 288-295.

6. Paulin G and Thailander B. "Dentofacial relations in young adults with unilateral complete cleft and palate. A follow-study". *Scandinavian Journal of Plastic and Reconstructive Surgery and Hand Surgery* 25.1 (1991): 63-72.
7. Shetye PR and Evans CA. "Midfacial Morphology in adult Unoperated Complete Unilateral Cleft Lip and Palate Patients". *Angle Orthodontist* 76.5 (2006): 810-816.
8. Williams AC., et al. "Cleft lip and palate care in the United Kingdom- The Clinical Standards Advisory Group (CSAG) Study. Part 2: dentofacial outcomes and patient satisfaction". *Cleft Palate-Craniofacial Journal* 38.1 (2001): 24-29.
9. Yatabe M., et al. "Bone-anchored maxillary protraction therapy in patients with unilateral complete cleft lip and palate: 3-dimensional assessment of maxillary effects". *American Journal of Orthodontics and Dentofacial Orthopedics* 152.3 (2017): 327-335.
10. Habbal MB and Reddi AH. "Bone grafts and bone substitute". W.B. Saunders Co., Philadelphia, USA (1992).
11. Akadiri OA., et al. "Tertiary bone grafting with or without premaxilla osteotomy in adult alveolar clefts- Techniques and early outcome". *Open Journal of Stomatology* 2 (2012): 122-129.
12. Carlini JL., et al. "Pilot study of ore-maxilla replacement and bone graft in a patient with lip and palate clefts: transforaminal relationship between upper canines and bone graft". *Dentistry* 3000 3.1 (2015): 1-8.
13. Isono H., et al. "The reconstruction of bilateral clefts using endosseous implants after bone grafting". *American Journal of Orthodontics and Dentofacial Orthopedics* 121.4 (2002): 403-410.
14. Verdi FJ. "Use of Brånemark implant in the cleft palate patient". *Cleft Palate-Craniofacial Journal* 28.3 (1991): 301-305.
15. Grayson B and Garfinkle JS. "Early cleft management: The case for naso-alveolar molding". *American Journal of Orthodontics and Dentofacial Orthopedics* 145.2 (2014): 135-142.
16. Cakmak O and Ergin T. "The versatile autogenous costal cartilage graft in septorhinoplasty". *Archives of Facial Plastic Surgery* 4.3 (2002): 172-176.
17. Rodovan C. "Tissue expansion in soft tissue reconstruction". *Plastic and Reconstructive Surgery* 74.4 (1984): 482-489.
18. Adamson H. "Nasal reconstruction with expanded forehead flap". *Plastic and Reconstructive Surgery* 81.1 (1988): 12-19.
19. Brånemark PI., et al. "Rehabilitation of Complex Cleft Palate and Cranio-maxillofacial Defects". Quintessence Publishing Co, Inc., Chicago, USA (1999).
20. Linder-Aronson S and Woodside G. "Excess face height malocclusion: etiology, diagnosis, and treatment". Quintessence, Chicago London (2000).

**Volume 17 Issue 3 March 2018**

**©All rights reserved by Wisam Al Hamadi., et al.**