

The Use of Resorbable Plate or Lag Screw in Fixation After Genioplasty a Comparative Study

Hiam Kesho¹, Jamal Dabbas² and Yamen Tarakji^{3*}

¹Professor in the Department of Oral and Maxillofacial Surgery, Faculty of Dentistry, University of Aleppo, Aleppo, Syria

²Teacher in Orthodontic Department, Faculty of Dentistry, University of Aleppo, Aleppo, Syria

³Department of Oral and Maxillofacial Surgery, Faculty of Dentistry, University of Aleppo, Aleppo, Syria

***Corresponding Author:** Yamen Tarakji, Department of Oral and Maxillofacial Surgery, Faculty of Dentistry, University of Aleppo, Aleppo, Syria.

Received: November 21, 2017; **Published:** December 20, 2017

Abstract

Aim: The aim of this study was to assess the hard and soft tissue response and complications after osseous genioplasty using resorbable fixation technique.

Material and Methods: 12 adult patients were prepared for osseous genioplasty. resorbable lag screw (19 X 2,5 mm) was used in 7 cases for fixation, and resorbable X plate with 4 screws (11 X 2 mm) were used to fix 5 cases.

Results: No significance changes in nose, upper lip or lower lip. Labio mental corner was decreased by 17° (P < 0.05). The soft tissue of the chin was found to follow the bony movement at a ratio of 1:0.94 (P < 0.05) when using resorbable lag screw in fixation and no complications were noticed, the using of resorbable plate and screw in fixation is not potential.

Conclusion: We conclude that two resorbable lag screw is an effective method for fixation after genioplasty with satisfactory soft tissue response for skeletal movement and has minimal complications, and the use of X plate was not satisfactory.

Keywords: Resorbable Plate; Lag Screw; Genioplasty

Introduction

The chin achieves an important function in the coordination and facial harmony in the sagittal level and has an important role in achieving the symmetry and harmony of the facial frontal view. Therefore, the surgical procedure on the chin area is often to correct the facial profile and as an auxiliary procedure for correcting facial asymmetry [7].

Anatomical consideration

Chin: Is the region located between the lower lip and the lower surface of the anterior area of the lower jaw. The covering skin varies from thin flowing with the lower edge of the lip to a thick called chin pad, which is located on the most prominent part of the mentum. Under the skin notes the thick subcutaneous layer and many muscles can be distinguished. Another important view is the Labiomental fold or Labiomental Sulcus, which is located between the red lip and the chin pad [1,33].

Mandible and Teeth: The anatomical distinctive marks on the mandible are the mental protuberance and mental tubercle and mental foramen which are usually located below premolars roots, we should be careful to make the osteotomy below the roots of lower canines 5 - 8 mm to avoid injury to the roots of the other teeth and prevent fractures of mandible as a post-osteotomy complain and allow to make a perfect installation away from the roots of the teeth.

Nerve supply: The inferior alveolar nerve enters from the mandibular foramen within the mandibular canal to give off the mental foramen and then called the mental nerve, but before it appear from the foramen almost will be 4 mm below the foramen and make loop 3 - 5 mm forward then back and up to get out of the mental foramen so at any way the osteotomy should be done 5 - 6 mm below the mental foramen to avoid mental nerve injury [35,36], mental nerve supply the sensory to the chin and lower lip area [33] and the chin receive more sensory supply from the mylohyoid nerve and lingual nerve and cervical plexus [23,33].

Muscles: When we make the intra oral incision we should aware the mentalis muscle which situated at the tip of the chin, It originates from the mentum and inserts into the chin soft tissue as in the shape 7, This muscle lifts the lower lip leading to a wrinkle in the chin skin, and laterally we found orbicularis oris muscle, and the marginal branch of the facial nerve supply those muscles, at the lingual surface of the chin we can see suprahyoid muscles which are very important for the tongue movement, which are genioglossus geniohyoid and anterior belly of digastric shape 8, this muscles are very important for the blood supply for the free bone segment after osteotomy, It is responsible for repairing the cervical angle, which is often indicated in advanced genioplasty, as for the mentalis muscle the suturing of its fibers very important to avoid chin ptosis [1].

The surgical technique used in genioplasty

Alloplastic [58] Osseous genioplasty

Include horizontal osteotomy with advanced genioplasty, horizontal osteotomy with anterioposterior reduction, vertical reduction genioplasty, vertical augmentation [6], genioplasty for widening the chin, genioplasty for narrowing of the chin [42,71], and asymmetric genioplasty [72], also modified osteotomy line include double sliding horizontal osteotomy [73], Tenon technique [74], sagittal curving osteotomy [63], and functional genioplasty to treat obstructive sleep apnea [45,75,76].

Fixation after osseous genioplasty: Wires or plate and screw or lag screw or absorbable fixation materials can be used for fixation after chin osteotomy [30].

Tissue response after surgery: Osseous Genioplasty is a consistent surgical procedure, most changes in soft and solid tissues occur during the first 6 months, long term studies shows there is no changes in the outcome of this procedure. The amount of relapse on the bone tissue is very small and the soft tissue response to the hard tissue movement are at the upper limits and that a completely acceptable and stable change occurs over time, especially in cases of chin advanced [116-118].

Hard tissue response: That each of the following factors: osseous repositioning [30], fixation used technique [8], also the amount of chin advancement [67], and the amount of soft tissue dissection [5] are very important to affect the rate of hard tissue response.

Soft tissue response: The amount of dissection is the main factor that affect the response of soft tissue response to the hard tissue movement, and when it is in the minimum rate the soft tissue follow the hard tissue without any chin ptosis [116,118,128,130].

And in the next table we found the soft tissue changes after advanced genioplasty.

Soft tissue changes after advanced genioplasty			
Chin (H*)	0.75:1	Pgs†:Pg‡ ant. Sliding	Bell, dann (1973) [119]
Chin (H)	0.75:1	Pgs:Pg horizontal(some multistep)	Mcdonnel., et al. (1977) [120]
Chin (H)	0.67:1	Horizontal W\proad soft tissue	Proffit, epker (1980)
Chin (H)	1:1	pedical IVRO¥setback	Bell (1980) [40]
		Pgs: pg(some w\ osteotomy)	
Chin (H)	0.83:1	Pgs:pg horizontal w\broad pedicle	
Chin (H)	0.97:1	(IVRO setback)	Busquets, sassouni (1981) [150]
		horizontal w\broad pedicle	Scheideman., et al. (1981) [129]
Chin (H)	0.85:1	pgs: pg advanced only horizontal	
Chin (H)	0.81:1	sliding with broad bidcle	Bell, gallegher (1983) [130]
		pgs: pg Adv. And vertical reduction, horizontal sliding w\ broad pedicle	
Chin (H)	0.93:1	max impacction	Gallegher., et al. (1984) [116]
		horizontal	
		pgs:pg overlapping bone flap	Epker, fish (1986)
Chin (H)	0.7:1	pgs:pg horizontal w\ broad pedicle	Tulasne (1987)
Chin (H)	0.73:1	pgs: pg	Park., et al. (1989) [118]
Chin (H)	0.97:1	pgs: pg	
Chin (H)	1:1		Kerkmanov, kahenberg (1992) [121]
Chin (H)	1.1:1		Ewing, ross (1992) [151]

*H: Horizontal

†Pgs: soft tissue pogonion

‡Pg: pogonion

¥IVRO: Intraoral vertical ramus osteotomy

And in the next table we can note the changes in soft tissue at the vertical standard.

The changes in soft tissue at the vertical standard			
Augmentation			
Chin (v¥)	1:1	Interpositional	Wessberg, <i>et al.</i> (1980)
Reduction			
Chin (v)	-0.25:1	Mes+:me- inf. Border Ostectomy\ degloving dissection	Hohle, epker (1976) [132]
Chin (v)	0.26:1	Pgs: pg horizontal w\ broad pedicle	Park, <i>et al.</i> (1989) [118]
Chin (v)	0.35:1	Mes:me	Krkmanov, kahnberg (1992) [121]
Chin (v)	0.4;1	Mes:me	Ewing, ross (1992) [151]

¥V: Vertical

+Mes: Soft tissue menton

-Me: menton

Complications after osseous genioplasty

Sensitivity dysfunction [140], severe absorption or free bony segment necrotic due to lack of blood supply [141], hemorrhage hematoma [6], chin ptosis [142], necrotic pulp for the tooth [6], infection [6], mandible fracture [143], gingival rescission [6], and asymmetry [6].

Aim of Study

- This search aim to asses clinically and radiology for two different methods in fixation after genioplasty, resorbable lag screw and resorbable plate and screw in this points.
- Comparative Radiological study for soft and hard tissue response in the chin and compare it with the old study that already use different fixation techniques in the middle term.
- Asses the sensitivity response in chin area in the middle term.
- Asses the tooth sensitivity.
- Asses the after surgery complains infection, mentalis muscle dysfunction, wound healing, and the degree of patient acceptance of the outcomes of surgery.
- Detect the bone tissue healing in the osteotomy line by radiologically.

Materials and Methods

The sample of study have 12 patient 8 females and 4 males between 18 - 25 years age from the patient of the orthodontic department of dentistry college Aleppo university and the treatment plan for them include advanced genioplasty to improve the facial profile within the orthodontic treatment.

The sample divide to a

- Group A: The suggested fixation for this group after advanced genioplasty by using tow resorbable lag screw (RLS).
- Group B: The suggested fixation for this group was resorbable x plate with 4 screws at the mid line (RPS) and the follow up range 6 month for both.

Principles of Sample Selection

- The case study and the orthodontic treatment plan confirmed that advanced genioplasty should be done to correct the facial profile.
- All the patient have no periodontitis and have good oral hygiene.
- All the patient healthy and they have no medical history prevent the surgical procedure or healing for soft and bone tissue or muscle activity.
- All the sample have no previous surgical procedures on head and neck area.
- The ages of the sample from 18 to 30 as a maximum.
- The approval of the patient and respect for the Helsinki Convention.

Place of the search

- The cephalometric and panoramic x ray and radiological study were done in the department of dentofacial orthodontic in dentistry college university of Aleppo.
- All the laboratory tests and surgical procedures and clinical follow up were done in the maxillofacial surgery department.
- The radiological study by using computed tomography done in the university of Aleppo hospital.
- The medical consultation done in the department of internal medicine- Aleppo university hospital.

The material of the search

The fixation materials used after osseous genioplasty are a resorbable plates and screws from INION company which is specialized company in production of bioresorbable materials used for fixation in maxillofacial trauma and orthognathic surgery for maxillofacial area and we depend on the compact power system CPS which has been produced from 2001 from INION for clinical procedures in oral maxilla facial, craniofacial, and replastic mandibular surgery after mandible removal surgeries.

The chemical composition for this system: The co-polymers used for this product consists of L-Lactide, D-Lactide, Polyglycolide, TMC, and all of this polymers are safety for clinical use, and from the Self-Reinforced type and the percentage of each polymer is differ depend on the indication to use the product but the strength and adaptation ability and metabolism pattern considered as the most important clinical features for this materials.

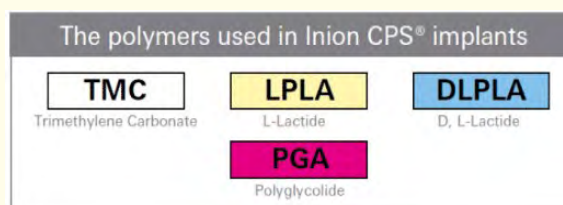


Figure 1: The chemical composition of polymers.

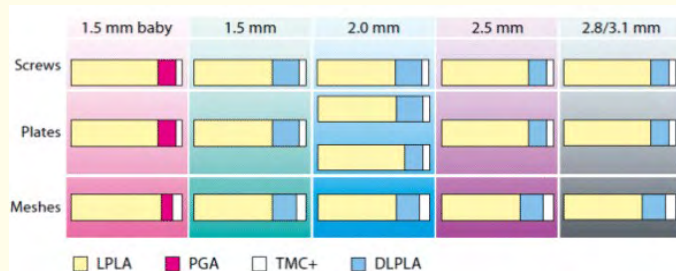


Figure 2: The polymer percentage for each product.

Degradation pattern: The polymers used in CPS are amorphous and in the laboratory hydrolysis happens to her but in the body degradation and metabolism happen for this polymers to produce water with CO₂ and this system have enough fixation period and then slowly decompose to replace with bone tissue and this material strong enough for 6 - 12 weeks and full decomposition happens after 12 months.



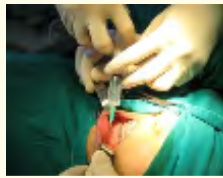
Figure 3: Degradation of polymers.

And we select this products of INION for work.

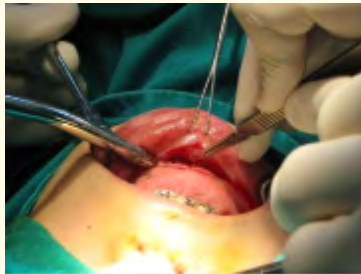- Resorbable lag screws 19 X 2.5 mm
- X resorbable plate shape from Cps 2 mm
- Fixation resorbable screw 11 X 2 mm
- Sterilized curtain for special water heater
- Special water heater
- Special surgical kit of INION
- Panoramic and cephalometric x-ray devise from GENDEX
- CT scan from Siemens in radiology department of Aleppo university hospital
- Surgical instrument included the Vibratory electric saw to perform the osteotomy from Striker.

Search form application.

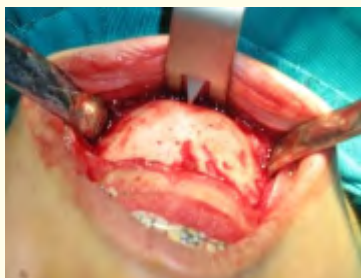3. Local anesthesia lidocaine 2% with adrenaline 1/80000 in the vestibule to decrease the bleeding and facilitate the dissection.



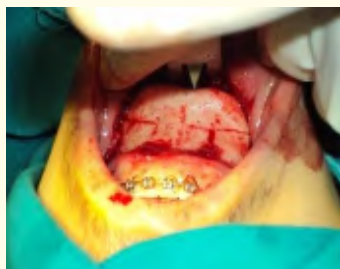4. Surgical incision from the lateral of the canine to the lateral of the canine from the opposite side 5 mm below the mucogingival connection.



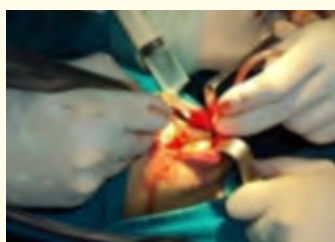5. Decision: subperiostium decision done to expose the bone and the lower border of mandible then the mental foramen from the two sides then we isolate the mental nerve and special retractor for the chin applied.



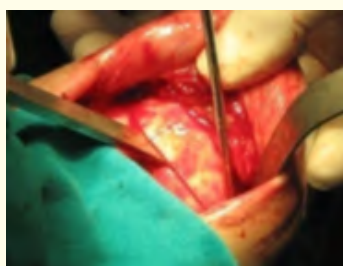
6. The facial midline marked on the chin the we draw equal lines at the 8mm two sides of the midline the we mark the osteotomy line by using fine drill.



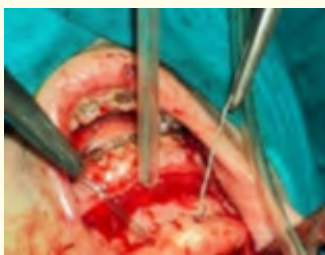7. The Vibratory electric saw used for complete osteotomy in one movement to include the cortical bone from labial and lingual sides.



8. We can use the chisel to perform the osteotomy from the lingual side.

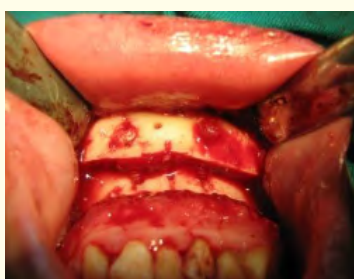

9. Small hole at the tow side of the midline near to the osteotomy line done at the free bone segment and insert wire inside to control the movement of the bone segment and fixed it in the new position.

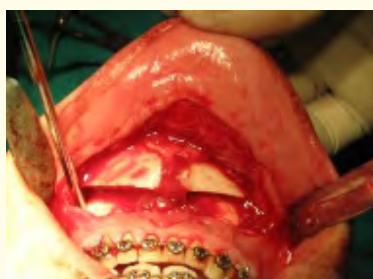

10. The new position for the chin detected while the amount of the advanced the same in the treatment plan and then the fixation.

11. In case the fixation by using lag screws small cavity at the cortical bone made by using small rounded drill and use the designed drill (diameter 2 mm) to perform the canal for the screw which pass throw the segment and the mandible (three cortical bone fixation).

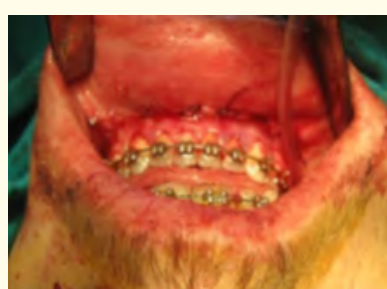
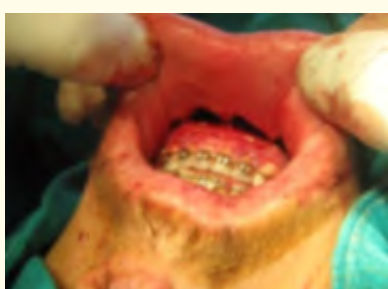
12. In case the fixation by using plate and screws the same step performed then we adapt the x plate by using enclosed heater full with saline temperature from 45 - 49, the plate insert in water for 7 - 10 min and the adaptation speedy done at a shape of metal wire we already adapt and it take the desired shape after 10 seconds the plate is x shape plate from Cps2 equal to a titanium 1.7 mm plate, placed at the midline and fixed by using 2 screws at each side of the osteotomy line 2 x 11 mm.



13. The suturing done double layer first the fiber of the mentalis muscle by using vicryl 0-3, second we close the oral mucosa by contentious suturing from the midline to the end and from the midline to the other end side.

14. Chin bandage apply.



The after surgery procedures:

- Patient stay in hospital for 24h
- Remove the bandage after 5 days
- Coverage with antibiotic and anti-inflammatory
- Remove the suture after 10 days

Examinations after surgery:

1. Check the incision if the wound open or there is any infection and the stability of the bone segment
2. Check the disturbance in sense in lip and chin and teeth sensitivity
3. The function of mentalis muscle
4. The patient satisfaction with the outcome of the surgery

Radiological study

Panoramic x-ray: was done before the surgery in purpose to check if there is any dental problems and to assess the inferior alveolar canal and the position of the mental foramen.

Cephalometric x-ray: was done for all the patient in central occlusion position and the relaxed lips in different times.

1. T0 before the surgery in purpose to make the cephalo design and radiological setup and make decision for the advanced amount and the place of osteotomy
2. T1 24 - 72h after surgery to assess the stability and fixation for the bony segment
3. T2 1 month after surgery to reassess the soft and hard tissue changes
4. T3 3 month after surgery to reassess the soft and hard tissue changes
5. T4 6 month after surgery to reassess the soft and hard tissue changes and fix this results at the medium term

Describe the cephalometric study: Detected and selected landmarks to draw lines and detect angles and perform the measurement for specific standards detect the chin position and the defect to take the right decision for the surgery and give us expected cephalo design by radiological setup, and all the points and lines and standards in the table 3 and 4.

Points on hard tissue	
Center of sella	S
Higher point at external auditory	Po
Lower points at the lower border of orbit	OR
Most anterior point of nasal frontal suture	N
The most deep point at the anterior border of maxilla	A
The most deep point at the anterior border of mandible	B
Most anterior point on nasal spin	Ans
The most anterior point at the chin	Pog
The lowest point of the lower border of chin	Me

Table 3: The bony points used in study.

Points on the soft tissue	
Skinny point equal to N on the bone	N'
The most anterior point on the soft tissue of the chin	Pog'
The lowest point at the border of the soft chin	Me'
the most deep point at the labiomental sulcus	Mlf
Tip of the nose	Pn
The connection point between the upper lip and columella	Sn
Mid of columella	Cm
The most anterior point at the upper lip	Ls
The most anterior point at the lower lip	Li
The most lower point at the upper red lip	Sts
The most higher point at the lower red lip	Sti

Table 4: The soft tissue point for study.

Cephalometric analysis: We consider Frankfort standard FH from Po to Or with the column from N as a references lines for all the studied values, this tow lines fixed on a paper and consider It is a single sheet in the demarcation on all subsequent radiographs with three clear marks on all the images which are S-Ans-N.

Bone tissue parameters

Parameter	Normal	Aim of Parameter
S N A	82	Axial assessment of skeletal basics
S N B	80	
A N B	+2	
N-A-Pog	165 - 175	Axial expected changes for chin
Pog - macnamara	0 - 4 mm	Axial expected changes for chin
N-Ans/Ans-Me projected to macnamara	44/56	Vertical expected change for chin
Angel between N-Pog with FH	88+-3,6	Axial expected changes for chin

Table 5: The bonny studied parameters.

Table 6: The soft tissue studied parameter.

Aim of analyses	Normal	Parameter
Nasofacial angel	22,8	Evaluation of the sagittal emergence of the nose
Nasolabial angel	102+-8	
The distance from the deeper point in mentolabial sulcus from macnamara		Evaluation of the mentolabial sulcus axially and vertically
Mantolabial angel	122+-11	
Pog' from Gonzales, ulloa, stevens	0 mm	Pog' Axially
Z angel of Mairfield	90-92	Pog' Axially
Tip of nose from zimmer line	2:	Evaluation the thickness of soft tissue
Tip of upper lip from zimmer line	1:	
Tip of lower lip from zimmer line	1:	
Pog' from Zimmer	1:	
Thickness of lower lip-Mairfield	12	Comparison of changes in soft tissue thickness
Thickness of upper lip-Mairfield	12	
Thickness of the chin-Mairfield	12	
N'-Sn/Sn-Me'	43/57%	Evaluation of facial aesthetics at the vertical level
Sn-Sts/Sts-me'	1/2	The condition of the lower third of the face vertically

The cephalometric study done To give a prior expectation of the surgical progress, and the expectation result.

Computerized tomography (CT): We make it to detect the healing bone tissue progress after fixation, is it direct or indirect healing?

The study:

1. CT for the mandible
2. Axial slides with 1mm width taken
3. This slides processed by the computer to get coronal and sagittal 1 mm slides
4. 6 vertical slides made 3 on each side of the midline and we calculate the bone density in each slide by a point up to the osteotomy line and one at the line and one below by Hounsfield, the Arithmetic mean for this point detect and put in a special table for each patient.

If there is difference between the results of measurement that means there is a space and the healing progress indirectly and if the difference not significant that means there is a contact between the free bony segment and the mandible and the healing progress is direct type.

The assessment of the sensation in the lower lip: the sensation assessment made by test the tingling using the dental probe at the right and left side if the test was positive we give sign +, if negative or confused felling we give sign -, and also test the touch by moving the tip of the probe on the lip from right to left or from left to right in case the patient realize the filling and the direction of probe tip movement we give +, in case the patient have no ability to detect the filling we give sign.

This tests done when the patient is blindfolded and one of the student in the department of oral and maxillofacial not by the researcher and we make it 2 weeks, one month and six month after surgery.

Assessment the vitality of the tooth

We test the vitality of the tooth from right lower canine to the left one by using Ethyl chlorine in case no response we record the tooth number, this test done after 27 hours, 2 weeks, 2 weeks, 6 weeks after surgery.

Assessment the complications of surgical procedure:

1. The mentalis muscle function: the assessment done like in the table.

Before Surgery	Hyperactivity	Normal	
After surgery	Hyperactivity	Normal	Dysfunction

2. The infection, fixation, wound opening, and asymmetry: in case there is any complication we record in the file of the case.

The patient comfort for the result: we ask the patient how do you see the result, and are the changes excellent or good or never mind or bad.

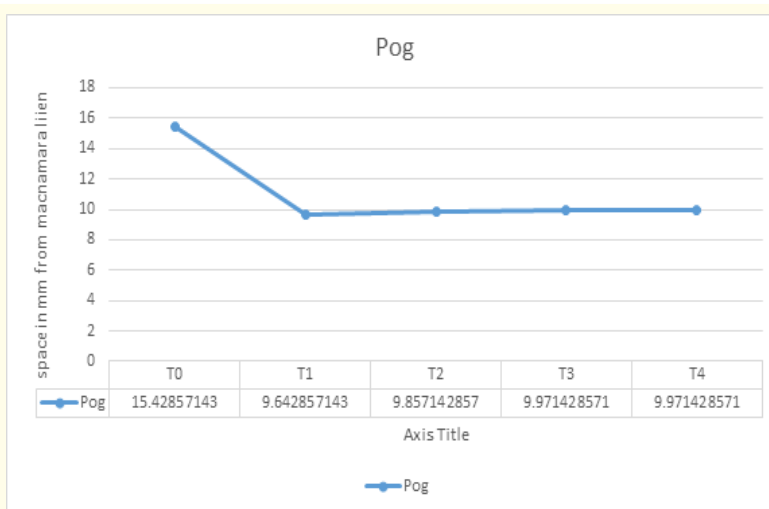
Results

Study results for the group A: the study include 7 patient we make osteotomy genioplasty with advanced 5.78 mm in average 4 mm the minimum advance and 7 mm higher advance.

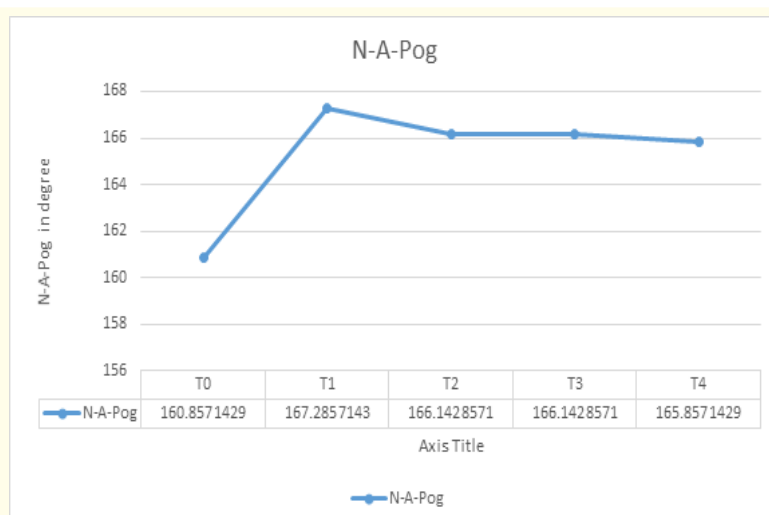
The skeletal cephalometric results

Changes for point Pog: The results showed that the distance between Pog and McNamara line has been changed by the same amount of advanced 5.78 mm in average and the relapse or the bone resorption was 0,33 mm in average with 0 mm minimum value and 0,5 mm higher value.

This relapse has Statistical significance ($P < 0,05$) but clinically not significant and the chart below show the changed amount in the distance between Pog and McNamara line during the study.



The result for angel N-A-Pog: We note that this angel increase when the amount of advancement increase and it increase in average 6,5 degree (5,52 - 7,6 degree) and that means very good improvement in the facial profile, and the relapse was 1,4 degree and that was statistically significant ($P < 0,05$) but clinically not significant, whereas the relapse for Pog 2 mm to get clinically significant means reduction in the angel value by 2,5 degree, and the chart explain the changes in the value of N-A-Pog during the study.

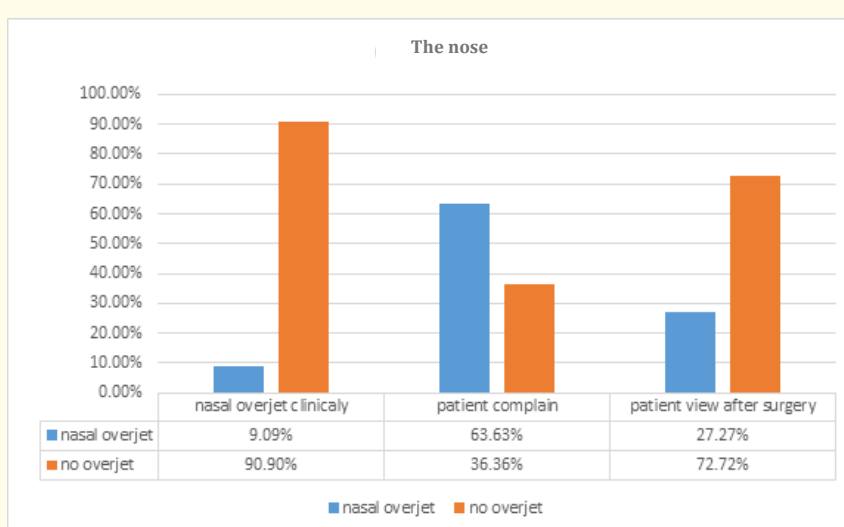


Results of the study on changes in the ratio of Ans-Me\N-Me: The change in the proportion of the lower third of the face to the total length of the face reached 2% by a minimum value for raise the bone segment 0mm and highest value 4mm and this change was statically significant and stable during the study ($p < 0,1$).

The results of the study on changes in the proportion of N-Ans\N-Me: The rate of change in the length of the midface in the proportion to the total face length reach 2% and it is constant change during the study and statically significant ($p < 0,1$).

The results of the study on the soft tissue

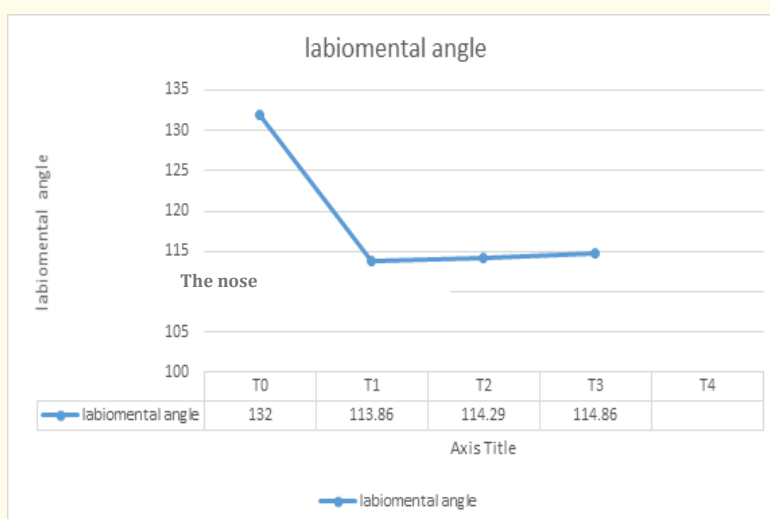
The nose: The assessment of the nasal prolapse with the detection of the patient complaint before the surgery, we compare if he have any nasal prominence and the satisfactory of the patient after surgery the result was 9% of the patient have clinically nasal prolapse but 63.36% have the complaint of nasal prolapse after surgery this compliant decreased 43%.



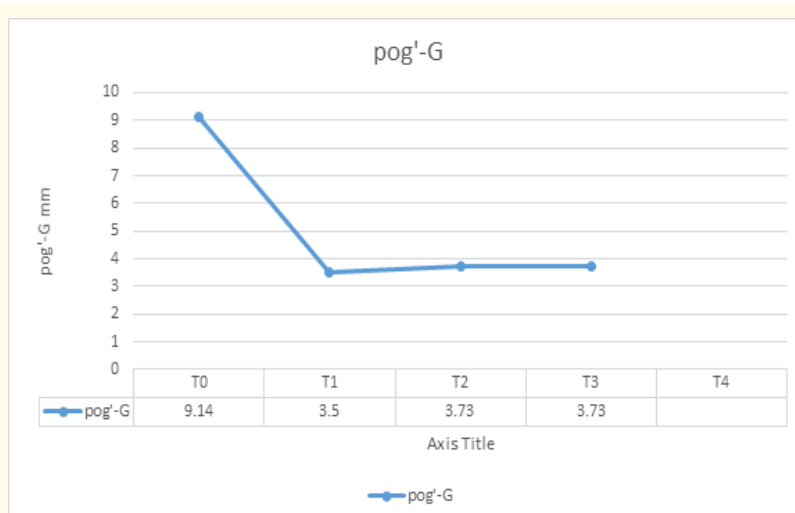
The upper lip: The study shows that the changes in the nasolabial angel and the distance between point Ls and zimmer line and the thickness of the upper lip depends on mairfield were not noticeable and not significant clinically or statically.

Lower lip: The study shows that the changes in the distance between li point and zimmer line and the thickness of the lower lip were very slight and not significant, the change in the distance between Sts and Sti points this space disappeared in relaxation for three patient they have 1 - 3 mm space before surgery this number is not significant statically but have very important clinical significant.

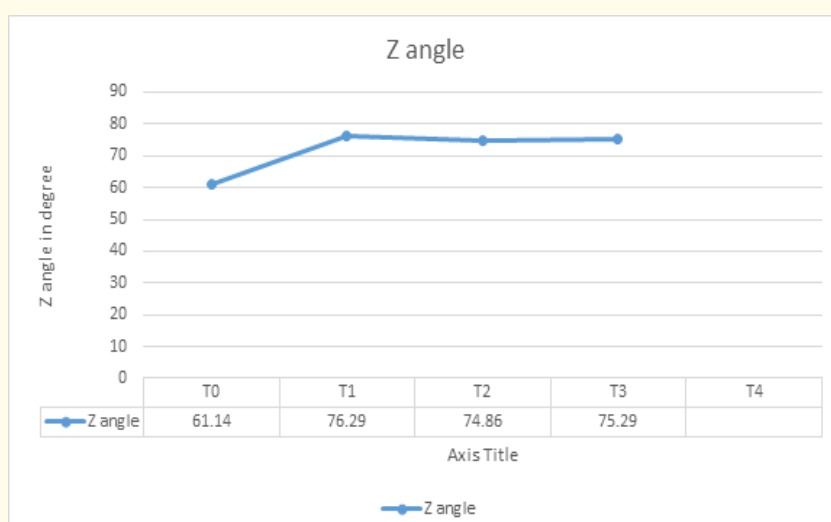
The labiomental sulcus: The study cleared that there is no difference in the position in point mlf after surgery but the labiomental corner changed 18 degree in average and that was statically and clinically significant and the reduction in this angle during 6 month almost 1 degree and that is not significant and the chart below cleared the changes in the labiomental corner (MLC).



The result of study for the chin soft tissue: The changes in the thickness of the chin (pog-pog') was not statically or clinically significant whereas the highest value 0,25m, also if we study the distance between pog' from G line the result showed it was 9.14 mm in average before surgery and decreased to 3.5 mm after one month surgery and increased 0.23 mm after 6 month and this reduction was not significant and the chart below cleared this results.



The result for the study of Z angel (Mairfield): This angle increased 15 degree in average after surgery and that was significant clinically and statically and the relapse after 6 month not more than 1 degree and this change not significant and the chart clear the changes in Z angle value during the study.



The result for study for the percentage Sn-Me`/N`-Me`: The study showed the change in this percentage almost 1% and not statically significant.

The result for study for the percentage Sts-Me`/Sn-Me` and this change near to be 2% and have statically and clinically significance ($p < 0.1$) improved harmony at the vertical level of the lower third of the face.

The result of the response in soft tissue to the advanced in hard tissue: The changes in the thickness of the covered soft tissue were almost non-existent in a ratio of 1:0.99 and the response for the soft tissue when we use Lag screw in fixation in a ratio of 1:0.94 during 6 month observation.

The results of study group B

The distance from Pog to McNamara: The result showed that the value of change near to 7 mm in average 4 mm the lower value and 9 mm the highest value and relapse after 6 month 0.75 and this is statically significant ($p < 0.5$) but not clinically significant.

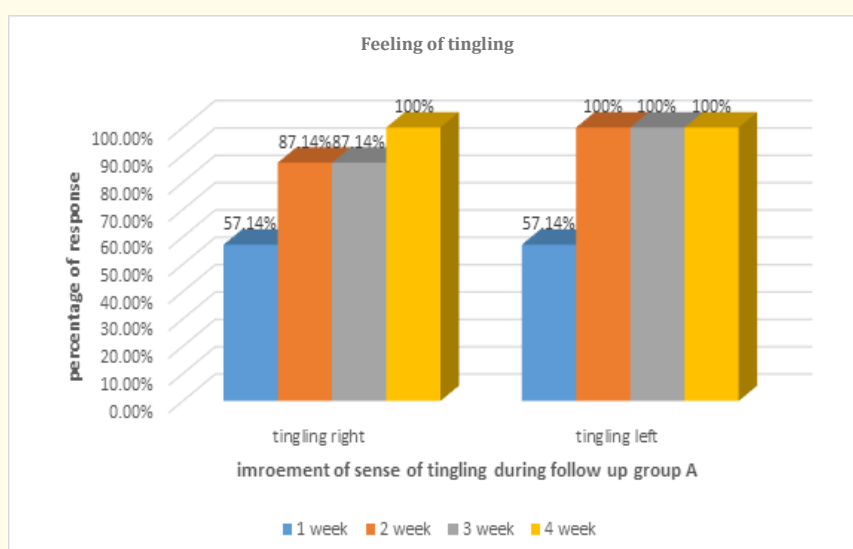
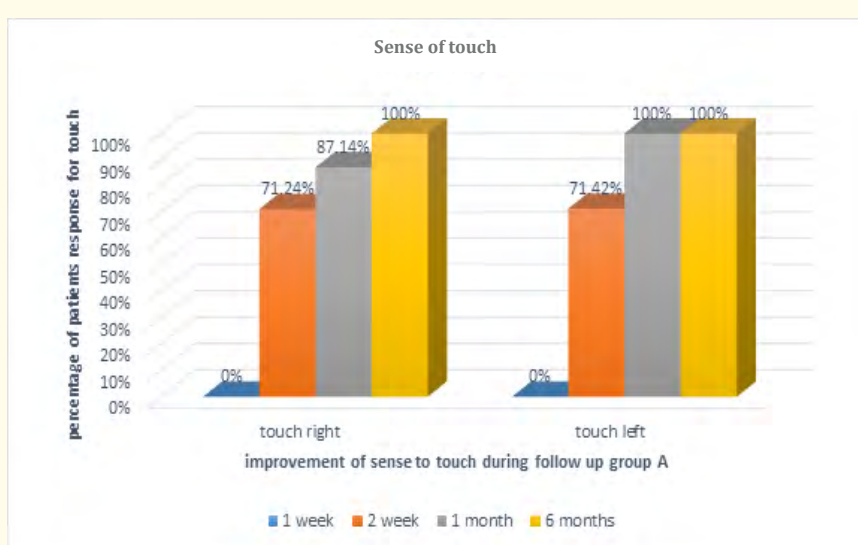
The change in distance between Pog` from G line: The value of this changes 6.6 mm in T2 and 6.125 mm at T4 and this is statically significant ($P < 0.5$) but clinically have no significance.

The response of soft tissue to the advancement of hard tissue: The ratio of response was 1:0.85 during 6 month.

The result of study the sensation changes for group A

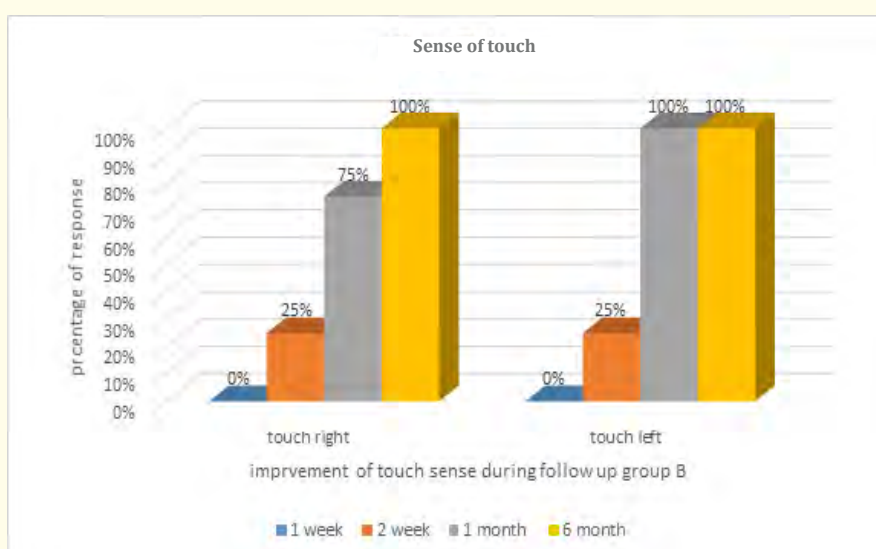
Sense of touch: In the first week the response not exist from the two sides in the second week the response 71.42% from the two sides after 1 month 87.14% for the right side and 100% left side after six months 100% for the two side.

Feeling of tingling: At the first week 57.14% from the two sides after two weeks 87.14% for the right side and 100% left side, after 1 month the same result, after 6 months 100% from the two sides, the age or sex of patient or the advancement amount have no relationship with the result or any statically significance.



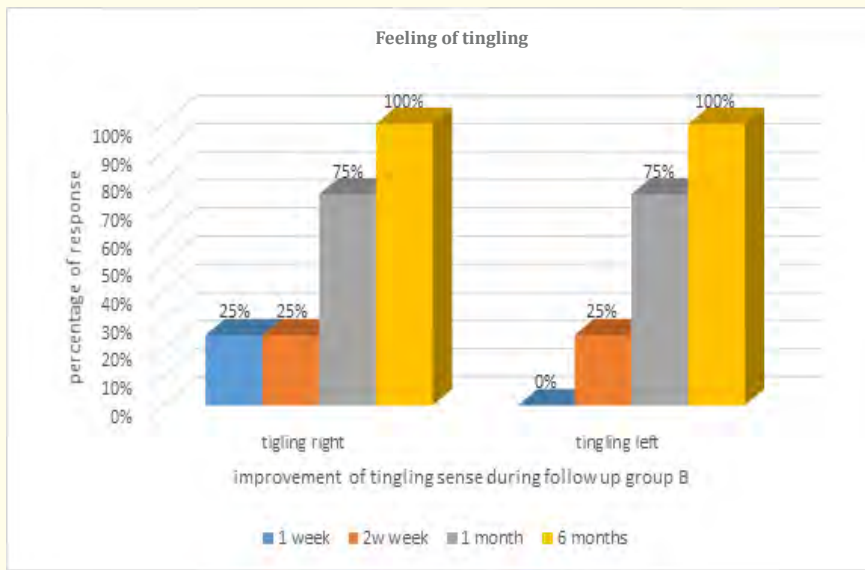
The result of study for the sensations for group B

Sense of touch: In the first week the response not exist or confused from the two sides in the second week the response 25% from the two sides after 1 month 75.5% for the right side and 100% left side after six months 100% for the two side.



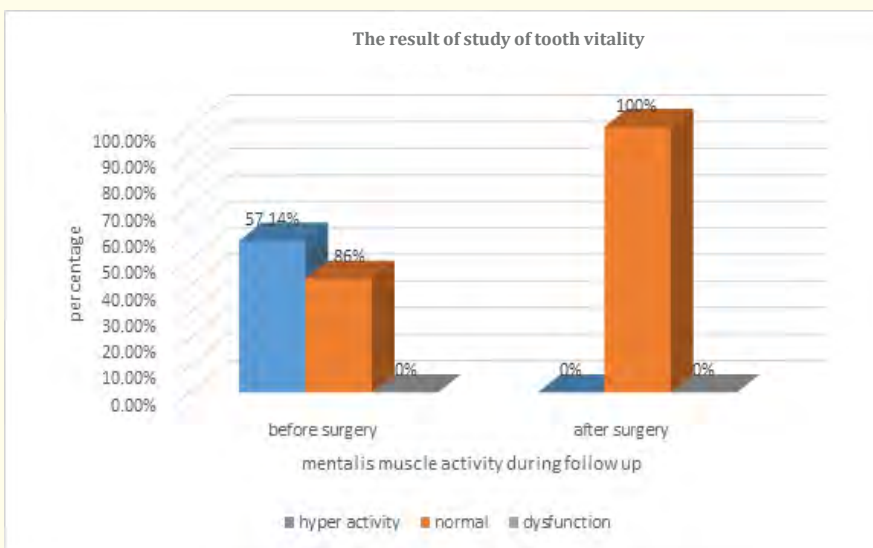
Feeling of tingling: At the first week 25%% from the right and 0% from the left, after two weeks 25% for the two sides, after 1 month 75% from the two sides, after 6 months 100% from the two sides.

The result of study of tooth vitality: There is no dental injuries during 6 weeks later study.

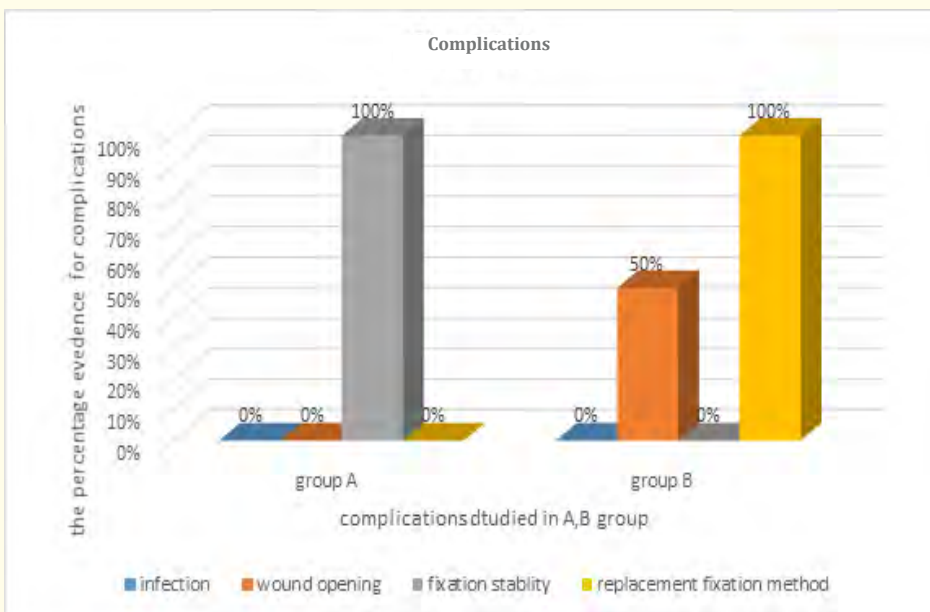


Complications

- Mentalis muscle function: 57.14% of the patients have hyperactivity in mentalis muscle reduced to 0% after surgery.

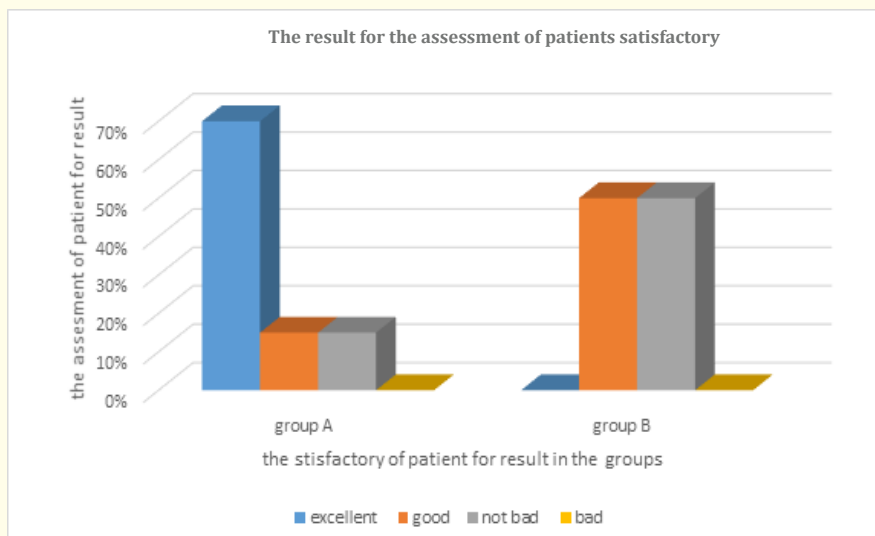


- Infection: There is no infection at all.
- Wound opening: Found in 50% of group B.
- The stability of the bony segment: The bony segment stability did not materialize in group B which fixed by using X plate and 4 screws.



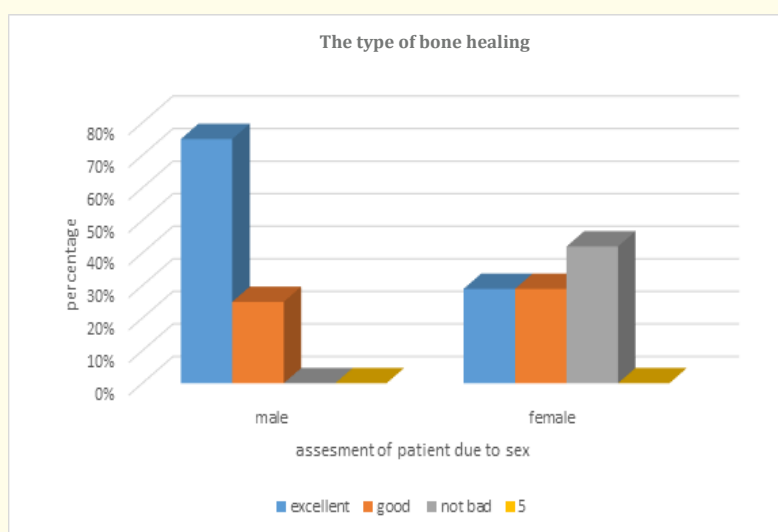
The result for the assessment of patients satisfactory

There is statically difference between the two groups, there is relationship between the sex of patient and the assessment from the patient to the result of surgery and the chart below cleared that.



The type of bone healing

The study showed that the bone healing for group A was direct bone healing type and the bone tissue density have no effect at the bone resorption after surgery during the study.



Discussion

The number of the patients of the sample is 12, advanced osseous genioplasty was done for 7 patients and fixation by using 2.5 x 19 mm resorbable lag screws (group A), and 4 patient the osteotomy and fixation done by using resorbable X plate at the midline with 2 x 11 mm resorbable screws (group B), the plate replaced during 48 hours post surgery by X titanium plate with 4 screws due to lack in activity of fixation for the resorbable plates (Search image extension 22-26).

For the last patient we make osseous genioplasty to correct asymmetry without advancement and we use the same resorbable plate and screws 2 x 11 mm for fixation just to detect the reason for the deficiency of activity in the previous cases (Search image extension 27).

All the surgical procedures were done under general anesthesia with nasal intubation and this is a routine procedure but some articles confirmed the possibility to use intravenous sedation with local anesthesia to reduce the financial cost [59].

The procedures took 90 minutes in average, intraoral incision 5 mm below the mucogingival connection between the lower canines, the osteotomy done 5 - 6 mm below the mental foramen and 8 mm below the apex of lower canine in minimum, then the fixation and double layer suturing and this is consistent with the recommendations of Brett and Leach [8].

Skeletal changes discussion

For group A

The skeletal parameters have been studied by cephalometric x ray for group A are the change in position of Pog and the change in angle N-A-Pog to detect the sagittal skeletal changes in the chin, and the changes in percentages Ans-Me/N-Me, N-Ans/N-Me to detect the vertical skeletal changes for the lower and mid third of the face, and this parameters were studied as the most important ones which detect the skeletal changes for the chin in many studies which aim to make overall skeletal evaluation for face Shaughnessy, *et al.* [52], Talebzadeh and Porgel, *et al.* [66].

Most of the studies confirmed that the most important change was the position of point Pog which really changes the associated skeletal parameters and angles Shaughnessy, *et al.* [52].

The average for surgical advanced in our study reach 5.78 ± 0.9 mm and the average of relapse after 6 months was 0.33 ± 0.23 mm the percentage $4.1 \pm 3.9\%$ in a ratio of 1:0.959 mm.

Proffit, *et al.* [144] cleared that relapse more than 2 mm skeletally in minimum will be greatly significant clinically so the relapse in our study was significant statically but no clinical significant found and that agree with Proffit, *et al.*

In the study of Shaughnessy, *et al.* the skeletal relapse 8.2% in average of 1.4 mm after 3 years and he assured that this is statically significant but not significant clinically [52] and that was agree with Proffit, *et al.* [144] and with the studies of Mc Donnell, *et al.* [120], Park, *et al.* [118], Wittbjerand Runne [124], Polido, *et al.* [123], Van sickles, *et al.* [125], Reyneke, *et al.* [122], Talebzadeh and Porgel [66] and all this study confirmed that the stability for the bone segment was very good in advanced surgery.

We can say that it is difficult to detect the relapse reason if it is the week stability of the bony segment or the changes caused by bone regeneration in the area, but it is clear that bone regeneration have main role in the existing relapse for Pog position in our study, bone regeneration happened by the periosteum response (activity) to the external forces applied from the tissue and surrounded muscles to perform re-sharpening of the sharp border and angles to make smooth anterior edges Edward, *et al.* [30].

It can be said that the conservative dissection during surgery and the non-dissection of the free bony segment from the lingual side of the connective tissue has had significant effect to decide that the bone absorption in the sample patients is mainly due to the osseous repositioning because of the small amount of relapse for Pog and that what assured by Vedtofte, *et al.*, he make complete dissection for the segment from the connective tissue for 15 patient and conservative dissection for 14 patient after the study there is significant difference in relapse in the first group [145], Ellis, *et al.* assure in their study that the connection between the bony segment ant the lingual tissue is very important to avoid the absorption for the segment after surgery [5].

The mentioned previous studies which give results near to our results and the rates of recurrence within the permissible limits and confirmed that the relapse mainly due to the osseous reconstructive and repositioning Shaugehnessy, *et al.* [52], Talebzadeh and Pogrel [66], Proffit, *et al.* [144], and due to the simple relapse value in our study we assured for the high fixation strength and stability to use

The mentioned previous studies which give results near to our results and the rates of recurrence within the permissible limits and confirmed that the relapse mainly due to the osseous reconstructive and repositioning Shaugehnessy, *et al.* [52], Talebzadeh and Pogrel [66], Proffit, *et al.* [144], and due to the simple relapse value in our study we assured for the high fixation strength and stability to use

The most surfaces we note that have bone reformation in our study was the upper anterior surface of the free chin segment and the lingual edge of mandible which have bone resorption, while the bone reposition area was the labial surface near to the osteotomy edge and that was very clear in cephalometric X-Ray for 6 month fellowship and that agree with Shaughnessy, *et al.* [52], Talebzadeh and Pogrel [66], Shaughnessy, *et al.* assured that the repositioning of the bone at the point B (lowest point at the labial surface of mandible) has statically significant and that is the most important manifestation of reforming the bone and assured that the points AGP (the apex of the upper anterior edge of the bony segment), B, Pog are the most bone reformation areas and that agree with our results.

And also agree with the study of Ayoub, *et al.* who use the finite element analysis by computer to confirm that Pog and the upper anterior edge of the bony segment have bone resorption and the labial surface at point B of mandible has bone repositioning [127].

Shaughnessy, *et al.* in their study for 21 patient have advanced osseous genioplasty and follow up for 3 years that the most skeletal and soft tissue changes and osseous repositioning occurred during the first 6 month after surgery and the changes after that have no clinically and statically significant [52], and that agree with the study of Talebzadeh and porgel [66], there for we consider that 6 months follow up is enough to study the changes after advanced osseous genioplasty.

In the study of Ryneke, *et al.* assured that 6 months follow up is enough and it is a minimum time to study this cases [122], and Troulis, *et al.* [146] they study the results and complications after genioplasty for 15 patient during 6 months and this period considered as enough and the results and the size of sample near to our study.

Discussion the skeletal fixation and fixation method

From the results we assured that the use of 2 resorbable lag screws in fixation after advanced osseous genioplasty is enough and ideal, whereas the relapse average was in minimum.

Richard, *et al.* in a laboratory study assured that 3 lag screws for fixation was enough to accommodate as much vertical power as possible and the increase in screw's numbers is not recommended [156] so to but 2 screws in the chin area which have no strong efforts or power consider it enough.

Jones and Vesely [23] used s titanium screws after advanced genioplasty and assured that the result was very good.

Edward, *et al.* used tow resorbable lag screws 2.5× 18-15 mm in fixation after osseous genioplasty and assured that the results were perfect [30], and that agree with our study we use tow resorbable lag screws 2.5 x 19 mm and the table below showed many studies which were compared with our study and the differences were in the fixation technique, the size of the sample, follow up time, in addition to the advancement amount and relapse at point Pog.

Study	Sample Size	Fixation Technique	Follow Up	Advancement Amount	Relapse
Bell and Dann 1973 [119]	11	Wires	18 months	6.6 mm	Less than 40%
Wittbjer and Runne 1989 [124]	17	Wires	3 years	8.3 mm	2 mm
Park, <i>et al.</i> 1989 [118]	23	Plate	6 months	6.6 mm	0.39 mm
Polido, <i>et al.</i> 1991[123]	10	Wires/plate	6 months	11.7 mm	2.9 mm
DeFreitas, <i>et al.</i> 1992 [148]	39	Plate	6 months	5.7 mm	0.04 mm
VanSickels, <i>et al.</i> 1994 [125]	18	Plate	6 months	7.4 mm	0.92 mm
Reyneke, <i>et al.</i> 1997 [122]	40	Wire 20 Lag screw 20	6 - 10 months	5.8 mm 6.3 mm	0.5 mm 0.3 mm
Talebzadeh and Pogrel 2001 [66]	20	Plate	1 year	11.9 mm	0.38 mm
Shaughnessy, <i>et al.</i> 2006 [52]	21	Plate10 Wires 11	3 years	7.1 mm 9.7 mm	0.3 ± 1.3 mm 1.1 ± 1.3 mm
Our study	12	Resorbable lag screws	6 months	5.8 mm	0.3 mm

From the previous studies we note that the use of wire in fixation will have more relapse in point pog and that is explained by lower stability but Shaughnessy, *et al.* attributed the increase in relapse when he used the wires in fixation to increase the amount of advancement [52], Reyneke, *et al.* assured that the use of wires increase the relapse [122].

The use of plate and screws give us good results and high stability and that was clear in the studies, and the use of lag screws give the best results and that what Reyneke, *et al.* assured they have only 0.3 mm relapse in average [122] ad that agree with the results we have the relapse was 0.33 mm in average.

All the previous results showed that there is statically significant between the use of wires or the use of other fixation technique but most of studies said there is no important difference clinically and the relapse was not more than 2 mm at point pog Reyneke, *et al* [122].

The use of plate and screws or the use of lag screws give us almost the same results but it's worth mentioning that the osseous repositioning that happen after surgery means to cover a part of the fixed plate at the labial surface of mandible by the new formation bone and

The use of plate and screws or the use of lag screws give us almost the same results but it's worth mentioning that the osseous repositioning that happen after surgery means to cover a part of the fixed plate at the labial surface of mandible by the new formation bone and the absorption at point Pog and the upper anterior edge of the segment makes the plate to be palpable after six months and the removal Edward, *et al.* [30] assured that the cost of 2 or 3 absorbable screws is less than metal plate and 4 screws and we agree in our study.

There is no radiological confused when we use resorbable material on the contrary when we use metal fixation technique and that have great effect when we need to make diagnosis for some issues in the area at the long term.

Vansickles raised in his article many logical questions about absorbable materials and he consider that to use resorbable plate and 4 screws at the midline is more easy to use lag screws for fixation [30], but on the other hand we disagree with his study and confirm that the use of tow lag screws to fix the segment is more easier and faster to perform the surgery and give us higher stability and perfect results in long-term.

So our study assured that the benefits to use resorbable lag screws in fixation after advanced genioplasty:

- We consider it ideal for the stability of the bony segment
- Give us the less relapse value comparable to the other fixation technique for point Pog
- Easy technique to apply and more faster to perform the surgery
- Avoid the patient secondary surgery to remove the fixation materials
- Do not interfere with radiography and less in cost.

The discussion for the skeletal changes for the group B

The group B consist of 4 patient whose undergone osseous genioplasty and the fixation by using resorbable X plate at the midline with 4 screws the size is 2×11 mm (this plate equal to titanium plate 1.7 mm) and his is most likely to many studies used 4 screws with plate, Vansickels cleared that metal plate with 4 screws at the midline is the most common and easy to fix the chin osteotomy [30], Edward, *et al.* use plate and 4 screws (absorbable) to fix the segment and confirmed that it is useable [30], but in our study this plate and screws were replaced during 48 hours after surgery by a titanium one due to the weakness in fixation and that was clear in the x ray after surgery.

The advancement was 7 mm in average and the relapse at pog was 0.75 ± 0.18 mm in a percentage of 11.48% in a ratio of 1:0.88 and we justify the increase in skeletal relapse to the re surgical opening at the area so increase in the inflammatory and surgical trauma and increase the time for healing and that is natural and noted so to compare our results with the other study we see clearly the increase in skeletal relapse and we mention from this studies Park, *et al.* he showed that the relapse was 0.39 mm [118], Talebzadeh and Pogrel the relapse about 0.38 mm for 11.9 advanced in average [66], Shaughnessy, *et al.* was 0.3 in average [52].

We note that the increase in relapse in compare with the other studies refer to the surgical reopening, but this relapse still within the permissible limits and not clinically significant.

The bone reformation places were the same in group A and the other studies but we not the increase in prominence of the plate at Pog after 6 months and that agree with Shaughnessy, *et al* [52].

Edward, *et al.* [30] assured that the use of resorbable plate with 4 screws is available and that was not available in our sample so we stop to perform the sample and we replace one of the patient with another one indicated for asymmetry correction for the chin and fixation by using resorbable plate and screws just to discover the reasons for failure in use with advancement cases.

In fact we note that the use of this technique in Edward, *et al.* study happen only in simple advance cases and the study did not project any photo for this cases, but all the cases which mentioned in the photo as advancement and fixation by resorbable plates were accom-

panying to use independently lag screws at the sides of the plate so it depends in its stability on this lag screws, he said that only slightly adaptation is recommended to use it, and he ask for more time to follow up and assured that the stability was less than the metal one [30].

So we agree with Sickles he assured that it is very hard to adapt this plate to shape S and he refer to use metal plate and nothing support the use of resorbable plate and 4 screws after being heavily adapted or modified and confirmed that this technique need lot of improvement to use [30].

When we apply this plate for asymmetry correction case for the chin after osteotomy the stability was good and we never note any complications during the follow up where the adaptation of the plate was in minimum so we suggest that the adaptation or excessive formal adjustment is the main reason in the failure of use this plate and we think that the form and regularity of the crystals or fibers of the chemical composition of absorbable materials has been damaged during over-modification, in addition to the muscular tension applied on the free bony segment as an adjunct agent and that agree with Sickles [30], and disagree with Edward., *et al.* [30].

Discussion the changes of soft tissue

Nose: When we evaluate the nasal prolapse and the complain of patient about it before surgery only about 10% have a reason to perform rhinoplasty while 65% of patients complained of nasal prolapse and 57% of patients who had this complaint had disappeared after surgery at the chin, so our study confirmed at the big role that the advanced genioplasty made to achieve the facial harmony and that agree with the study of Romain., *et al.* [149] who assured that good evaluation for the chin position should be done before rhinoplasty, and that agree also with what Willett refer to in his book Facial Plastic Surgery that 10 to 50% of rhinoplasty cases have indication for advanced genioplasty [1].

In the study of Jones and Vesely [23] 28 of 62 patient have been made for them rhinoplasty in addition to advanced genioplasty that near to 50% and the increase in this percentage we think is due to the fact that the researcher did not mention the reason for which these patients underwent surgery on the nose, but it is certain that nasal prolapse is one of the most important reasons for the procedure of the nose and requires a full facial evaluation and that is what our study has touched upon.

The position of the upper lip: the parameter have been studied to assess the position of the upper lip did not show any significant differences after surgery and during the follow up and that agree with Shaughnessy., *et al.* [52] and Brett and Leach [8].

The position of the lower lip: the parameter have been studied to assess the position of the upper lip did not show any significant differences after surgery and during the follow up, but the change in the space Sts-Sti was clinically significant, as the number of sample increases, it can be said to be a significant difference and that agree with the study of Shaughnessy., *et al.* [52] and Brett and Leach [8].

We note that Veltkamp., *et al.* [51] assured that the thickness of the lower lip has changed in a ratio of 1:0.79, the studies of Sassouni and Busquets [150] and Ross and Ewing [151] all of this studies showed changes even if it simple in the thickness of the lower lip but it is very hard to compare this results with ours because there are lot of studied variables in a different way to our study in addition to important factor that additional orthognathic surgery procedures made over the maxilla and mandible.

Discussion the position of the labiamental sulcus

The position of the point MLf there was good stability in the position of this point and that agree with the most studies which confirmed that the change in the position of this point was not noted, Shaughnessy., *et al.* [52] cleared that the change in the depth of the labio mental fold near to 1.8 mm and this is near to our study so we cleared that by the decrease in the labio mental angle in a ratio of 17 degree so we should just be careful that the increase in the depth of the sulcus happened by the advance of the point Pog and not the movement of MLf.

Discussion the changes overall the chin

The changes in the position of the soft tissue and the effect on the profile can be noted clearly after the surgery, and the improvement in the facial harmony was clear through the improvement in the labiomental angle, the study of the parameters cleared that the changes in the space Pog-Pog` was not significant and almost near to be stable and that agree with Shaughnessy, *et al.* [52] and Gallagher, *et al.* [116] and that result is explained by the conservative dissection specially from the lingual side and that what Gallagher, *et al.* confirmed.

In our study the ratio of soft tissue response to skeletal advanced (group A) was 1:0.94 and it is ideal percentage, while in group B 1:0.88 and it still within acceptable limits although this value is bigger than in group A and there are many reasons for that we already explain.

Many studies which evaluate the soft tissue response for advanced osseous genioplasty assured that the ratio of response was from 1:0.6 to 1:1 and that found in all searches from 1992 Ewing and Ross [151] the response percentage near to 90% also Shaughnessy, *et al.* [52] the response ratio 1:0.9 and this is near to our results.

Bell, *et al.* assured that as much as the connection between the bone segment and the tissue increase as the tissue response increased [40], Gallagher, *et al.* [116] they just made dissection allowed for them for vision only and perform the osteotomy (minimum dissection) and have more than 1:0.9 response ratio.

Polido, *et al.* [123] confirmed that the shrinkage of the scar during the healing process causes a decrease in the thickness of the soft tissue compared to pre-surgery, Shaughnessy, *et al.* [52] confirmed that the good connection from the lingual and labial sides to the soft tissues with the free bony segment gives a good soft tissue response and reduce the thickness of soft tissue and thus provide predictable results and these opinions are consistent with our findings in our study.

In fact, there are many studies that evaluated the soft tissue response relative to the skeletal chin advanced but from the results that can be observed:

Dann and bell [119], McDonnel [120] received a response rate of 60% and 75%, respectively, which is low compared with the findings of other studies, including our study and explanation of the reason is due to the use of other surgical techniques accompanied on one of the jaws in addition to the use of wires in fixation.

The same was true for Talebzadeh and Pogrel [66] the percentage where 75%, that was due to the excessive advancement amount and the involvement of another surgery on one jaw at least, although platelets were used for stabilization.

Wittbjer and Rune [124] have 1:0.94 ratio, also Kerkmanov and Kahanberg [121] have a 90% - 100% noting the difference in fused fixation technique.

Polido, *et al.* [123] have a ratio 1:0.98, Edward, *et al.* when they use resorbable material in fixation the results were acceptable and they did not have any differences with the other studies which use other fixation materials [30].

In fact, it is possible to say that the advanced genioplasty results have an excellent response for the soft tissue to the skeletal advanced at the chin level, and in our study, the factors that give a good response to the soft tissue to the skeletal advance are to make the dissection as minimal as we can, and the good skeletal stability of the bone, which reduces bone absorption and accelerate healing in the region and this is consistent with most previous studies.

Discussion the changes in the parameters values during the follow up

The results of the study showed that the skeletal changes were significant during the first month of follow up, (T1-T2), and thus we obtained relative stability in the results until the end of the observation period.

And the changes in the studied parameters for the soft tissue were significant during the phase T0-T2, To-T4 and therefore the largest change was during the first period after surgery and thus this is a stable result in the long term and that the change in it is only foreseeable in the near term, and most of these changes occur within the first three months. This is consistent with the study of Brett and Leach [8] who provided a comprehensive review of most of the studies and gave comprehensive recommendations on osseous genioplasty, and Shaughnessy, *et al.* [52] have Sample control for 3 years, Wittbjer and Rune [124] also the sample monitoring for 3 years, Reyneke, *et al.* [122] continued their studies until one year and all these studies considered that the changes occurred significantly during the first six months and this is consistent with Our study.

Chin sensitivity discussion

As noted in the results of our previous study no disturbances observed after 6 months, or even decrease, deformation or weakness in the ability to determine the nature of the sensors in the lower lip area of the two parties in all sample individuals.

The sense of touch was the most affected in the first week after surgery. In the second week 30% of members of group A and 75% of group B have confused sense response, after one month only one patient from each group have sense confusion for touch sense at one side of the lip after six month the response was very natural for all the patient.

As for the feeling of prickling, 45% of the respondents had an inability to determine the nature of the feeling, which was completely reduced when the examination was performed after one to six months.

We explain the absence of permanent damage after the end of the observation period in our study that the line of the osteotomy away below from the mental foramen more than 5 mm at least, and there was no direct injury during the operation of any patient where the protection and isolation of mental nerve priority in all stages of Surgical treatment.

We explain the delay in the return of the ability to determine the nature of the sensors in the sample until the second week or the first month to the surgical trauma and the accompanying edema. This was evident in the group B, especially for the sense of touch due to the increase in the surgical trauma and the delay of the healing process, our study agree with recommendations of Brett and leach [8] who assured the necessity of to be the osteotomy line 5 - 6 mm below the mental foramen as a minimum, Lopes, *et al.* [152] when he made osteotomy for 10 patient they have lake in sense response during 3-10 days next to the surgery and this issue did not exist after 6monthes and that agree with our study to a large extent.

Westermarck, *et al.* [153] concluded that 12% of the 78 patients who underwent osteotomy on the chin continued to have some difficulty in determining the nature of the sensations on the lower lip and we believed it to be high compared with the results of other studies.

Nishioka, *et al.* [154], one out of 30 patients continued to have a complaint with one end of the lower lip to determine the feeling of touch, and the reaction to the tingling was completely normal, and it was reported that this injury did not affect quality of life of this patient, this is a perfectly reasonable result.

Ousterhout [36] confirmed that in order to avoid sensory injury, the osteotomy line should be a maximum of 5.5 mm below the mental foramen, and 3 of 50 patients underwent genioplasty have injuries indicating that the line of osteotomy was closer to the permissible distance Out.

Rietter, *et al.* [35] using high-resolution radiographic images to determine the pathway of the mandibular canal, they stressed the need to move up to 6 mm below the mental foramen to avoid injury. This is what happened in 52 patients.

Gianni, *et al.* [140] presented a detailed study of the inferior alveolar nerve injury and examined the different sensations on the chin and lower lip area. 10 patients only of the sample were performing osteotomy genioplasty and no sensory disturbances were observed

after six months and that agree with our study, The second group, which was applied ramus osteotomy, and other group was involved between the vertical ramus osteotomy with genioplasty, and their study showed that the third group had a greater sense disturbances and the difference was essential at the lower lip area, and thermal sensations were not affected but mechanical sensors were Most affected.

Discussion of dental vitality

In our study, the response of the lower frontal teeth from the canine to the canine was clear. We did not see differences between the first 72 hours and the six weeks later. The response in all patients was normal and that due to the osteotomy line below the apex of the lower canines 5 - 8 mm and that agree with the most studies which confirmed that 5 - 8 mm below the apex of frontal lower teeth is enough to perform the osteotomy and fixation without and nerve or blood supply damage to this teeth. Brett and Leach [4] and Storum., *et al* [34].

Discussion of the complications after surgery

Discussion of the mentalis function

In our study, about 57% of the subjects were suffering from hyperactivity of the mentalis muscle, the appearance of orange peel on the surface of the chin was evident when the mouth was closed voluntarily by patients, the absence of hyperactivity was evident after surgery and advancement of chin, and we consider this one of the most important clinical difference after surgery, and agree with Bedhet., *et al* [155].

We did not have any case of mentalis muscle dysfunction or chin ptosis, This is explained by the surgical stitching after surgery, which was done on two layers, the internal layer to the mentalis muscle fibers and external to the mucosa.

This is consistent with Chaushu., *et al.* [70] who compared 10 patients who had stitching to the mentalis muscle fibers and 11 patients who had not been stitched and found that the length of the lip increased in the first case while the second case decreased, and the exposure of the lower incisors In the second group was clear, while there is lack of exposure to teeth in the first group, and described what happened in the members of the second group Chin ptosis and confirmed that the sewing of the fibers of the mentalis muscle prevents the chin ptosis.

Richard., *et al.* [156] studied a sample of 200 patients who had genioplasty and recorded the complications. Chin ptosis was an incoming but rare, complication caused by non-stitching of the mentalis muscle fibers and provided a way to treat this mingling.

Discussion of infection

There was no infection an any case we explained that by the average age of the patient 21 years (young) they are healthy without any injuries or periodontal disease, we already made scaling and increase the oral hygiene of the patients using antiseptic mouth wash 1 week before surgery, and with good coverage of antibiotic after surgery and to comply with conditions of sterilization during surgery, according to the manufacturer the plate and screws undergone to a strict cycle of sterilization so the increase of infection, as these products are not re-sterilized or used, in addition the conservative dissection and not to separate the lingual tissue attachments with the bony segment and that agree with Vedtofte., *et al.* [145] they confirmed that the sample of study who have lingual tissue dissection the chance of infection was bigger than the other group who conservatively done.

Discussion of wound opening

The opening of the wound was not noticed in group A, whereas the opening of the wound in group B was explained by the surgical reopening of the wound again and the suturing difficulties at the second time, this complain is rare and the chance to have is not more than 3 - 5% of the evidence with augmented genioplasty and that agree with Guyuron., *et al.* [157] and Richard., *et al.* [156] and both provided a range of possible complications and method of treatment.

Discussion of the stability of the bone

This idea was discussed in advance. It should be noted that the cases in which the adsorbent plates were stabilized were 100% non-existent. VanSickels [30] said that the use of these materials needed much more study and development and that they were still controversial and disagree to what Edward., *et al.* [30] where they said that the use of these plates is possible and the shortcomings of the study was mentioned in advance, and we assured that the excessive conditioning is the main reason for the loss of these plates of their properties and ability for fixation.

Discussion of patient satisfaction and evaluation of the outcome of surgery

There was no patient who gave a negative evaluation of the surgical work and 45% of the patients described it as excellent and we consider the use of absorbable fixation materials is an encouraging factor and increases the patient's satisfaction and acceptance of the surgical operation compared with the mineral materials, which many studies have agreed that the presence of foreign body generates a case of Long-term dissatisfaction with the patient and the desire to remove them.

Discuss the bone-healing type

The type of bone healing according to the radiological evaluation in our study on group A is a direct bone healing type, including the possibility of healing by the contact or gaps. This is explained by the osteotomy using the electric vibration saw and as far as possible with one movement and a steady hand without abnormal movement during cutting, that agree with Brett and Leach [8] recommendations, in addition to the tight, close and compressive fixation using the lag screws. This corresponds to Steinmann [135] and Aboagweh [139].

Conclusion

If the osseous advanced genioplasty is indicated it gives a wonderful result and satisfactory for the patient and maxillofacial surgeon on the whole, and through our study we conclude:

1. The use of 2 resorbable lag screws in fixation after advanced osseous genioplasty consider as ideal in terms of hard tissue changes and the soft tissue response.
2. The use of resorbable X plate at the midline and 4 screws for fixation are not recommended for advanced osseous genioplasty.
3. To make the osteotomy line 5 - 6 mm below the mental foramen is sufficient for the absence of damage to the mental nerve and thus maintain the safety of sensation for the lower lip.
4. A 7 - 8 mm distance between the osteotomy line and the canines apex is enough to keep the vitality of the teeth after genioplasty
5. The associated complications like infection, mentalis muscle dysfunction, the wound opening are rare or even non-existent when complying with the working conditions and use of these materials in the fixation.
6. Patients' satisfaction with the results of the surgical operation was felt after one month of surgery.
7. The use of three-core screws in the fixation determines the mechanism of bone healing on both sides of the osteotomy line with direct healing type, including the possibility of healing by contact or bone gaps.

Recommendations and Suggestions

We recommend:

1. To use tow resorbable lag screws 2.5×19 mm on the both side of the midline to fix the free bony segment of the chin to ensure an ideal outcome in terms of the stability of changes in the skeletal tissue and soft tissue response, avoiding the associated complications, and subsequent surgical procedure to remove the traditional fixation device and achieve optimal bone healing.

2. Do not use absorbable plates in fixation when conducting osteotomy necessitate the need to adapt these plates.
3. A real assessment for the chin position should be done before rhinoplasty is done especially in cases of nasal overjet, maybe the advanced genioplasty is indicated instead of rhinoplasty or shared with rhinoplasty
4. We recommend to use tow wires for holding the free bony segment temporarily to facilitate control during transfer to the desired location.

And we suggest:

1. Further laboratory and clinical research to develop the absorbable materials in aim to have a technique enable us to use it in all the osteotomies in the face.
2. Conducting research involving a larger sample presenting a final result using radiographic imaging approximates the amount of proposed advancement amount for the chin in the treatment plan with what is determined by the surgical possibility in the operating room.

Bibliography

1. Willet JM., *et al.* "Facial Plastic Surgery". 6th edition (2007): 107-117.
2. Lindquist C and Obeid G. "Complications of genioplasty done alone or in combination with sagittal split-ramus osteotomy". *Oral Surgery, Oral Medicine, Oral Pathology, and Oral Radiology* 66.1 (1988): 13-16.
3. Heiple K., *et al.* "A comparative study of the healing process following different types of bone transplantation". *Journal of Bone and Joint Surgery* 45 (1963): 1593-1616.
4. Thompson N and Casson J. "Experimental onlay bone grafts to the jaws. A preliminary study in dogs". *Plastic and Reconstructive Surgery* 46 (1970): 341-349.
5. Ellis E., *et al.* "Advancement genioplasty with and without soft tissue pedicle: An experimental investigation". *Journal of Oral and Maxillofacial Surgery* 42.10 (1984): 637-645.
6. Sullivan SM., *et al.* "FONESCA Oral and Maxillofacial Surgery". Orthognathic Surgery. 7th edition (2000): 403-415, 477-505.
7. Rijinko B. "Facial harmony, standards for orthognathic surgery and orthodontics" Quintessence publishing Co., LTD, London, U.K (1988): 1-49, 93-95, 145-147.
8. Brett AM and Leach JL. "Osseous genioplasty: Technical considerations". *Operative Techniques in Otolaryngology Head and Neck Surgery* 18 (2007): 181-188.
9. Converse J. "Micrognathia". *British Journal of Plastic Surgery* 16 (1963): 197-210.
10. Trauner R and Obwegeser H. "Surgical correction of mandibular prognathism and retrognathia with considration of genioplasty". *Oral Surgery* 10.7 (1957): 677-689.
11. Pitanguy I., *et al.* "Mentoplasty: A critical analysis". *Aesthetic Plastic Surgery* 10 (1986): 161-169.
12. Simons RL. "Adjunctive measures in rhinoplasty". *Otolaryngologic Clinics of North America* 8 (1975): 717-742.
13. Safian J. "Progress in nasal and chin augmentation". *Plastic and Reconstructive Surgery* 37 (1966): 466.
14. Pierce GW and O'Connor GB. "Refrigerated cartilage 150 graft". *Surgery, Gynecology and Obstetrics* 67 (1938): 796.

15. Beekhuis J. "How I do it" -augmentation mentoplasty with polyamide mesh". *Laryngoscope* 86 (1976): 1602.
16. McCollough EG and weil C. "Augmentation of facial defects using Mersilene mesh implants". *Archives of Otolaryngology-Head nd Neck Surgery* 87 (1979): 515-521.
17. Johanson CM and Toriumi DM. "Open Structure Rhinoplasty". Philadelphia WB Saunders (1990): 218.
18. Johanson CM and Toriumi DM. "Open Structure Rhinoplasty". Philadelphia WB Saunders (1990) 219-237.
19. Rosen HM and Ackerman JL. "Porous block hydroxyapatite in orthognathic surgery". *Angle Orthodontist* 61.3 (1991): 185-192.
20. Vuyk HD and Lohuis PJ. "Facial Plastic and Reconstructive Surgery". Hodder Arnold, Oxford University Press Inc, New York (2006): 29-36, 329-337.
21. Strauss RA and Abubaker AO. "Genioplasty: A case for advancement osteotomy". *Journal of Oral and Maxillofacial Surgery* 58.7 (2000): 783-787.
22. Chang EW, *et al.* "Sliding genioplasty for correction of chin abnormalities". *Archives of Facial Plastic Surgery* 3.1 (2001): 8-15.
23. Jones BM and Vesely MJ. "Osseous genioplasty in facial aesthetic surgery-a personal perspective reviewing 54 patients". *Journal of Plastic, Reconstructive and Aesthetic Surgery* 59 (2006): 1177-1187.
24. Danahey DG, *et al.* "Importance of chin evaluation and treatment to optimizing neck rejuvenation surgery". *Facial Plastic Surgery* 17 (2001): 91-97.
25. Hofer O. "Operation der Prognathic and Mikrogenie". *Deutsche Gesellschaft für Zahn-, Mund- und Kieferheilkunde* 9 (1942): 121-132.
26. Converse JM. "Restoration of facial contour by bone grafts introduced through the oral cavity". *Plastic and Reconstructive Surgery* 6.4 (1950): 295-300.
27. Converse JM and Wood-Smith D. "Horizontal osteotomy of the mandible". *Plastic and Reconstructive Surgery* 34 (1964): 464-471.
28. Reichenbach E, *et al.* "Chirurgische Kieferorthopadie". Leipzig, Johann Amrosious Barth Verlag (1965).
29. Hinds EC and Kent JN. "Genioplasty: The Versatility of Horizontal osteotomy". *Journal of Oral and Maxillofacial Surgery* 27.9 (1969): 690-700.
30. Edwards RC, *et al.* "Resorbable fixation techniques for genioplasty". *Journal of Oral and Maxillofacial Surgery* 58.3 (2000): 269-272.
31. Triaca A, *et al.* "Treatment of mandibular retrusion by distraction osteogenesis: a new technique". *British Journal of Oral and Maxillofacial Surgery* 42 (2004): 89-95.
32. Guyman B. "Genioplasty". Guyman B (ed) Boston, Little Brown (1993): 170-185.
33. Snell RS. "Clinical Anatomy for medical students". 5th edition (1995): 70-78.
34. Storum KA, *et al.* "Microangiographic and histologic evaluation of revascularization and healing after genioplasty by osteotomy of the inferior border of the mandible". *Journal of Oral and Maxillofacial Surgery* 46.3 (1988): 210-216.
35. Ritter EF, *et al.* "The course of the inferior alveolar neurovascular canal in relation to sliding genioplasty". *Journal of Craniofacial Surgery* 3.1 (1992): 20-42.
36. Ousterhout DK. "Sliding genioplasty avoiding mental nerve injuries". *Journal of Craniofacial Surgery* 7.4 (1996): 297-298.

37. Guyot L., et al. "Alteration of Chin Sensibility Due to Damage of the Cutaneous Branch of the Mylohyoid Nerve During Genioplasty". *Journal of Oral and Maxillofacial Surgery* 60.11 (2002): 1371-1373.
38. Marinho RO and Tennant CJ. "Paresthesia of the cutaneous branch of the mylohyoid nerve after removal of a submandibular salivary gland". *Journal of Oral and Maxillofacial Surgery* 55.2 (1997): 170-171.
39. Rhee SC., et al. "Balanced Angular Profile Analysis". *Plastic and Reconstructive Surgery* 114.2 (2004): 535-544.
40. Bell Wh., et al. "Surgical Correction of Dentofacial Deformities". Philadelphia WB Saunders (1980): 1212-1213.
41. Powel N and Humphreys B. "Consideration and components of the aesthetic face". In *Proportion of the Aesthetic face*. Pawell N, Humphreys B. (eds). New York, Thieme-Stratton (1994): 1-40.
42. Stella JP, Mark E. "Osteoplasty and Advancement Genioplasty for Widening of the Chin". *Journal of Oral and Maxillofacial Surgery* 55.12 (1997): 1493-1496.
43. Frodel JL. "Evaluation and treatment of deformities of the chin". *Facial Plastic Surgery Clinics of North America* 13 (2005): 73-84.
44. Driemel O., et al. "Genioplasty alone and in combination. Long-term results with emphasis on sensitivity and photoanalysis". *Mund, Kiefer- und Gesichtschirurgie* 8.5 (2004): 289-295.
45. Stanton DC. "Genioplasty". *Facial Plastic Surgery* 19.1 (2003): 75-86.
46. Schendel SA and Bell WH. "Cephalometrics and orthognathic surgery". In, edition. *Modern Practice in Orthognathic and Reconstructive Surgery*, Philadelphia, PA: WB Saunders 1 (1992): 84-99.
47. Burstone CJ. "Lip posture and its significance in treatment planning". *American Journal of Orthodontics and Dentofacial Orthopedics* 53 (1967): 262-284.
48. Burstone CJ. "Integumental contour and extension patterns". *Angle Orthodontist* 29.2 (1959): 93-104.
49. Yeo DK., et al. "Distortions in panoramic radiographs". *Australian Orthodontic Journal* 18.2 (2002): 92-98.
50. Choi YG., et al. "Cross-sectional study of the factors that influence radiographic magnification of implant diameter and length". *International Journal of Oral and Maxillofacial Implants* 19 (2004): 594-596.
51. Veltkamp T., et al. "Predicting lower lip and chin response to mandibular advancement and genioplasty". *American Journal of Orthodontics and Dentofacial Orthopedics* 122.6 (2002): 627-634.
52. Shaughnessy S., et al. "Long-term skeletal and soft-tissue responses after advancement genioplasty". *American Journal of Orthodontics and Dentofacial Orthopedics* 130.1 (2006): 8-17.
53. Ricketts RH. "Planning treatment on the basis of the facial pattern and an estimate of its growth". *Angle Orthodontist* 27.1 (1957): 14-37.
54. Gonzales-Ulloa M and Stevens E. "The role of chin correction in profileplasty". *Plastic and Reconstructive Surgery* 41.5 (1974): 477-486.
55. Merrifield LL. "The profile line as an aid in critically evaluating facial esthetics". *American Journal of Orthodontics* 52.11 (1966): 804-826.
56. Hambleton RS. "Soft tissue covering of the skeletal face as related to orthodontic problems". *American Journal of Orthodontics* 50.6 (1964): 405-420.

57. Zimmer GH. "Another look at the soft tissue profile". Unpublished manuscript (1970).
58. Matarasso A, *et al.* "Labial incompetence: A marker for progressive bone resorption in Silastic chin augmentation". *Plastic and Reconstructive Surgery* 98.6 (1996): 1007-1014.
59. Van Sickels JE and Tiner BD. "Cost of a genioplasty under deep intravenous sedation in a private office versus general anesthesia in an outpatient surgical center". *Journal of Oral and Maxillofacial Surgery* 50.7 (1992): 687-690.
60. Schubert G, *et al.* "Mandibular advancement and reduction genioplasty". *American Journal of Orthodontics and Dentofacial Orthopedics* 98 (1990): 481-487.
61. Satoh K and Onizuka T. "A new osteotomy for genioplasty-stepped osteotomy: Preliminary report". *Annals of Plastic Surgery* 31.2 (1993): 186-190.
62. Wang J, *et al.* "The sagittal curving osteotomy: A modified technique for advancement genioplasty". *Journal of Plastic, Reconstructive and Aesthetic Surgery* 60.2 (2007): 119-124.
63. Wider TM, *et al.* "Simultaneous osseous genioplasty and mentoplasty". *Plastic and Reconstructive Surgery* 99.5 (1997): 1273-1281.
64. Mommaerts MY, *et al.* "Intraoral transmental suction lipectomy". *International Journal of Oral and Maxillofacial Surgery* 31.4 (2002): 364-366.
65. Dolce C, *et al.* "Maintenance of soft tissue changes after rigid versus wire fixation for mandibular advancement with and without genioplasty". *Oral Surgery, Oral Medicine, Oral Pathology, Oral Radiology, and Endodontics* 92.2 (2001): 142-149.
66. Talebzadeh N and Pogrel MA. "Long-term hard and soft tissue relapse rate after genioplasty". *Oral Surgery, Oral Medicine, Oral Pathology, Oral Radiology, and Endodontics* 91.2 (2001): 153-156.
67. Dolce C, *et al.* "Five-year outcome and predictability of soft tissue profiles when wire or rigid fixation is used in mandibular advancement surgery". *American Journal of Orthodontics and Dentofacial Orthopedics* 124.3 (2003): 249-256.
68. Gibbons AJ, *et al.* "Stabilisation of Genioplasty During Rigid Fixation: Use of A Holding Screw". *British Journal of Oral and Maxillofacial Surgery* 40.4 (2002): 346-347.
69. Precious DS, *et al.* "Anatomic placement of fixation devices in genioplasty". *Oral Surgery, Oral Medicine, Oral Pathology, and Oral Radiology* 73.1 (1992): 2-8.
70. Chaushu G, *et al.* "The effect of precise reattachment of the mentalis muscle on the soft tissue response to genioplasty". *Journal of Oral and Maxillofacial Surgery* 59.5 (2001): 510-516.
71. Joban P, *et al.* "A Simplified Technique of Genioplasty With Simultaneous Widening or Narrowing of the Chin". *Journal of Oral and Maxillofacial Surgery* 59.10 (2001): 1244-1245.
72. Raffaini M and Sesenna E. "Hemi-Genioplasty: A Technique to Correct Chin Asymmetry". *Journal of Oral and Maxillofacial Surgery* 53.11 (1995): 1362-1364.
73. Nevner O. "Correction of mandibular deformities". *Oral Surgery* 36.6 (1973): 779-789.
74. Michelet FX, *et al.* "L'Utilisation de la Symphyse Mentonniere". *Annales De Chirurgie Plastique* 19 (1974): 69.
75. Riley R, *et al.* "Mandibular osteotomy and hyoid bone advancement for obstructive sleep apnea: A case report". *Sleep* 7.1 (1984): 79-82.

76. Alvarez CM., *et al.* "Mandibular advancement combined with horizontal advancement genioplasty for treatment of obstructive sleep apnea in an edentulous patient". *Oral Surgery* 64.4 (1987): 402-406.
77. Vert M., *et al.* "Totally bioresorbable composite systems for internal fixation of bone fractures". In: Proceedings of the 2nd International Conference on Polymers in medicine: biomedical and pharmaceutical applications. Capri, Italy (1985): 3-7.
78. Tormola P. "Biodegradable self-reinforced composite materials, manufacturing structure and mechanical properties". *Clinical Materials* 10.1-2 (1992): 29-34.
79. Antikainen T., *et al.* "Polyglycolic acid membrane interpositioning for the prevention of skull deformity following experimental craniostenosis". *Pediatric Neurosurgery* 21.1 (1994): 77-82.
80. Eppley B L. "Resorbable biotechnology for craniomaxillofacial surgery". *Journal of Craniofacial Surgery* 8.2 (1997): 85-86.
81. Habal MB and Pietrzak WS. "Key points in the fixation of craniofacial skeleton with absorbable biomaterial". *Journal of Craniofacial Surgery* 10.6 (1999): 491-499.
82. Tormola P., *et al.* "Ultra-highstrength absorbable self-reinforced polyglycolide (SR-PGA) composite rods for internal fixation of bone fractures: in vitro and in vivo study". *Journal of Biomedical Materials Research* 25.1 (1991): 1-22.
83. Ashammakhi N., *et al.* "Effect of self reinforced polyglycolide membranes on cortical bone: an experimental study on rats". *Journal of Biomedical Materials Research* 29.6 (1995): 687-694.
84. Ashammakhi NA., *et al.* "Developments in craniomaxillofacial surgery: use of self-reinforced bioabsorbable osteofixation devices". *Plastic and Reconstructive Surgery* 108.1 (2001): 167-180.
85. Ashammakhi N., *et al.* "New resorbable bone fixation Biomaterials in craniomaxillofacial surgery: present and future". *European Journal of Plastic Surgery* 26.8 (2004): 383-390.
86. Kallela I., *et al.* "Fixation of mandibular body osteotomies using biodegradable amorphous self-reinforced (70L: 30DL) polylactide or metal lag screws: an experimental study in sheep". *Journal of Cranio-Maxillo-Facial Surgery* 27.2 (1999): 124-133.
87. Tiainen J., *et al.* "Comparison of the pull-out forces of bioabsorbable polylactide/glycolide screws (Biosorb and Lactosorb) and tacks: a study on the stability of fixation in human cadaver parietal bones". *Journal of Craniofacial Surgery* 13.4 (2002): 538-543.
88. Veiranto M., *et al.* "In vitro properties of antibiotic releasing SR-PLGA CMF fixation screws". Oulu University Science Day, Oulu, Finland (2003).
89. Peltoniemi HH., *et al.* "Biodegradable and titanium plating in experimental craniotomies: a radiographic follow-up study". *Journal of Craniofacial Surgery* 8.6 (1997): 446-451.
90. Peltoniemi H. "Biocompatibility and fixation properties of absorbable minimplants and screws in growing calvarium". An experimental study in sheep. PhD Thesis, Department of Surgery, University of Helsinki, Helsinki, Finland (2000).
91. Bergsma JE., *et al.* "Late degradation tissue response to poly(L-lactide) bone plates and screws". *Biomaterials* 16.1 (1995): 25-31.
92. Serlo W., *et al.* "Clinical application of a new technique for correction of trigonocephaly: use of bioabsorbable osteofixation tacks, tackshooter and plates". 16th Congress of European Association for Cranio-maxillofacial Surgery, Monster, Germany (2002).
93. Serlo W., *et al.* "Self-reinforced polylactide osteosynthesis devices in craniofacial surgery: A long-term follow-up study". *Scandinavian Journal of Plastic and Reconstructive Surgery and Hand Surgery* 35.3 (2001): 285-292.

94. Ninkovic M., *et al.* "Preliminary clinical experience with biodegradable plate and screw fixation In Proceedings of the European Union Demonstration Project BMH4-98-3892, Treatment of craniofacial syndromes with biodegradable plates, screws and wire". 2nd Symposium on Biodegradable Materials in Craniofacial Surgery, April, Saariselk, Finland (1999).
95. Vesala AL., *et al.* "Poly-Llactic acid plate for covering of small cranial bone holes. An experimental study in rabbits". *European Journal of Plastic Surgery* 23.1 (2000): 36-38.
96. Pietrzak WS and Eppley BL. "Resorbable polymer fixation for craniomaxillofacial surgery: development and engineering paradigms". *Journal of Craniofacial Surgery* 11.6 (2000): 575-585.
97. Ashammakhi N., *et al.* "Spotlights on naturally absorbable osteofixation devices: a review". *Journal of Craniofacial Surgery* 14.2 (2003): 247-259.
98. Tormola P., *et al.* "Bioabsorbable polymers: materials technology and surgical applications". *Proceedings of the Institution of Mechanical Engineers* 212 (1998): 101-111.
99. Peltomiemi HH., *et al.* "Biodegradable semirigid plate and miniscrew fixation compared with rigid titanium fixation in experimental calvarial osteotomy". *Journal of Neurosurgery* 90 (1999): 910-917.
100. Ashammakhi N., *et al.* "Use of bioabsorbable tacks and plates to fix parietal bone split grafts used for reconstruction of a post-traumatic frontal bone defect". 16th Congress of European Association for Cranio-maxillofacial Surgery, Germany (2002).
101. Getter L., *et al.* "A biodegradable intraosseous appliance in the treatment of mandibular fractures". *Journal of Oral and Maxillofacial Surgery* 30.5 (1972): 344-348.
102. Gerlach KL., *et al.* "Use of absorbable osteosynthesis material for mandibular fracture treatment of dogs". In: Pizzoferrato A, Marchetti PG, Ravaglioli A, Lee AJC (eds) *Biomaterials and clinical applications. Advances in biomaterials*, Elsevier, Amsterdam (1997).
103. Edwards RC and Kiely KD. "Resorbable fixation of Le Fort I osteotomies". *Journal of Craniofacial Surgery* 9.3 (1998): 210-214.
104. Waris T and Pohjonen T. "Self-reinforced absorbable polylactide (SR-PLLA) plates in craniofacial surgery. A preliminary report on 14 patients". *European Journal of Plastic Surgery* 17.5 (1994): 236-238.
105. Fuente del Campo AF., *et al.* "Estabilidad de las placabiodegradables en in cirugía ortognatica valoracion a largo plazo". *Revista Acta Chirurgiae Plasticae* 2 (1996): 218.
106. Tams J., *et al.* "High-impact poly (L/D-lactide) for fracture fixation: in vitro degradation and animal pilot study". *Biomaterials* 16.18 (1995): 1409-1415.
107. Yaremchuk MJ and Posnick JC. "Resolving controversies related to plate and screw fixation in the growing craniofacial skeleton". *Journal of Craniofacial Surgery* 6.6 (1995): 525-538.
108. Sun ZL., *et al.* "Effects of metal ions on osteoblastlike cell metabolism and differentiation". *Journal of Biomedical Materials Research* 34.1 (1997): 29-37.
109. Hofmann GO., *et al.* "Postoperative irradiation treatment and bioresorbable implants in orthopaedic surgery: an experimental in vitro study". *Biomaterials* 17.11 (1996): 1149-1153.
110. Rozema FR., *et al.* "Influence of resorbable poly(L-lactide) bone plates and screws on the dose distributions of radiotherapy beams". *International Journal of Oral and Maxillofacial Surgery* 19 (1990): 374-376.

111. Honig JF, *et al.* "Passive and active intracranial translocation of osteosynthesis plates in adolescent minipigs". *Journal of Craniofacial Surgery* 6 (1995): 292.
112. Leinonen S, *et al.* "Holding power of bioabsorbable ciprofloxacin-containing selfreinforced poly-L/DL-lactide 70/ 30 bioactive glass 13 miniscrews in human cadaver bone". *Journal of Craniofacial Surgery* 13.2 (2002): 212-218.
113. Eppley BL. "Use of a resorbable fixation technique for maxillary fractures". *Journal of Craniofacial Surgery* 9.4 (1998): 317-321.
114. Pietrzak WS, *et al.* "Effect of simulated intraoperative heating and shaping on mechanical properties of a bioabsorbable fracture plate material". *Journal of Biomedical Materials Research* 38.1 (1997): 17-24.
115. Cutright DE and Hunsuck EE. "The repair of fractures of the orbital floor using biodegradable polylactic acid". *Oral Surgery, Oral Medicine, and Oral Pathology* 33.1 (1972): 28-34.
116. Gallagher DM, *et al.* "Soft tissue changes associated with advancement genioplasty performed concomitantly with superior repositioning of the maxilla". *Journal of Oral and Maxillofacial Surgery* 42.4 (1984): 238-242.
117. Davis WH, *et al.* "Long-term bony and soft tissue stability following advancement genioplasty". *Journal of Oral and Maxillofacial Surgery* 46.9 (1988): 731-735.
118. Park HS, *et al.* "A retrospective study of advancement genioplasty". *Oral Surgery, Oral Medicine, Oral Pathology* 67.5 (1989): 481-489.
119. Bell WH and Dann JJ. "Correction of dentofacial deformities by surgery in the anterior part of the jaws: A study of stability and soft tissuechanges". *American Journal of Orthodontics and Dentofacial Orthopedics* 64.2 (1973): 162-187.
120. McDonnell JP, *et al.* "Advancement genioplasty: A retrospective cephalometric analysis of osseous and soft tissue changes". *Journal of Oral and Maxillofacial Surgery* 35.8 (1977): 640-647.
121. Krekmanov L and Kahnberg K. "Soft tissue reponse to genioplasty procedures". *British Journal of Oral and Maxillofacial Surgery* 30.2 (1992): 87-91.
122. Reyneke JP, *et al.* "Screw osteosynthesis compared with wire osteosynthesis in advancement genioplasty: a retrospective study of skeletal stability". *British Journal of Oral and Maxillofacial Surgery* 35 (1997): 352-356.
123. Polido WD, *et al.* "Bone resorption, stability, and soft-tissue changes following large chin advancements". *Journal of Oral and Maxillofacial Surgery* 49.3 (1991): 251-256.
124. Wittbjer J and Rune B. "Changes of the profile after advancement genioplasty". *Scandinavian Journal of Plastic and Reconstructive Surgery and Hand Surgery* 23.1 (1989): 65-70.
125. Van Sickels JE, *et al.* "Hard and soft tissue predictability with advancement genioplasty". *Oral Surgery, Oral Medicine, Oral Pathology, and Oral Radiology* 77.3 (1994): 218-225
126. G J Kim GJ, *et al.* "Long-term results of vertical height augmentation genioplasty using autogenous iliac bone graft". *Oral Surgery, Oral Medicine, Oral Pathology, Oral Radiology, and Endodontology* 100.3 (2005): 51-57.
127. Ayoub AF, *et al.* "Evaluation of changes following advancement genioplasty using finite element analysis". *British Journal of Oral and Maxillofacial Surgery* 31.4 (1993): 217-222.
128. Bell WH. "Correction of mandibular prognathism by mandibular setback and advancement genioplasty". *International Journal of Oral and Maxillofacial Surgery* 10.4 (1981): 221-229.

129. Scheideman GB., *et al.* "Soft tissue changes with combined mandibular setback and advancement genioplasty". *Journal of Oral and Maxillofacial Surgery* 39.7 (1981): 505-509.
130. Bell WH and Gallegher DM. "The versatility of genioplasty using a broad pedicle". *Journal of Oral and Maxillofacial Surgery* 41.12 (1983): 763-769.
131. Friedland JA., *et al.* "Retrospective cephalometric analysis of mandibular bone absorption under silicone rubber chin implants". *Plastic and Reconstructive Surgery* 57.2 (1976): 144-151.
132. Hohl TH and Epker BN. "Macrogenia: a study of treatment results, with surgical recommendation". *Oral Surgery, Oral Medicine, Oral Pathology, and Oral Radiology* 41.5 (1976): 545-567.
133. Harle F., *et al.* "Atlas of Craniomaxillofacial Osteosynthesis" (1999).
134. Phillips ill and Rahn BA. "Bone healing". In: Yaremchuk MJ, Gruss JS, Manson PN, eds. *Rigid fixation in the craniomaxillofacial skeleton*. Boston: Butterworth-Heinemann (1992).
135. Steinemann SG. "Implants for stable fixation of fractures. In: Rubin LR, ed. *Biomaterials in reconstructive surgery*. St. Louis: Mosby (1983): 283- 311.
136. Ewers R and Harle F. "Experimental and clinical results of new advance: the treatment of facial trauma". *Plastic and Reconstructive Surgery* 75 (1983): 25-31.
137. Champy M and Lodde JP. "Study of stresses in the fractured mandible in man. Theoretical measurement and verification by extensometric gauges in situ". *Revue De Stomatologie Et De Chirurgie Maxillo-Faciale* 78.8 (1977): 545-551.
138. Schenk R and Willenegger H. "On the histology of primary bone healing". *langenbecks arch ken chir ver dtsch z chir* 308 (1964): 440-452.
139. Aboagweh T. "Evaluation of resorbable plate usage in treatment of mandibular fractures in comparison with normal titanium plate". PHD search, Damascus UN (2009).
140. Gianni AB., *et al.* "Neurosensory alterations of the inferior alveolar and mental nerve after genioplasty alone or associated with sagittal osteotomy of the mandibular ramus". *Journal of Cranio-Maxillo-Facial Surgery* 30.5 (2002): 295-303.
141. Mercuri L and Laskin Dm. "Avascular necrosis after anterior horizontal augmentation genioplasty". *Journal of Oral and Maxillofacial Surgery* 35 (1977): 296-298.
142. Zide BM and McCarthy J. "The mentalis muscle: an essential component of chin and lower lip position". *Plastic and Reconstructive Surgery* 83.3 (1989): 413-420.
143. Goracy ES. "Fracture of the mandible body and ramus during horizontal osteotomy for augmentation genioplasty". *Journal of Oral and Maxillofacial Surgery* 36.11 (1978): 892-894.
144. Proffit WR., *et al.* "Orthognathic surgery: a hierarchy of stability". *International Journal of Adult Orthodontics and Orthognathic Surgery* 11.3 (1996): 191-204.
145. Vedtofte P., *et al.* "Soft tissue changes after advancement genioplasty performed as pedicled or free transplants". *Journal of Cranio-Maxillofacial Surgery* 19.7 (1991): 304-310.
146. Troulis MJ., *et al.* "Extended genioplasty: long-term cephalometric, morphometric and sensory results". *International Journal of Oral and Maxillofacial Surgery* 29.3 (2000): 167-175.

147. Haug RH., *et al.* "An in vitro comparison of the effect of number and pattern of positional screws on load resistance". *Journal of Oral and Maxillofacial Surgery* 57 (1999): 300-308.
148. DeFreitas CE., *et al.* "A retrospective study of advancement genioplasty using a special bone plate". *Journal of Oral and Maxillofacial Surgery* 50.4 (1992): 340-346.
149. Romain P., *et al.* "Rhino-genioplasty". *Revue De Stomatologie Et De Chirurgie Maxillo-Faciale* 91.3 (1990): 233-239.
150. Busquets CJ and Sassouni V. "Changes in the integumental profile of the chin and lower lip after genioplasty". *Journal of Oral and Maxillofacial Surgery* 39.7 (1981): 499-504.
151. Ewing M and Ross RB. "Soft tissue response to mandibular advancement and genioplasty". *American Journal of Orthodontics and Dentofacial Orthopedics* 101.6 (1992): 550-555.
152. Lopez PE., *et al.* "Mandibular Basal Osteotomy (Wing Genioplasty)". *Oral Surgery, Oral Medicine, Oral Pathology, Oral Radiology, and Endodontology* 110.3 (2010): 315.
153. Westermarck A., *et al.* "Inferior alveolar nerve function after mandibular osteotomies". *British Journal of Oral and Maxillofacial Surgery* 36.6 (1998): 425-428.
154. Nishioka GJ., *et al.* "Neurosensory disturbance associated with the anterior mandibular horizontal osteotomy". *Journal of Oral and Maxillofacial Surgery* 46.2 (1988): 107-110.
155. Bedhet N., *et al.* "Hyperactivity of the muscles of the lip and chin and indications for surgery to reduce it". *L'Orthodontie Francaise* 72.4 (2001): 317-330.
156. Richard O., *et al.* "Complications of genioplasty". *Revue De Stomatologie Et De Chirurgie Maxillo-Faciale* 102.1 (2001): 34-39.
157. Guyuron B and Kadi JS. "Problems following genioplasty: Diagnosis and treatment". *Clinics in Plastic Surgery* 24.3 (1997): 507-514.

Volume 16 Issue 5 December 2017

© All rights reserved by Yamen Tarakji., *et al.*