

## Minimally Invasive Treatment of a 2<sup>nd</sup> Class II Using Transparent Aligners and Ceramic Veneers

**Ignacio Faus Matoses\* and Vicente Faus Matoses**

*Associate Professor of Stomatology, University of Valencia, Spain*

**\*Corresponding Author:** Ignacio Faus Matoses, Associate Professor of Stomatology, University of Valencia, Spain.

**Received:** October 27, 2017; **Published:** December 04, 2017

### Abstract

More and more adult patients are coming to their dentist/orthodontist, seeking a solution to their problems of crowding or dental malposition. On many occasions these patients demand an aesthetic and minimally invasive solution to carry out their treatment. The removable aligners play in these cases a very important role as a correction tool used by the orthodontist. Dental wear, loss of parts or old rehabilitative treatments can, in many cases, be a determining factor to be taken into account in this type of patients. In some of these cases, an interdisciplinary approach is essential to evaluate, diagnose and solve all the aesthetic problems that the patient poses. From a restorative point of view, before any rehabilitation of the smile, and especially in cases of adult patients, a treatment plan and a selection of the appropriate materials are required, previous orthodontics performing a very important role to perform minimally invasive treatments, improve inter-related relationships, as well as periodontal health. In the clinical case presented below, we will try to explain in a clear way the procedures carried out for the aesthetic rehabilitation of the smile in an adult patient with a class II division 2nd, by means of the use of transparent aligners and laminated fronts of adhered porcelain.

**Keywords:** *Minimally Invasive; Transparent Aligners; Ceramic Veneers*

### Introduction

Any oral rehabilitation requires a diagnosis, treatment plan and a selection of the appropriate materials [1]. In some cases, an interdisciplinary approach is essential to evaluate, diagnose and solve these problems, whether esthetic or functional [2].

The orthodontist plays an important role in the resolution of these treatments, helping the restorer when it comes to correcting problems with the dental position, inter-related relationships and improving the smile line [3]. Both disciplines, used together and appropriately, can help us achieve more demanding treatment goals and a much more conservative procedure with healthy tooth structure.

In this clinical case, an interdisciplinary approach was proposed given that orthodontic therapy prior to restoration with veneers in crowded and misaligned teeth shows predictable periodontal, functional and aesthetic results well documented in the literature [4].

### Presentation of the Case

The clinical case presented below is that of a 52-year-old patient who was looking for an aesthetic and functional improvement of her mouth. In the past, he had ruled out orthodontic treatment on several occasions due to the need for dental extractions as he had been proposed. In addition, the proposal of fixed multibrackets as the only valid system for the treatment of his case had also been one of the factors who had opted for the patient not to be treated so far.

On clinical examination, a Class II division II type B malocclusion of Van der Linden was observed [5], with the typical retroinclination of both upper central incisors and proclination of lateral incisors. At the vertical level there is an overbite approximately 1/3. Transversally, dental compression of the maxillary arch with a coronal inclination towards the palatine of maxillary canines and premolars (Figure 1a-1e) is observed, which highlights marked buccal corridors when the patient smiles (Figure 2).

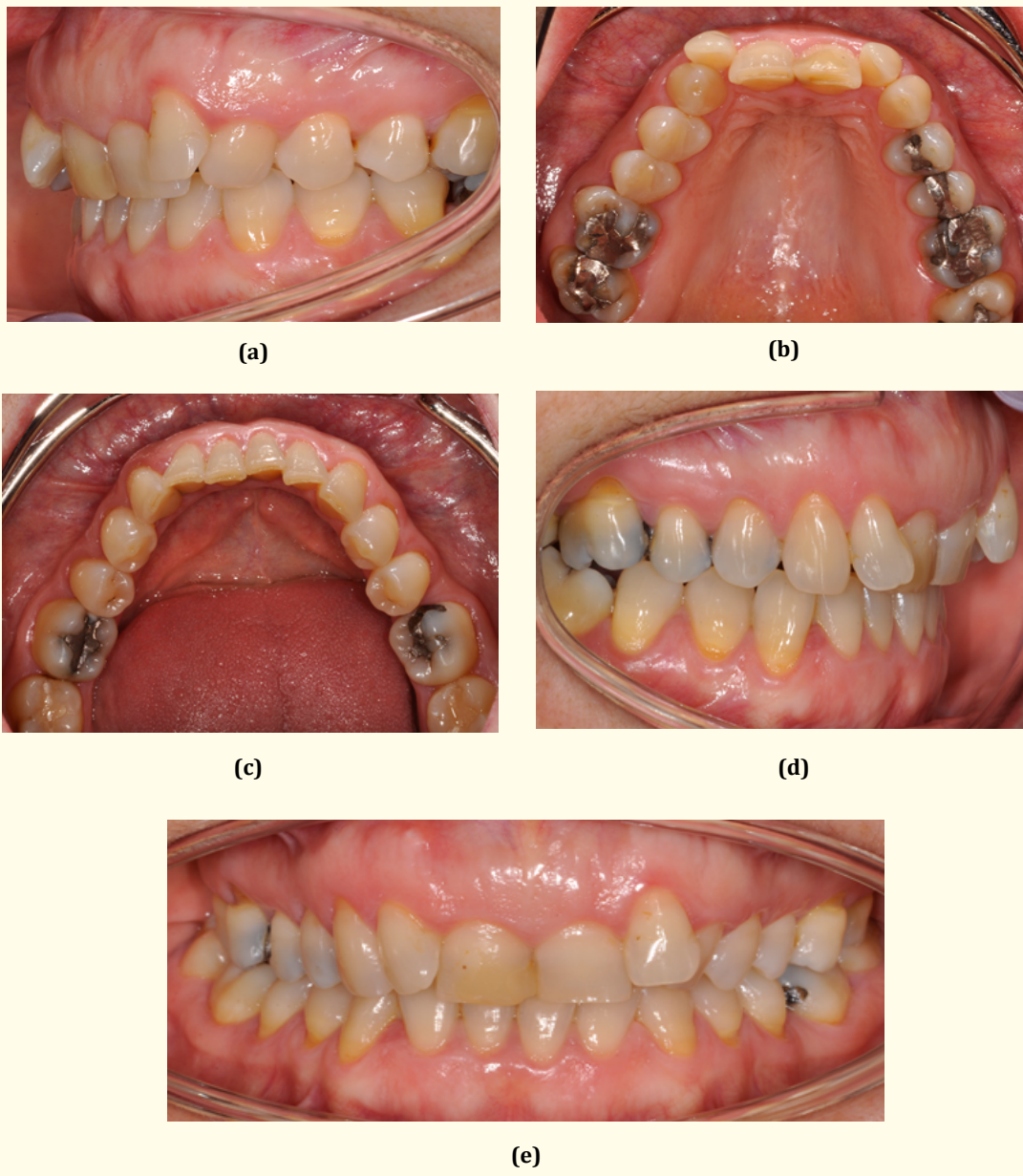


Figure 1a, b, c, d and e.

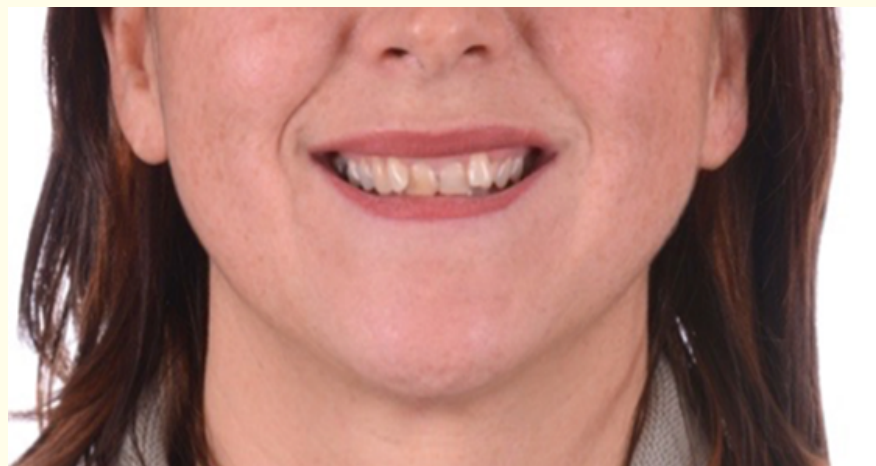
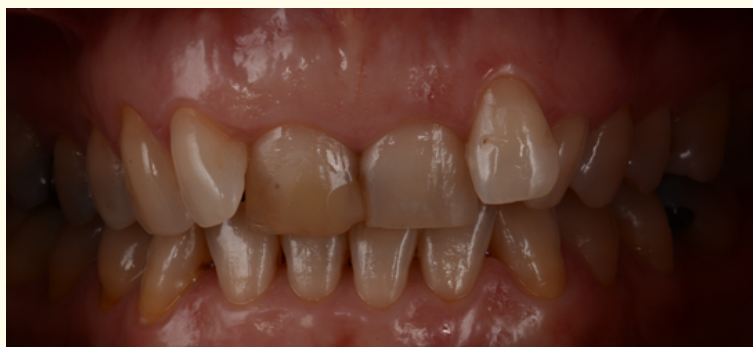
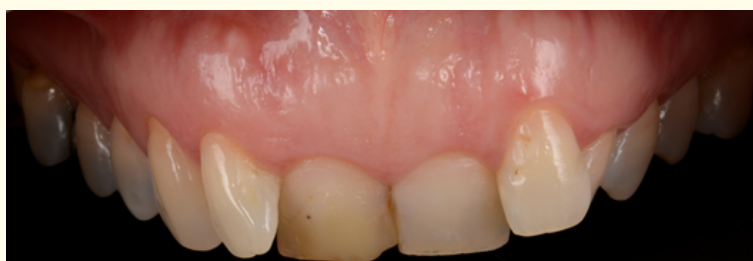Figure 2

At the previous level, there is marked wear of the upper central incisors and an old composite restoration on tooth 1.1 that the patient wanted to change, due to the staining that had suffered over time (Figure 3a, 3b).



(a)



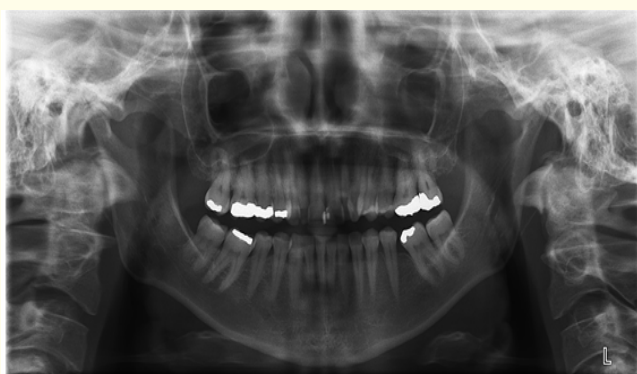(b)

Figure 3a and 3b.

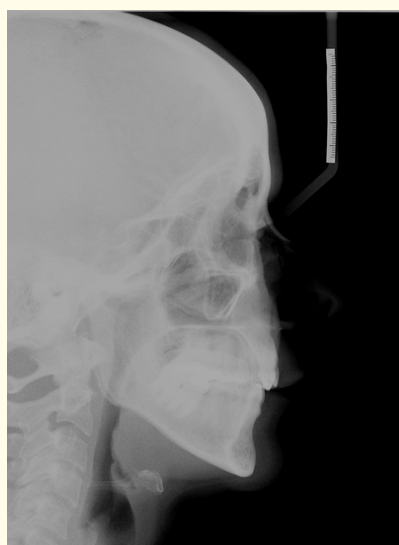Radiographically in the Orthopantomography (Figure 4a) we see the absence of both upper third molars that had been extracted and of the first lower molars that had suffered the same fate although a long time ago, which meant that there were no spaces in the arch through spontaneous mesialization of the lower second and third molars.

Orthodontically the case was approached with the help of transparent aligners because the patient demanded an aesthetics and comfort greater than what could be offered with conventional multibrackets.

The extraction of dental pieces was not considered, given that the patient had no third molars (Figure 4a, 4b) and the treatment strategy consisted of the distalization of the upper arch and the use of the space of said molars to achieve an occlusion of dental class I and space at a previous level to achieve an adequate alignment. Another objective of the orthodontic treatment was to obtain a correct anterior guide to avoid the continuous wear that the incisors had suffered and to protect in turn the future ceramic restorations of possible harmful occlusal loads.



(a)



(b)

Figure 4a and 4b.

For the preparation of personalized orthodontic appliances, the necessary impressions were taken and the necessary dental movements in the computer software were carried out in order to achieve the objectives previously enumerated.

The clinical instructions that were given to the technicians for dental movement were the following (Figure 5):

1. Sequential distalization of the upper arch with V protocol at maximum speed until canine class I.
2. Interproximal reduction (IPR) in lower incisors, as necessary, to compensate for the negative Bolton Index of both upper lateral incisors.
3. Performing dentoalveolar expansion of the posterior superior sectors during the distalization movement to achieve an ovoid shaped arch.
4. Alignment of the gingival margins with the protocol “high-low-high” (Kokich) for canines - lateral - central [6].
5. Placement of cut-outs for button in teeth 3.7 - 4.7 and cuts for elastic in 1.4 and 2.4.

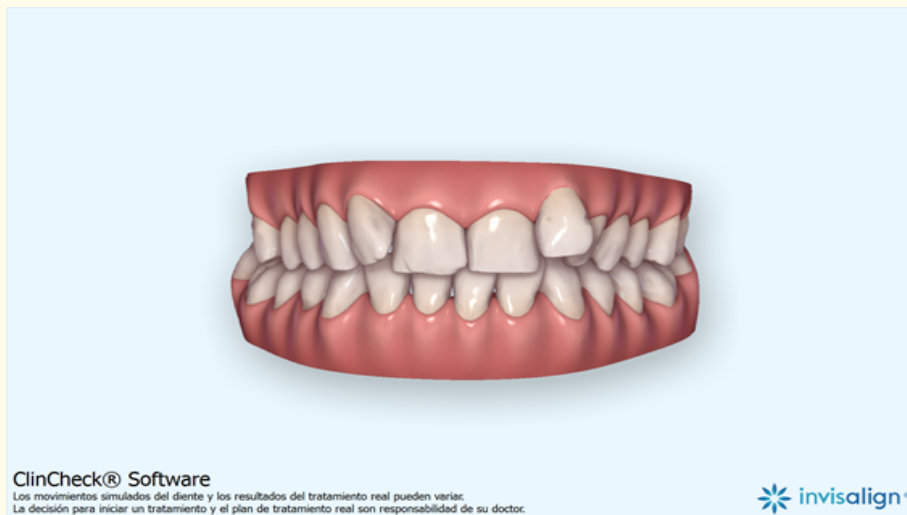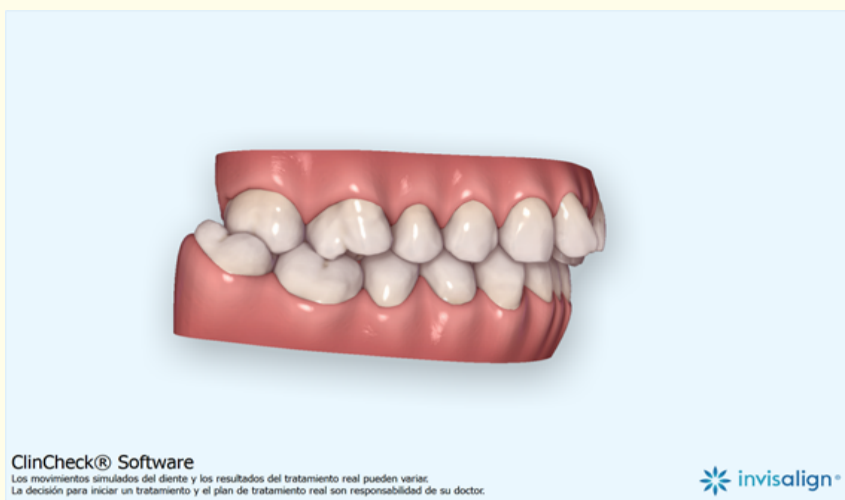


Figure 5.

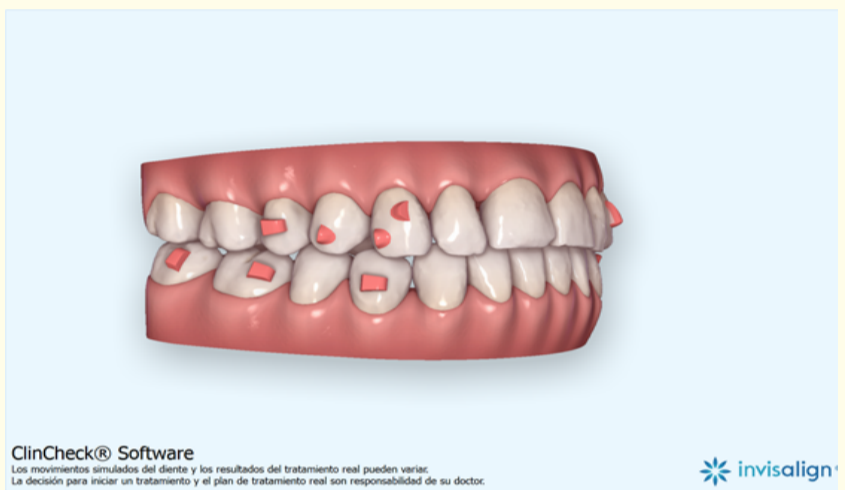
From the clinical point of view and in a general way, the following considerations were taken:

1. The aligners were initially changed every 15 days, later and progressively the use of them was reduced to 5 days each.
2. The attachments were cemented the day the patient began using the number 3 aligner. The IPR was performed once the lower incisors were correctly aligned.
3. From number 10 aligner, the buttons for the use of elastics were cemented and intermaxillary elastics were prescribed with class II component, 24 hours/day, 3/16 “in length and 4.5 oz. of force.

It was necessary an initial treatment plan and three refinements to achieve the objectives set from an aesthetic and functional point of view. The duration of all the phases of the treatment, including the waiting times for the planning of each of them and manufacture of the aligners, was 24 months (Figure 6a, 6b).



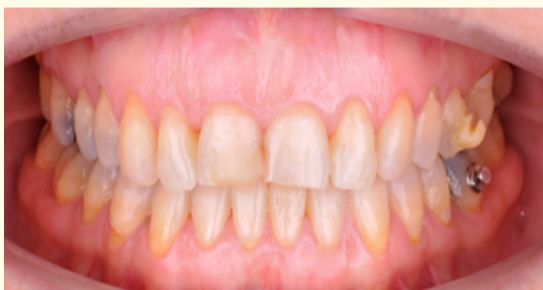(a)



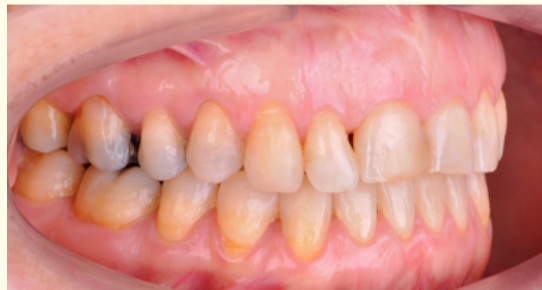(b)

Figure 6a and 6b.

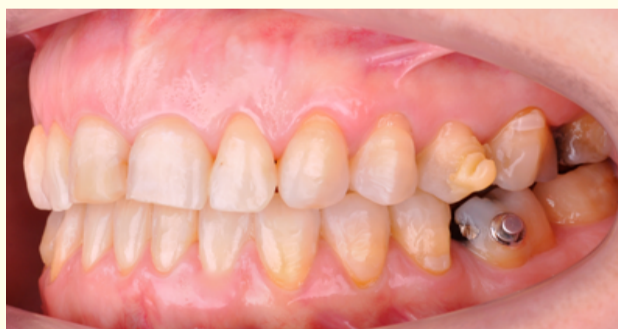Once the orthodontic treatment was completed and the dental class I achieved with an optimal dental alignment, with overjet and functional overbite, we observed a lack of harmony in the aesthetics of the patient’s smile at the extraoral level, with an inverted smile [7,8] (Figure 7) fruit of the initial planning, with the aim of achieving prosthetic free space for the adhered ceramic veneers that were later to be placed, and seeking in this way that the restorative treatment was minimally invasive.



(a)



(b)



(c)

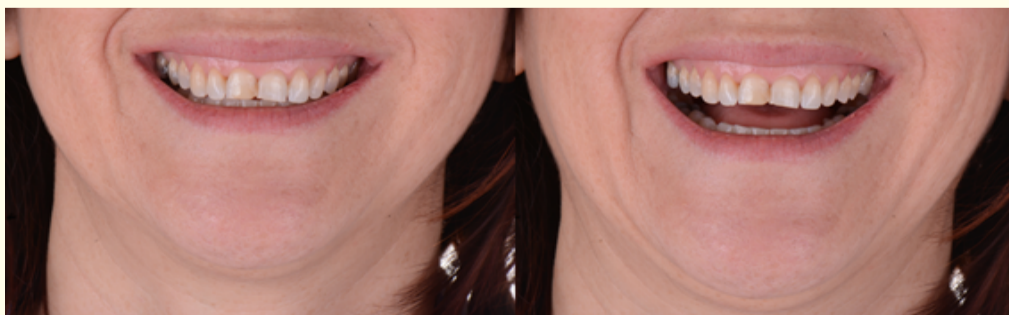

Figure 7.

Given the lack of harmony in the dental proportions of both upper central incisors, it was decided, by replacing the old composite of tooth 1.1 and placing two feldspathic ceramic veneers in 1.1 and 2.1, looking for that thanks to the translucence of said material you get an aesthetic appearance that mimics the rest of natural teeth. Contrary to what can be thought about feldspathic ceramic veneers, they show high rates of long-term survival, being in the study by Layton., *et al.* of 96 +/- 2% after a period of 21 years [9].

For the fabrication of the adhered porcelain restorations, an additive diagnostic wax was first performed (Figure 8) of both central incisors that was used to make a “mock up” [10] (Figure 9) or test aesthetics, used both for the static and dynamic assessment of the patient’s smile, as well as for assessing the realization of the relevant modifications and deciding the size and definitive shape of the attached ceramic restorations, guided by facial aesthetics as a whole.

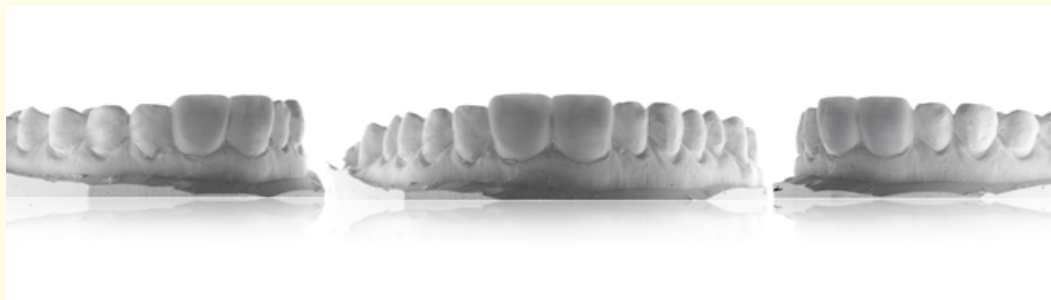

Figure 8: Diagnostic waxing of both plants.



Figure 9: Mock up placed in mouth

Validated the “mock up” aesthetically, and as described by Pascal Magne [11], it was used as a guide for the preparation of both incisors, in order to perform a minimally invasive dental carving (Figure 10). After dental preparation gingival retraction threads were placed prior to taking impressions with polymethylsiloxane.

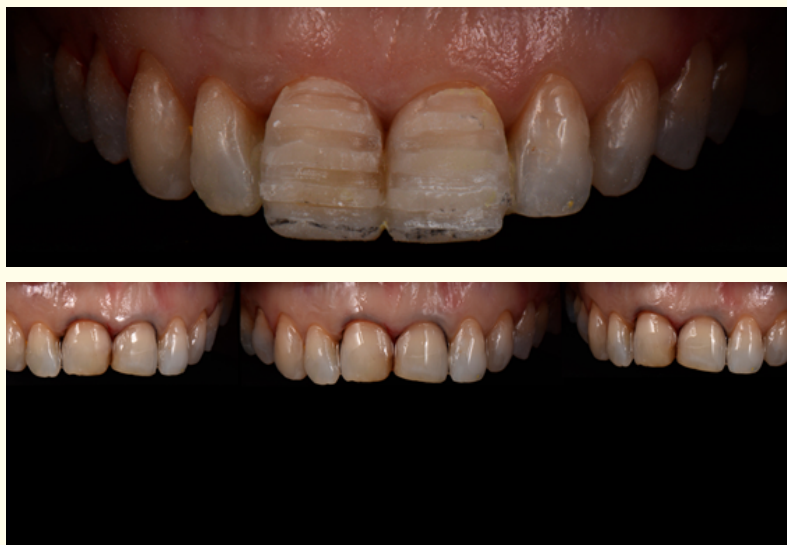
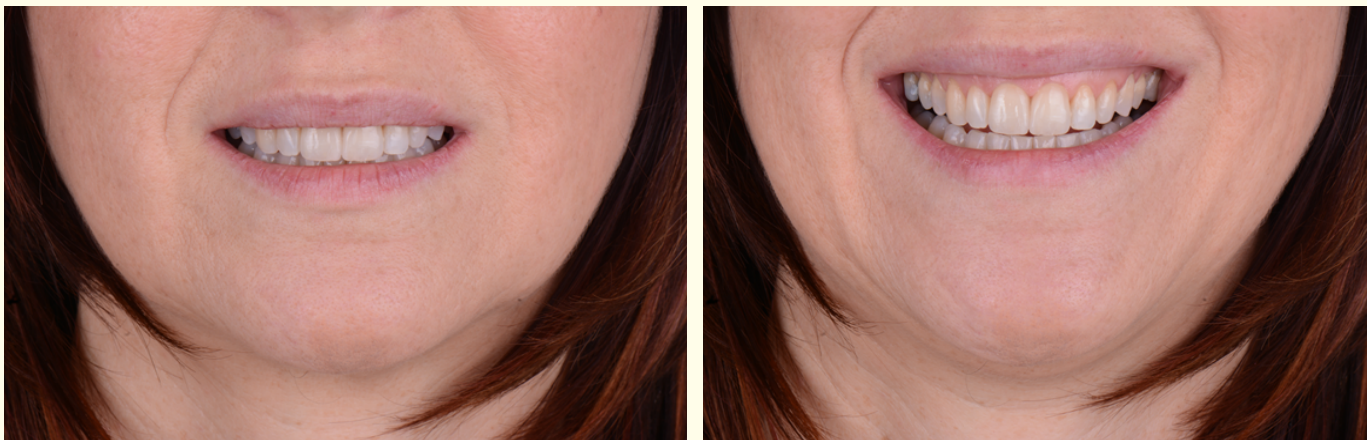
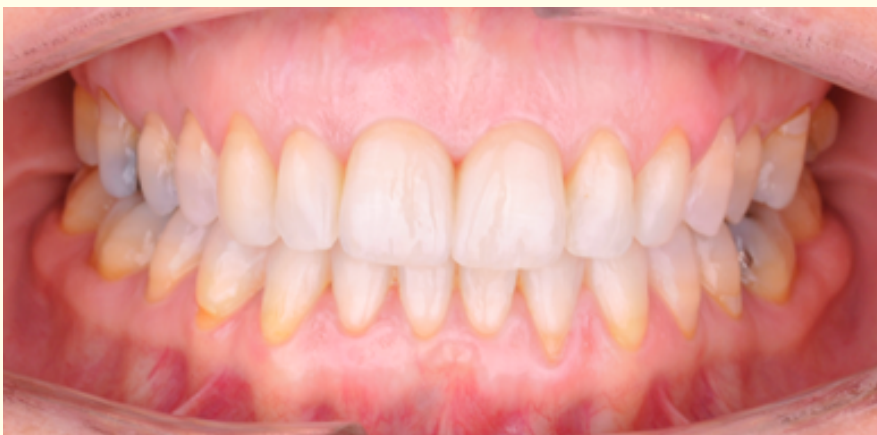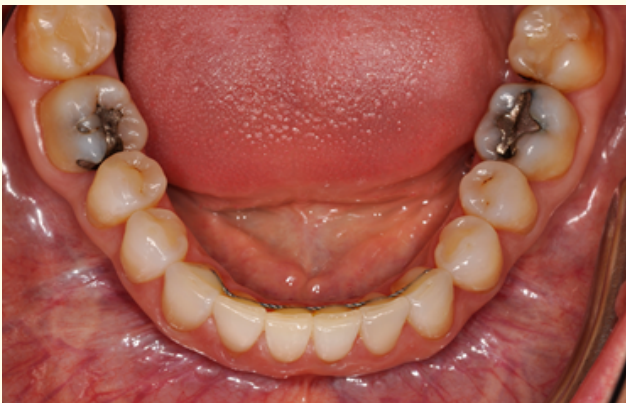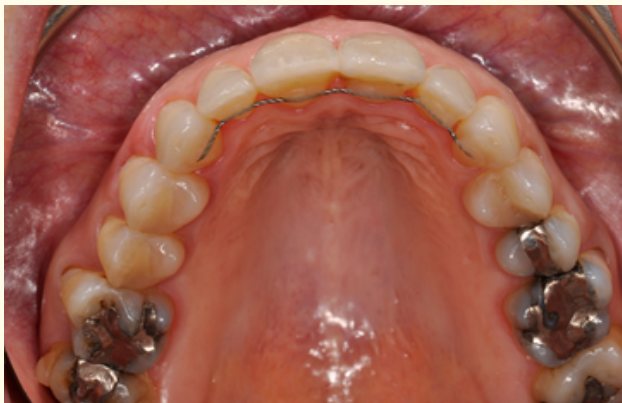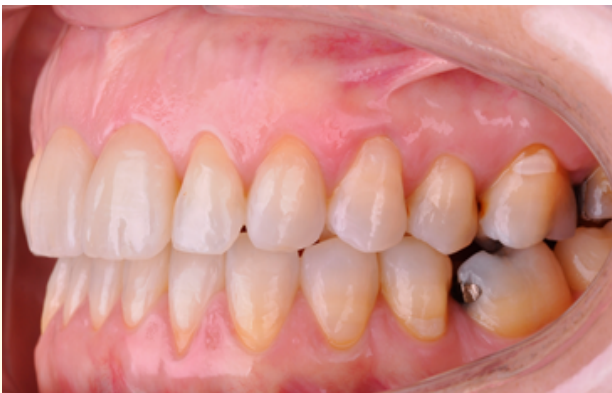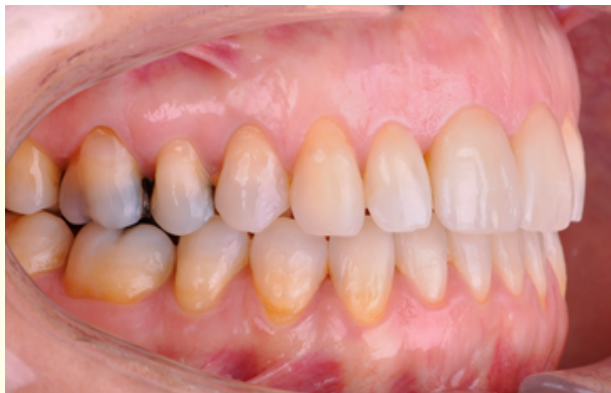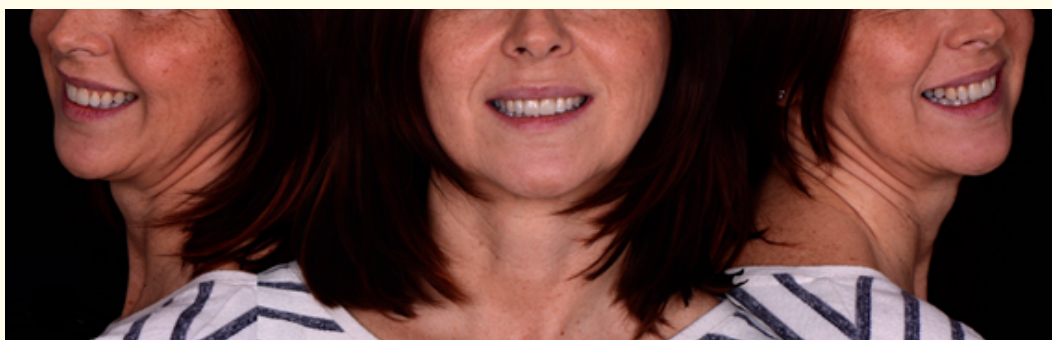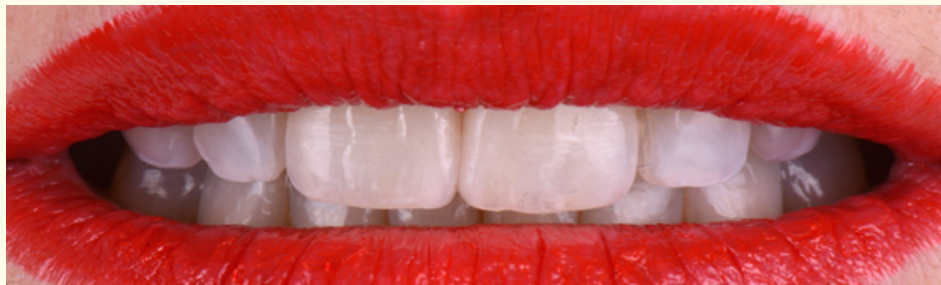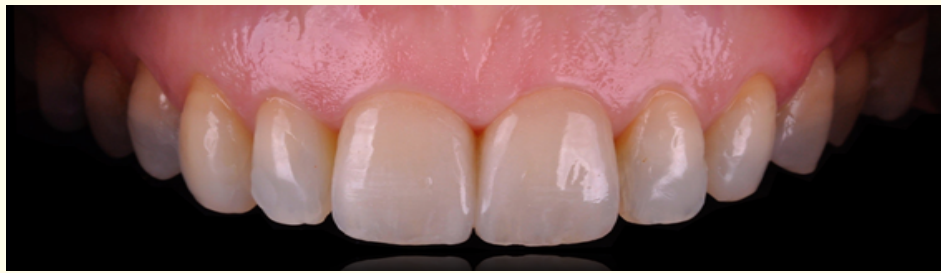Figure 10: Carved through the mock-up.



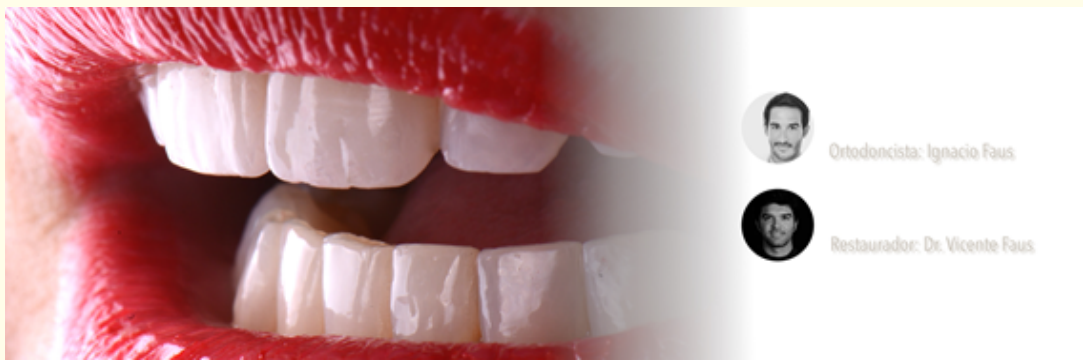*Figure 11a and b: Photo at rest and smile with some veneers once placed.*



*Figure 12a, b, c, d and e: Final intraoral photographs where we appreciate occlusal and aesthetic improvement.*



*Figure 13a, b and c: Final intra and extraoral photographs*



*Figure 14.*

Once the teeth were prepared, a photographic series was carried out with polarized filters and color guide, in this way the visualization of the real color of the tooth is clearer, since the filters eliminate any brightness that could distort said taking of color. After this procedure all the photographic material and dental impressions were sent to the laboratory technician, who proceeded to make the feldspathic ceramic veneers.

Prior to the cementing process, the veneers were placed in the mouth to check the marginal fit. Next, the cement was selected by try-in tests (Calibra Veneer, Dentsply Sirona, Konstanz, Germany) and the two veneers were simultaneously cemented. For tooth preparation, the composite restoration was silicated using an air abrasion device at a pressure of 2.5 bar from a distance of approximately 10 mm for 5 seconds (Cojet, 3M ESPE, Seefeld, Germany). Enamel and dentin were etched with 37% orthophosphoric acid (DeTrey Conditioner 36, Dentsply Sirona, Konstanz, Germany) and an adhesive layer was applied (Prime and Bond NT, Dentsply Sirona, Konstanz, Germany). On the other hand, the veneers were prepared by 9.5% hydrofluoric acid for 2 minutes (Ultradent, Ultradent Products, Inc.), ultrasonic bath with distilled water for 2 minutes, silane (Calibra, Dentsply Sirona, Konstanz, Germany) for one minute and dried with hot air and a thin layer of adhesive.



Finally, cement was applied on the inside of the veneers and placed on the teeth carefully. It was polymerized for 3 seconds to remove excess cement and then polymerized for 40 seconds by palatin and 40 seconds by vestibular.

### Brief Revision of the Topic

It is common to find situations in which patients, especially adults, need orthodontic treatment to improve both the aesthetics and the function of their mouth, even as a correction prior to restorative aesthetic treatment with veneers attached to crowded and misaligned teeth. This interdisciplinary combination shows predictable periodontal, functional and aesthetic results, as well documented in the literature [4].

But occasionally, adults reject the previous orthodontic phase due to the time required and the aesthetic concerns and daily alterations that these treatments can cause [4,12]. The development and introduction of removable transparent aligners has increased the acceptance of orthodontic treatments by adult patients [13].

Initially, these treatment using aligners were limited to minor corrections of crowding at the previous level, leaving aside as a goal of orthodontic treatment a correct interrelation between arches. Nowadays, with the evolution of these transparent orthodontic systems, together with the greater experience in the use of these by the professional, results similar to those achieved with conventional fixed appliances can be achieved, opening up great possibilities for the treatment interdisciplinary of adult patients.

### Conclusions

After the completion of the following clinical case, we can conclude that a treatment plan carried out from an interdisciplinary point of view, with proper coordination and communication between professionals is key to obtain an adequate result both functional and aesthetic and minimally invasive in the sector previous.

### Bibliography

1. Federizzi L., et al. "Use of Feldspathic Porcelain Veneers to Improve Smile Harmony: A 3-Year Follow-up Report". *Brazilian Dental Journal* 27.6 (2016): 767-774.
2. Moon JE., et al. "Esthetic restorations of maxillary previous teeth with orthodontic treatment and porcelain laminate veneers: a case report". *Journal of Advanced Prosthodontics* 2.2 (2010): 61-63.
3. Ittipuriphat I and Leevailoj C. "Previous space management: interdisciplinary concepts". *Journal of Esthetic and Restorative Dentistry* 25.1 (2013): 16-30.
4. de Andrade OS., et al. "Esthetic and functional rehabilitation of crowded anterior mandibular teeth using ceramic veneers: a case report". *Quintessence International* 43.8 (2012): 661-670.
5. Van der Linden F P G M. "Development of the dentition". Quintessence, Chicago (1983).
6. Kokich VO Jr., et al. "Comparing the perception of dentists and lay people to altered dental esthetics". *Journal of Esthetic Dentistry* 11.6 (1999): 311-324.
7. Frush JP and Fisher RD. "The Age Factor in Dentogenics". *Journal of Prosthetic Dentistry* 7.1 (1957): 5-13.
8. Sarver D. "The importance of incisor positioning in the esthetic smile: the smile arc". *American Journal of Orthodontics and Dentofacial Orthopedics* 120.2 (2001): 98-111.
9. Layton DM and Walton TR. "The up to 21-year clinical outcome and survival of feldspathic porcelain veneers: accounting for clustering". *International Journal of Prosthodontic* 25.5 (2012): 604-612.
10. Magne P and Belser UC. "Novel porcelain laminate preparation approach driven by a diagnostic mock-up". *Journal of Esthetic and Restorative Dentistry* 16.1 (2004): 7-18.
11. Magne P and Magne M. "Use of additive waxing and direct intraoral mock-up for enamel preservation with porcelain laminate veneers". *European Journal of Esthetic Dentistry* 1.1 (2006): 10-19.
12. Türkaslan S and Ulusoy KU. "Esthetic rehabilitation of crowded anterior maxillary teeth utilizing ceramic veneers: a case report". *Cases Journal* 2 (2009): 8329.
13. Kim J., et al. "Restorative space management: treatment planning and clinical considerations for insufficient space". *Practical Procedures and Aesthetic Dentistry* 17.1 (2005): 19-25.

**Volume 16 Issue 2 December 2017**

**© All rights reserved by Ignacio Faus Matoses and Vicente Faus Matoses.**