

## Massive Hemangioma of Buccal Mucosa in Adults: A Case Report

Sana Hashmi<sup>1</sup> and Faisal Idrees<sup>2\*</sup>

<sup>1</sup>Senior Resident, Department of Dentistry, ESIC Hospital, Indore, India

<sup>2</sup>Specialist, Department of Dentistry, ESIC Hospital, Indore, India

\*Corresponding Author: Faisal Idrees, Specialist, Department of Dentistry, ESIC Hospital, Indore, India.

Received: August 08, 2017; Published: October 04, 2017

### Abstract

Hemangioma is a benign vascular abnormality characterized by rapid growth of endothelial cells. It arises during first 8 weeks of life, rapidly proliferates during 6 - 12 months of life and gradually involutes by 9 - 12 years. Hemangiomas occur more in females with male to female ratio being 1:3 to 1:5. Almost 80 to 90% of hemangiomas involute completely by the age of 9 years. The remaining 10 - 20% involute incompletely and require post adolescent ablative treatment or other modes of management. 50 - 60% of hemangiomas occur in head and neck region. Lips, buccal mucosa and tongue are the most common sites of involvement intra orally. Here, we report a case of non involuting type of hemangioma located on buccal mucosa which were diagnosed histopathologically as cavernous (deep) hemangioma. Radiotherapy, cryotherapy, laser therapy, injection of sclerosing agent, selective embolisation are the various treatment modalities currently available for managing hemangiomas. Considering the location, size, accessibility and nature of lesion, surgical excision is the treatment of choice for smaller lesions.

**Keywords:** Cavernous Haemangioma; Intraoral; Phleboliths; Surgical Excision

### Introduction

Hemangioma is a benign vascular abnormality characterized by rapid endothelial cell proliferation. It is not present at birth but can be seen within the first month of life [1]. Hemangioma exist in three phases viz rapid proliferative phase, involuting phase, non-existent phase [2]. 65% of haemangiomas are located in the head and neck region. Intra orally lips, tongue, buccal mucosa and palate are common sites. Presence of phleboliths was also reported in some cases [3]. Hemangiomas are known to bleed excessively on manipulation. Hence, it is important for the clinician to diagnose such lesions.

The presentation of hemangiomas is variable in terms of size, extent and morphology. When there is superficial dermal involvement, the skin becomes raised, firm and bosselated with a vivid crimson color. If the hemangioma is limited to the deeper dermis, subcutaneous tissue or muscle, the overlying skin may be only slightly raised, warm, and have a bluish hue. All of these structures may be involved with a superficial raised component overlying a deeper tumor.

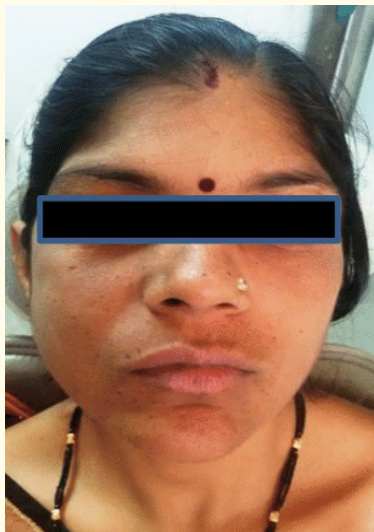The adjectives cavernous and capillary-previously used to describe deep and superficial hemangiomas, respectively-are confusing and inaccurate and should thus be eliminated [4,5].

This paper report a case of deep buccal hemangiomas, diagnosed on the basis of clinical, radiographic and histopathological findings and was treated surgically.

### Case Report

A 30 year old female patient reported with a chief complaint of intra oral swelling on the right buccal mucosa. Patient became aware of the swelling 4 months back and since then the swelling has gradually increased to the present size. On intra oral examination, a single, well defined, nodular lesion of normal mucosal color was seen on the right buccal mucosa. The overlying surface was irregular with normal surrounding area (Figure 2). On palpation, the lesion was soft and compressible, non tender, non pulsatile, non mobile and non adherent to underlying structures. The lesion blanched on pressure. Depending on the clinical features a provisional diagnosis of hemangioma was made. On aspiration, dark red colored fluid was collected suggestive of blood (Figure 4).

Routine blood investigations were normal. The computed tomography scan of neck as well as ultrasonography of right parotid was done to rule out the disease. The CT neck confirmed the presence of 3.9 x 2.5 x 1.9 cm size well defined well capsulated subtle enhancing hypodense area which is just indenting to right masseter muscle and smooth indentation on posterolateral wall of right maxillary sinus and alveolar process of right maxilla (Figure 3). The ultrasonography of right parotid was done using high frequency linear probe 7.5 - 12 MHz which was not contributory. On surgical excision, histopathological examination revealed deep cavernous hemangioma with stratified squamous keratinized epithelium. The connective tissue stroma showed large dilated and congested thin walled vascular channels engorged with red blood cells. Deeper connective tissue showed adipose tissue, muscle and mild chronic inflammatory cell infiltrate.



**Figure 1:** Pre operative facial asymmetry.

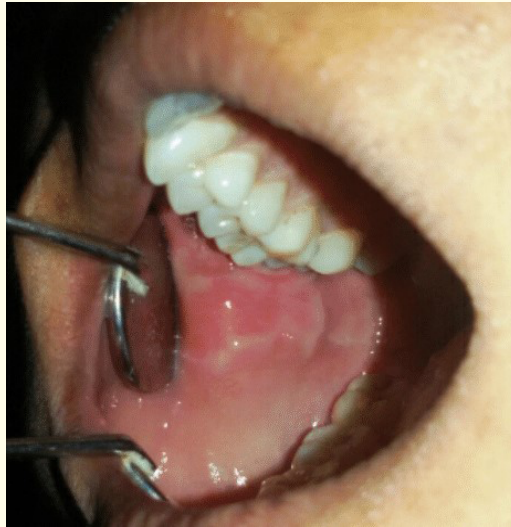

Figure 2: Irregular surface with normal surrounding area.

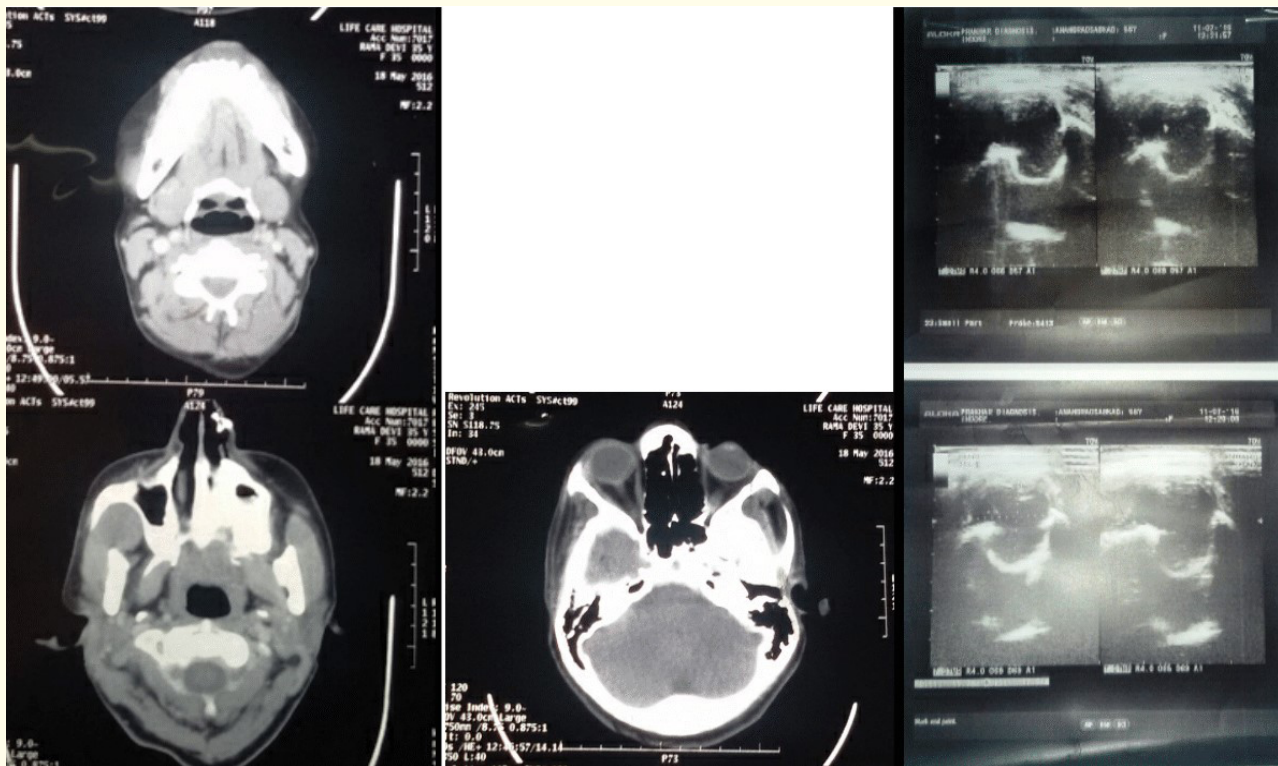
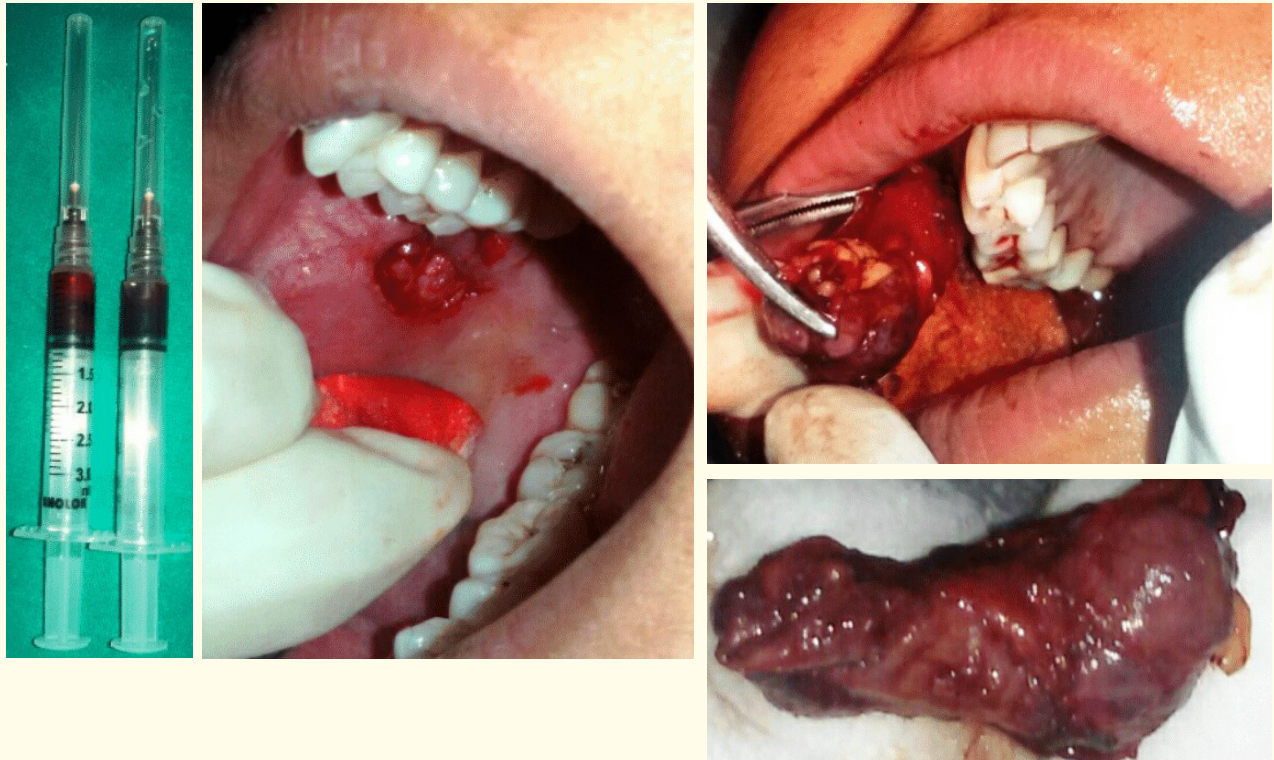
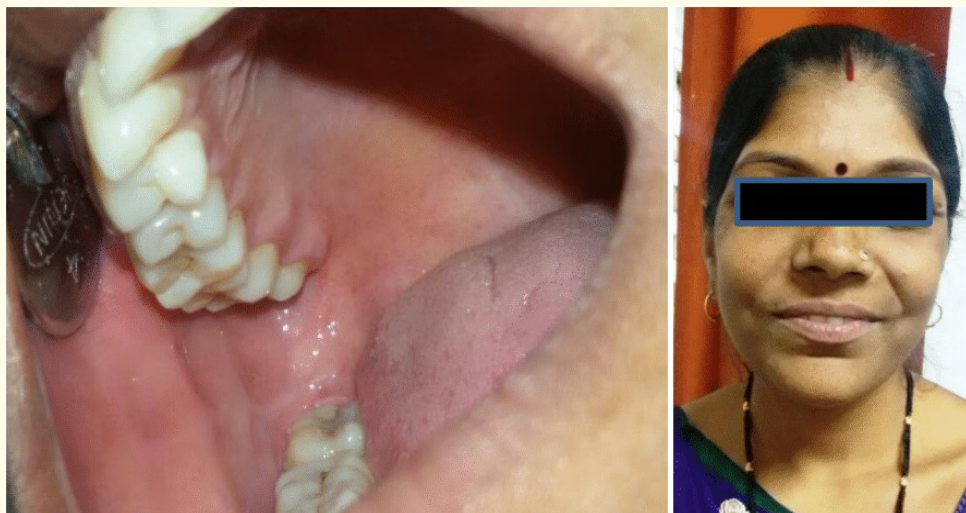

Figure 3: CT Neck and Ultrasonography of right parotid.





**Figure 4:** Blood on aspiration, Intraoperative procedure and Excised lesion.



**Figure 5:** Post operative intraoral and profile view.

### Discussion

Hemangiomas are considered benign tumors of the infancy and childhood, and have a different life cycle, being characterized by 3 stages: endothelial cell proliferation, rapid growth, and, at last, spontaneous involution. The lesion affects females in a higher, and the superficial type is the most frequent one [6-8]. With regard to the location and the number of lesions, a similarity with cases reported in the literature was observed, since approximately 80% of the patients present a single lesion, and the head and neck region is the most commonly affected [9].

The treatment plan established for hemangiomas must consider aspects such as size, location, length and lesion hemodynamics, patient's age and viability of the technique to be used [10]. Systemic corticosteroid therapy is considered as the most efficient for treating common cutaneous infantile hemangiomas if initiated early in the proliferative phase. Oral prednisone has been used to treat hemangiomas of infancy for 30 years and remains the first-line therapy for difficult hemangiomas. The dosage commonly used is 3 - 5 mg/kg per day of oral prednisone between the 1<sup>st</sup> and 30<sup>th</sup> months. The main side-effects of high dose therapy in long-term systemic corticosteroids are cushingoid features, influence on growth, and susceptibility to serious infections, appetite changes, behavior changes, polyuria, thrush, and gastrointestinal discomfort [11].

In the absence of response to the systemic treatment, surgery is indicated for small lesions and for esthetic corrections. It must be preceded by sclerotherapy because endothelial cell fibrosis facilitates lesion removal, thus avoiding hemorrhage risk [12,13], justifying the treatment protocol used in the present clinical case. The association of sclerotherapy and surgery are the most used techniques for the treatment of oral hemangiomas [13,14]. Among the sclerosing agents available, excellent results have been reported for sodium morrhuate, sodium sulfate tetracycl, polydocanol and ethanolamine oleate, and hypertonic glucose solution [13-15].

The patient is under a 2-year postoperative follow up showing no signs of hemangioma recurrence (Figure 5), which confirms the low recurrence rates of these lesions [16]. In this study, the size, location, and systemic conditions allowed establishing the surgical procedures with favorable prognosis and satisfactory healing of the operated area.

### Conclusion

In conclusion, surgical excision of hemangioma, non responsive to other modality is a treatment option to be considered as it provides good esthetic and functional outcome.

### Bibliography

1. Lara-Sanchez H., *et al.* "Cavernous Hemangioma of the Parotid Gland in Adults". *Journal of Clinical and Experimental Dentistry* 6.5 (2014): e592-e594.
2. Zheng J W, *et al.* "A Practical guide to treatment of infantile hemangiomas of the head and neck". *International Journal of Clinical and Experimental Medicine* 6.10 (2013): 851-860.
3. de Avila ED., *et al.* "Lip Cavernous Hemangioma in a Young Child". *Brazilian Dental Journal* 21.4 (2010): 370-374.
4. Mulliken JB and Glowacki J. "Hemangiomas and vascular malformations in infants and children: A classification based on endothelial characteristics". *Plastic and Reconstructive Surgery* 69.3 (1982): 412-422.
5. Mulliken JB and Young A. "Vascular birthmarks: hemangiomas and malformations". Philadelphia 7 WB Saunders (1988).
6. Kin HJ., *et al.* "Ulcerated hemangiomas: clinical characteristics and response to therapy". *Journal of the American Academy of Dermatology* 44.6 (2001): 962-972.

7. Bruckner AL and Frieden IJ. "Hemangiomas of infancy". *Journal of the American Academy of Dermatology* 48.4 (2003): 477-493.
8. Hamlitt A., et al. "Pathophysiology of capillary haemangioma growth after birth". *Medical Hypotheses* 64.6 (2005): 1093-1096.
9. Mulliken JB., et al. "Vascular anomalies". *Current Problems in Surgery* 37.8 (2000): 518-584.
10. Zhao Y., et al. "A human peripheral blood monocyte - derived subset acts as pluripotent stem cells". *Proceedings of the National Academy of Sciences of the United States of America* 100.5 (2003): 2426-2431.
11. Zhou Q., et al. "Short-term high-dose oral prednisone on alternate days is safe and effective for treatment of infantile hemangiomas". *Journal of Oral and Maxillofacial Surgery* 109.2 (2010): 166-167.
12. Matsumoto K., et al. "Sclerotherapy of hemangioma with late involution". *Dermatologic Surgery* 29.6 (2003): 668-671.
13. Johann ACBR., et al. "Sclerotherapy of begin oral vascular lesion with ethanolamine oleate: an open clinical trial with 30 lesions". *Oral Surgery, Oral Medicine, Oral Pathology, Oral Radiology, and Endodontology* 100.5 (2005): 579-584.
14. Marchuk DA. "Pathogenesis of hemangioma". *Journal of Clinical Investigation* 107.6 (2001): 665-666.
15. Un ZJ., et al. "Epithelioid hemangioma in the oral mucosa: a clinicopathological study of seven cases and review of the literature". *Oral Oncology* 42.5 (2006): 441-447.
16. Baumash H and Mandel L. "The nonsurgical treatment of hemangioma with sotradecol". *Oral Surgery, Oral Medicine, Oral Pathology* 16 (1963): 777-782.

**Volume 15 Issue 1 October 2017**

**© All rights reserved by Sana Hashmi and Faisal Idrees.**