

## Plasmacytoma in TMJ Region

Zajko J, Gális B, Kupcová I and Czakó L\*

*The Department of Maxillofacial Surgery, Faculty of Medicine, Comenius University and University Hospital, Bratislava, Slovakia*

**\*Corresponding Author:** Ladislav Czakó, The Department of Maxillofacial Surgery, Faculty of Medicine, Comenius University and University Hospital, Bratislava, Slovakia.

**Received:** July 13, 2017; **Published:** August 17, 2017

### Abstract

Plasmacytoma is a rare malignant disease based of differentiated plasmatic B cells, which occurs also in the head and neck region. It rarely involves the mandible. The authors present an unusual evaluation of this pathology through a clinical case of a 45-year-old patient diagnosed with solitary plasmacytoma in the temporomandibular joint (TMJ) region. The solitary tumor was located in the area between the muscular and articular process of the left side of the mandible. Resection of the tumour and articular process was performed under general anesthesia. Histopathology revealed sheets of plasma cells with cartwheel appearance and expansive bone trabecula – plasmacytoma of the mandible. Complementary treatment was performed by four cycles of systemic chemotherapy. The tumor recurrence was diagnosed after three year during control MRI examination. The patient underwent autologous cell transplantation from his brother without any surgical treatment. In the three-year follow up the patient didn't show local progression of the tumour. The oncologist did not recommend another surgery. Five-year post operation and chemotherapy patient died for gastrointestinal complication.

**Keywords:** *Plasmacytoma; Solitary Extramedullary Plasmacytoma; Multiple Myeloma; Temporomandibular Joint*

### Introduction

Solitary plasmacytoma is a rare malignant tumor, characterized by neoplastic proliferation of differentiated B-cells. This is a rare form of malignant tumor and is characterized by neoplastic proliferation of differentiated B lymphocytes. Local proliferation is rare. Disease tend to affect mainly the bone marrow cells of vertebrae, ribs, sternum and skull bones [1,3]. More than 90% of extramedullary plasmacytomas occur in the head, neck, and upper respiratory tract and affected tissues include the nasal cavity, sinuses, oropharynx, salivary glands, and larynx [6]. The etiology of this disease remains unknown, but chronic stimulation, overdose of radiation, viruses, and gene interactions in the reticuloendothelial system have been suggested as etiological factors [7].

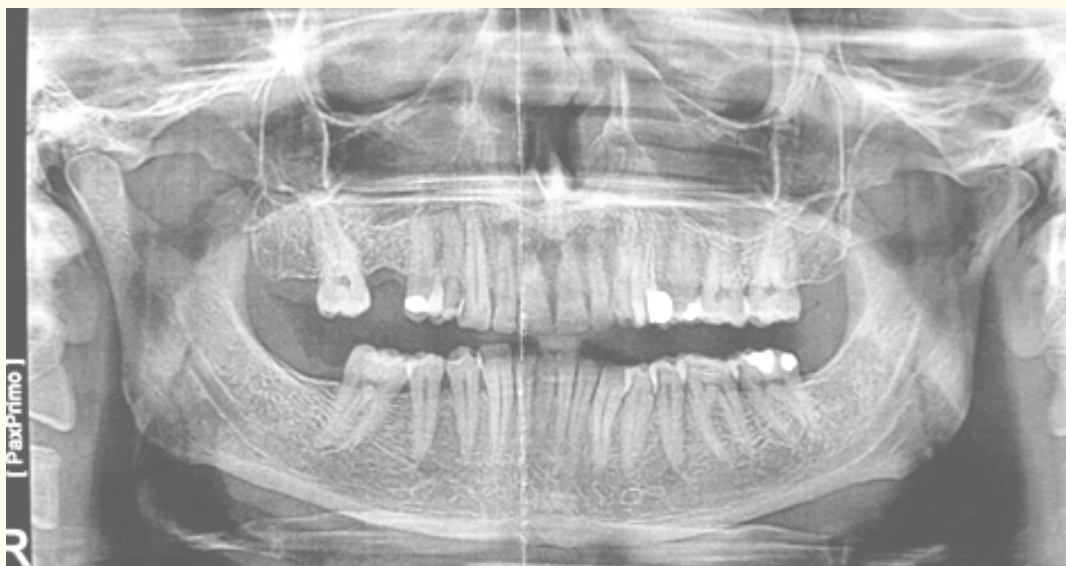Plasmacytomas are divided into three types: solitary plasmacytoma of bone (SPB), extramedullary plasmacytoma (EMP) and disseminated form also called as multiple myeloma (MM). When examination detects more plasma cells regions, disorder is reclassified as multiple myeloma (MM). Tumour cells my appear in vertebrae, ribs, sternum and skull bones. The extramedullary form is locally expansive and has little tendency to generalization of the condition [4,14]. The bone form is more frequent. It is always a question, whether it is a form of solitary plasmacytoma, or imperfectly recognized form of multiple myeloma. It is always important to determine, which form it is, because each form requires different approach for treatment. Risk factors are contact with pesticides, dioxins, organic solvents, immunodeficient condition congenital or acquired, or HIV infection.

The incidence of MM is estimated 3-4 cases per 100 thousand inhabitants. It is a disease of middle and older age with diverse clinical course. In general, the cause is unknown, but 90% of patients exhibit genetic mutations of certain genes. Age over 60 years may be a risk factor for this illness. Male – female ratio is 3 : 1. In 3% of the population the disorder occurs under 40 years of age. Literature data confirm the occurrence in 5<sup>th</sup>-6<sup>th</sup> decade [3,11]. Overall, the incidence is 0.4 to 1 million inhabitants per year. In the USA, myeloma occurs in approximately 75 - 100,000 people. According to the latest statistics are diagnosed each year more than 20 000 new cases. The tumor affects 3 - 4 people per 100 000 population per year in Slovakia [3,12].

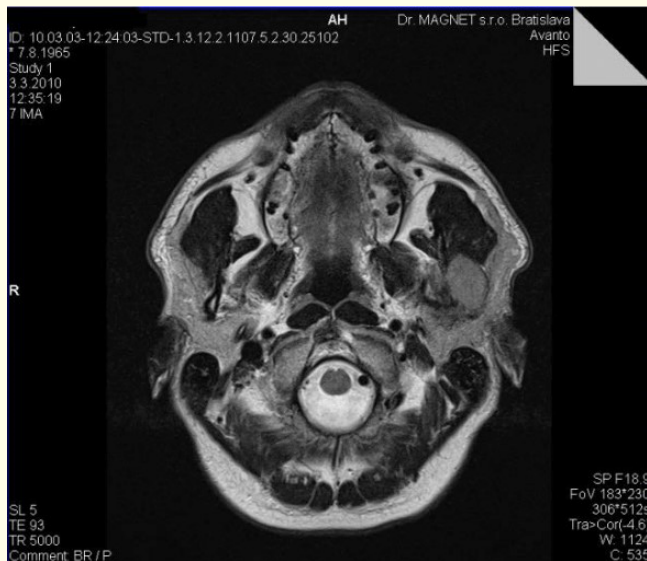
The basic diagnostic features of solitary plasmacytoma manifested on X-ray confirmed the presence of only one lytic lesion. Plasmacytoma must be histologically documented from the pathological focus. The level of lymphocytes may be normal and the number of plasma cells is less than 5%. Normal may be also the concentrations of the hemoglobin, count of erythrocytes, calcium level and also renal function. Also low is concentration of monoclonal IgA. Bence - Jones protein is less than 1g/24h [9,10]. When other foci of the disease are present, then we do not speak about solitary plasmacytoma, but the disease must be treated as multiple myeloma (MM). Clinical signs in MM are determined mainly by the accumulation of myeloma cells and the presence of paraprotein [2]. A common symptom is bone pain at the site of bone lesions. Another symptom is anemia, which is manifested by fatigue or impaired tolerance to physical stress. Repeated infections are manifestation of immunodeficiency [5,8].

### Case Report

A 45-year-old patient presented with a problem in eating food. He had a feeling of sudden rupture when eating. Since then he had impaired mouth opening. In patients, personal history was longer duration of fatigue. The extra oral examination with palpation was negative. The intraoral mucous membrane was pink; mouth opening slightly limited to 2.9 cm. Panoramic X-ray revealed translucent area around the mandibular condyle on the left side (Figure 1). Subsequently we performed MRI. MRI confirmed a solid expansion based on the structures of the mandibular head and neck, dimensions in scan, size 29x 28 x 27 mm (Figure 2). Due to persistence of problems the diagnosis was defined as a tumor in TMJ on left side. Operation was indicated.

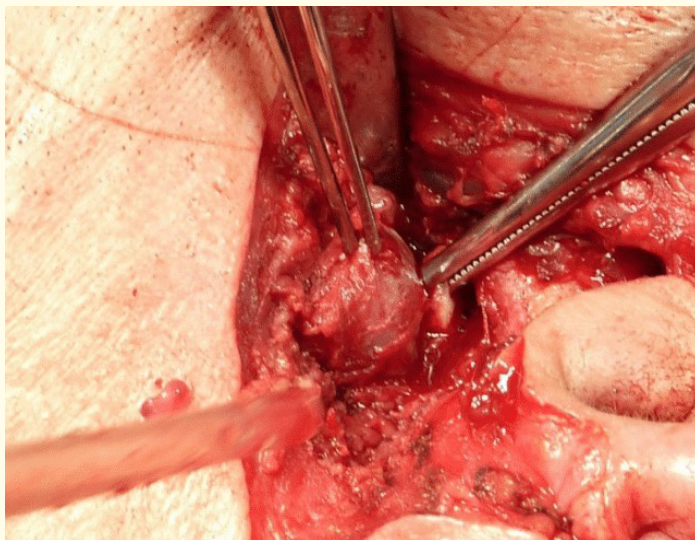


**Figure 1:** Panoramic view with translucency in the mandible in left site.



**Figure 2:** Panoramic view with translucency in the mandible in left site.

By operation was removed the tumorous tissue of mandibular incisure and following the head of mandible was removed (Figure 3). Postoperative course was uneventful. The result of histological examination confirmed a tumor composed of mature plasma cells. Immunophenotype examination confirmed presence of factors CD20-, CD138+, CD45 CD56-, CD38+, Ka, La+. Perichondrium and compact bone was infiltrated by mature plasmacytoma. Histological conclusion - plasmacytoma of the mandible. Value of La+, CD56 negativity confirmed the origin of the solitary intramedullary tumor.



**Figure 3:** Perioperative view.

The wound healed primarily. Opening of the mouth was significantly improved with mild deviation to the left. Oncological examination followed. Control whole-body CT covering the areas of C, TH, LS spine, was performed, which demonstrated lytic lesion in alla ossis sacri on the left side. The finding in the Th spine was described osteoporosis. Biochemical examination - slightly elevated ALT 0.73, lymphocytes 48.8, 12.7 Eo, Neutrophils -38.5. Urine was negative. Control biochemical values of IgA were stable. Based on the lytic lesions in the skeleton, the condition was reclassified as multiple myeloma IgA lambda, stage IIIA classification ISS 1.

In November 2010, the patient underwent four cycles of chemotherapy. When he came to regular controls, his condition was better. MRI control in 2012 confirmed relapse of the process. Conclusion of MRI: The recurrence of the tumour process in the resected condyle on the left side which the examination did not demonstrate (Figure 4). Therefore, in February 2013 was made mini allogenic bone marrow transplantation of plasma cells from his brother.

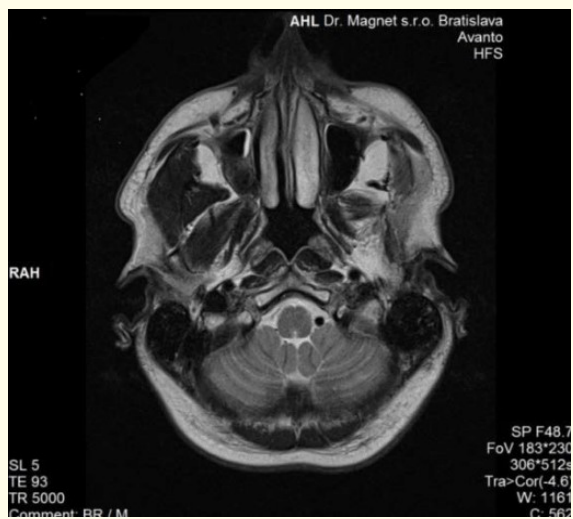


Figure 4: Control MRI in 2012.

After this procedure, the patient felt well. On the checkup examination after half a year palpation again confirmed in the angle of the mandible limited a resistance size 2x2 cm. Control MRI in September 2013 confirmed recurrence of the primary pathological expansion on the left size 31x 30 x 38 mm sharply contoured by surrounding structures (Figure 5). Patient’s condition was paradoxically reactivated after the application of plasma cells. Reoperation was recommended by maxillofacial surgeons; the oncologist did not support this opinion and recommended monitoring of the patient with supportive oncological care.

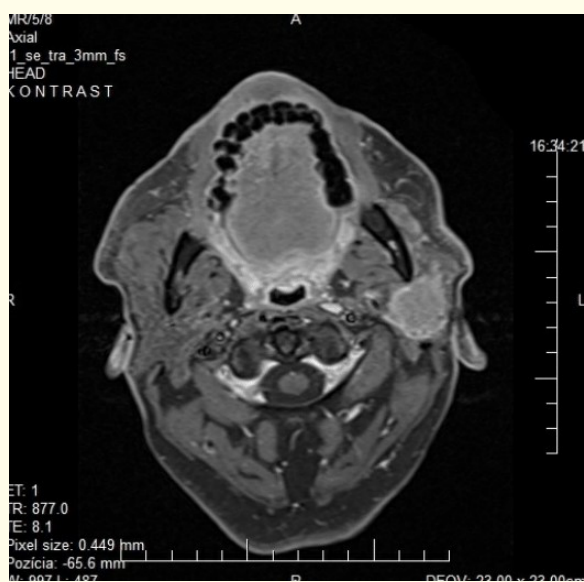
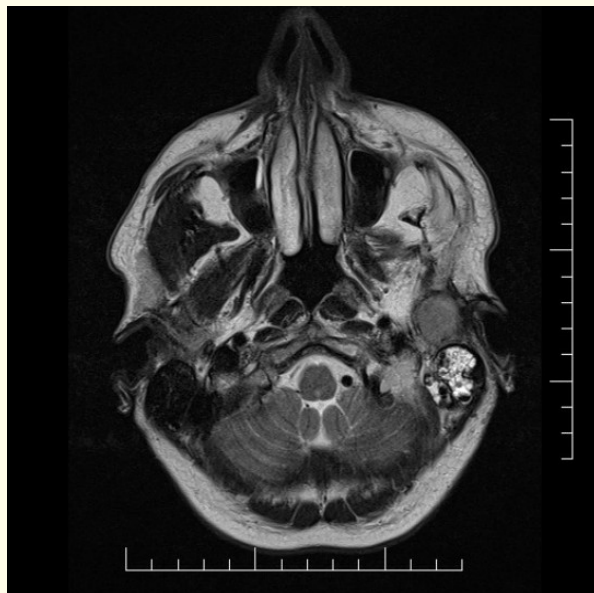
Figure 5: Control MRI in 2013.

On further inspection after 8 months the patient again felt quite well. On palpation, the pathological process was reduced. Further checkup MRI in March of 2014 confirmed a significant tumour in the left TMJ region. Sharp outer contour remained without infiltration of surrounding structures. Central necrosis absented. In post-contrast opacification, the tumorous expansion was homogeneous (Figure 6). After five years during the chemotherapy treatment the patient died for gastrointestinal complication.



**Figure 6:** Control MRI in 2014.

## Discussion

Plasma cells are an important part of the immune defense system. Their main task is the production of immunoglobulins. Therefore, even a tumor of plasma cells also produces immunoglobulins called paraproteins [2]. They are worthless for the defense system [6]. Plasmacytoma is an oncological condition based on the bone marrow, characterized by neoplastic proliferation of differentiated B cells [3,13,14]. They tend to particularly affect the marrow cells of vertebrae, ribs, breast bone and skull bones.

The first symptom of the disease may be very poor. The disease may present with frequent infections, poorly healing wounds, general feeling of weakness and fatigue. Often is added headache, chest pain, pain of ribs and spine. In control laboratory blood tests and biochemical tests there are usually high values of FW and high levels of blood proteins and immunoglobulins. It is important to make X-ray examination of the skeleton, which can detect translucency of the skeleton or pathologic fracture. Bone scintigraphy and ultrasonography of parenchymatous organs, particularly the spleen and kidneys can be made. On examination of urine are detected high levels of protein.

## Conclusion

The patient died five years after surgery and oncological treatment using transplantation of bone marrow cells from his brother. The plasmacytoma of the articular process of the mandible had to be reclassified as multiple myeloma IgA lambda, stage IIIA classification ISS. The chemotherapy treatment was made in scheme VAD - Vincristine, Adriamycin, Doxorubicin and oncological support treatment with Dexamethazon and bisphosphonates. Control laboratory values were normal. Patient was in regular and long-term care dispensary.



Two years after surgery the patient was free of recurrence. But after mini transplantation of bone marrow, relapse appeared again on the left side. Unlike in literary source [6], when the process after histology disappeared, in our case report appeared relapse after administration of bone marrow cells of his brother. After 6 months, recurrence of the tumour started again. According to the oncologists, the process should have been stabilized and slowly eliminated. The patient was then under strict observation, and we were waiting for opinion of oncologists, when the operation would have been possible. The mechanism of spontaneous regression is not fully understood. It may be mediated through immune response, tumor inhibition growth factors, cytokinesis and inhibition of angiogenesis and apoptosis [12,13]. Regeneration can follow as a non-specific mechanism, such as biopsy or incomplete excision. Optionally it is associated with local infection, autoimmune disease, transfusion reaction, or pregnancy [3,10]. The hypothesis is supported by the fact that bacterial and viral infection stimulates the immune system, which includes regression through humoral and cellular mechanisms. This increases the activity of natural killer cells, which can lead to spontaneous regression, what happened in a patient described in literature [6], after removal of nasosinus plasmacytoma. This disease despite of advances in treatment still has poor prognosis.

### Bibliography

1. Adam Z and Maisnar V. "Mnohočetný myelóm" 73 (2008).
2. Ambler Z. "Neurologické projevy mnočetného myelomu". *Neurologia pre prax* 5 (2008): 283-285.
3. Ballová V. "Mnohopočetný myelóm - diagnostika a liečba pre praktického lekára". *Via Practica* 4.7-8 (2007): 338-341.
4. Durie B., et al. "Myeloma management guidelines. A consensus report from the scientific advisor of the international Myeloma Foundation". *Journal of Hematology* 4.6 (2003): 379-398.
5. Chao M., et al. "Radiotherapy in the management of solitary extramedullary plasmacytoma". *Journal of Internal Medicine* 35.4 (2005): 211-215.
6. Mezin M., et al. "Solitary plasmacytoma: ghost tumor?". *International Journal of Oral and Maxillofacial Surgery* 41 (2012): 17-19.
7. Seema Dengra., et al. "Oral manifestation of multiple myeloma as plasmacytoma: A case report". *Journal of Oral and Maxillofacial Surgery, Medicine, and Pathology* 26.3 (2014): 421-423.
8. Sevinc Kenan., et al. "PP035: Various manifestations of multiple myeloma in the maxillofacial region: Case reports". *Oral Oncology* 49 (2013): S105.
9. Strojjan P., et al. "Extramedullary plasmacytoma: clinical and histopathologic study". *International Journal of Radiation Oncology \* Biology \* Physics* 53.3 (2002): 692-701.
10. Straub J., et al. "Mnohočetný myelom - časná diagnostika". *Medicína pro praxi* 6.4 (2009): 197-199.
11. Radocha J and Maisnar V. "Solitárny kostný plazmocytoom-kazuistika". *Klinická biochemie a metabolismus* 15.36 (2007): 89-90.
12. Tothová E. "Možnosti liečby mnohopočetného myelómu". *Onkologie* 1.1 (2007): 14-17.
13. Vošmik M and Maisnar V. "Solitárny extramedulárny plazmocytoom-diagnostika a liečba". *Klinická biochemie a metabolismus* 15.36 (2007): 82-84.
14. Weber DM. "Solitary bone and extramedullary plasmacytoma". *Hematology American Society of Hematology Education Program* (2005): 373-376.

Volume 13 Issue 3 August 2017

© All rights reserved by Zajko Juraj., et al.