

Clinical Management of the Impacted Maxillary Canines. Review and Report of Cases

George Litsas*

Private Practice in Orthodontics, Venizelou, Kozani, Greece

***Corresponding Author:** George Litsas, Private Practice in Orthodontics, Venizelou, Kozani, Greece.

Received: June 14, 2017; **Published:** July 14, 2017

Abstract

Maxillary canines are well recognized as very important teeth regarding their contribution to arch form to establish a functional occlusion and to create an esthetical smile. The orthodontic treatment of impacted maxillary canine remains a challenge to today's clinicians. Their impaction is a frequently encountered clinical problem the treatment of which usually requires surgical exposure followed by orthodontic traction to guide and align it into the dental arch. This paper reviews the literature relating to radiographic diagnosis, surgical exposure and orthodontic management of the maxillary impacted canines.

Keywords: *Maxillary Canine Impaction; Diagnosis; Treatment*

Introduction

Maxillary canine is one of the most frequently impacted teeth, more common in girls than in the boys, with the prevalence ranging from 0.8 to 5.2 per cent [1-4]. The ratio of palatal to buccal impaction is 8 to 1 [5]. Buccal canine impaction is thought to be a form of crowding [6] while the genetic theory [7] and the guidance theory [8] have been proposed to explain the aetiology of palatal canine impaction. The impacted canine can cause migration of the neighbouring teeth, loss of arch length, cystic lesions as well as root resorption of the nearby lateral incisors, jeopardizing their longevity [9]. Palatal canine impaction should be discriminated from "palatal canine displacement" in mixed dentition that defined [10] as the 'developmental dislocation to a palatal site often resulting in tooth impaction requiring surgical and orthodontic treatment'.

Clinical Diagnosis

Radiographic Considerations

The clinical prognosis of impacted canine can be assessed accurately only when the exact position of the tooth is known. Several radiographic methods have been suggested to evaluate the position of the impacted maxillary canines [11,12]. The parallax (horizontal or vertical) technique is the most commonly used method in localized impacted maxillary canines. This technique requires two intra-oral films for horizontal parallax or one intra-oral (anterior occlusal) and the panoramic radiograph for vertical parallax method [13]. Single panoramic radiograph could be used also to determine the buccal-lingual position of the impacted teeth based on the degree of magnification of the canine relative to adjacent teeth or the contralateral side [14]. However, magnification method is difficult to apply because panoramic radiography has some inherent limitations regarding the distance of the impacted teeth from the radiation source on the vertical level [15].

Three variables visible on panoramic radiographs (Figure 1) have been proposed: i) angle measured between the long axis of the impacted canine and the midline, ii) distance between the canine cusp tip and the occlusal plane (from the first molar to the incisal edge of the central incisor) and iii) the sector where the cusp of the impacted canine is located. Stewart., *et al.* [16] stated that if the distance of the impacted canine is less than 14 mm from the occlusal plane, the treatment length is about 23.8 months; if it is more than 14 mm from the occlusal plane, treatment duration averaged 31.1 months. Zuccati., *et al.* [17] reported that the treatment time was proportional to the d-distance and the sector (s). According to them when the canines cusp located mesially to the long axis of the lateral incisor 10 more visits required than the distally located canines. Crescini., *et al.* [18] found that for every 5 degrees of the α -angle opening and 1 mm increase of d-distance, 1 more week of active orthodontic traction was required. Regarding the sector of impaction, when the impacted canine belongs in sector 1, six more weeks of active orthodontic traction was required comparing to impaction in sector 3. However, these variables could not be considered as prognostic factors of the final periodontal status of repositioned impacted canines.

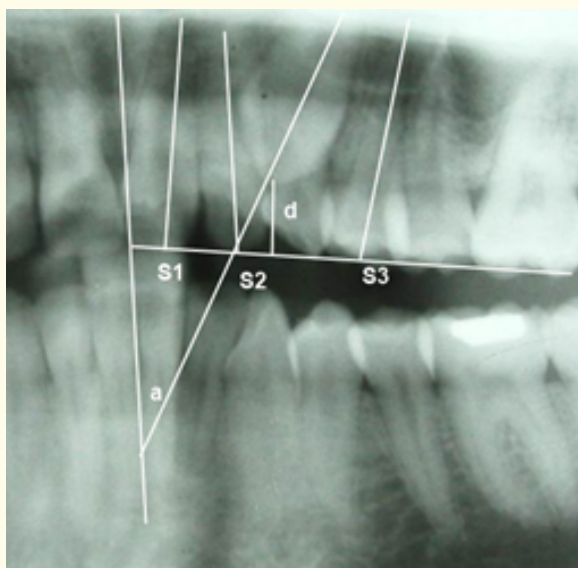


Figure 1: a: Angulation, d: Distance, s: Sector of impaction.

CBCT imaging has recently been explored for orthodontic applications, including visualization of impacted teeth. CBCT provides elements for the impacted teeth such as the size of follicle, the amount of the bone covering the tooth, 3D proximity of adjacent teeth, much better than panoramic radiographs [19]. Haney., *et al.* [20] comparing the traditional 2D images to cone-beam computed tomography in patients with maxillary impacted canines, found a 21% disagreement in the mesio-distal location and 16% in the labial-palatal position of the impaction producing different treatment plans for the same patient. However, the authors did not estimate the accuracy of either radiographic method. On the same line, Alqerban., *et al.* [21] and Boticcelli., *et al.* [22] found that 3D images increase the precision in the localization of the canines improving the diagnosis and the treatment planning. One the other hand, when panoramic radiograph and CBCT were compared in order to describe the position of the maxillary impacted canines, the labiopalatal position of impacted canines could be predicted accurately using sector location on panoramic radiography [23].

In CBCT, even if the effective radiation dose is reduced by 98% compared with conventional CT systems, it remains 4 to 15 times greater than that of a single panoramic radiograph [24]. However, the clinician should be considering the increased cost, radiation exposure

and medico-legal issues associated with routine use of CBCT. As Kokich [25] stated “will the benefit that I gain from this scan outweigh the potential risk to the patient? The responsibility is ours”.

Periodontic considerations

Final periodontal health is a fundamental key to evaluate the success of therapy for impacted maxillary canines. Orthodontic correction of impacted canines influences the adjacent teeth, which are exposed to heavy intrusive and lingual torque forces during extrusion, distal movement, and alignment of the impacted canine. Bone and attachment loss at the distolingual region of the lateral incisor and at the distobuccal region of the premolar area have been reported [26]. Three most commonly used surgical methods for exposing the palatal impacted maxillary canines are:

- i) The open surgical exposure and spontaneous eruption. This method is most useful when the impacted canine has a correct axial inclination [27].
- ii) The open surgical technique with subsequent bonding of an auxiliary orthodontic attachment. The advantages of this method are the faster eruption as well as the continuing access to the impacted teeth during the eruption process while bone loss, gingival recession and decreased width of keratinized tissue have been reported as the main disadvantages [28].
- iii) The closed surgical technique. In this technique, a mucoperiosteal flap is reflected, the bone covering the crown of the impacted teeth is removed, an attachment is bonded and the flap is repositioned and sutured. Many authors supported that the closed surgical technique is superior to the other techniques because the tooth is exposed with minimum tissue removal, rapid healing and immediate orthodontic traction [29,30]. However, an increase in pocket depth at the distobuccal surface of the impacted canines and at the mesiolingual, distolingual, and mesiolabial surfaces of the adjacent lateral incisors and first premolars have been reported [31]. Parkin., *et al.* [32] in a Cochrane based systematic review failed to find any high quality clinical trials to support the closed surgical over the open surgical technique.

The summary of the orthodontic treatment of two cases with impacted canines -one palatal and the other at the middle of the alveolar ridge- will be described.

Case Report

Case I

A 15-year-old healthy Caucasian girl was referred by her dentist because of dental crowding and retained primary canine in the left maxilla. She had Class I molar relationship on both sides and Class I canine relationship only on the right side. The left permanent canine was impacted while the periodontic support for the upper right first premolar was questionable. Overjet and overbite were both 4 mm (Figure 2). Panoramic and occlusal radiograph revealed a palatal impacted upper left permanent canine.

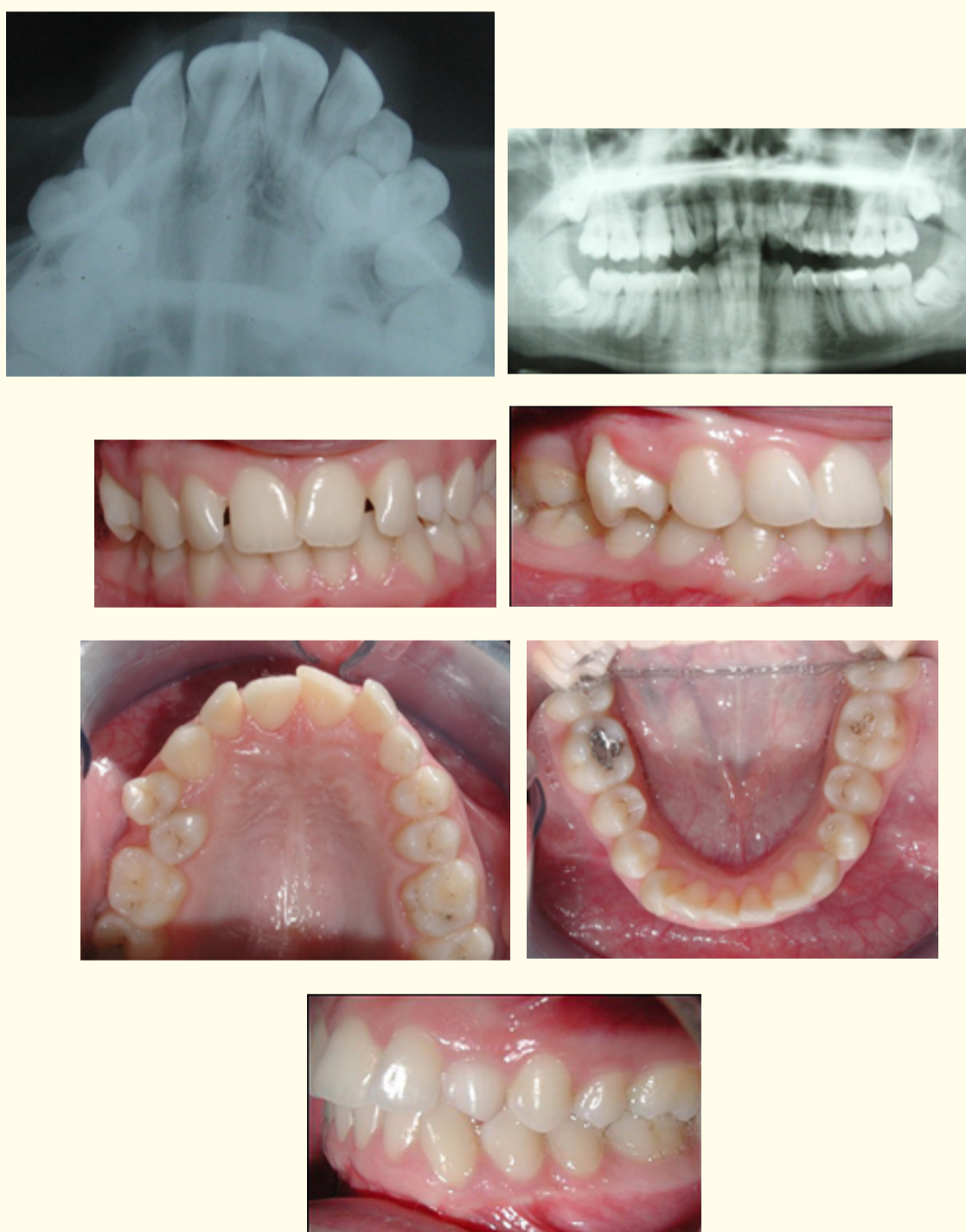

Figure 2: Intra-oral pictures, panoramic and occlusal radiograph before treatment.

The tooth size-arch length discrepancy (Hays-Nance) was -5.3 mm in the maxillary arch and -3.5 mm in the mandibular arch. Bolton analysis revealed 1.6 mm maxillary excess for 12 teeth and 1.3 mm maxillary excess for 6 teeth. Non-extraction orthodontic treatment was decided in order to relieve the crowding to bring the canine into the arch, to achieve class I molar and canine relationship, proper overjet-overbite as well as to improve her function and esthetics.

Treatment

- 1) The orthodontic treatment was performed using 0.018 × 0.025-inch preadjusted multibracket appliances. Removable Cetlin type TPA was inserted to i) derotate the upper left permanent molar ii) to support the anchorage during alignment and leveling (0.0175-inch multi-stranded wire, 0.016-inch NiTi and 0.016 × 0.022-inch NiTi archwire) and iii) to increase the anchorage during the traction of the impacted tooth.
- 2) A full-thickness flap was elevated exposing the crown of the impacted canine. The bone covering the crown was removed and an eyelet attachment on steel mesh, threaded with 0.011" soft ligature wire was bonded in the mid-buccal surface and the flap was repositioned [19]. A small eyelet is recommended as the initial attachment because is soft, small and easy to contour, making its adaptation to the bonding surface more accurate. It is important also to place the eyelet on the mid-buccal surface of the crown in order to avoid any rotation during the orthodontic traction. The orthodontic traction was divided into two distinct stages. In the first stage, a segmental modified ballista spring constructed of 0.014 S.S round wire with vertical direction was applied to erupt the canine into the palate. Once the canine erupted into the palate the eyelet was substituted by 0.018 × 0.025-inch bracket attachment and the second stage of orthodontic traction was commenced, with the "piggy-back" mechanics forced to the buccal direction while a 0.017 x 0.025 S.S. base archwire and the TPA appliance served as anchorage (Figure 3).

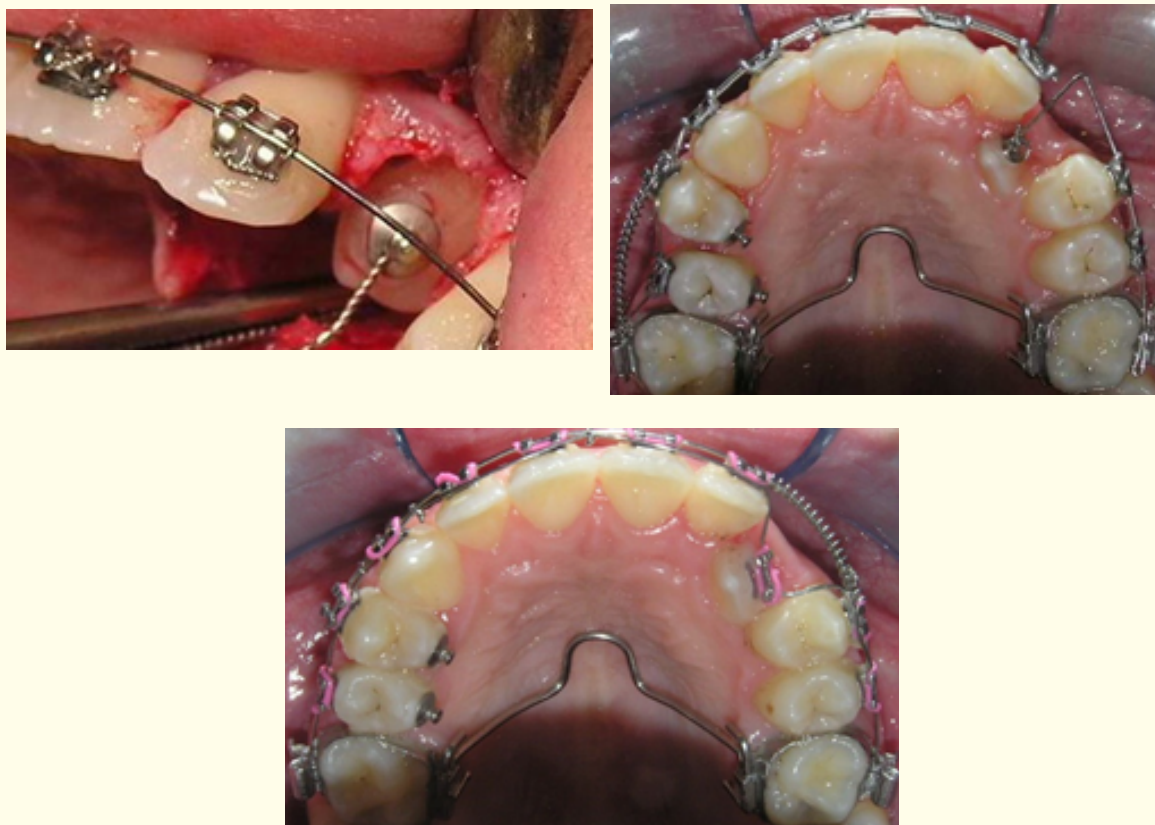


Figure 3: Surgical exposure and orthodontic traction of the canine.

- 3) The final 0.016 × 0.022–inch TMA and 0.017 × 0.025 S.S. archwires were placed to adjust the root torque. An excessive buccal root torque for overcorrection was applied on the upper left canine to prevent relapse. None periodontal defects were reported. The total treatment time for this patient was 26 months. The lower third molars will be extracted because of their unfavorable position (Figure 4).

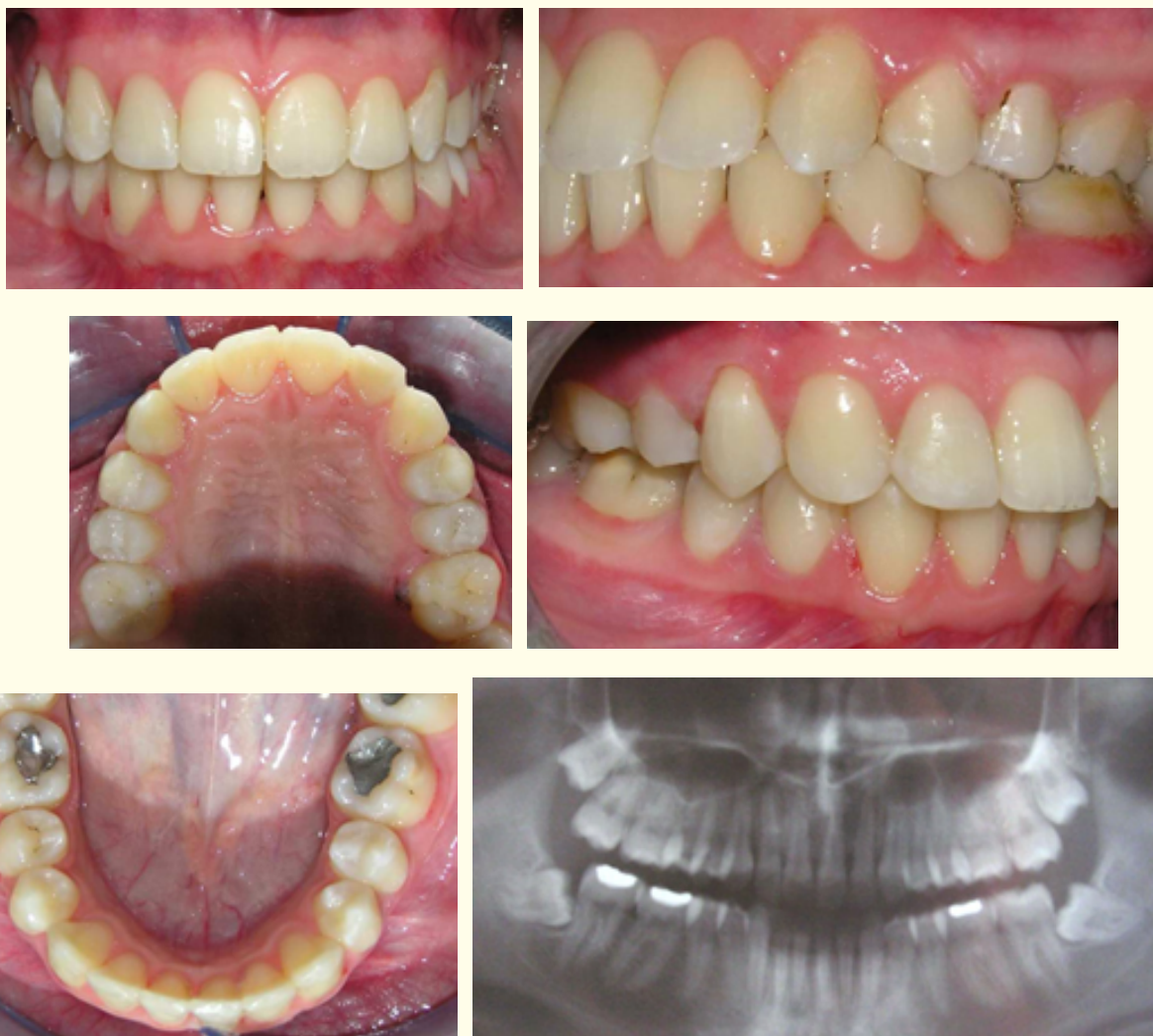

Figure 4: Intra-oral pictures and panoramic radiograph after the treatment.

Case II

A girl, aged 14 years, came for treatment because of her “missing tooth”. There was Class I molar relationship on left side but Class II on the right side. The upper right canine was unerupted, overjet was 3 mm, and overbite 4 mm (Figure 5). Panoramic and occlusal radiograph revealed an impacted, rotated upper left permanent canine at the middle of the bone. The tooth size-arch length discrepancy

(Hays-Nance) was -4 mm in the maxillary arch and -2.5 mm in the mandibular arch. Bolton analysis revealed 1.9 mm mandibular excess for 12 teeth and 0.8 mm mandibular excess for 6 teeth.

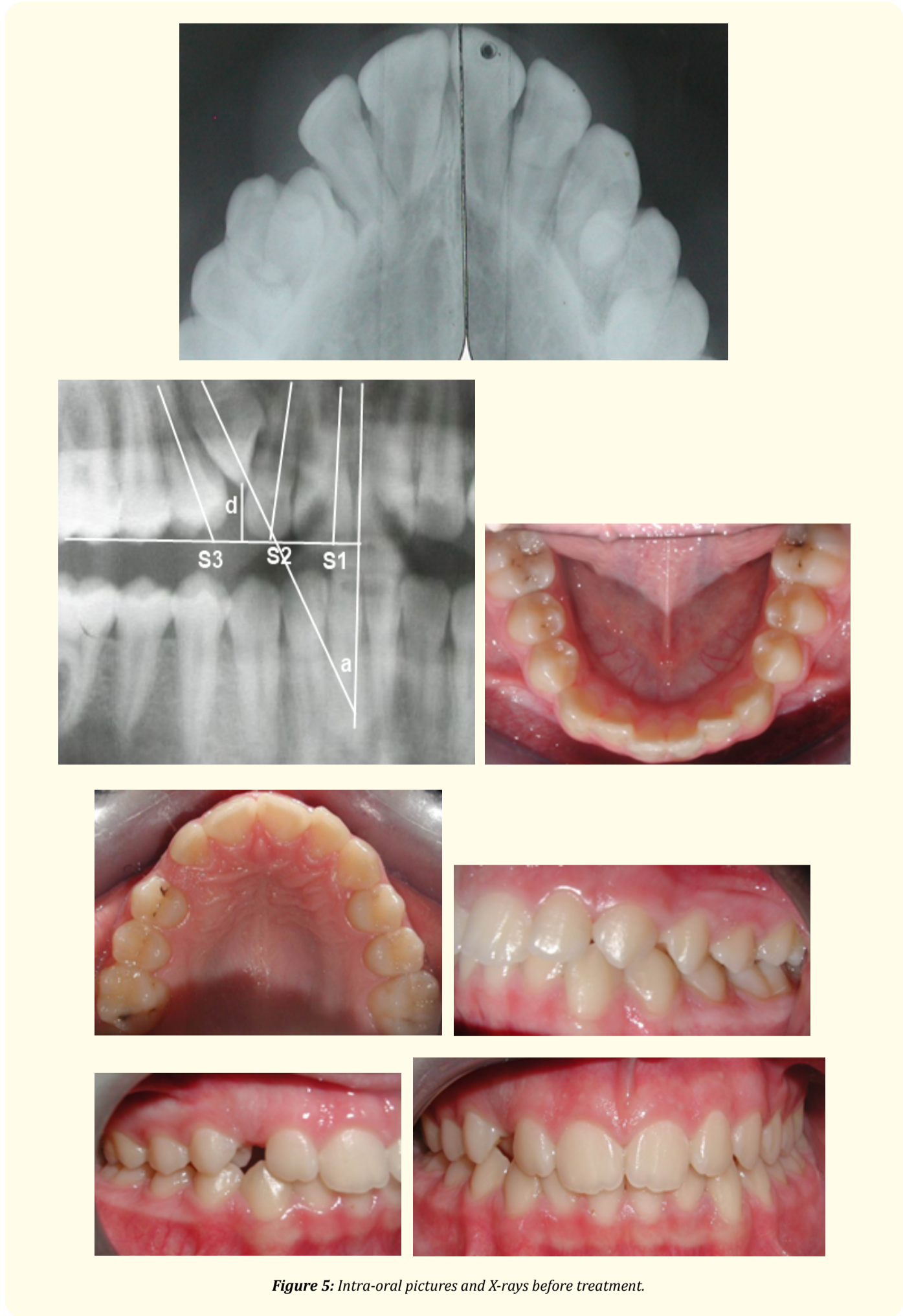


Figure 5: Intra-oral pictures and X-rays before treatment.

Non-extraction orthodontic treatment was decided in order to correct the unilateral Class II molar relationship creating space for the unerupted canine, to achieve Class I relationship, proper overjet and overbite improving her function and esthetics.

Treatment

- 1) The orthodontic treatment was performed using 0.018 × 0.025–inch preadjusted multibracket appliances. The alignment and leveling was achieved in both arches with a wire sequence of 0.0175-inch multi-stranded wire, 0.016-inch NiTi and 0.016 × 0.022–inch NiTi archwire. A unilateral molar distalization appliance (Hyrax, Leone Co) was inserted in the upper arch in order to create an adequate space for the canine to erupt. A Nance holding arch was used as stabilization appliance (Figure 6).

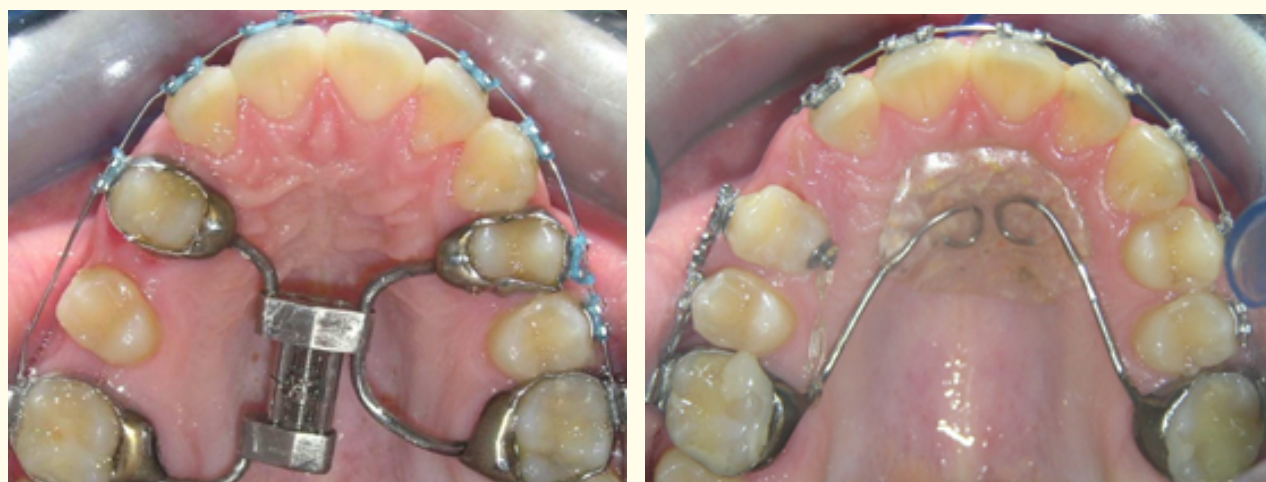

Figure 6: Distalization procedures.

- 2) The canine started to erupt spontaneously without any surgical intervention and “piggy-back” mechanics were used to bring it in the normal position while a Connecticut intrusion arch (0.017 x 0.025 CNA) was inserted to intrude the lower anterior teeth. The size of upper and lower archwires was increased till the finishing 17 x 25 S.S. size. Class I molar and canine relationship as well as proper overjet and overbite was established (Figure 7,8). The third molars will be extracted because of their unfavorable position.

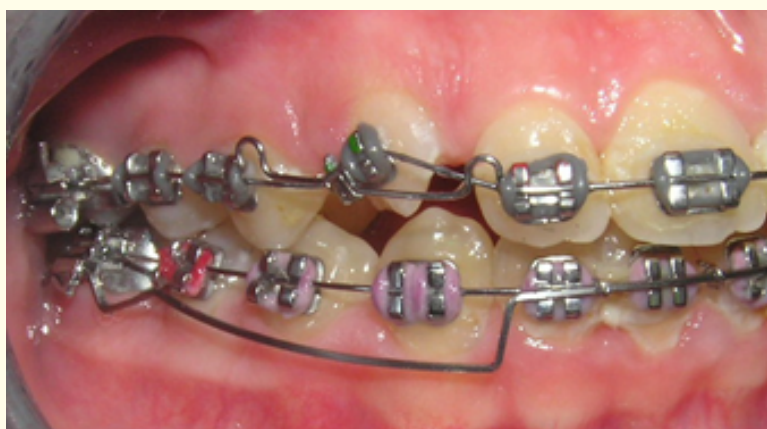

Figure 7: Eruption of the canine.

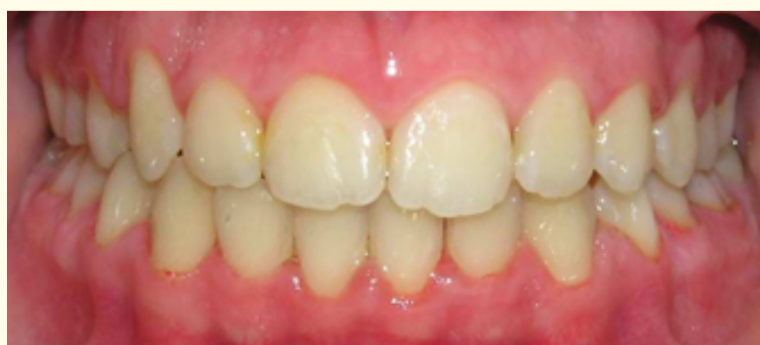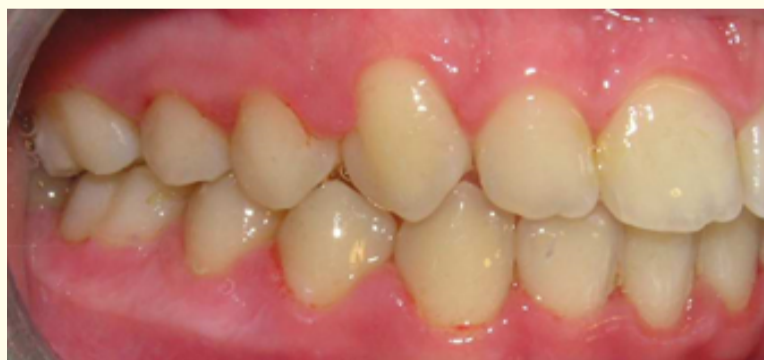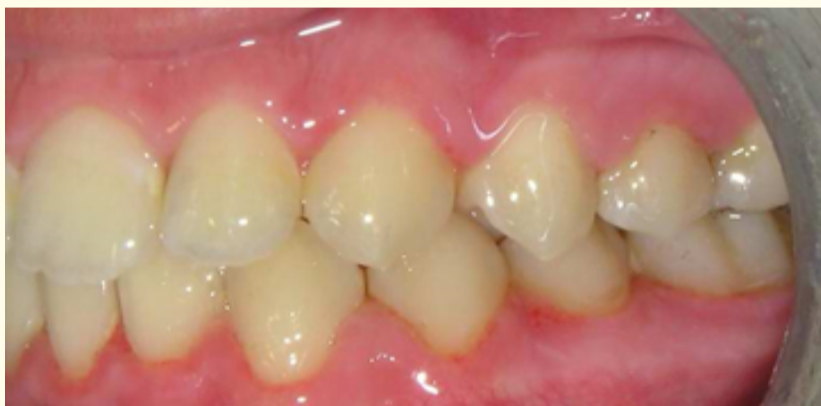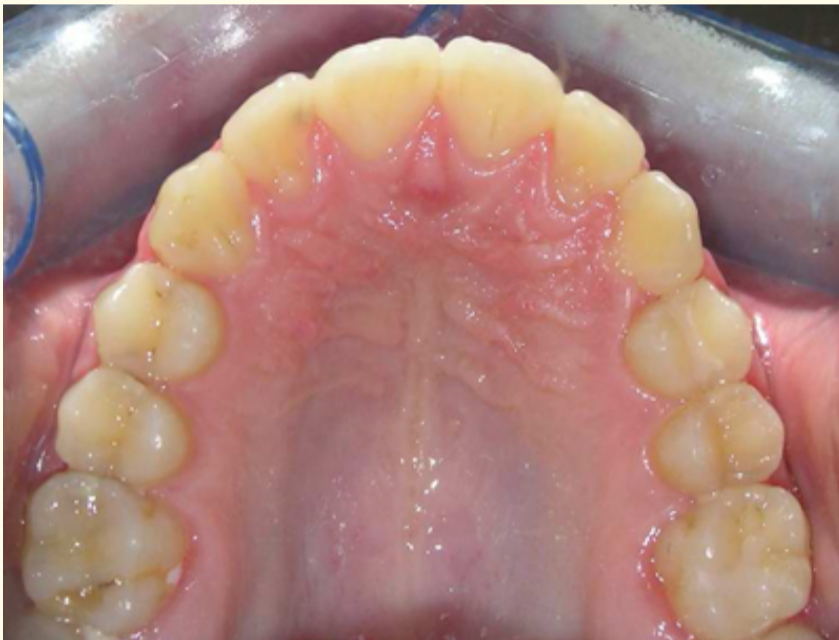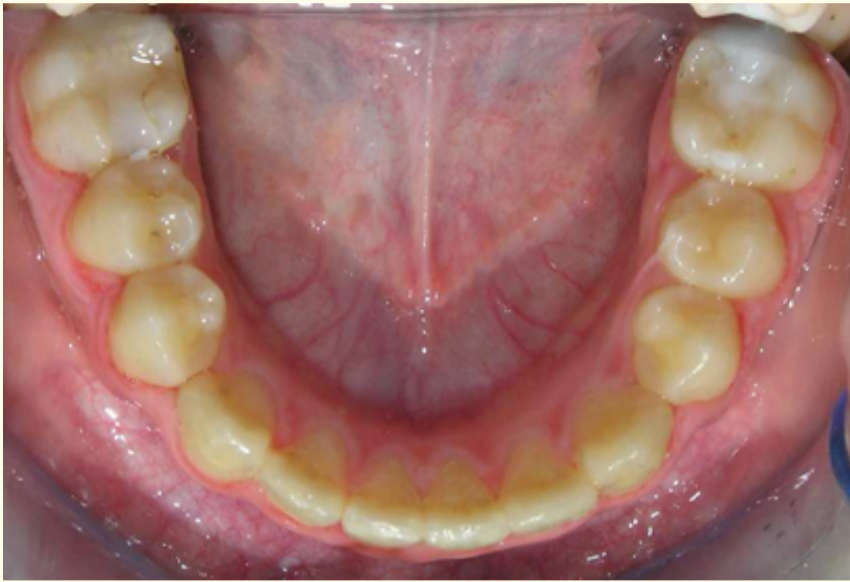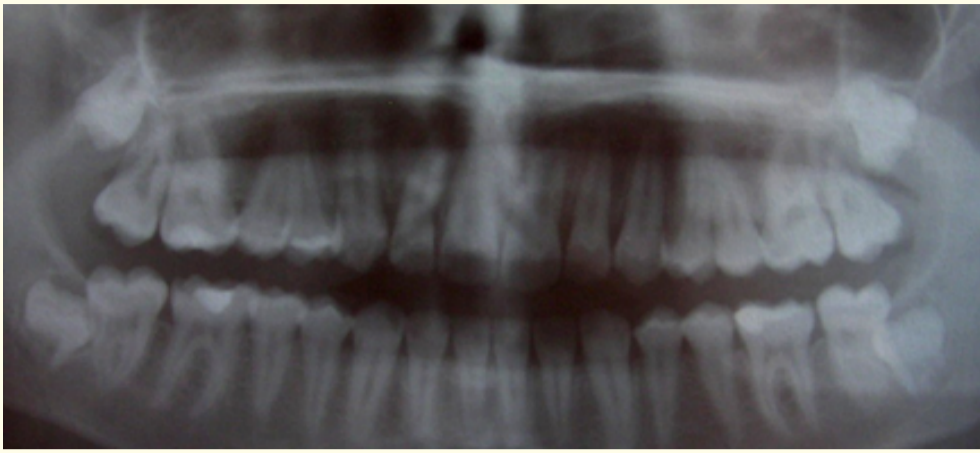


Figure 8: Intra-oral pictures and panoramic radiograph after treatment.

Discussion

Radiographic evaluation is an important requisite for the patient prior to combined surgical/orthodontic treatment of impacted teeth. The accurate diagnosis of the position will permit the clinician to make a detailed treatment plan causing the least trauma during the exposure procedure and applying the orthodontic forces in the proper direction. Two-dimensional diagnostic imaging has served dentistry well and permits us to make the proper diagnosis in the above cases. Greater angulation of the impacted teeth was related to greater distance of the cusp tip to occlusal plane and more unfavorable impaction sector. The buccal-lingual position of the impacted teeth, the orientation of the long axis, and the root apex position were defined from radiograph views taken at different angles.

A full-thickness flap was used to expose the crown of the impacted canine. This technique permits to expose only the crown of the impacted tooth avoiding any exposure and instrumentation of the root surface which can be damaging to the periodontal fibers. Beneath the bone, the dental follicle was removed to fully match the extent of minimal bone opening. The effect on the dental arches of the eruptive forces of the impacted canine should not be underestimated, particularly if they are applied for a long period of time. Becker, *et al.* [4] reported that anchorage loss was a main failure reason (48.6%) of orthodontic treatment of impacted canines. The dimensions of inserted archwires on both arches were increased giving the proper 1st, 2nd and 3rd order bends till the finishing 0.017 x 0.025 S.S archwire. Some class II elastic forces (¼, 6oz) were used night-time during the last month of her treatment.

Primary etiological cause of unerupted canine includes space deficiency. Each patient with a labial impacted canine must undergo a comprehensive evaluation of the malocclusion. The exact position of the tooth and the available space into the arch can vary widely. The orthodontic biomechanics includes distalization, expansion or even extraction protocol in order to create the necessary space for the unerupted teeth. In our case, the medium tooth size-arch length discrepancy (-4 mm), the deep bite and the favor inclination of the unerupted canine, make us to decide a unilateral distalization procedure. After finishing the molar distalization procedure, premolars were distalized as well, and, as its space was opening up, the canine started to erupt spontaneously without any surgical intervention.

Conflict of Interests

The author declares that there is no conflict of interests regarding the publication of this article.

Bibliography

1. Thilander B and Jakobsson SO. "Local factors in impaction of maxillary canines". *Acta Odontologica Scandinavica* 26.2 (1968): 145-168.
2. Brin I, *et al.* "Position of the maxillary permanent canine in relation to anomalous or missing lateral incisors: a population study". *European Journal of Orthodontics* 8.1 (1986): 12-16.
3. Baccetti T. "A controlled study of associated dental anomalies". *Angle Orthodontist* 68.3 (1998): 267-274.
4. Chu FC, *et al.* "Prevalence of impacted teeth and associated pathologies-a radiographic study of the Hong Kong Chinese population". *Hong Kong Medical Journal* 9.3 (2003): 158-163.
5. Hitchin AD. "The impacted maxillary canine". *British Dental Journal* 100 (1956): 1-14.
6. Jacoby H. "The etiology of maxillary canine impactions". *American Journal of Orthodontics and Dentofacial Orthopedics* 84.2 (1983): 125-132.
7. Peck S, *et al.* "Concomitant occurrence of canine malposition and tooth agenesis: evidence of orofacial genetic fields". *American Journal of Orthodontics and Dentofacial Orthopedics* 122.6 (2002): 657-660.

8. Becker A. "The orthodontic treatment of impacted teeth". London: Informa UK Ltd (2007).
9. Algerban A., et al. "In-vitro comparison of 2 cone-beam computed tomography systems and panoramic imaging for detecting simulated canine impaction-induced external root resorption in maxillary lateral incisors". *American Journal of Orthodontics and Dentofacial Orthopedics* 136.6 (2009): 764-765.
10. Peck S., et al. "Site-specificity of tooth maxillary agenesis in subjects with canine malpositions". *The Angle Orthodontist* 66.6 (1996): 473-476.
11. Ericson S and Kuroi J. "Radiographic examination of ectopically erupting maxillary canines". *American Journal of Orthodontics and Dentofacial Orthopedics* 91.6 (1987): 483-492.
12. Mason C., et al. "The radiographic localization of impacted maxillary canines: a comparison of methods". *European Journal of Orthodontics* 23.1 (2001): 25-34.
13. Jacobs SG. "Localization of the unerupted maxillary canine: how to and when to". *American Journal of Orthodontics and Dentofacial Orthopedics* 115.3 (1999): 314-322.
14. Fox NA., et al. "Localising maxillary canines using dental panoramic tomography". *British Dental Journal* 179.11-12 (1995): 416-420.
15. Chaushu S., et al. "The use of panoramic radiographs to localize displaced maxillary canines". *Oral Surgery, Oral Medicine, Oral Pathology, Oral Radiology, and Endodontology* 88.4 (1999): 511-516.
16. Stewart JA., et al. "Factors that relate to treatment duration for patients with palatally impacted maxillary canines". *American Journal of Orthodontics and Dentofacial Orthopedics* 119.3 (2001): 216-225.
17. Zuccati G., et al. "Factors associated with the duration of forced eruption of impacted maxillary canines. A retrospective study". *American Journal of Orthodontics and Dentofacial Orthopedics* 130.3 (2006): 349-356.
18. Crescini A., et al. "Orthodontic and periodontal outcomes of treated impacted maxillary canines". *Angle Orthodontist* 77.4 (2007): 571-577.
19. Walker L., et al. "Three-dimensional localization of maxillary canines with cone-beam computed tomography". *American Journal of Orthodontics and Dentofacial Orthopedics* 128.4 (2005): 418-423.
20. Haney E., et al. "Comparative analysis of traditional radiographs and cone-beam computed tomography volumetric images in the diagnosis and treatment planning of maxillary impacted canines". *American Journal of Orthodontics and Dentofacial Orthopedics* 137.5 (2010): 590-597.
21. Algerban A., et al. "Comparison of two cone beam computed tomographic systems versus panoramic imaging for localization of impacted maxillary canines and detection of root resorption". *European Journal of Orthodontics* 33.1 (2011): 93-102.
22. Botticelli S., et al. "Two- versus three-dimensional imaging in subjects with unerupted maxillary canines". *European Journal of Orthodontics* 33.4 (2011): 344-349.
23. Jung Y., et al. "The assessment of impacted maxillary canine position with panoramic radiography and cone beam computed tomography". *Dentomaxillofacial Radiology* 41.5 (2012): 356-360.
24. Schulze D., et al. "Radiation exposure during midfacial imaging using 4- and 16-slice computed tomography, cone beam computed tomography systems and conventional radiography". *Dentomaxillofac Radiology* 33.2 (2004): 83-86.
25. Kokich VG. "Cone-beam computed tomography: have we identified the orthodontic benefits?" *American Journal of Orthodontics and Dentofacial Orthopedics* 137.4 (2010): S16.

26. Zasciurinskiene E., *et al.* "Initial Vertical and Horizontal Position of Palatally Impacted Maxillary Canine and Effect on Periodontal Status Following Surgical-Orthodontic Treatment". *Angle Orthodontist* 78.2 (2008): 275-280.
27. Kokich V and Mathews D. "Surgical-orthodontic management of impacted teeth". *Dental Clinics of North America* 37.2 (1993): 181-204.
28. Gharaibeh TM and Al-Nimri KS. "Postoperative pain after surgical exposure of palatally impacted canines: closed-eruption versus open-eruption, a prospective randomized study". *Oral Surgery, Oral Medicine, Oral Pathology, Oral Radiology, and Endodontology* 106.3 (2008): 339-342.
29. Quiryneen M, *et al.* "Periodontal health of orthodontically extruded impacted teeth. A split-mouth, long-term clinical evaluation". *Journal of Periodontology* 71.11 (2000): 1708-1714.
30. Crescini A., *et al.* "Tunnel technique for the treatment of impacted mandibular canines". *International Journal of Periodontics and Restorative Dentistry* 29.2 (2009): 213-218.
31. D'Amico RM., *et al.* "Long-term results of orthodontic treatment of impacted maxillary canines". *Angle Orthodontist* 73.3 (2003): 231-238.
32. Parkin N., *et al.* "Open versus closed surgical exposure of canine teeth that are displaced in the roof of the mouth". *Cochrane Database Systematic Reviews* 8.4 (2008).
33. Becker A., *et al.* "Analysis of failure in the treatment of impacted maxillary canines". *American Journal of Orthodontics and Dentofacial Orthopedics* 137.6 (2010): 743-754.

Volume 12 Issue 4 July 2017

© All rights reserved by George Litsas.