

## Early Assessment of Ectopic Maxillary Canine

Ibtesam Alzain<sup>1</sup>, Waeil Batwa<sup>2\*</sup>, Afnan Kamrani<sup>3</sup> and Rawan Bawazir<sup>3</sup>

<sup>1</sup>Assistant Professor and Consultant, Department of Pediatric Dentistry, Faculty of Dentistry, King Abdulaziz University, Jeddah, Saudi Arabia

<sup>2</sup>Assistant Professor and Consultant, Department of Orthodontics, Faculty of Dentistry, King Abdulaziz University, Jeddah, Saudi Arabia

<sup>3</sup>General Dentist, Faculty of Dentistry, King Abdulaziz University, Jeddah, Saudi Arabia

**\*Corresponding Author:** Waeil Batwa, Assistant Professor and Consultant, Department of Orthodontics, Faculty of Dentistry, King Abdulaziz University, Jeddah, Saudi Arabia.

**Received:** April 26, 2017; **Published:** May 22, 2017

### Abstract

**Objective:** The aim of the present study was to evaluate (1) the significance of orthopantomograms (OPG) in the diagnosis of ectopic maxillary canine at an earlier age, and (2) dental students' ability to identify ectopic maxillary canines on an OPG.

**Methods:** We reviewed the records of all patients aged between 8 and 13 years who had attended our pediatric dentistry clinic between September 2013 and September 2014. In total, we obtained 581 digital OPGs and progress notes; these were examined for the presence of ectopic maxillary canines, as well as for documentation of the ectopic position. The following criteria were used to assess the developing canine: (1) extent to which the canine horizontally overlapped the adjacent lateral incisor root; (2) angulation towards the midline; (3) horizontal position above the premolar.

**Results:** The prevalence of ectopic maxillary canines was 9.5% (55 patients). Five patients were diagnosed at the age of 8 - 9 years. Thirty-seven (67.3%) patients with ectopic canine had gone undiagnosed; of these, 23 were treated by undergraduates, while 14 were treated by postgraduate pediatric dentistry students. The results were not significantly different between the two students' groups ( $P = 0.63$ ).

**Conclusion:** The orthopantomograms was useful in the early identification of ectopic canines at the age of 8 years. Postgraduate pediatric dentistry students are no better than undergraduates are when it comes to assessing ectopic canines.

**Keywords:** Ectopic; Canine; Interceptive; Extraction; Orthopantomograms

### Introduction

The presence of permanent canines in the dental arch plays a major role in smile esthetics and functional occlusion. Despite this, it remains a challenge for dental professionals to treat impacted canines in daily practice. Treatment usually involves surgical exposure and orthodontic traction; such procedures are not risk free, as they may lead to bone loss, gingival recession and root resorption [1]. Apart from third molars, the maxillary permanent canines are the most frequently impacted teeth [2]. These canines may be described as "ectopic", whereby a malposition of the permanent tooth bud causes the tooth to erupt in the wrong position [3]. Tooth impaction occurs when a tooth is prevented from reaching its normal position in the dental arch. This can be due to hard or soft tissue obstruction and/or an abnormal eruption pattern (e.g. after the expected time of eruption) [4]. Studies have shown that the prevalence of impacted canines is between 1% and 2% [5-7]. Failure to diagnose and manage an ectopic maxillary canine efficiently may necessitate more

complex treatment. Furthermore, there is a risk of unfavorable sequelae, such as cyst formation [8], internal resorption of the impacted tooth, external resorption of the impacted or neighboring teeth [9], ankylosis, infection, or loss of arch length. Perhaps the greatest risk associated with palatal impaction of a maxillary canine is resorption of the roots of the lateral incisor; previous studies have reported that the chance of lateral root resorption is up to 48% [10]. Interestingly, the more medial the canine, the higher the chance of lateral incisor root resorption [9]. Therefore, it is important that dentists assess the maxillary canine early to prevent impaction and avoid these unfavorable outcomes [11].

Many authors have recommended regular inspection and palpation of the canine region from the age of 8 years [12-14]. For example, Ngan, *et al.* reported that periodic examination, including clinical intraoral palpation and selective radiographs (Occlusal, periapical or orthopantomograms), should be carried out regularly- beginning at age 8- to facilitate early diagnosis of an unerupted ectopic permanent canine [14]. Similarly, the American Dental Association guideline for dental radiographic examination recommended taking orthopantomogram (OPG) radiographs for patients in the mixed dentition, to assess unusual eruption patterns, however they did not specify taking the OPG to screen for the unerupted, ectopic canines.

Panoramic radiographs can provide valuable information regarding the presence and general location of ectopically erupting maxillary canines [15]. Several authors have reported that, when radiographic signs of an ectopic pathway of eruption are identified early, a deciduous canine extraction should be carried out between the ages of 10 and 13 years. Such a procedure reduces the likelihood of canine impaction and maxillary incisor root resorption [15-18].

Moreover, Ericson and Kurol reported that, if the deciduous canine is extracted when the permanent canine has not yet crossed the lateral root midline, there is a 91% chance that the permanent canine will erupt successfully. However, this number drops to 64% if the permanent canine has crossed the lateral incisor root midline before extraction of the deciduous canine [11]. A similar success rate (62.5%) was reported by Baccetti, *et al* [19]. Extraction of the primary canine was reported to prevent maxillary permanent canine impaction [13], although the literature is not conclusive in this regard [16].

Many studies have aimed to assess the etiology and complications of canine impaction. However, few investigations have analyzed the importance of early canine assessment using orthopantomograms. Therefore, the objectives of this study were (1) to assess the significance of OPGs in the diagnosis of ectopic maxillary canine at an earlier than 10 years of age, (2) to evaluate whether undergraduate dental students and postgraduate students of pediatric dentistry are able to recognize ectopic maxillary canines on an OPG.

## Materials and Methods

This was a cross sectional study, wherein we reviewed the records of patients (male and female) who had attended pediatric dentistry clinic between September 2013 and September 2014. Ethical approval was obtained from Ethical Research Committee of faculty of dentistry. The investigation aimed to use standardized criteria to assess the early signs of ectopic canine on OPGs (Table 1) [20,21], as well as to examine patient notes for any documentation of these canines by the attending clinician. The inclusion criteria were as follows; (1) Patient aged between 8 and 13 years, (2) good-quality panoramic radiographs, (3) no previous experience of orthodontic treatment, (4) absence of severe labial crowding. The exclusion criteria were, (1) absence of permanent maxillary canines or lateral incisors, and (2) patient currently undergoing orthodontic treatment.

The following criteria were used to judge the ectopic position of the maxillary canine on the OPG [20,21].

- The extent to which the canine crown horizontally overlapped the adjacent lateral incisor roots;
- Canine angulation towards the midline;
- The horizontal position of the canine above the premolar;

These three indicators were used to rate the position of the maxillary canine as either “good” or “ectopic” (Table 1). The maxillary canine was considered ectopic when one or more of the above categories suggested it. All the radiographs were assessed by two examiners and confirmed by a senior orthodontic consultant to insure accurate diagnosis.

Criteria	Good position	Ectopic position
Overlap	Canine root does not horizontally overlap lateral root	Crossing lateral incisor root midline
Angulation	0° - 30°	> 30°
Position of the permanent canine	Above the position of the primary canine	Above premolars

Table 1: Criteria for assessing the position of the maxillary canine.

### Statistical Analysis

The statistical package for social sciences (SPSS) version 16 (International Business Machines Corporation; Armonk, New York, USA) was used for data analysis. Differences between the groups (undergraduate and postgraduate) were tested using the chi-square test. The level of significance was set at 5% (P ≤ 0.05).

### Results

A total of 581 out of 648 patients records met the inclusion criteria and were examined. Out of these 581 patients, 345 (59.4%) had been treated by undergraduate students, while 236 (40.6%) had been treated by postgraduate students. The prevalence of ectopic maxillary canine in our sample was 9.5% (55/581 patients). Thirty-seven (67.3%) of the unfavorable canines were undocumented, while 18 were documented as unfavorable or ectopic canines (32.7%). Of the 37 undocumented, unfavorable canines, 23 (62.2%) were treated by undergraduates, while 14 (37.8%) were treated by postgraduate students of pediatric dentistry (Figure 1). The results were not significantly different between the two groups (P = 0.63; Table 2). Regarding age distribution, ectopic canines were found in five patients aged 8 - 9 years, 29 patients aged 10 - 11 years, and 21 patients aged 12 - 13 years (Figure 2). Moreover, 29 of the 55 cases of ectopic canine occurred in male patients, while 26 occurred in female patients.

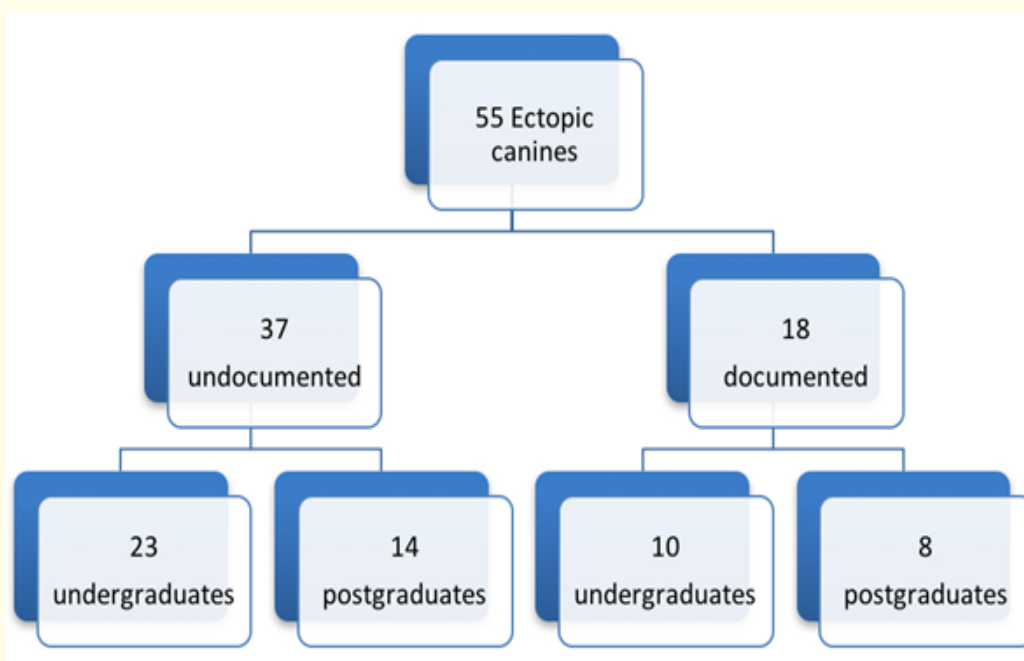
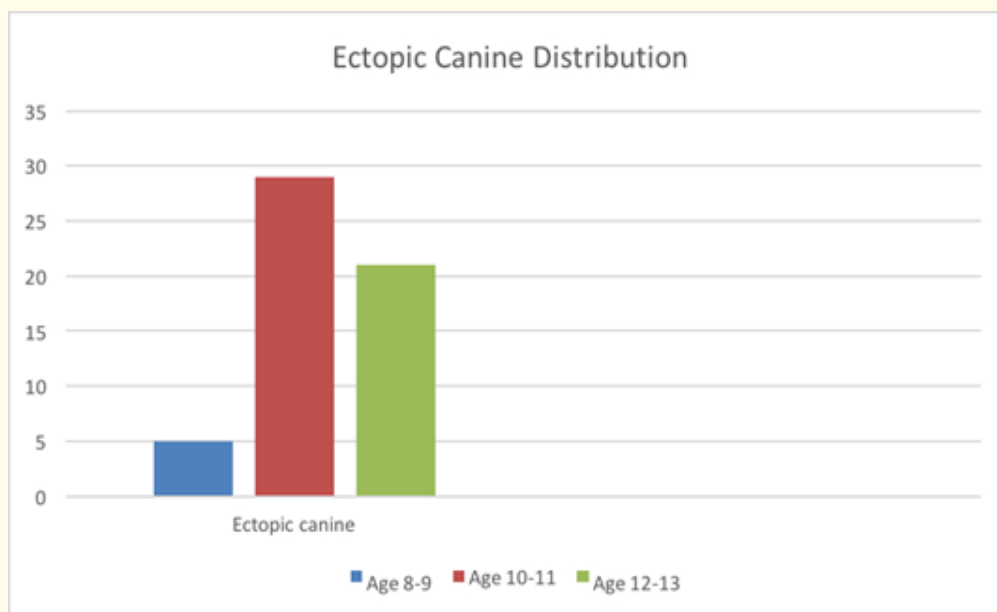


Figure 1: Distribution of unfavorable canine cases.

	Documented	Undocumented	Total
Undergraduates	10	23	33
Postgraduates	8	14	22
Total	18	37	55

**Table 2:** The distribution of documented vs. undocumented ectopic canines in terms of the dental students' level. The difference between the two groups was not significant ( $P = 0.63$ ).



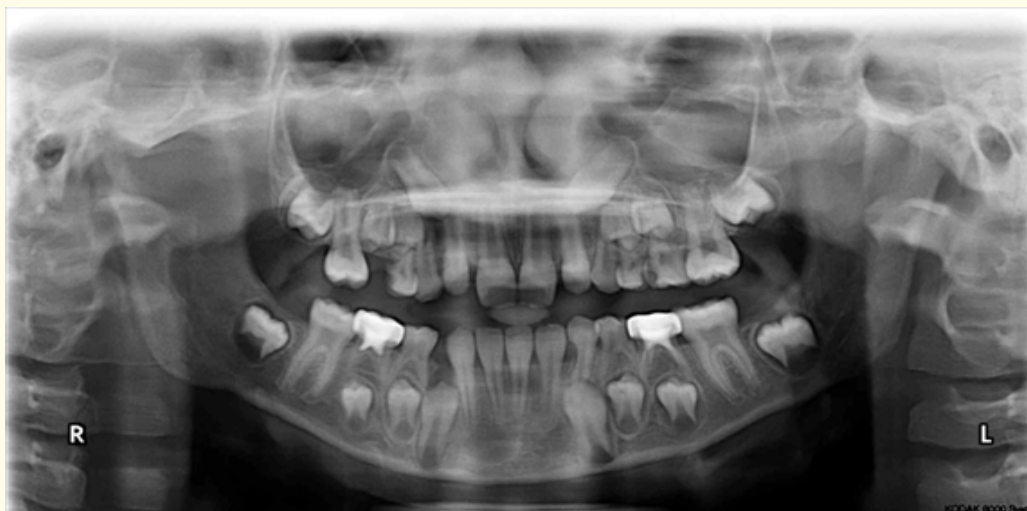**Figure 2:** Ectopic canine distribution by age.

### Discussion

This was a retrospective study, wherein the inclusion and exclusion criteria were carefully established. Patients with previous experience of orthodontic treatment were excluded, because it is unlikely that an orthodontist would overlook an impacted or ectopic tooth. Moreover, missing lateral incisors can alter the path of canine eruption [22], thus eliminating the need for interceptive extraction of the primary canine. Therefore, patients with absent lateral incisors were excluded. The students in our study examined OPGs rather than cone beam computed tomography (CT) scans because OPGs are taken routinely in pediatric dentistry clinics in our hospital, for every new patient at the age of 8 years. In contrast, cone beam CT scans are only requested as supplemental radiographs, not as a standard procedure.

According to Naoumova, *et al.* ectopic canines should be treated by extraction of the primary canine; such treatment facilitates and accelerates permanent canine eruption and may improve the position of the permanent canine [18]. Ngan, *et al.* suggested that periodic examination should start at the age of 8 years, and that this may facilitate early diagnosis of ectopically erupting permanent canines [14]. In this way, the authors corroborated the guidelines of the Royal College of Surgeons in England [12], although these recommend

carrying out only a clinical examination and palpation of the maxillary canines at the age of 8 - 9 years, while delaying radiographic assessment until the age of 10 years in the case of impalpable canines. In our own study, in contrast to both these previous reports, five patients presented with an ectopic canine at the age of 8 - 9 years; all of these patients would have benefited from interceptive extraction of the primary canine. The argument would still be; should our gold slandered be not to miss diagnosing any ectopic canine or to avoid any excessive radiation. Figure 3 is an OPG from one of these patients: an 8-year-old boy whose permanent maxillary canines were approaching the midline of the lateral incisor roots. We believe he would have benefited from an early extraction of the primary canine. Many clinicians would argue that a radiograph should only be taken at the beginning of orthodontic treatment-usually around the age of 10. However, Figure 3 shows that extraction of the primary canine may help the permanent canine to adjust its eruption path. Moreover, an OPG taken at the age of 8 years may allow us to better predict the success of an interceptive extraction. Indeed, the specific predictive factors were described by Naoumova., *et al*. They include the relationship of the canine cusp tip to the midline, and the mesial angulation of the canine tip [17]. In the present study, the prevalence of ectopic maxillary canine was high (9.5% of cases), indicating that early radiographic assessment is important.



**Figure 3:** OPG of an 8-year-old patient showing both maxillary permanent canines approaching the midline of the permanent lateral incisor roots. This patient would benefit from extraction of the primary canine.

Most of the records examined in this study came from patients who had been treated by undergraduate students (59.4%); the remainder had been treated by postgraduate students (40.6%). This reflects the nature of the dental school structure, where undergraduates typically comprise 80% of the school's capacity.

More than half (67.3%) of all cases of ectopic canine were undocumented, and only 18 (32.7%) of the 55 ectopic canines were documented and received interceptive treatment. This discrepancy may be due to many factors. For example, the developing canine may not have been evaluated during OPG assessment; this may occur in the case of younger patients, in whom the canine tends to be in a higher position. Alternatively, staff may have been unfamiliar with the concept of an ectopic canine, which is an early predictor of impaction risk; instead, they may have focused on assessing impacted canines rather than ectopic ones. A third factor that may have contributed to the under diagnosis of ectopic canine may have been the large ratio of students to clinical teaching staff during the clinical sessions. This may

have discouraged the staff from carrying out a full canine evaluation, as they may have chosen to focus on more obvious problems such as caries. In any case, it is worrying that the results were not significantly different between undergraduate and postgraduate students ( $P = 0.63$ ); this result suggests that postgraduate students are no better than undergraduates are when it comes to assessing ectopic canines, which is worrisome. Nevertheless, neither an undergraduate nor a postgraduate student should neglect the assessment of ectopic canines.

Number of records examined and the fact that it was all from one center are limitations that we acknowledge. Further multicenter studies are needed to explain why so many ectopic canines go undiagnosed. Strategies should be established to minimize this problem; local guidelines should be developed and international ones should be updated to recommend that OPGs be taken at an earlier age. Such action would result in better assessment of ectopic canines [23].

### Conclusion

The prevalence of ectopically erupting maxillary canine was 9.5%. OPG proved to be useful in the early assessment of ectopic canine at the age of 8 years. Further studies are needed to explain why so many ectopic canines go undiagnosed. International guidelines should be updated to recommend that OPGs are taken at the age of 8 years to screen for ectopic canines.

### Conflict of Interest and Source of Funding

This was self-funded research with no conflicts of interest.

### Bibliography

1. Bishara SE., *et al.* "Management of Impacted Canines". *American Journal of Orthodontics* 69.4 (1976): 371-387.
2. Afify AR and KH Zawawi. "The Prevalence of Dental Anomalies in the Western Region of Saudi Arabia". *ISRN Dentistry* (2012): 837270.
3. Hitchin AD. "The Impacted Maxillary Canine". *British Dental Journal* 100 (1956): 1-14.
4. Thilander B and N Myrberg. "The Prevalence of Malocclusion in Swedish Schoolchildren". *Scandinavian Journal of Dental Research* 81.1 (1973): 12-21.
5. Langberg BJ and S Peck. "Adequacy of Maxillary Dental Arch Width in Patients with Palatally Displaced Canines". *American Journal of Orthodontics and Dentofacial Orthopedics* 118.2 (2000): 220-223.
6. Shapira J., *et al.* "Prevalence of Tooth Transposition, Third Molar Agenesis, and Maxillary Canine Impaction in Individuals with Down Syndrome". *Angle Orthodontist* 70.4 (2000): 290-296.
7. Sajnani AK. "Permanent Maxillary Canines - Review of Eruption Pattern and Local Etiological Factors Leading to Impaction". *Journal of Investigative and Clinical Dentistry* 6.1 (2015): 1-7.
8. Brown LH., *et al.* "A Radiological Study of the Frequency and Distribution of Impacted Teeth". *Journal of the Dental Association of South Africa* 37.9 (1982): 627-630.
9. Ericson S and J Kurol. "Resorption of Maxillary Lateral Incisors Caused by Ectopic Eruption of the Canines. A Clinical and Radiographic Analysis of Predisposing Factors". *American Journal of Orthodontics and Dentofacial Orthopedics* 94.6 (1988): 503-513.
10. Ericson S and J Kurol. "Incisor Root Resorptions Due to Ectopic Maxillary Canines Imaged by Computerized Tomography: A Comparative Study in Extracted Teeth". *Angle Orthodontist* 70.4 (2000): 276-283.

11. Ericson S and J Kuroi. "Early Treatment of Palatally Erupting Maxillary Canines by Extraction of the Primary Canines". *European Journal of Orthodontics* 10.4 (1988): 283-295.
12. Husain J., et al. "National Clinical Guidelines for Management of the Palatally Ectopic Maxillary Canine". *British Dental Journal* 213.4 (2012): 171-176.
13. Litsas G and A Acar. "A Review of Early Displaced Maxillary Canines: Etiology, Diagnosis and Interceptive Treatment". *Open Dentistry Journal* 5 (2011): 39-47.
14. Ngan P., et al. "Early Timely Management of Ectopically Erupting Maxillary Canines". *Seminars in Orthodontics* 11 (2005): 152-163.
15. Garib DG., et al. "Complications of Misdiagnosis of Maxillary Canine Ectopic Eruption". *American Journal of Orthodontics and Dentofacial Orthopedics* 142.2 (2012): 256-263.
16. Naoumova J., et al. "A Systematic Review of the Interceptive Treatment of Palatally Displaced Maxillary Canines". *European Journal of Orthodontics* 33.2 (2011): 143-149.
17. Naoumova J., et al. "Extraction of the Deciduous Canine as an Interceptive Treatment in Children with Palatally Displaced Canines - Part II: Possible Predictors of Success and Cut-Off Points for a Spontaneous Eruption". *European Journal of Orthodontics* 37.2 (2015): 219-229.
18. Naoumova J., et al. "Extraction of the Deciduous Canine as an Interceptive Treatment in Children with Palatal Displaced Canines - Part I: Shall We Extract the Deciduous Canine or Not?" *European Journal of Orthodontics* 37.2 (2015): 209-218.
19. Baccetti T., et al. "A Randomized Clinical Study of Two Interceptive Approaches to Palatally Displaced Canines". *European Journal of Orthodontics* 30.4 (2008): 381-385.
20. McSherry PF. "The Assessment of and Treatment Options for the Buried Maxillary Canine". *Dental Update* 23.1 (1996): 7-10.
21. Pitt S., et al. "A Treatment Difficulty Index for Unerupted Maxillary Canines". *European Journal of Orthodontics* 28.2 (2006): 141-144.
22. Becker A., et al. "The Etiology of Palatal Displacement of Maxillary Canines". *Clinical Orthodontics and Research* 2.2 (1999): 62-66.
23. "The Use of Dental Radiographs". *The Journal of the American Dental Association* 137.9: 1304-1312.

**Volume 10 Issue 5 May 2017**

**© All rights reserved by Waeil Batwa., et al.**