

Multidisciplinary Treatment of Oligodontia: Six Years Follow Up Case Report

Ivanov ICh^{1*}, Bartak P² and Dostalova T¹

¹Department of Paediatric Stomatology, Charles University in Prague, 2nd Medical School, Czech Republic

²Department of Stomatology, First Faculty of Medicine Charles University in Prague and General University Hospital, Czech Republic

***Corresponding Author:** Ilija Christo Ivanov, Department of Paediatric Stomatology, Charles University in Prague, 2nd Medical School, Czech Republic.

Received: March 09, 2017; **Published:** March 27, 2017

Abstract

This case report presents the multidisciplinary treatment of oligodontia by orthodontist and implantologist in a female Caucasian patient with hypothyroidism, aged 33 years 2 months. Clinical and radiological examination showed the congenitally determined absence of the upper lateral incisors, all second premolars and wisdom teeth. The patient displayed an unaesthetic smile showing upper canines in place of laterals and rotated first premolars; her profile was slightly concave due to the tooth agenesis leading to retrusion of the upper and lower incisors. The orthodontic phase of treatment aimed to create sufficient space for the alignment of all teeth and implants. Subsequently implants were inserted and augmentation done at the space open for lateral incisors. The total time taken to accomplish treatment, achieved stable and aesthetic occlusion and to meet the patient's expectations was 4 years and 4 months (3 years and 10 months for the upper jaw and 1 year and 2 months for the lower jaw). Follow-up checks took place over a period of 6 years after completion of the treatment in order to maintain the stability of the results achieved.

Keywords: Tooth Agenesis; Adult Patient; Orthodontic Treatment; Implantology

Introduction

Physical attractiveness, including facial aesthetics, is widely considered to be an important asset when looking for a job or seeking a life partner. Therefore, many adults consult dental specialists such as orthodontists, implantologists or general dental practitioners (GDP) to seek advice and treatment for what they perceive to be a social problem.

Tooth agenesis is a dental malformation in which teeth are missing because they fail to develop during the initial stages of tooth formation (initiation and proliferation). According to the degree of severity, this malformation can be subdivided into hypodontia, oligodontia and anodontia. Hypodontia, a condition in which the patient is missing up to 5 permanent teeth (excluding wisdom teeth), reportedly affects between 3% and 8% of the population [1]. Oligodontia is a rare developmental dental anomaly in humans characterized by the absence of six or more teeth (excluding the 3rd molars). Occasionally, it occurs in a patient with no apparent systemic problem or congenital syndrome. Not all teeth are equally susceptible to a reduction in odontogenic potential. As a general rule, if only one or a few teeth are missing, the absent tooth will be the most distal tooth of any given type [2]. Anodontia is a rare genetic disorder characterized by the congenital absence of all primary or permanent teeth. It usually manifests itself as part of one of the dermatological and nervous syndromes collectively known as ectodermal dysplasias and seldom occurs as an isolated entity.

The orthodontic treatment of missing teeth and especially of oligodontia requires a multidisciplinary approach which very often includes the insertion of implants.

Modern implants come in a variety of shapes and sizes to suit the different teeth which they replace, and the types of prosthetic (false) teeth they will replace. They differ also in thread design, in type of an implant- abutment connection and in the material used for their

manufacture. The surface of an implant can be modified by using a variety of techniques such as sandblasting, acid etching, hydroxyapatite layering etc., which dramatically increase the overall surface area to which bone can attach.

Case Presentation

A female Caucasian patient, aged 33 years 2 months was seeking to improve her aesthetic appearance as well as to achieve proper occlusion. The patient gave her written informed consent to the clinical examinations, X-rays, dental casts and regular follow-ups, including the taking of photographic records, and to the publication of all of the above, in accordance with the Declaration of Helsinki.

Extraoral status (Figure 1): Showed a mesocephalic face with a more prominent right facial half and symmetrical facial thirds. The profile was slightly concave with incompetent lips up to 3 mm. When smiling, the patient displayed her upper canines in place of laterals and rotated upper first premolars. This unaesthetic appearance was one of the main factors in the patient’s decision to consult an orthodontist.

Intraoral status (Figure 1 and 2): In the upper jaw, lateral incisors, second premolars and third molars were missing. The canines were mesialized in the place of the missing laterals. The palatal cusps of the first upper premolars were mezially inclined and the teeth rotated vestibulo-distally by nearly 90°. The fillings were present in the first molars and the right second molar. Dental discrepancy measured at the upper jaw dental casts showed an excess of a plus 8 mm.

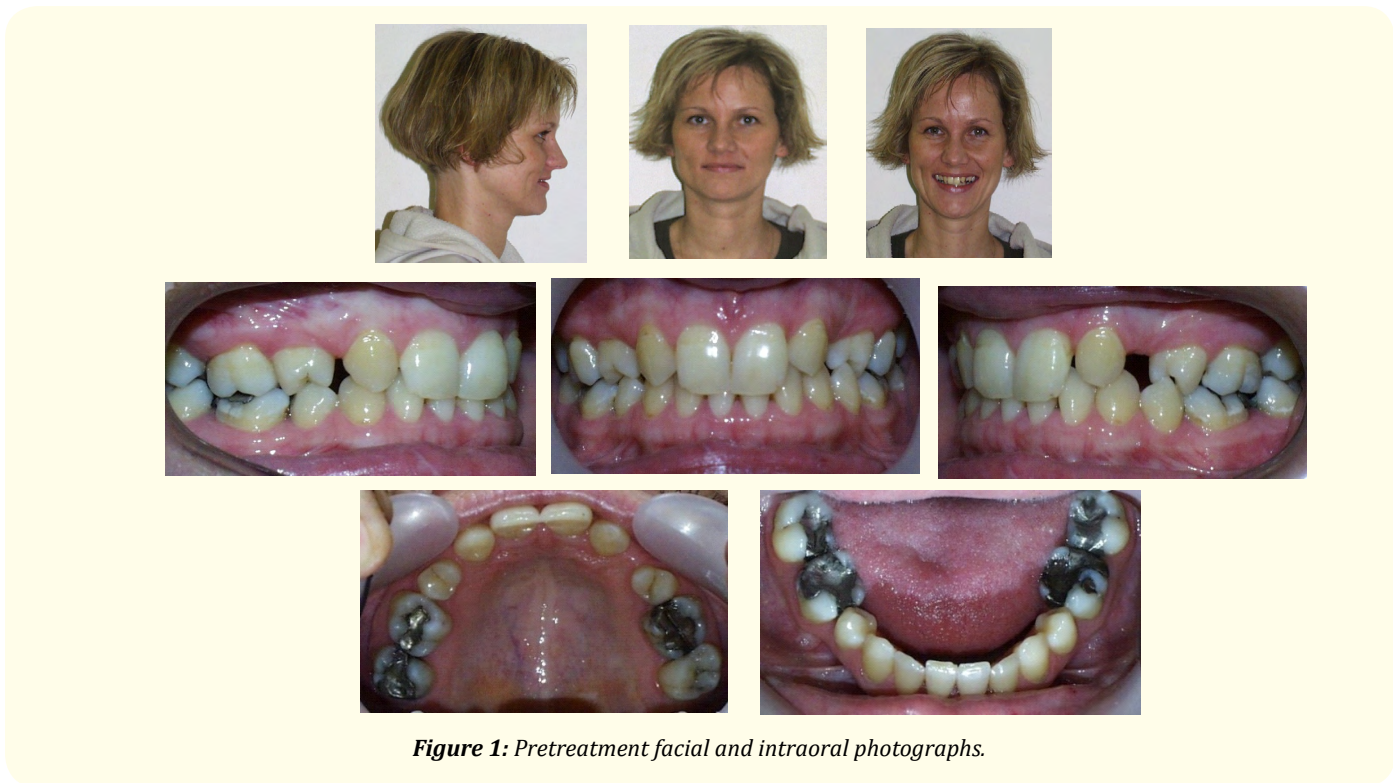

Figure 1: Pretreatment facial and intraoral photographs.

In the lower jaw, second premolars and third molars were missing. Due to the missing premolars all teeth from the lateral area were mesialized without spacing. Substantial amalgam fillings were present in the first and second molars with a cavity in the right first premolar. The dental discrepancy was plus 2 mm.

The molar relationship showed ½ Class II on the right side and I Class on the left. Due to the missing teeth, it was not possible to assign Angle Class relations in the canines region. The midline in the upper jaw was shifted by 2 mm to the right. Measurements revealed an overjet of 2 mm and an overbite of 6mm. Buccal nonocclusion was present in the right upper first premolar.

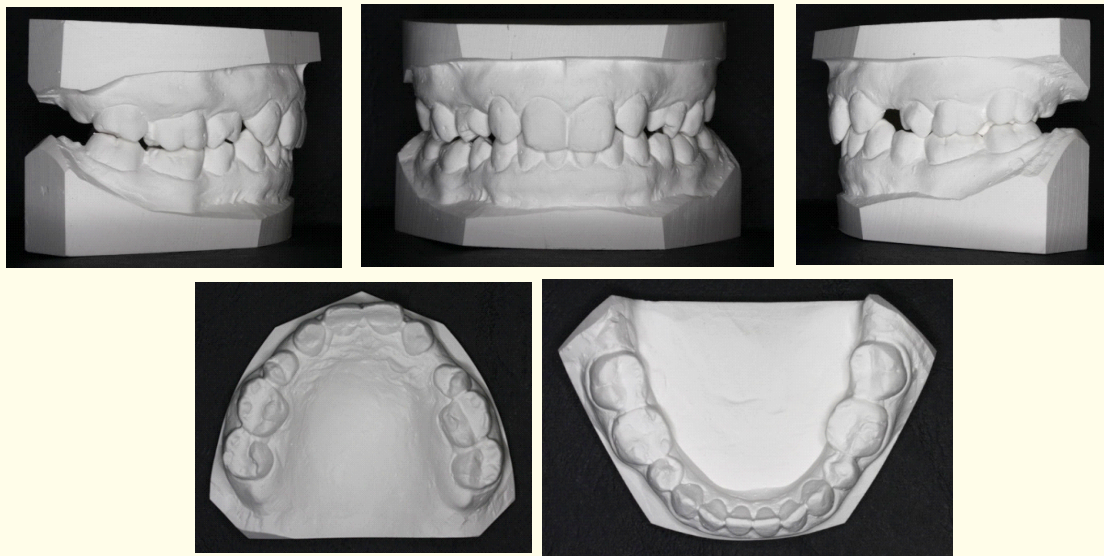


Figure 2: Pretreatment dental casts.

The orofacial muscles had a normal tone and the temporomandibular functions did not cause any inconvenience, sound phenomena or pain. Dental hygiene was found to be adequate and the periodontal status matched this finding.

Personal anamnesis: The patient did not report any infectious diseases, allergies, bad habits or current illnesses. Because of hypothyroidism she was taking Letrox 50 mg /Berlin-Chemie AG (Menarini Group), Germany/ 1 tablet daily. The family anamnesis was not substantive.

Orthopantomogram (OPT) evaluation (Figure 3): This confirmed the intraoral findings and diagnosed oligodontia, with the absence of 6 permanent teeth and all 3rd molars. To investigate the suspected cavity under existing fillings in the lower jaw, bite wings were requested from the patient's general dental practitioner. The bone showed periodontal changes in the interdental horizontal height loss in both upper and lower jaw. Radiographic and clinical examinations of the temporomandibular joint (TMJ) showed no symptoms of destructive changes, as far as could be determined from the quality of the X-ray, which was on plastic film.

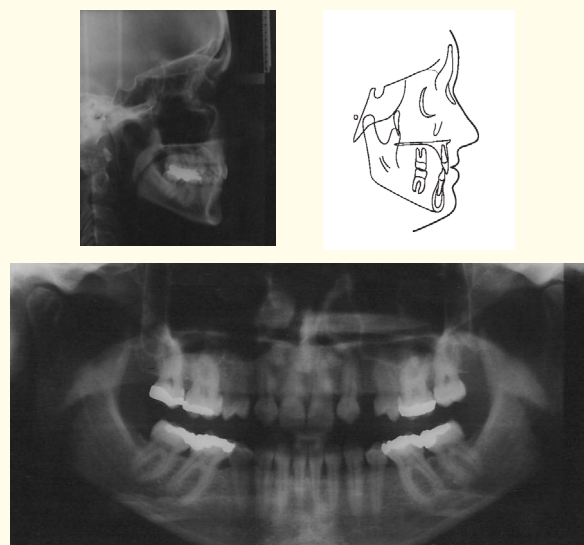


Figure 3: Pretreatment radiographs and tracing.

Cephalometric analysis (Table, Figure 3): Skeletal I Class occlusion with a Wits appraisal value of -1.4mm and an ANB angle of -0.7° was measured. The upper and lower incisors were retruded ILS/NL 97.3° and ILI/ML 76.3° respectively. This finding was confirmed by the interincisal angle with values of +1-1 = 155.7°. The lower incisors were also retruded by -2.9 mm.

Cephalometric values			
	Norm	Pretreatment	Final
SNA (°)	82	81.5	81.1
SNB (°)	79	80.1	81.2
ANB (°)	3	1.4	-0.1
ILs/NL (°)	110	97.3	119.1
ILi/ML (°)	94	76.3	86.6
SNP _g (°)	80	81	82.3
Wits (mm)	0	1.5	-1.7
NL/ML (°)	25	28.9	27.7
ArGoMe (°)	126	126.6	125.4
1+1- (°)	1	155.7	124.1
1-Apg (°)	1	-2.9	-0.3
Overjet (mm)	3	4	3.8
Overbite (mm)	2.5	4.8	0.9

Table: Cephalometric values.

Treatment objectives: The treatment objectives for the patient were as follows: 1. Derotation of the maxillary first premolars; 2. Creation of sufficient space for implants at the lateral incisor sites by distalizing the canines in their place. 3. Increase in bite height and creation of an ideal overbite and overjet; 4. Improvement of facial profile thereby improving aesthetic appearance.

Treatment plan

1. Insertion of bands at the upper first molars with a transpalatal arch (TPA) for derotation and anchorage; braces at the second molars and buttons on the palatal side of the first premolars for its derotation.
2. Completion of full upper fixed appliance insertion, correction of midline, distalization of the canines and the opening of space for implants at both lateral incisor sites.
3. Full lower fixed appliance insertion and alignment, increasing of the deep bite.
4. Implant insertion at the upper laterals prior to the finishing phase and removal of the appliances.
5. Retention by means of fixed retainer in the upper jaw at the central incisors and lower teeth from canine to canine, and simple removable appliance in each jaw.

Treatment progress

Orthodontic phase (Figure 4 and 5)

The start of treatment in the upper jaw followed our treatment plan (Figure 4). After derotation of the first upper premolars, braces were inserted on the canines and the central incisors, and the canines were distalized. Measurements showed 5.5 mm space available for the left incisor and 3 mm for the right. It was clear that there was not enough space for an implant insertion. Because of this, dental casts were made and the distalization appliance was manufactured to achieve right first molar distalization and create sufficient space for the right premolar and canine also to be distalized, and implant space obtained. The appliance consisted of a Nance acrylic button and three

soldered bands: two at the premolars and one at the left first molar. The right side had a sliding arm, and on the vestibular side a Stainless steel (SS) wire with a push Nickel –titanium (NiTi) coil spring was inserted to transmit right molar distalization (Figure 2). When the right first molar was in a I Class Angle relationship, the soldered TPA was used for anchorage of the result achieved.

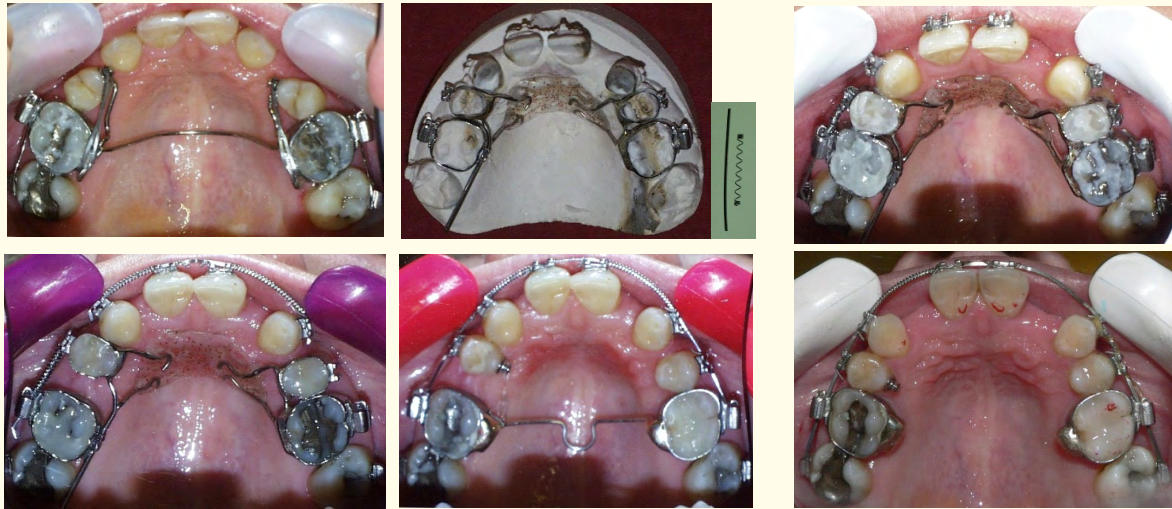


Figure 4: Phases of treatment: first row shows initial insertion and distalization appliance. Second row shows result of distalization and subsequent creation of space for implants at the laterals.

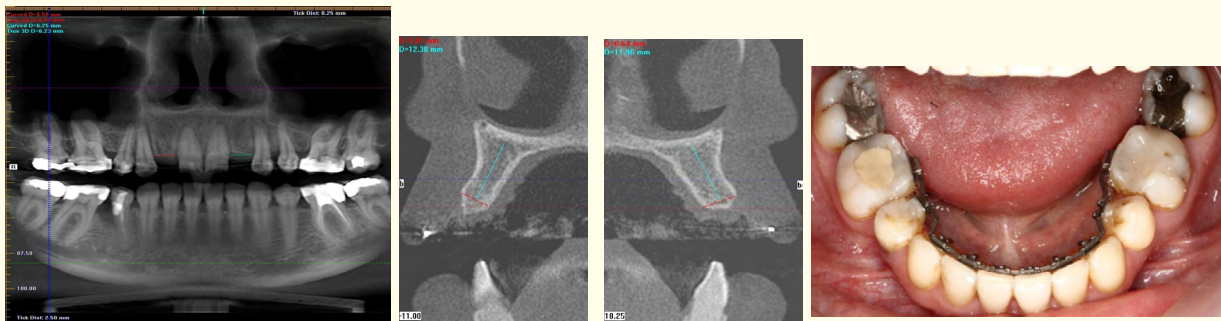


Figure 5: CBCT images before implant insertion and photograph of the lower 2D lingual appliance.

In the lower jaw, the right first premolar and both first molars required endodontic treatment, which was undertaken by the patient’s general dental practitioner (GPD). Then 2D lingual braces (catalogue number 763-1126, Forestadent, Germany) were inserted in the lower jaw with an initial 0.012” CuNiTi wire (Figure 5).

Orthodontic treatment in the upper jaw was accomplished using Gemini braces by 3M Unitek, Roth prescription with 0.018” slot. During subsequent visits, the wire was upgraded from round soft NiTi wire to stiff SS wire. Space for the insertion of upper lateral incisor implants was created by use of push coil springs. On the CBCT space was measured to be 6,5mm on the right and 6mm on the left side (Figure 5).

Implantological phase

The CBCT analysis of the site for the lateral incisors showed sufficient space for implant insertion of 6.5 mm at the right and 6.23 mm at the left sides, after orthodontic phase. The vestibular surface of the alveolar crest was found to be concave and the vestibulo-oral width to be slightly reduced, which required augmentation on both sides (Figure 5). Prior to surgery, the patient was premedicated with an antibiotic (ATB): 1g amoxicillin daily for 7 days + clavulanic acid in association with an analgetic: 40mg ibuprofen daily for 7 days. Insertion itself was carried out under local anaesthesia with Supracain 4% 2 ml (Zentiva, Czech Republic). Two Dentis Submerged titanium implants (Dentis, South Korea) measuring 3.7x12 mm were inserted in the prepared sites for the upper laterals with a torque moment of 35 M.cm⁻¹. Vestibular bone perforations were carried out using a small spherical bur, and both concave vestibular sites were filled with the augmentation material Poresorb-TCP (Lasak, Czech Republic), whose particles have a size of 0.6 - 1 mm. Then the augmentation material was covered with a collagen barrier membrane Hyprosorb F (Hypro Otrokovice, Czech Republic). Repositioning of the mucoperiosteal flaps and suturing of the wound completed the implant insertion. Control intraoral X-rays of the inserted implants were taken to ensure the accuracy of the placement. Healing was under control of ATB used for 3 days and rinsing with chlorhexidindigluconate 0.15% three times daily for 10 days.

Three and a half months later, taking into consideration the slight concavity in the vestibular aspect of the implant sites, connective tissue grafts were harvested from the palatal mucosa bilaterally. Augmentation was undertaken under local anaesthesia and after a horizontal incision on the alveolar bone ridge. A supraperiosteal pouch was created buccally on each implant site and the grafts were inserted into the pouches. After the grafts were secured in place using mattress sutures, the recipient and donor sites wounds were sutured and a removable palatal protective appliance put into place.

Three months after soft tissue grafting, the upper orthodontic appliance was removed and both implants were uncovered under local anaesthesia. Impressions were taken using A-silicones.

A-Basic Precise Fast Set plus Betasil Vario Medium (Müller-Omicron, Germany) and Impressions Copings Pick-Up (Dentis, South Korea)/. One day later temporary screw retained crowns were fixed (torque moment of 25N.cm⁻¹) to the implants for the purpose of shaping the soft tissue. Four months later impressions were taken for ensuring implants position, soft tissue status and manufacturing the final crowns. Impressions bodies were individualized to stabilized soft tissue contour by the use of acrylic resin (Pattern Resin LS, GC America Inc., USA). After the impressions were taken, the temporary crowns were again fixed to the implants. The finishing phase took place a week later, when the temporary crowns were removed and the titanium abutments Angled Abutment (Dentis, South Korea) were inserted (torque moment of 30N.cm⁻¹). Subsequently all-ceramic zirconia crowns made by were fixed to the abutments by Fuji Plus (GC America Inc., USA). The patient received instructions about care of her teeth and checking for plaque. When examined four weeks later she showed good dental hygiene and was very satisfied with the results of the treatment. After completion of the implant insertion procedure, the patient was sent back to the care of her GDP.

Retention phase

After the appliance was removed, fixed retainers were inserted and bonded between the incisors in the upper jaw and from canine to canine in the lower jaw. Soft 0.16 braided lingual retainer wire (Bond•a•Braid™, Forestadent, Germany) bonded with a light cure resin Retensin MT and Opticor flow (Spofa Dental, Czech Republic) was used. The patient was shown how to maintain good oral hygiene with floss, and again familiarized with the correct methods for brushing teeth.

Two simple removable appliances were manufactured, one for each jaw, to secure the results of the orthodontic treatment. The treatment time for the upper jaw was 3 years and 10 months and for the lower jaw 1 year and 2 months. The completion of the oligodontia treatment took 4 years and 4 months in total.

Treatment results

Extraoral status (Figure 6)

At the end of the treatment process, a more symmetrical facial appearance in line with the patient’s expectations had been achieved. The midline was corrected, deep bite was increased, canines were properly positioned and implants inserted on both lateral incisor sites. When smiling, the patient now displayed all teeth in the upper jaw, leading to full smile without black buccal corridors and resulting in a more pleasant overall impression.

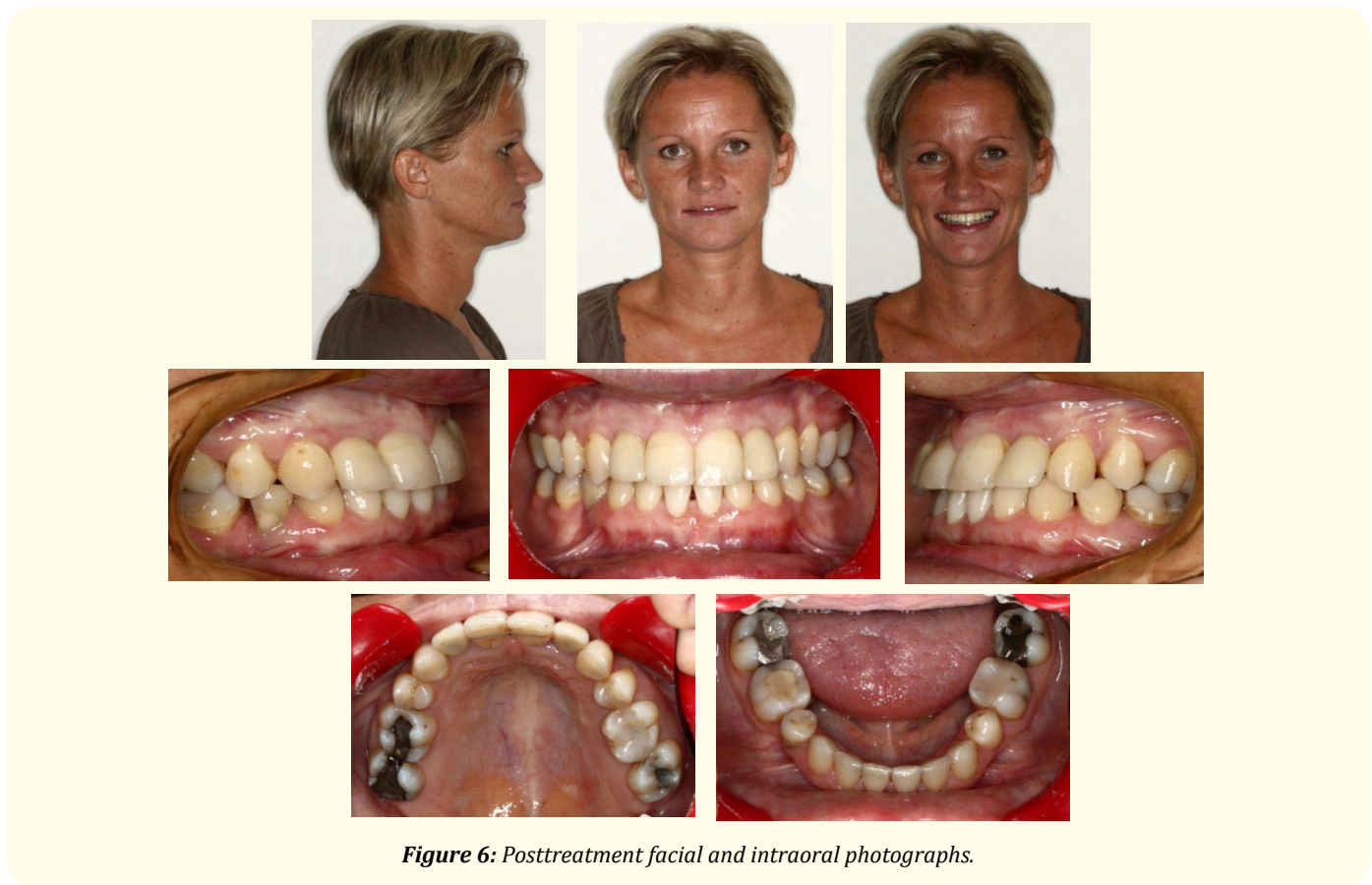

Figure 6: Posttreatment facial and intraoral photographs.

Intraoral status (Figure 6, 7)

In the upper jaw right side, teeth distalization led to sufficient width space in the frontal region for midline correction and implant insertion at the place of laterals. In the lower jaw, the 2D lingual technique allowed alignment of the lower teeth and an increase of the deep bite. A Class I Angle relationship was achieved after treatment in the molar and canine regions. The patient had no TMJ dysfunctions either before or after treatment.

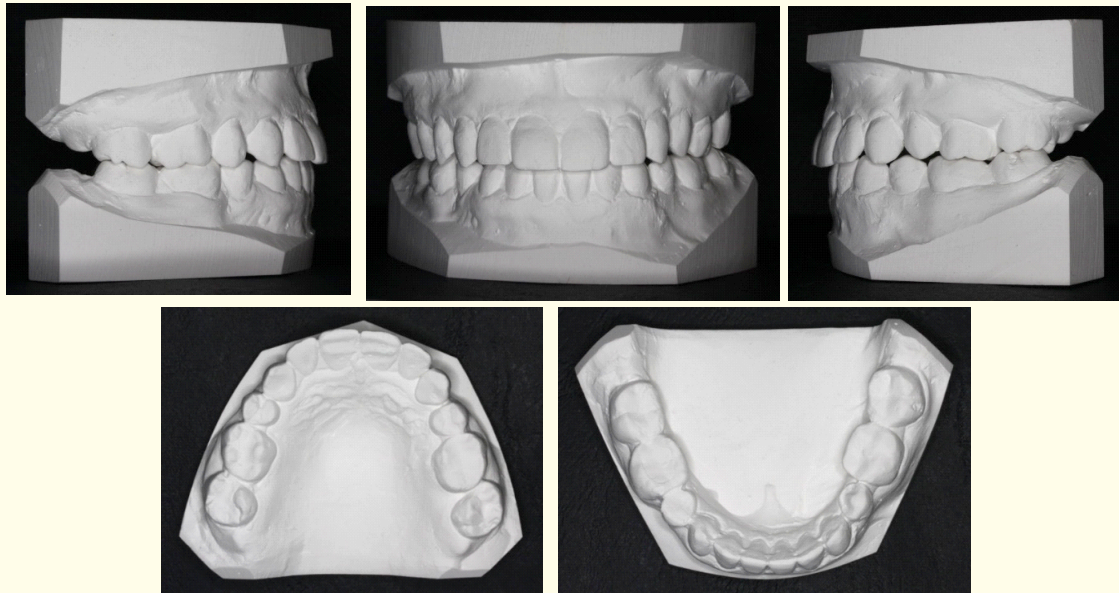

Figure 7: Posttreatment dental casts.

Periodontal status

Because of the braces affixation and implants insertion, the patient paid several visits to the dental hygienist and periodontologist before, during and after the treatment. Nevertheless, gingival recession was observed on the right lower first premolar before and after treatment. This tooth had a deep cavity under the gingival margin, and endodontic treatment and deep curettage were performed on it by the periodontologist.

The panorex taken after treatment showed no significant bone loss or root resorption, except in the above mentioned right lower first premolar (Figure 8). The implants inserted in the position of both upper laterals showed the same marginal bone level as the neighbouring teeth. Fixed retainers were in place, one in the upper jaw between the incisors and one in the lower jaw from canine to canine. After root canal treatment, both lower first molars showed periapical radiolucency. Also, a cavity was suspected under the amalgam filling of the upper right second molar. Therefore, the patient was referred again to her GDP.

Cephalometric evaluation (Table, Figure 8)

Posttreatment cephalometric analysis showed an improvement in skeletal relationships (Figure 8). The retrusive upper and lower incisors now displayed normal values of 119.1° and 86.6° respectively. The interincisal angle confirmed that finding with a value of 124.1° . Open bite was reduced by 9.6° and the gonion angle by 4.9° . The lower incisors no longer retruded, 1-APg went from -2.9 mm to -0.3 mm). The Wits appraisal actually showed a negative value of -1.7 mm. Overall, skeletal changes in the patient's face were satisfactory and led to a pleasant appearance. Cephalometric superimposition and a photographic comparison are presented in Figure 9.

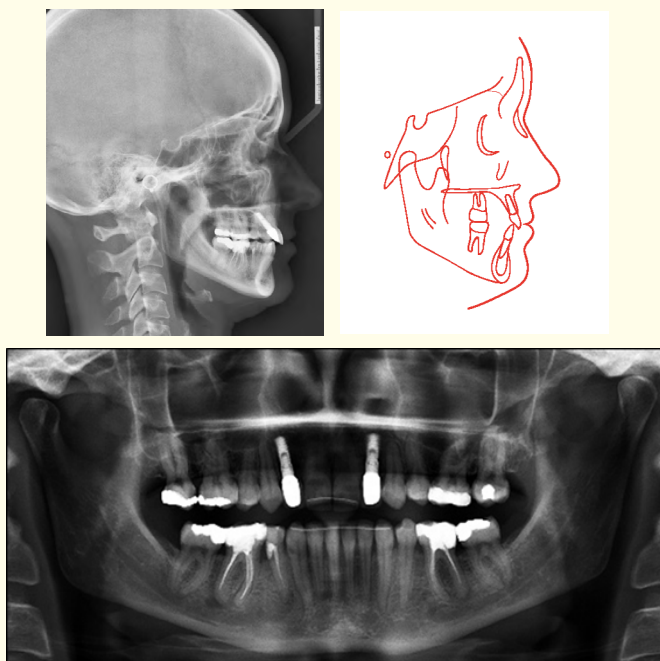


Figure 8: Posttreatment radiographs and tracing.

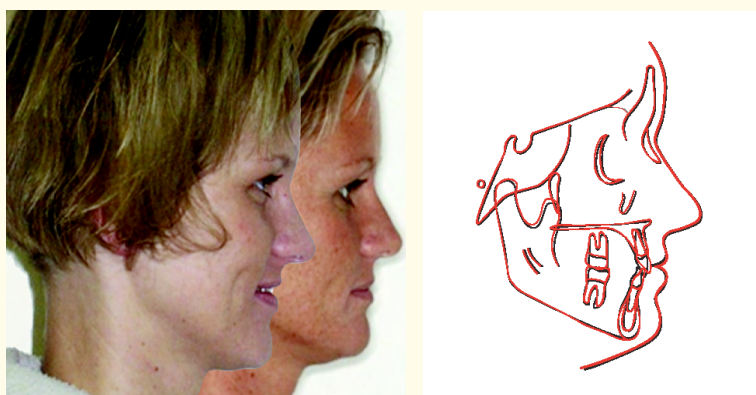

Figure 9: Photograph comparison and cephalometric superimposition.

Long term follow up

We have been conducting regular follow-up tests on the patient during the six years since completion of her treatment. Four years after implant insertion, clinical examination showed the thin mucosa at the right implant margin, whilst the implant abutment was visibly dark coloured around the tooth margin. The patient did not have a problem with this, since when smiling there was not any gum display. Better occlusion had developed, but slight gaps had occurred between the upper canines and the first premolars. The periodontal status showed exposure of the gingival margin without gum swelling, bleeding or tooth mobility. The upper jaw fixed retainer on the central incisors had to be removed 5 years after its initial insertion, due to cavities at their mezial surfaces. The composite fillings were made by her GDP (Figure 10).

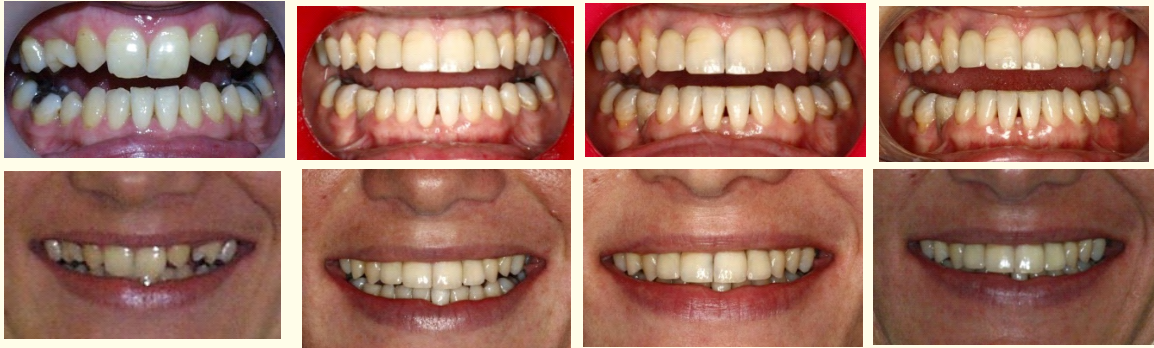

Figure 10: Photographs before, after and four and six years after treatment.

In discussion with the patient six years after treatment, her subjective feelings were that she had developed higher self-confidence following the orthodontic and implantological correction of her facial appearance. New occlusal development had improved also her chew ability. She attends our surgery for a check-up once a year and at this stage is not considering further augmentation procedures by implantologist or periodontologist.

Discussion

Hypodontia is a condition in which the patient has missing teeth as a result of the failure of those teeth to develop, also called tooth agenesis. Our patient was diagnosed with oligodontia because she was missing more than five permanent teeth, excluding 3rd molars. Missing wisdom teeth do not count as their agenesis occur in 9 - 30% of studied population. The literature review by Rakhshan found that congenitally missing teeth (CMT) usually appear in females and in the permanent dentition. He also reported that besides an unfavourable appearance, patients with missing teeth may suffer from malocclusion, periodontal damage, insufficient alveolar bone growth, reduced chewing ability, inarticulate pronunciation and other problems.

For the above-mentioned reasons treatment of this condition is often expensive and multidisciplinary [3]. The range of problems that can present in patients with hypodontia is confirmed by Carter, *et al.* whose recommendation is that every case should be considered on its own merits and discussed fully within the multidisciplinary team [4].

In our patient, due to symmetrical agenesis we had to deal mainly with second upper premolar rotations, upper lateral incisor agenesis and the deep bite. From an orthodontic point of view there were two treatment options regarding lateral incisor agenesis. The first was to leave the canines in the place of the laterals and to mesialize all distally sited teeth. Leaving canines in their place and mesialization of the premolars would require first premolar intrusion and canine extrusion for aesthetic reasons with a subsequent widening of the premolar crowns and, in our patient, ceramic veneers to the canines [5]. The second option was to distalize the canines in their place and to obtain enough space for implant insertion. There were a number of reasons for choosing canine distalization followed by implant insertion on the laterals in our patient. The main one was the unaesthetic appearance of the canines in the place of the laterals, then the rotation of the premolars, and finally the constricted bone area with undesirable spacing between canines and premolars, which needed remodeling. Last but not least there was a retrusion of the upper and lower incisors which led to an unaesthetic concave profile appearance. Therefore, incisors protrusion in both jaws with distalization of the upper right side lateral teeth was desired. The predictability, conservative nature, and long-term success rates of implants have made them an obvious restorative choice, especially in cases where the adjacent teeth are healthy, unrestored, and of normal size and shape [6-8].

In both above mentioned treatment options the use of Temporary Anchorage Devices (TAD's) would seem to be an elegant solution [9,10]. It was unfortunately not desired from our patient, who choose to use a noncompliance molar distalization appliance. A lot of ap-

pliances for molar distalization are described in the literature: the Pendulum Appliance (PA), the Distal Jet, the Keles Slider Appliance, the Jones Jigtm, the First Class Appliance and their modifications [11]. On the principals used in their construction we manufactured an easy to use, inexpensive distalization appliance especially for our patient (Figure 4). The effects like incisor proclination and a slight increase in vertical facial dimension described in a study by Fontana M. were desired, observed and described also in our patient [12].

From the patient's anamnesis we know that she was suffering from hypothyroidism, which was controlled by medication. In the case of congenitally missing teeth in combination with hypothyroidism, the clinician has to be aware of future bone loss. The patient should be informed in time about the possibility of future worsening of the bone condition which may have an impact on the implant treatment outcome. A study by Attard and Zarb investigating the success outcomes of implants and prosthodontic treatment in patients with a previous history of hypothyroidism observed twenty-seven female patients with a medically confirmed history of primary hypothyroid disease. Their findings confirmed that medically controlled hypothyroid female patients treated with dental implants are not at higher risk of implant failure when compared with matched controls; therefore, hypothyroidism is not a contraindication for implant therapy with endosseous implants [13].

For cephalometric analysis, the Williams method was used [14]. This method is sufficient to determine the skeletal and dental relationships and to serve our evaluation and diagnostic needs.

Today various types of dental endosteal or subperiosteal implants are available, simplified speaking. The endosteal implant can be submerged or non-submerged. The latter is claimed to be more reliable, allowing wider peri-implant attached gingiva and avoiding the need for a second surgical procedure, to substitute the cover screw with the healing screw. The submerged implants have covered healing thereby giving the possibility of making improvements during the second phase of surgery, which was desired and done in our patient. In a study by Cordaro L., *et al.* the clinical outcome of submerged vs. non-submerged tapered implants placed into fresh extraction sockets was compared. They found similar outcomes for implants placed in fresh extraction sockets and reported that 1 mm of mean soft tissue recession is seen after 1 year when compared with the pre-extraction state [15].

Patient age can be a prognostic factor for the long-term success of implant insertion. On average, older patients have potentially longer healing times, more systemic health issues and the likelihood of poorer local bone conditions [16]. Ageing changes in adults reported in a study by Oesterle *et al.* occur over decades, rather than rapidly, as in children. Growth changes occur in the arches and result in adaptive changes in the teeth over time, both vertically and horizontally, and in alignment [17]. We observed similar adaptive changes (described above) in our patient six years after treatment.

Conclusion

The treatment of congenitally missing teeth and especially of oligodontia is complex and involves a multidisciplinary approach. When formulating an appropriate treatment plan for each patient, it is necessary to take into consideration the individual characteristics of the teeth, the malocclusion and facial features, as well as the patient's expectations and objectives. Communication between the GDP, periodontologist, orthodontist, implantologist and laboratory technician was essential in our patient, to ensure a successful outcome.

Our case report shows that excellent aesthetic and stable results can be achieved by the orthodontic management of a patient with oligodontia when combined with the insertion of dental implants.

Conflict of Interest

We have no conflict of interest.

Bibliography

1. Polder BJ. "A meta-analysis of the prevalence of dental agenesis of permanent teeth". *Community Dentistry and Oral Epidemiology* 32.3 (2004): 217-226.

2. Proffit WR, *et al.* "Contemporary Orthodontics: 4th Edition". *Mosby* (2007): 135-136.
3. Vahid Rakhshan. "Congenitally missing teeth (hypodontia): A review of the literature concerning the etiology, prevalence, risk factors, patterns and treatment". *Dental Research Journal (Isfahan)* 12.1 (2015): 1-13.
4. Carter NE, *et al.* "The interdisciplinary management of hypodontia: orthodontics". *British Dental Journal* 194.7 (2003): 361-366.
5. Rosa M, *et al.* "Congenitally missing maxillary lateral incisors: Long-term periodontal and functional evaluation after orthodontic space closure with first premolar intrusion and canine extrusion". *American Journal of Orthodontics and Dentofacial Orthopedics* 149.3 (2016): 339-348.
6. Henry PH, *et al.* "Osseointegrated implants for single tooth replacement: a prospective 5-year multicenter study". *International Journal of Oral and Maxillofacial Implants* 11.4 (1996): 450-455.
7. Garber DA, *et al.* "Immediate total tooth replacement". *Compendium of Continuing Education in Dentistry* 22.3 (2001): 210-218.
8. Mayer TM, *et al.* "The single-tooth implant: a viable alternative for single-tooth replacement". *Journal of Periodontology* 73.7 (2002): 687-693.
9. Jason B Copea. "Temporary anchorage devices in orthodontics: A paradigm shift". *Seminars in Orthodontics* 11.1 (2005): 3-9.
10. Antoszewska J, *et al.* "Five-year experience with orthodontic miniscrew implants: A retrospective investigation of factors influencing success rates". *American Journal of Orthodontics and Dentofacial Orthopedics* 136.2 (2009): 158.e1-158.e10.
11. Moschos A Papadopoulos. "Orthodontic Treatment of the Class II Noncompliant Patient: Current Principles and Techniques". *Mosby* (2006): 231-271.
12. Fontana M, *et al.* "Non-compliance maxillary molar distalizing appliances: an overview of the last decade". *Progress in Orthodontics* 13.2 (2012): 173-184.
13. Attard NJ and Zarb GA. "A study of dental implants in medically treated hypothyroid patients". *Clinical Implant Dentistry and Related Research* 4.4 (2002): 220-231.
14. Williams S and Loster BW. "Cephalometrics rationalized: Presenting the Kracovia Composite System (KCS)". *Journal of Stomatology* 65.4 (2012): 525-542.
15. Cordaro L, *et al.* "Clinical outcome of submerged vs. non-submerged implants placed in fresh extraction sockets". *Clinical Oral Implants Research* 20.12 (2009): 1307-1313.
16. Wood MR and Vermilyea SG. "A review of selected dental literature on evidence-based treatment planning for dental implants: report of the Committee on Research in Fixed Prosthodontics of the Academy of Fixed Prosthodontics". *Journal of Prosthetic Dentistry* 92.5 (2004): 447-462.
17. Oesterle LJ and Cronin RJ Jr. "Adult growth, aging, and the single-tooth implant". *International Journal of Oral and Maxillofacial Implants* 15.2 (2000): 252-260.

Volume 9 Issue 1 March 2017

© All rights reserved by Ivanov ICh., *et al.*