

Alveolar Cleft Review Article

Hatem ElMekkawi¹, Ghada ElMorshedy^{2*} and Osama Alshahat³

¹Chairman Oral and Maxillofacial department, El Araby, El Shiekh Zayed Specialized, El Kateb, Heliopolis, Maadi Charity and One day Surgery Hospitals, Nasr City, Cairo , Egypt

²Consultant Oral and Maxillofacial Surgeon, Elraby, Elhiekh Zayed Specialized, Elateb, Heliopolis, Maadi Charity and One day Surgery Hospitals, Giza, Egypt

³Professor and head of plastic and reconstructive surgery department, ElHussien University Hospital, Cairo, Egypt

***Corresponding Author:** Ghada ElMorshedy, Consultant Oral and Maxillofacial Surgeon, Elraby, Elhiekh Zayed Specialized, Elateb, Heliopolis, Maadi Charity and One day Surgery Hospitals, Giza, Egypt.

Received: January 19, 2017; **Published:** February 13, 2017

Abstract

Various methods of repair of Alveolar cleft had been mentioned stressing on the outcome and the timing of the procedures. Secondary bone grafting seems more advocated by various authors, however primary bone grafting is still used.

The new procedures of stem cells, distraction osteogenesis, and BMP (bone morphogenetic protein) are a recent innovation to this field.

Further studies are needed to illy. The potential effects of BMP, Stem cells and distraction osteogenesis to an accepted method of alveolar cleft repair side by side with the bone grafting.

Keywords: Alveolar cleft; etiology and repair

Introduction

Cleft lip and palate is a common congenital anomaly affecting about 1:1,000(50 % of all clefts) [1].

The palate alone constitutes 1:2,000 (30 % of all clefts) and submucous cleft palate one in 1,200.

Etiology of cleft can be inherited or Environmental. A number of genes are involved including cleft lip and palate transmembrane protein [1].

However exposure to teratogens such as alcohol, cocaine, Smoking, Diabetes, Drugs and toxoplasmosis can produce same effect.

Cleft lip and palate can also be a part of more than 400 syndromes including Pierre Robin, Down syndromes, Treacher collin's.

30 % of cleft deformities are associated with a syndrome.

The algorithm of treatment is mentioned (Figure 1) with detail explanation for various procedures to follow.

Repair of cleft lip and palate is Multi-disciplinary procedure with Comprehensive care of functional and aesthetics, Starting From birth into adulthood.

The team of management might involve genetic counselor, Speech therapeutic, Orthodontist, maxillofacial surgeon, Social worker, Psychologist, Pediatrician, Nurse practitioner, Plastic surgeon, Pediatric dentist, Otolaryngologist and Geneticist. Depending on stage and procedure of repair.

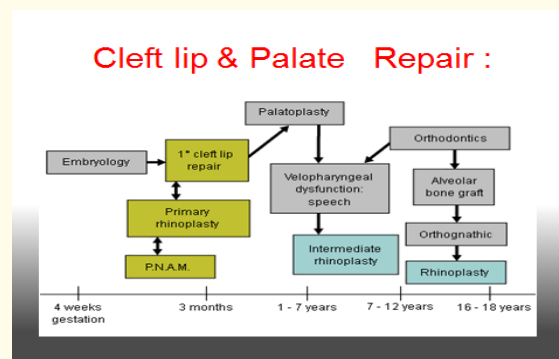


Figure 1

Aim of Study

This is a review article of the alveolar cleft with stress on the various method of repair.

Alveolar cleft is defined as a break in the continuity of the alveolar process, figure 2, usually congenital. It typically occurs with a cleft lip and/or a cleft palate.

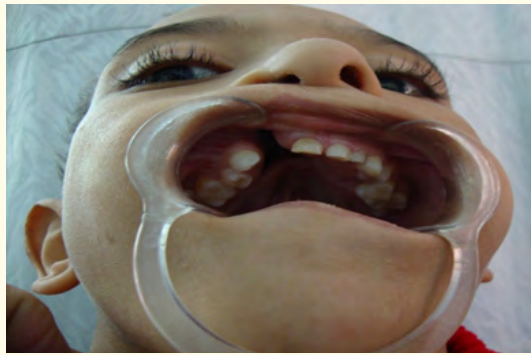

Figure 2

Repair of cleft is mandatory to: [7]

1. Allow production of trabecular bone to unify the maxilla and provide odontogenic support for Stabilization of the maxillary arch.
2. To eliminate the oronasal fistulae with its disturbance to the patient.
3. To create bony support for subsequent eruption of canine
4. To reconstruct of the hypoplastic pyriform aperture and to provide soft tissue nasal base support.

The reparative procedure can be done by [11,12]

1. Bone graft.
2. Cartilage graft.
3. Fat graft (buccal pad of fat).
4. Stem cells.
5. BMP (bone morphogenetic protein).
6. Distraction osteogenesis.

Bone graft:

Types (according to timing)

1. Primary younger than 2 years of age.
2. Early secondary between 5 - 6 years of age [16]
3. Intermediate Secondary between 8 - 10 years of age.
4. Late Secondary more than 10 years of age [4,6,9].

The operations of primary and secondary alveolar cleft grafting represent two methods with similar objectives but vastly different surgical techniques.

While secondary grafting remains by far the most common approach, primary grafting has a smaller but growing number of advocates.

Primary alveolar grafting:

Bone graft done at the time of primary cheiloplasty or bone graft done during the first 2 years of life, bone graft done prior to the eruption of the primary canine, usually done in conjunction with maxillary orthopedics.

Rib grafts placed either simultaneously with lip repair or shortly after.

Largely abandoned due to questions about maxillary growth and development

Aim in primary alveolar grafting:

- Prevention of maxillary arch collapse.
- Migration of teeth into the alveolar process.
- Stabilization of the pre-maxilla in bilateral cases.
- Support for the alar base.
- Early obliteration of the alveolar oronasal fistula eliminates nasal liquid escape and improves oral hygiene.

Gingivo-Periosteoplasty:

- Boneless primary bone graft.
- Relies on the osteoinductive capabilities of the periosteum.

Disadvantages:

- Data suggest that primary bone grafting has a negative effect on maxillary growth and nasolabial appearance.
- May necessitate further bone grafting in childhood due to insufficient alveolar bulk.

Early Secondary Bone Grafting:

- Done before eruption of the permanent lateral incisor
- Usually when the lateral is 1/3 to 2/3 formed.
- Ages 5 - 6.
- Lateral incisor is frequently hypoplastic.

Intermediate Secondary bone grafting: [16]

- Done before eruption of the permanent canine
- At the stage of the transitional dentition when the root of the canine is 1/3 to 2/3 formed.

- Between ages 8 - 10.
- Dental age is usually behind chronological age.

Late Secondary Bone Grafting:

- Done after eruption of the permanent canine
- Usually during adolescence or adulthood
- Sometimes done concomitantly with orthognathic surgery.

Aim in secondary bone grafting:

- Unify the maxilla and create an osseous environment that will support tooth eruption into the arch and allow advancement as one unit
- It is best to attempt to optimize maxillary arch alignment before graft placement.
- This will usually involve varying degrees of transverse maxillary expansion.

Surgical Technique:

- The two nasal mucosal layers medial and lateral are identified and raised with a periosteal elevator from the medial and lateral margins of each bony cleft.
- The nasal floor mucosa is repaired with resorbable sutures at as high a level as possible, which is at the level of what would be a normal nasal floor.

Other Bones:

- Graft harvested from the iliac crest can be either:
- Bone Or
- Ossifying Cartilage figure [11-15]
- Iliac crest / Bone
- Cancellous bone harvested from the anterior iliac crest is condensed into all of the defect [4,5,8]
- If there is a complete alveolar defect with no anterior bony palatal shelf, it helps to insert a finger behind the anterior palate to provide posterior support while packing the bone.
- Cartilage can be also harvested from the anterior iliac crest and used to close the defect (Figure 3-13).

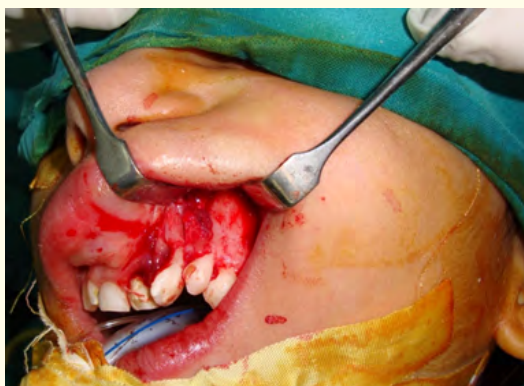


Figure 3: No incision is made of the premaxillary gingival margin medially. The mucoperiosteum should be preserved over the premaxilla in order not to compromise its blood supply.

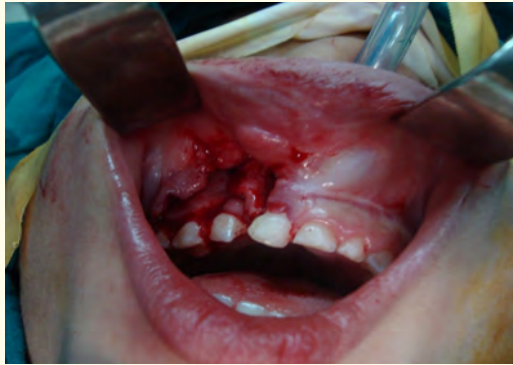

Figure 4: Lateral mucoperiosteal flaps are then raised to expose the alveolar cleft and floor of nose. it is important to separate the oral from the nasal mucosa.

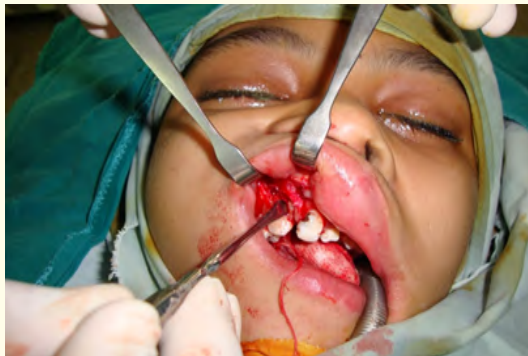

Figure 5: The two nasal mucosal layer (medial and lateral) are identified and raised with a periosteal elevator from the medial and lateral margins of each bony cleft.

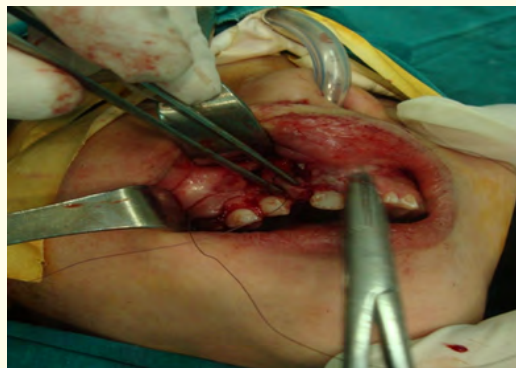


Figure 6: The nasal floor mucosa is repaired with resorbable sutures at as high a level as possible, which is at the level of what would be a normal nasal floor.

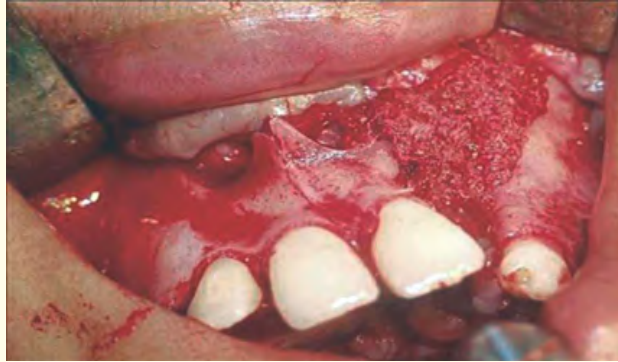

Figure 7: Cancellous bone harvested from anterior iliac crest is condensed into all of the defect.

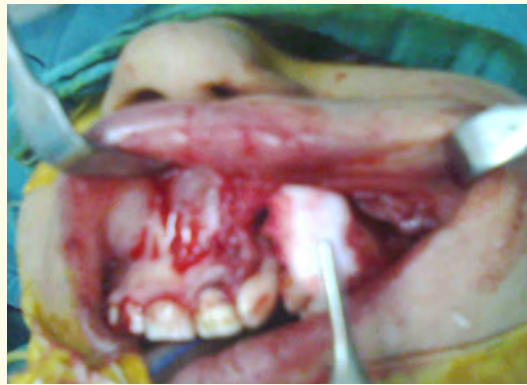

Figure 8: Cartilage can be also harvested from the anterior iliac crest and used to close the defect.

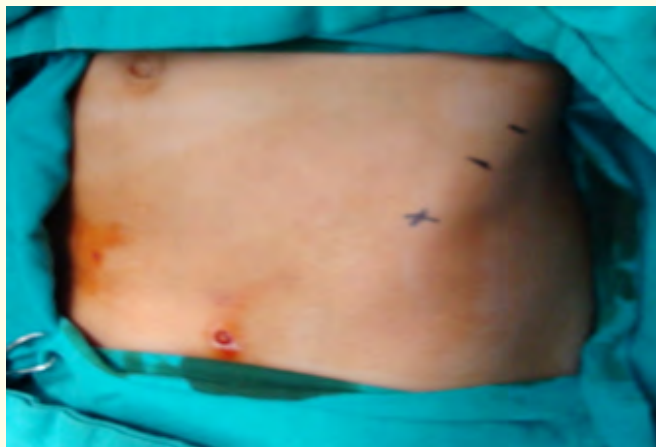


Figure 9: Iliac crest and cartilage harvesting.

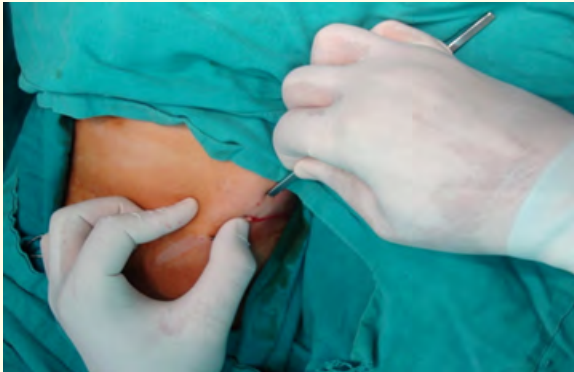

Figure 10

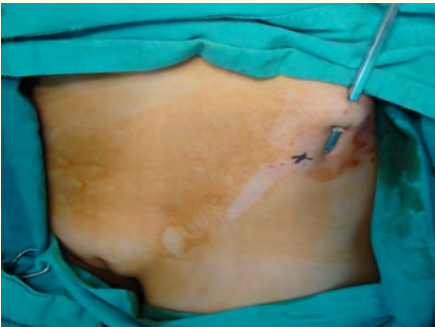


Figure 11

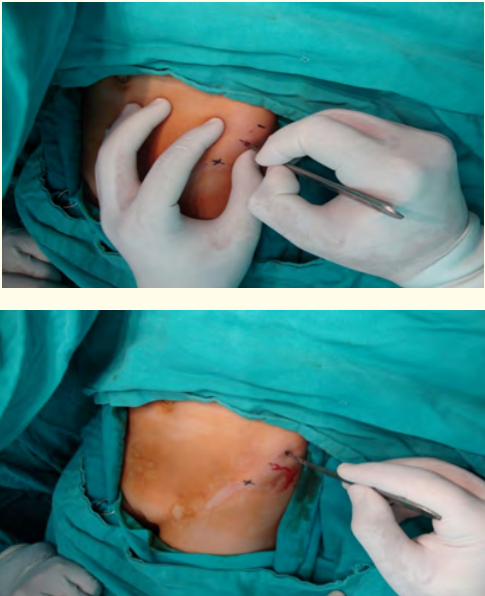

Figure 12a, b

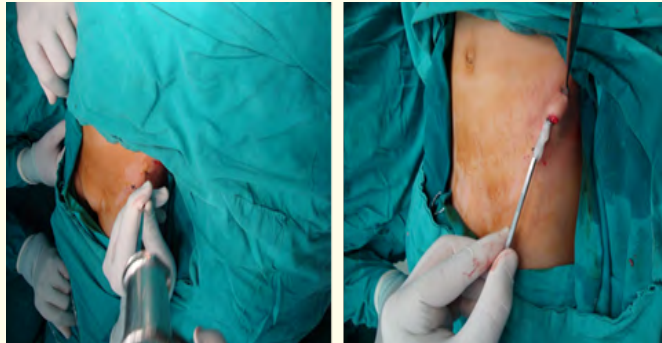

Figure 13a, b

Ribgraft:

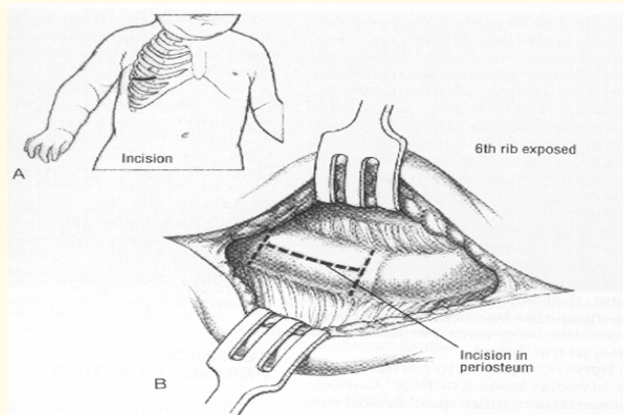


Figure 14: (Primary grafting).

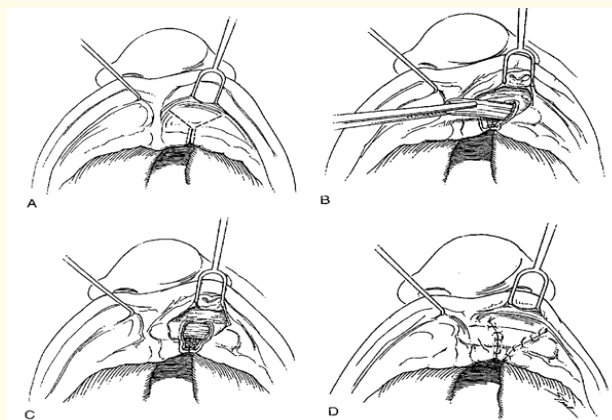


Figure 15: (Primary grafting).

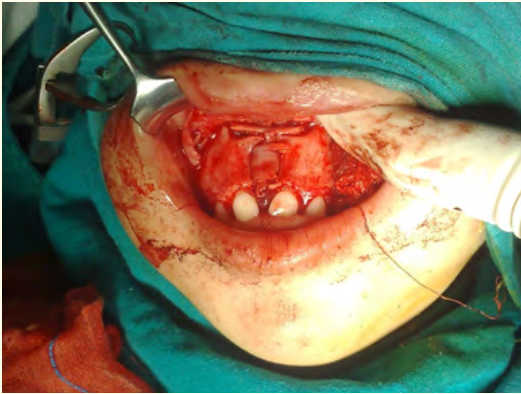
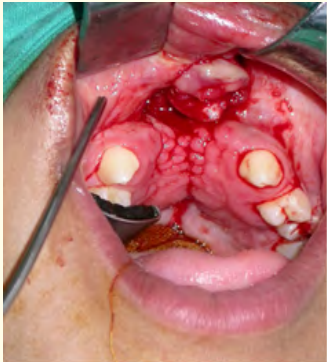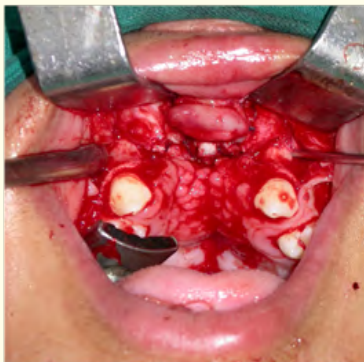


Figure 16: Rib graft.



Alveolar cleft

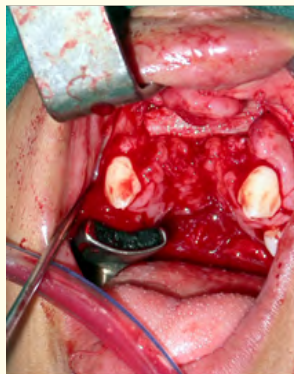


Closure of the nasal layer

Figure 17a, b

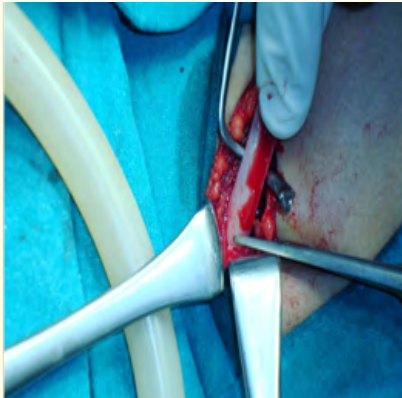
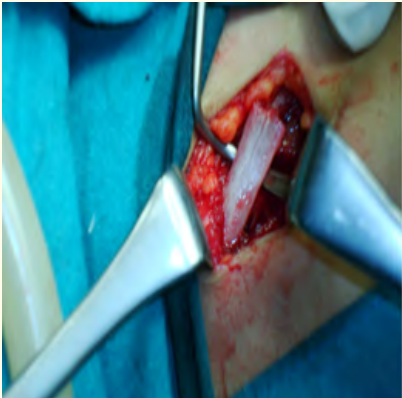
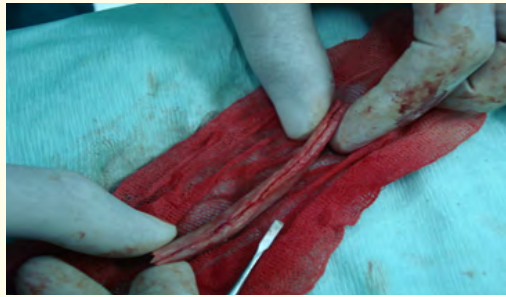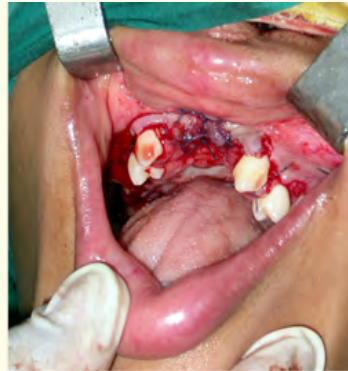Figure 18a, b



Insertion of bone graft



Immediate post-operative

Figure 19 a, b

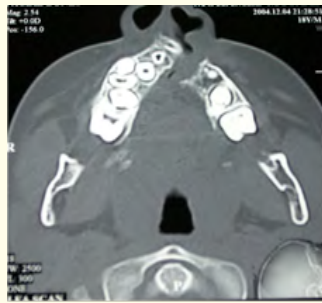- The donor site will reform the rib after 3 months (if taken subperiosteal)
- Easy to perform for experienced surgeons.
- Must be ready to insert a chest tube if pneumothorax (plural tear)
- Medico legal limitations.

Other bone

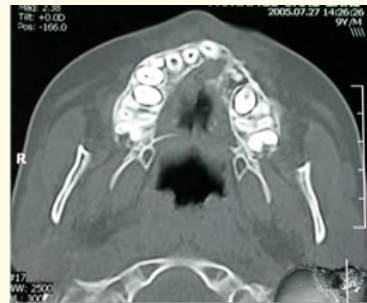1. Calvarium Bone
2. Coronoid Process
3. Menton

Fat (buccal pad of fat) [3]

Controversial aspect some authors claim bone formation others not. (Figure 20-25)



alveolar Axial C.T showing cleft.



Repair with rib graft "3-6 months later" showing complete healing and continuity of dental arch.

Figure 20a, b

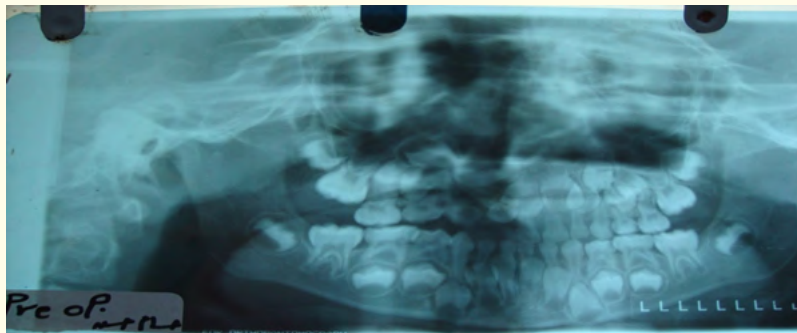


Figure 21

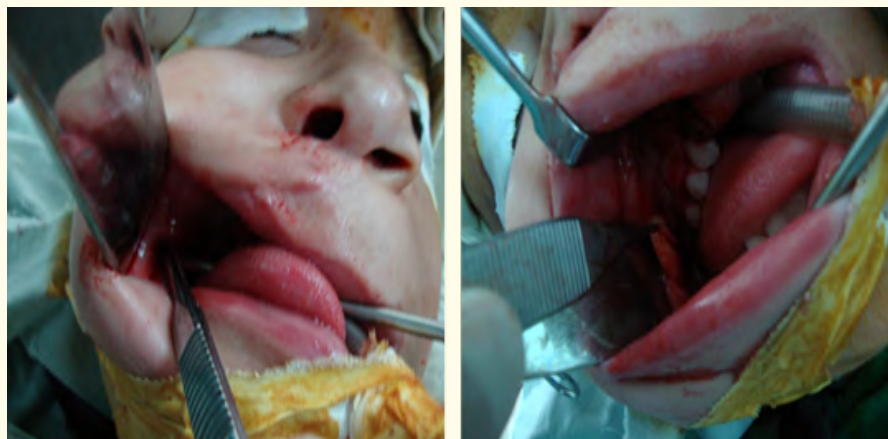

Figure 22

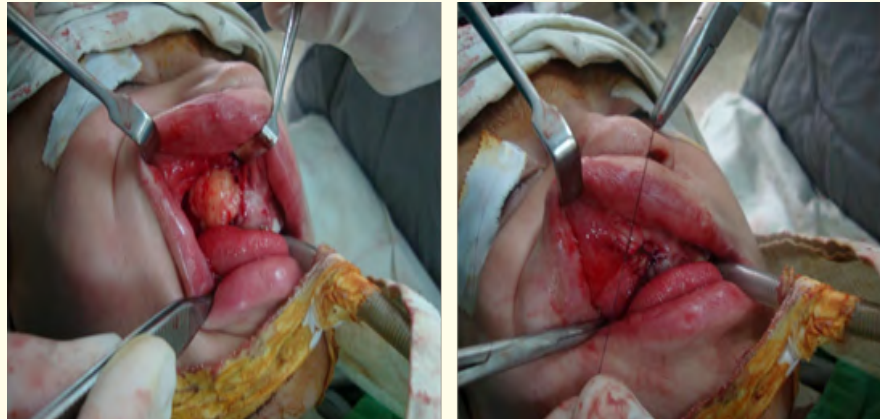

Figure 23

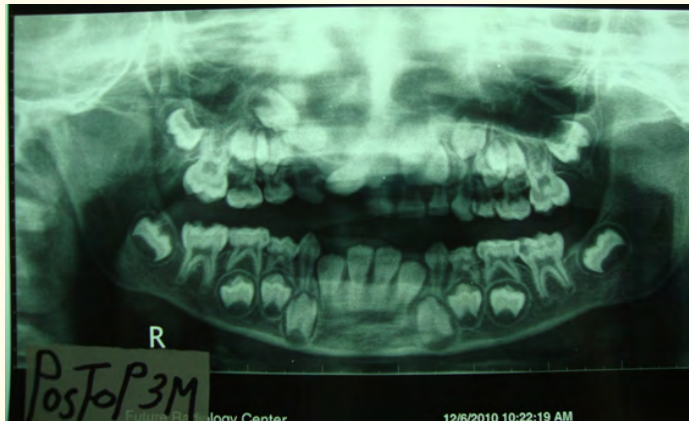

Figure 24

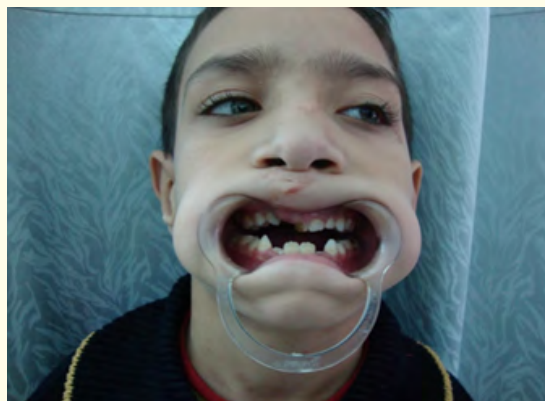


Figure 25

Stem cells: [14]

Types: Figure 26-28

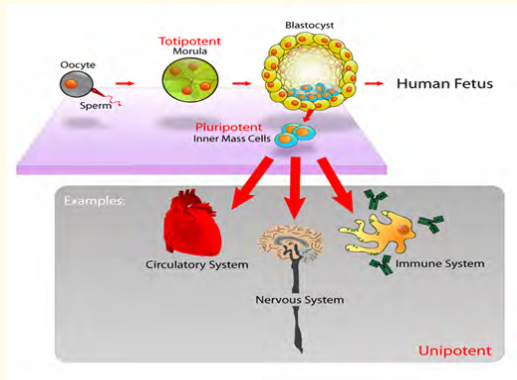


Figure 26

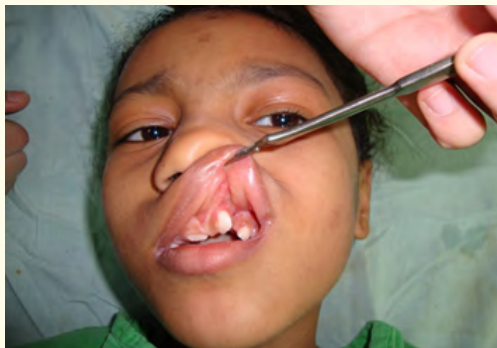

Figure 27

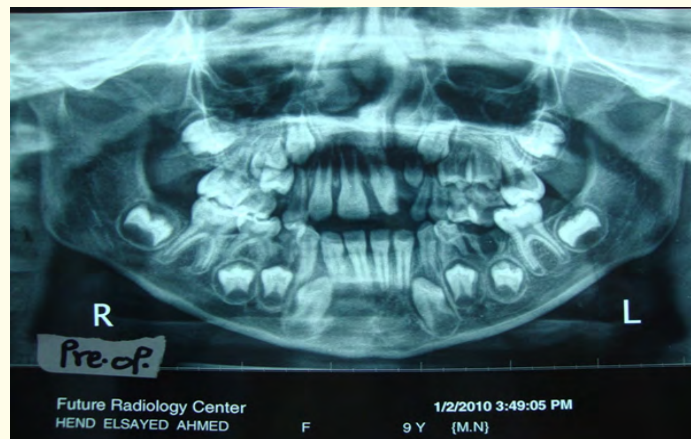

Figure 28

- Totipotent stem cells: can differentiate into embryonic and extra embryonic cell types. Such cells can construct a complete, viable organism.
- Pluripotent stem cells: are the descendants of totipotent cells and can differentiate into nearly all cells
- Multipotent stem cells: can differentiate into a number of cell types, but only those of a closely related family of cells.
- Oligopotent stem cells: can differentiate into only a few cell types, such as lymphoid or myeloid stem cells.
- Unipotent stem cells: can produce only one cell type, their own, but have the property of self-renewal, which distinguishes them from non-stem cells) muscle stem cells

Tissue engineering is defined as:

The regeneration of new tissues through the combined use of biomaterials and biologic mediators, such as the stem cell.

- Stem cells have the capacity for self-renewal and capability of differentiation to various cell lineages. Thus, they represent an important building block for regenerative medicine and tissue engineering.
- The stem cells are typically harvested directly from the red marrow in the iliac crest and mixed with Phosphocalcic hydroxyapatite $Ca_{10}(PO_4)_6(OH)_2$ which is the closest material to bone tissue in terms of its composition and structure Figure 29(a,b)-32(a,b).
- When used to treat alveolar clefts, clear evidence of osteogenesis was found by X-ray examination, and the density of the newly generated bone was comparable to that of normal bones, without visible bounds between the autografts and the normal bones Figure 33,34,35.

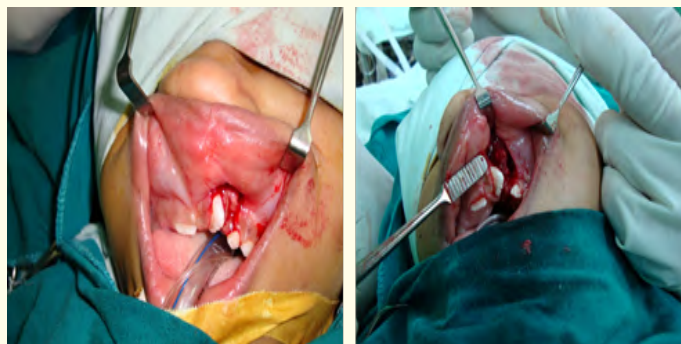

Figure 29a, b.

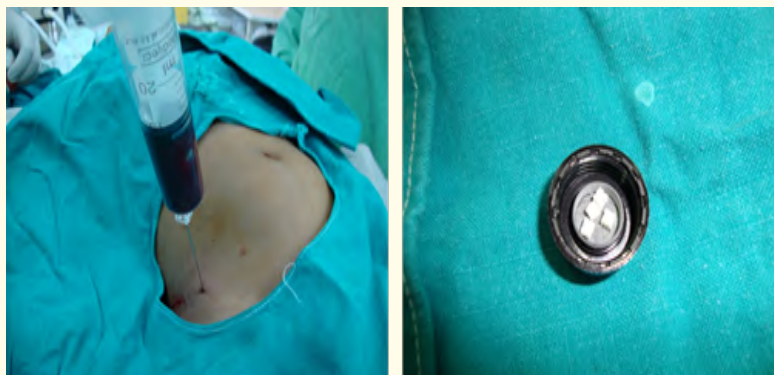

Figure 30a, b.

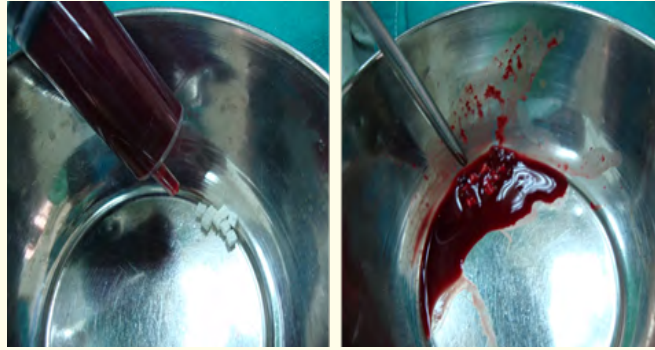

Figure 31a, b.

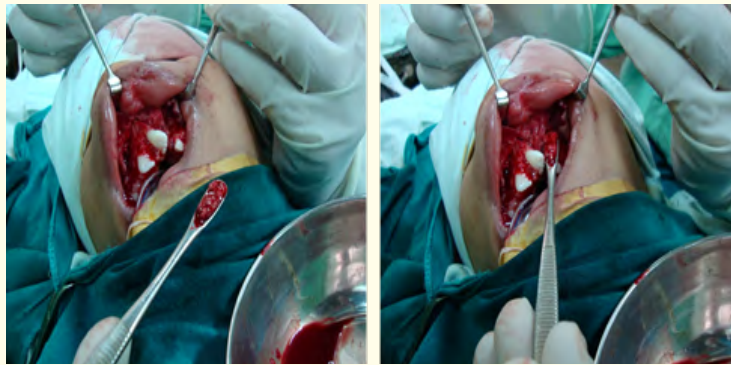

Figure 32a, b.

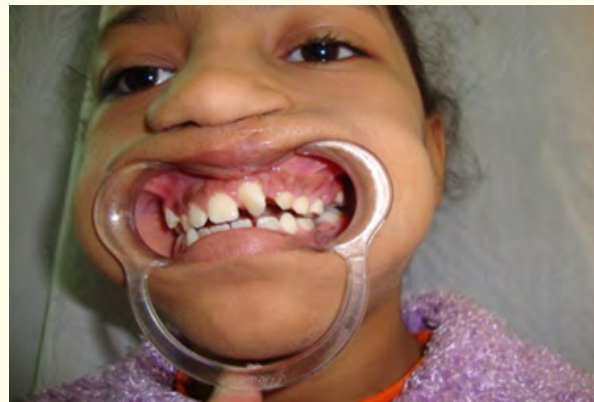

Figure 33.

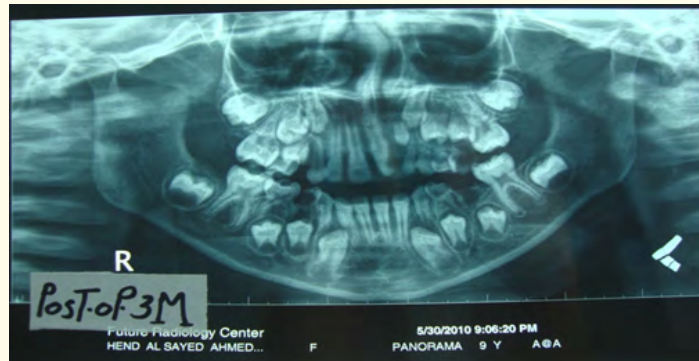

Figure 34.

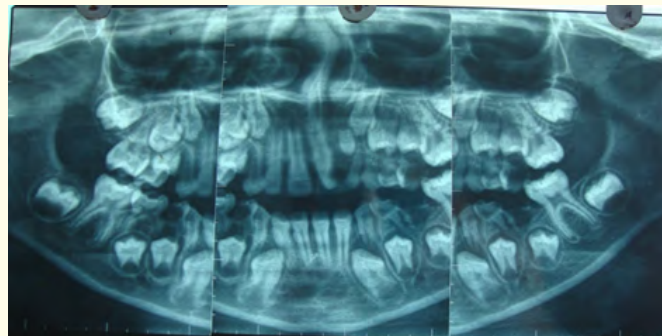


Figure 35.

Bone Morphogenetic Protein: [13,15]

- Stimulates a patient's own cells to induce the formation of bone and cartilage
Recombinant human bone morphogenetic protein-2, or rhBMP-2
- Generates and repairs bone faster and more reliably
- Late in bone growth enhancement

Applications:

- Delivered to the site of the defect
- Released gradually to allow bone formation
- Delivery in a purified collagen matrix
- Osteoinductive characteristics make BMPs valuable as an alternative to bone grafts
- Other methods of delivering BMPs to patients are undergoing evaluation
- Non-skeletal tissues
- Organogenesis

Advantages:

- Less pain, shorter hospital stays
- More rapid return to a normal life.
- As effective as bone grafts.

- Eliminate the need for bonetransplantation.
- Avoids the potential side effectsand complications of bone harvesting or grafts.

Disadvantages:

- BMP has only been FDA approved forone type of spinal fusion
- Expensive
- Side effects are not fullyunderstood

Future:

- Use of BMP will potentially extendbeyond skeletal disease and injury.
- Approval from the FDA to use BMP'sfor dental work.

Distraction Osteogenises:

Figure 36,37,38

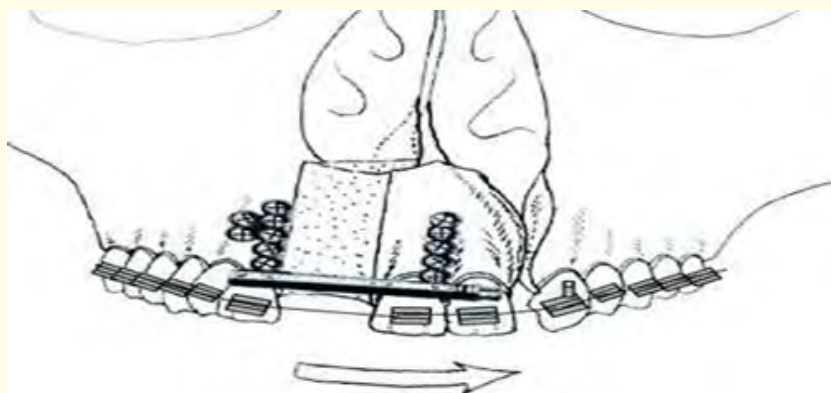

Figure 36

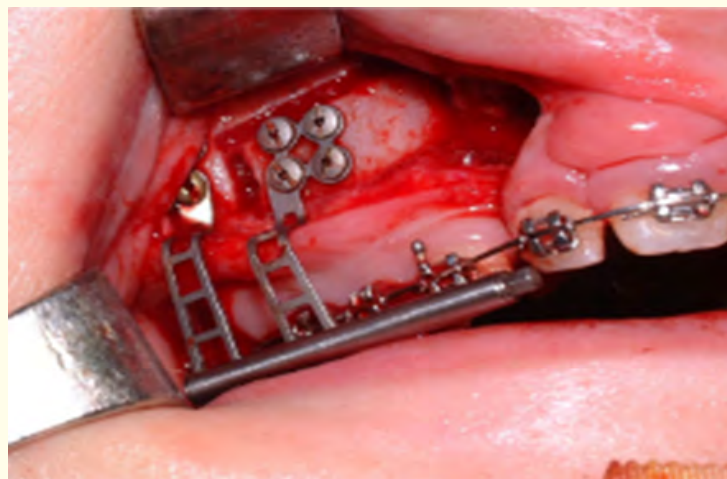


Figure 37

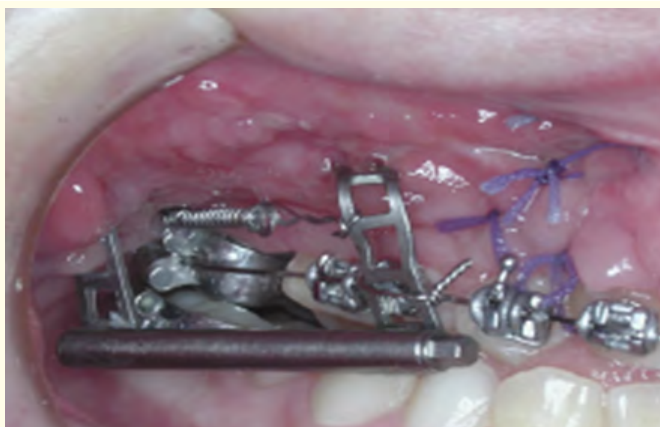

Figure 38

This method is based on distracting a dento-osseous segment created posterior to the cleft site and narrowing the large alveolar defect with mesial movement of this segment.

Alveolar bone is transported in the planned direction using a ready-made bone-borne distractor in combination with an orthodontic arch wire for transport guidance. New alveolar bone and soft tissue can be generated by this technique. The alveolar cleft can be more easily repaired and this makes an ideal soft tissue closure possible using newly generated attached gingiva.

- Distraction allows simultaneous correction of nasal septal deviation and also correction of maxillary arch deformities and malocclusion since the dental arch is expanded without donor sacrifice.
- Distraction can be regarded as tissue engineering to expand bone tissue.
- Distraction can be safely performed not only in patients undergoing initial treatment for alveolar clefts but also in patients in whom bone grafting has failed.

Assessment of Amount of Bone Formed .

Assessment either

Quantitative

Measure the amount of bone formed by

1. X-ray : Plain or Digital CT Figure 39-41.
2. U/S

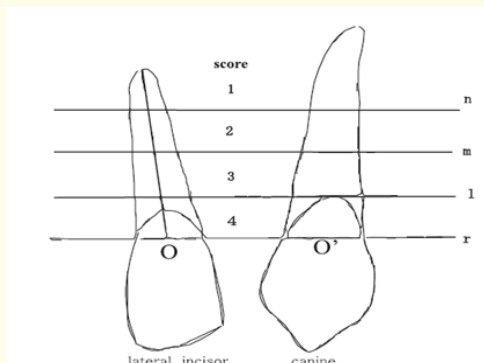


Figure 39

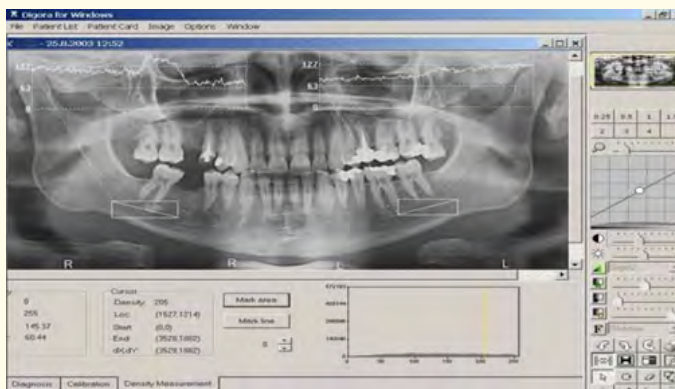

Figure 40

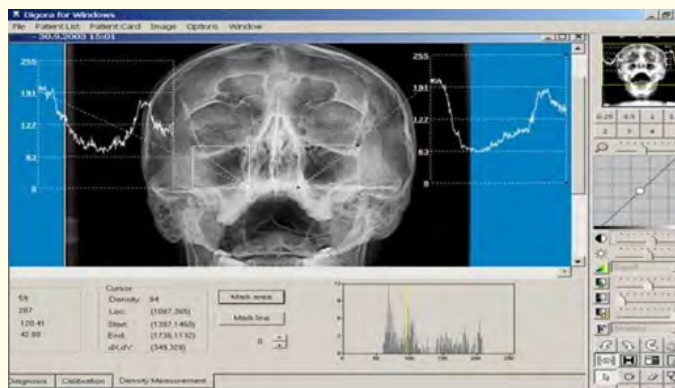


Figure 41

Qualitative:

Densitometry :Quantitative measurement of optical density in light-sensitivematerials, such as Bone.

Dentistometry The scanner itself produces two X-ray beams, One beam. One is high energy and the other is low energy. The amount of energy that can passthrough is dependent on the thickness of the bone.

Bibliography

1. https://en.m.wikipedia.org/wiki/Cleft_palate_incidence_by_population
2. <http://www.cleftline.org/parents-individuals/publications/bonegrafting-the-cleft-maxilla/>
3. <http://www.sciencedirect.com/science/article/pii/S0278239100909194>
4. Boyne PJ and Sands NR. "Secondary Bone Grafting of Residual Alveolar and Palatal Clefts". *Journal of Oral Surgery* 30.2 (1972): 87-92.
5. Johanson B., et al. "A follow up study of cleft lip and palate patients treated with orthodontics, secondary bone grafting and prosthetic rehabilitation". *Scandinavian Journal of Plastic and Reconstructive Surgery* 8.1-2 (1974): 121-135.
6. Abyholm FE., et al. "Secondary bone grafting of alveolar clefts. A surgical/orthodontic treatment enabling a non- prosthodontic rehabilitation in cleft lip and palate patients". *Scandinavian Journal of Plastic and Reconstructive Surgery* 15.2 (1981): 127-140.

7. Turvey TA, *et al.* "Delayed bone grafting in the cleft maxilla and palate: a retrospective multidisciplinary analysis". *American Journal of Orthodontics* 86.3 (1994): 244-256.
8. Bohn A. "Dental anomalies in harelip and cleft palate". *Acta Odontologica Scandinavica* (1963).
9. Ames JR, *et al.* "The autogenous paniculate cancellous bone marrow graft". *Journal of Oral Surgery* 39 (1981): 874.
10. Steedle JR and Proffit WR. "The pattern and control of eruptive tooth movements". *American Journal of Orthodontics* 87.1 (1985): 5666.
11. Albrektsson T. "Healing of bone grafts. In vivo studies of tissue reactions at autografting of bone in the rabbit tibia". Sweden: Thesis, University of Gothenburg (1979).
12. Jackson IT, *et al.* "Bone grafting of the secondary cleft lip and palate deformity". *British Journal of Plastic Surgery* 35.3 (1982): 345-353.
13. Rawashdeh MA and Telfah H. "Secondary alveolar bone grafting: the dilemma of donor site selection and morbidity". *British Journal of Oral and Maxillofacial Surgery* 46.8 (2008): 665-670.
14. https://en.m.wikipedia.org/wiki/Stem_cell
15. Chin M, *et al.* "Repair of alveolar clefts with recombinant human bone morphogenetic protein (rhBMP-2) in patients with clefts". *Journal of Craniofacial Surgery* 16.5 (2005): 778-789.
16. Newlands LC. "Secondary alveolar bone grafting in cleft of the lip and palate patients". *British Journal of Oral and Maxillofacial Surgery* 38.5 (2000): 488-491.

Volume 7 Issue 6 February 2017

© All rights reserved by Ghada ElMorshedy, *et al.*