

## **T-Scan III Computed Guided Occlusal Adjustment in Orthodontic Relapse Patient. The Procedure Description**

**Koval Svitlana\***

*ESLO Active member, AAO Fellow Member, Private practice limited to Orthodontics and TMD, Odessa, Ukraine*

**\*Corresponding Author:** Koval Svitlana, ESLO Active member, AAO Fellow Member, Private practice limited to Orthodontics and TMD, Odessa, Ukraine.

**Received:** December 01, 2016; **Published:** December 06, 2016

### **Abstract**

Orthodontic relapse is considered to have multiple causes. Occlusion is the major factor contributing to orthodontic stability. T-scan III computer guided occlusal analysis is aimed to reveal occlusal contacts that might be the cause of orthodontic relapse. Author's technique of the implementation of T-scan III computer guided occlusal adjustment procedure is described in details.

**Keywords:** *T-Scan III Occlusal Analysis; Orthodontic Relapse; Occlusal Guidance; Excursive Movements; Discussion Time Reduction*

### **Introduction**

Different authors argue on the contributions of different risk factors to orthodontic relapse. Literature on orthodontic relapse and post orthodontic stability endorses different points on risk factors. The main of them are: growth and aging stability [1,2], types of retainers used [3-6], evaluation of airways throughout the orthodontic treatment process [7], TMDs in orthodontic patients [8], and, finally occlusion impact on orthodontic stability [9-11].

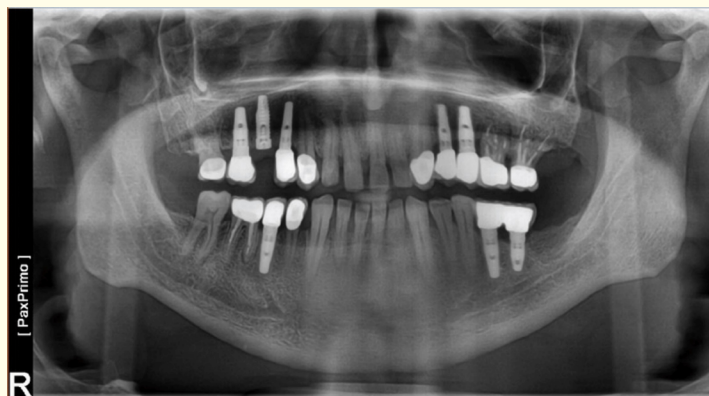Literature considering occlusal factors evaluation focuses on dimensional measuring of the dental arches and has less data on occlusal contact distribution [9]. Other sources [10,11] evaluate predominantly post-treatment occlusal contacts and use adjustment procedures to prevent orthodontic relapse.

Functional occlusion evaluation has been conducted by a group of authors [12], emphasizing the necessity of measuring the excursive movements in orthodontic patients. This issue is confirmed by the recent studies, adding, that Disclusion Time Reduction (DTR) - is one of the major parameters used for the functional occlusal evaluation [13].

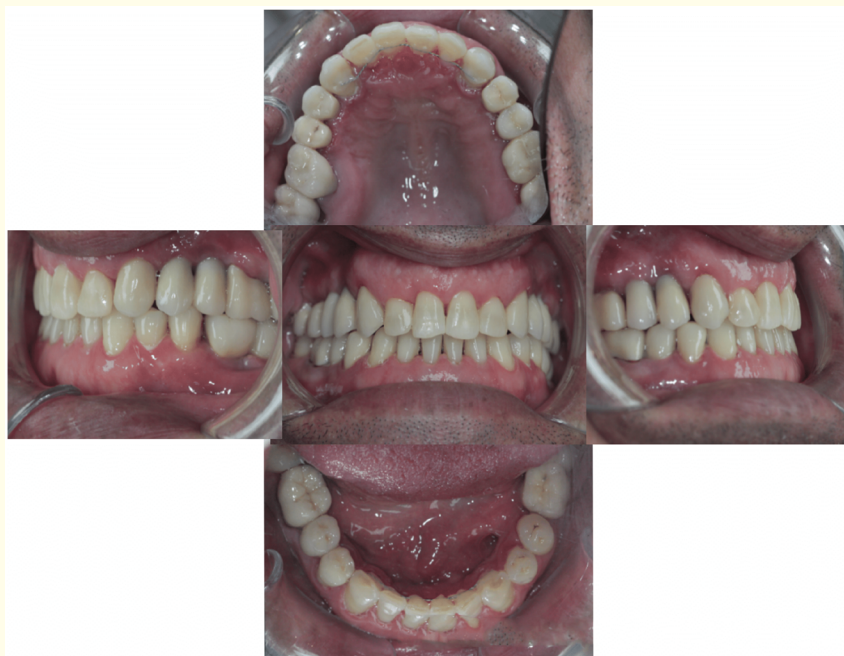This article is aimed to familiarize the reader with the author's technique of using T-scan III computer guided occlusal adjustment procedure in orthodontic relapse patients.

### **Case presentation and procedure description**

Orthodontic treatment of multiple spacing was conducted with the use of lingual bracket appliance. The pretreatment panoramic X-ray is presented in Figure 1. After the completion of treatment non-removable dead twisted stainless steel wire retainers were placed in both jaws (Figure 2). No occlusal analysis was performed after the completion of treatment. The treatment process lasted for 14 months.



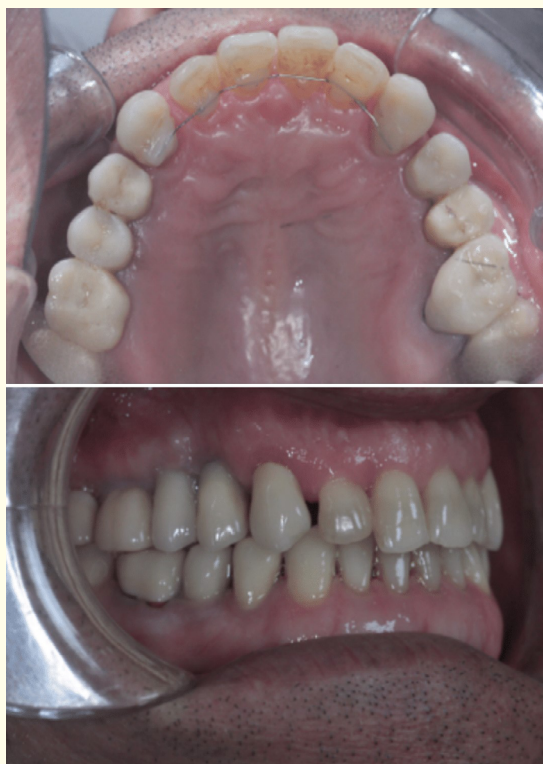**Figure 1:** Panoramic X-ray before treatment.



**Figure 2:** The completion of treatment.

Patient was scheduled for the regular check-ups every 3 months during the year after the completion of treatment.

The first check-up showed deterioration of orthodontic stability causing partially anterior spacing to retrieve (Figure 3). T-scan III occlusal analysis was performed on this stage to check the occlusal balance and the distribution of occlusal contacts along the dental arches. For this purpose, several standard occlusal recordings were made. The standard analyzing sequence, implemented in our practice, is: centric occlusion recording, multi-bite recording, left and right lateral excursions.



**Figure 3:** Relapse after 3 months in retainers.

The screenshot of the first centric occlusion recording is shown on the figure 4. Distribution of the occlusal contacts along the dental arch is poor, resulting in overforcing the posterior teeth. No contacts are seen on the front teeth, with no or little contacts at the premolar area.

The centric occlusal record is aimed to analyze several parameters: 1) the overall side balance (right-left side balance, %), 2) the distribution of the contacts, with the emphasis on those teeth that undergo the highest forces (3D -diagram, showing force distribution in colors, red and purple are the highest forces); 3) the occlusal time A1-B1 - the time of teeth coming together in centric occlusion ( the time is said to be not more than 0,3 sec)(14); and 4) the trajectory of the closing path (shown in a red track, starting outside the grey target. T-scan III computer guided occlusal adjustment was performed in several steps. Once the overforced contact was found on the tooth 3, it was eliminated. The position of the contact is checked via occlusal paper marks in the mouth (Arti-Tec, 15mkm, Bausch, Germany) (Figure 5). These occlusal paper marks are shown in Figure 6. After the several rounds of occlusal adjustment, occlusal contacts appeared more visible on the premolar area and no overforced contacts remained on the tooth 3 or others (Figure 7).

The excursive movements were analyzed during the next appointment, when right and left excursions were recorded. Figure 8 shows the right excursive movement made by the patient. The typical excursive movement diagram (as shown at the bottom) has several colored lines, each of them corresponding to its arch quadrant. Thus, right excursive movement should be concluded by the red line, as tooth #6 is situated in the red quadrant according to the T-scan III software. The diagram shows prevalence of the posterior right quadrant during the right laterotrusion resulting in the disclusion time (DT) being more than 0.5 sec. Disclusion time reduction (DTR) is one of the major goals in achieving a well-balanced occlusion.

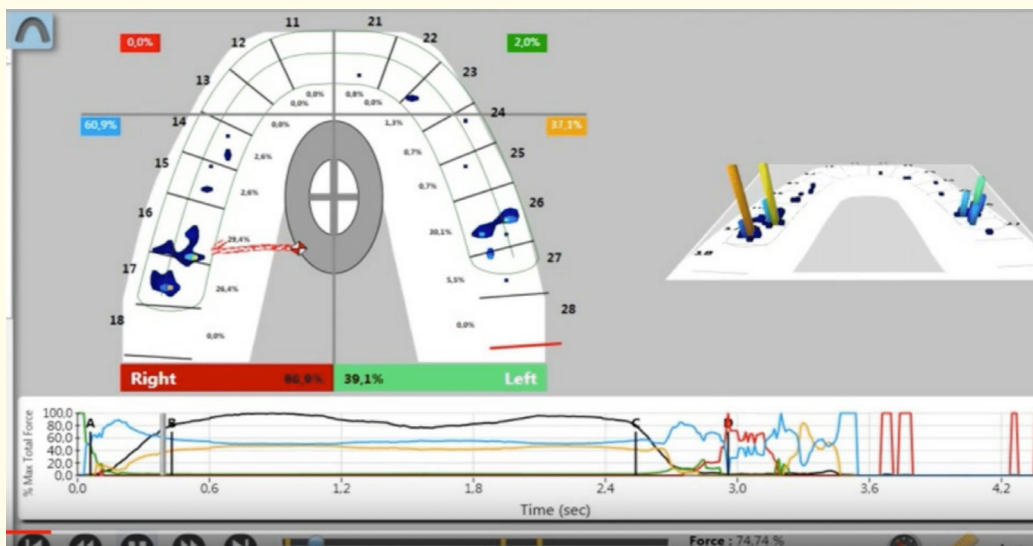


Figure 4.

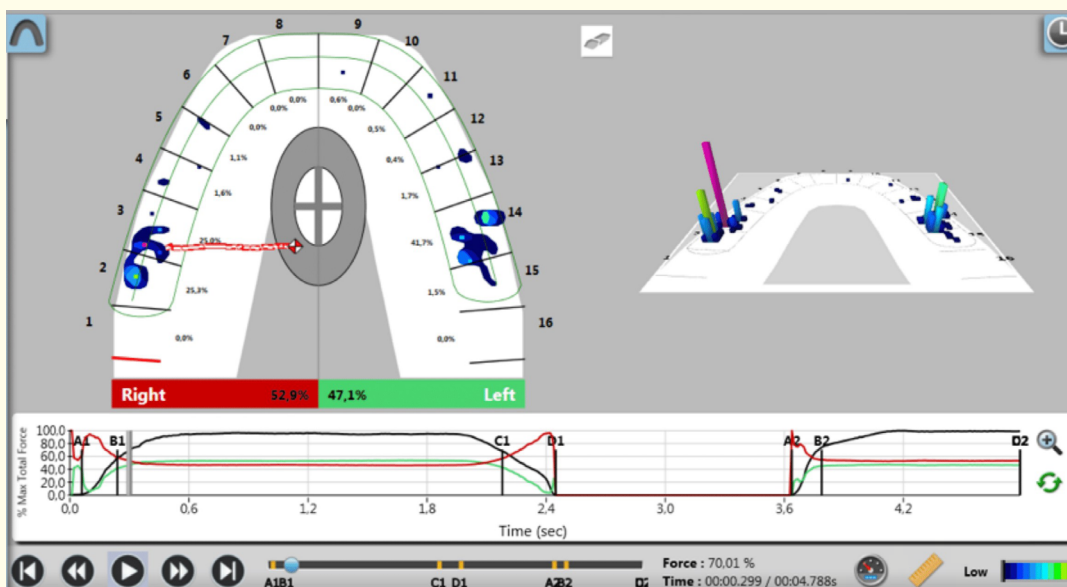


Figure 5.

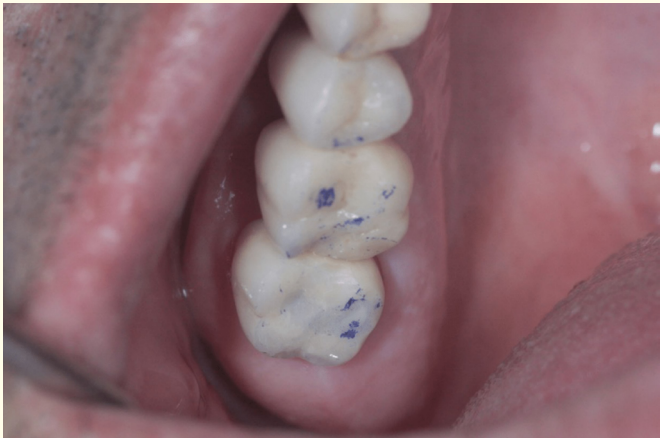

Figure 6.

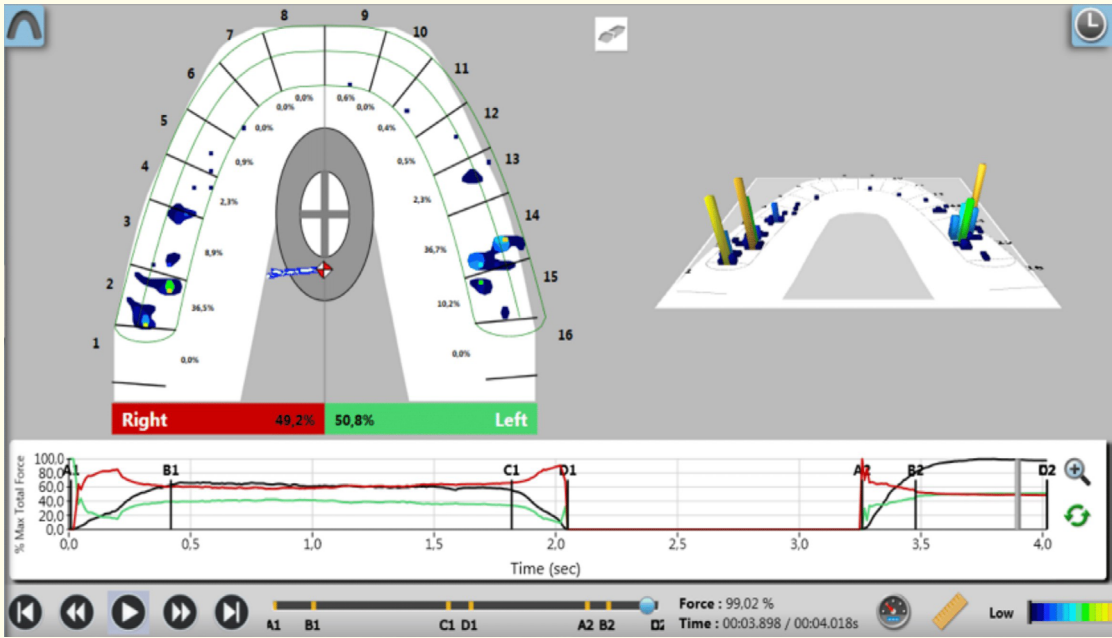


Figure 7.

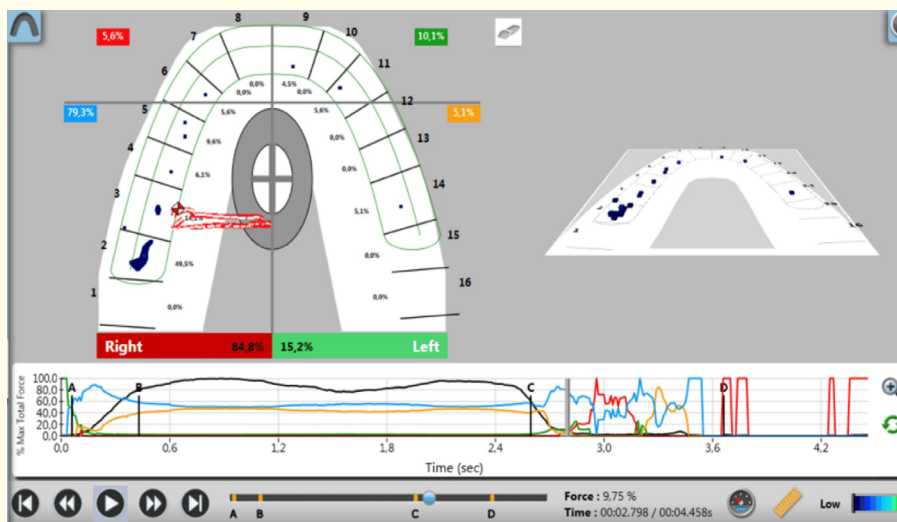


Figure 8.

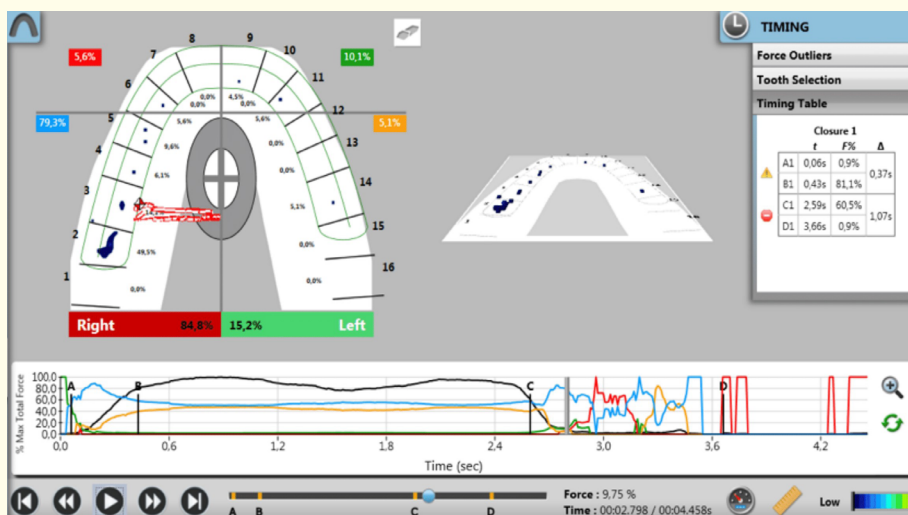


Figure 9.

Figure 10 shows the distribution of contacts along the upper dental arch during the right laterotrusion. During the period C1-D1 - the disclusion period - one contact is the highest one - the contact on the tooth 2 (almost 60% of force) and the additional contact, that should be the major one, is on the tooth 6 (exhibiting 21% of overall force). The intraoral occlusal paper marks are shown in the figure 11.

After balancing the right excursive movement, the left one was also checked (Figure 12). DT is heading towards the normal values (0.56 sec), resulting in a green quadrant with the tooth 11 to be prevalent.

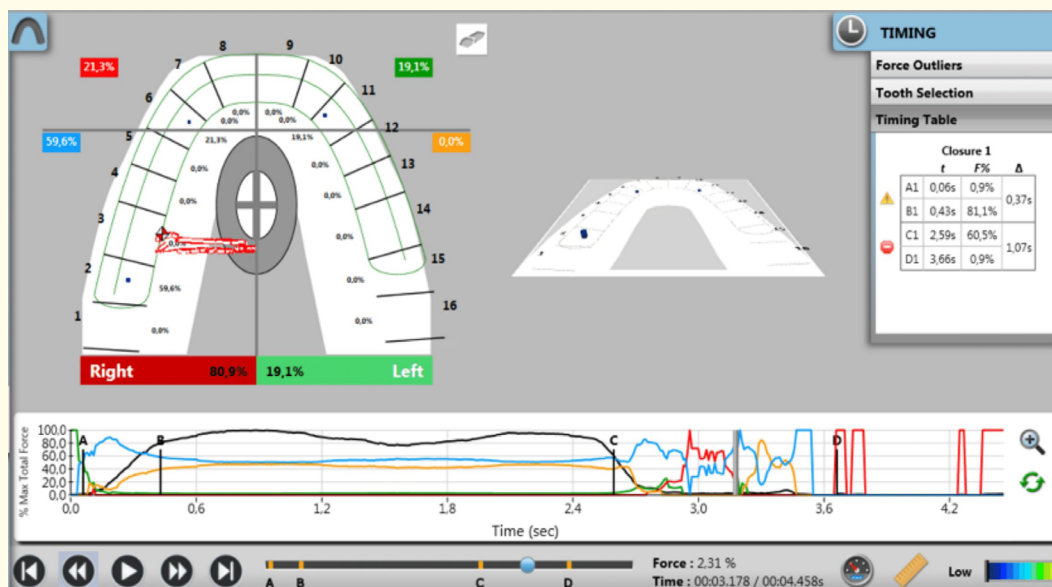


Figure 10.

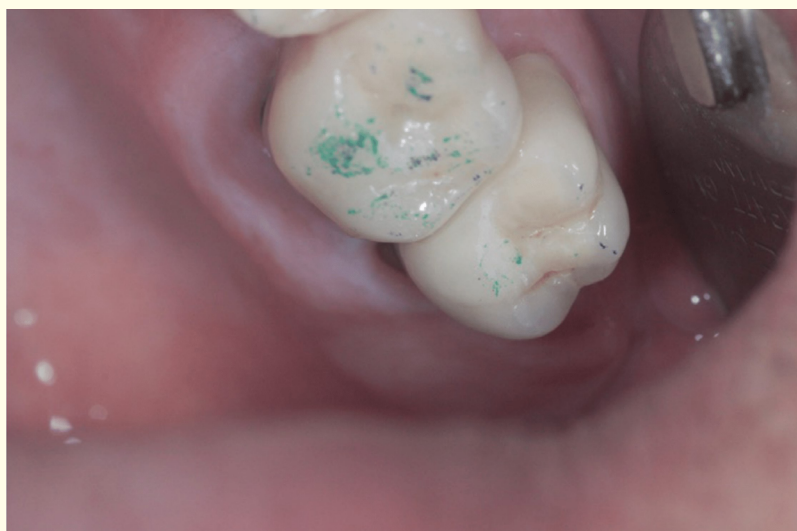

Figure 11.

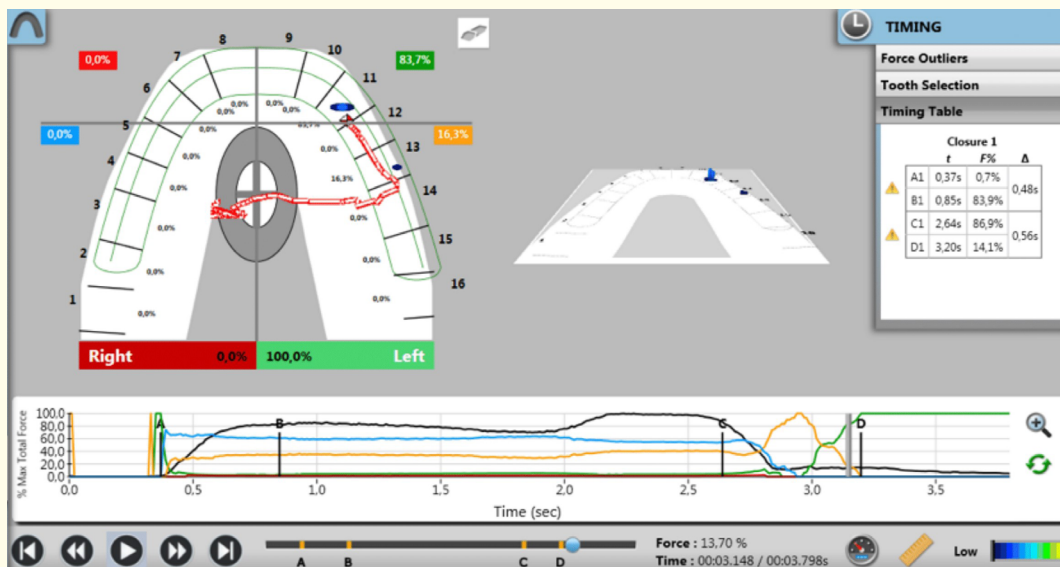


Figure 12.

After eliminating the excursive contacts on the teeth 2 and 3 in right excursive movement, canine guidance was finally achieved (Figure 13,14).

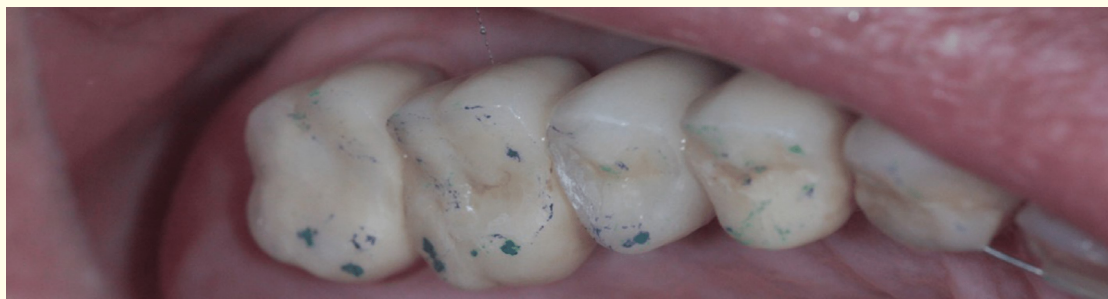

Figure 13.

The patient was left without upper retainer of any kind for three months.

On the next appointment, no spacing was found between teeth 6 and 7. The multi-bite recording was made (Figure 15). Lateral excursive movements were checked (Figure 16, 17, 18).



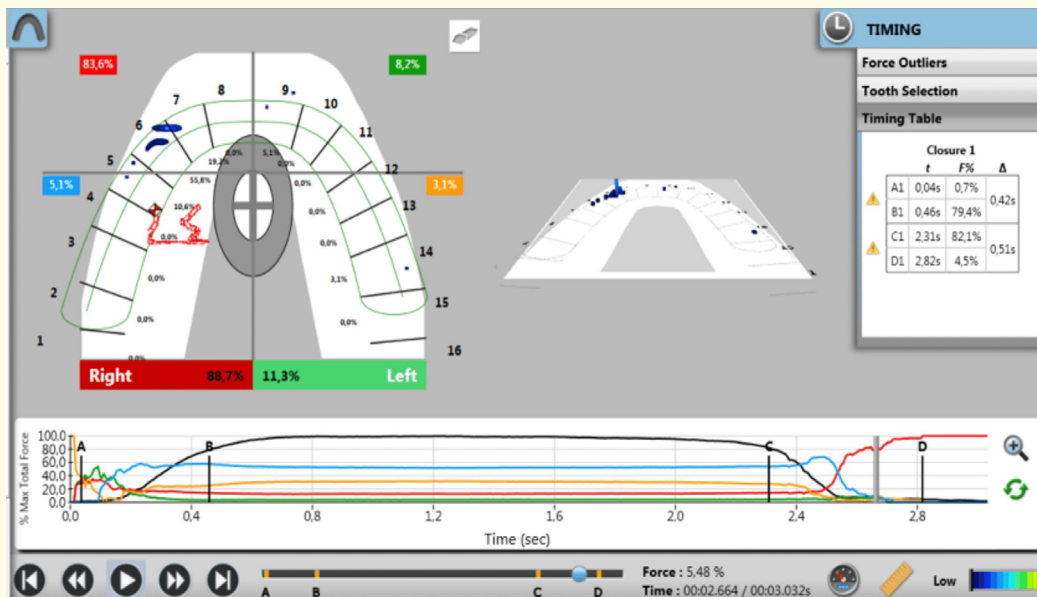


Figure 14.

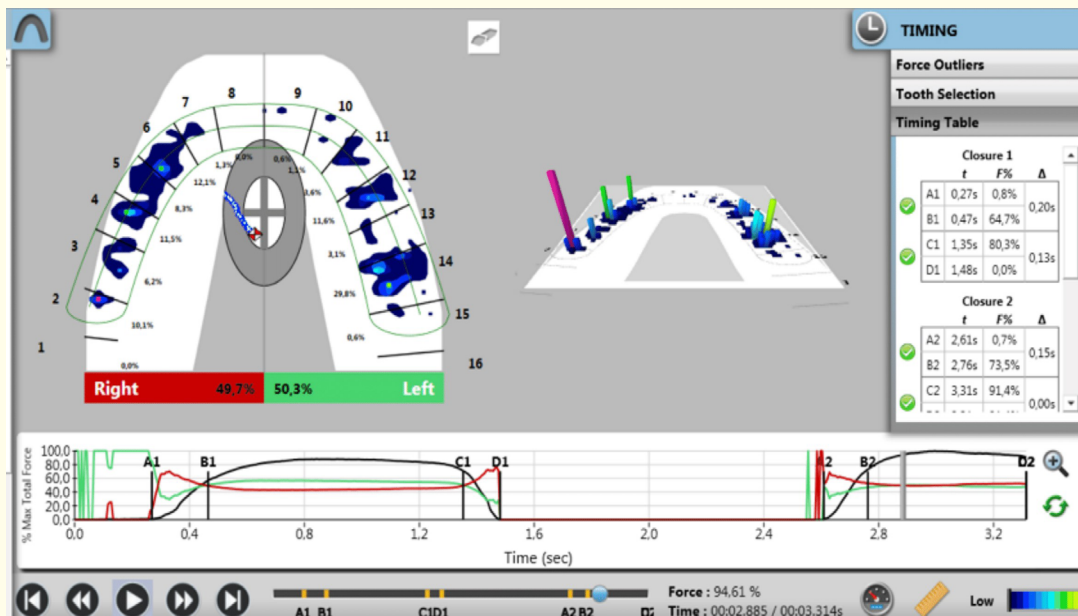


Figure 15.

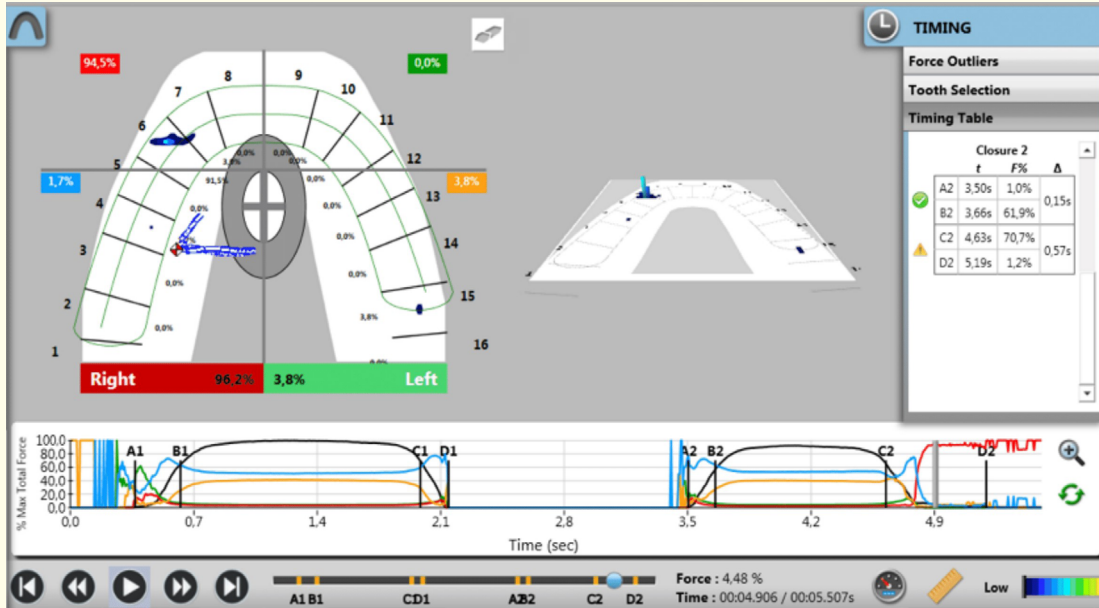


Figure 16.

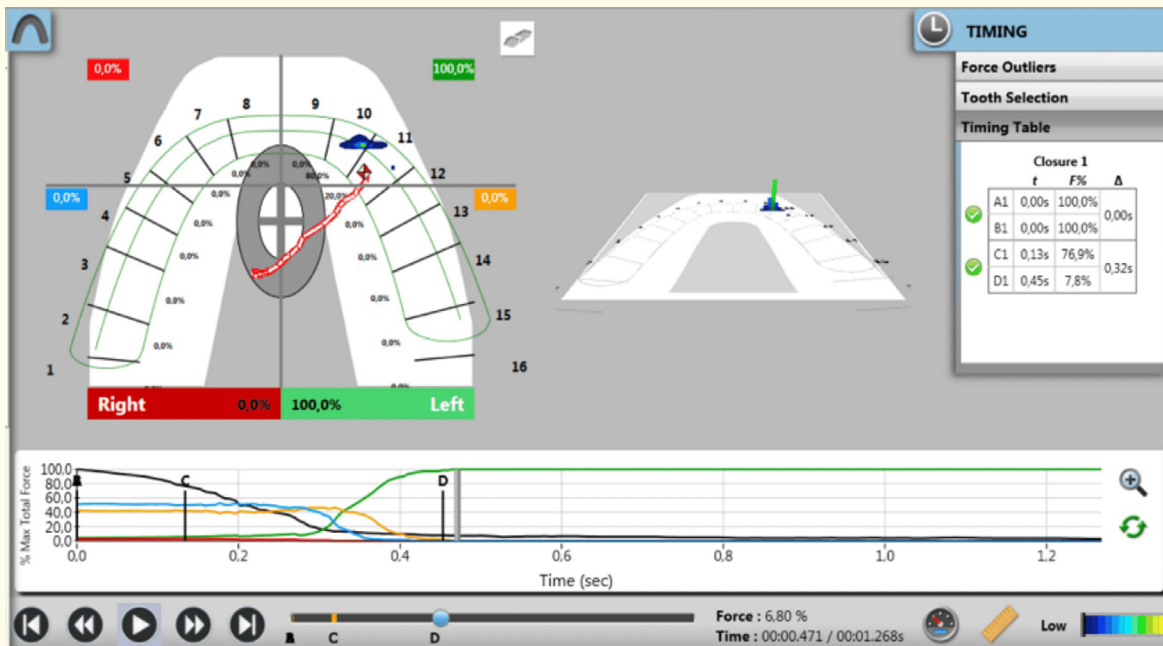
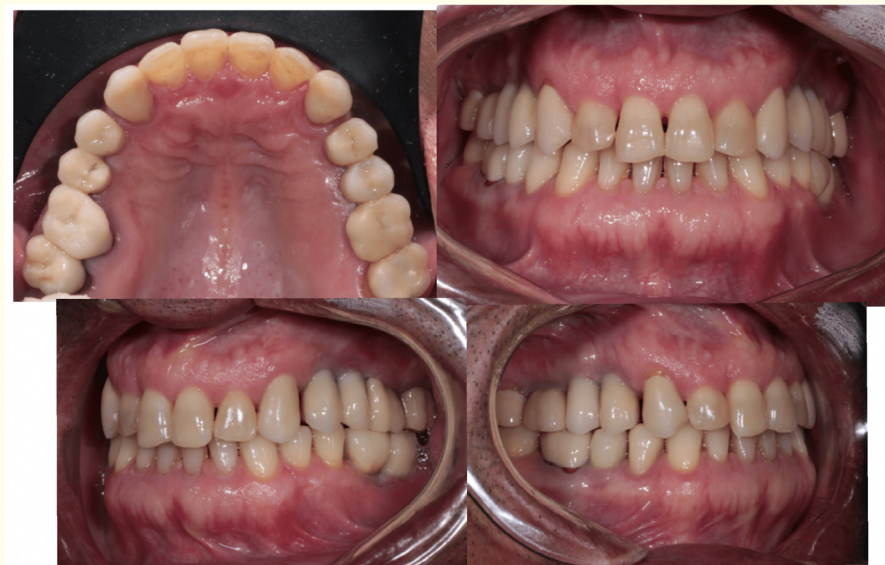

Figure 17.



**Figure 18.**

## Discussion

Many authors argue about the factors contributing to orthodontic result stability. The main points are occlusion and the type of retention appliance. As stated above, this article presents the author's technique of occlusal analysis with the T-scan III occlusal analysis system used in prevention and quick correction of orthodontic relapse.

The presented case shows the implementation of the T-scan III computer guided occlusal adjustment procedure in elimination of the orthodontic relapse. The computed guided occlusal adjustment had the main impact on retrieving the contacts between the upper front teeth and elimination of spacing in that area.

The authors procedure of conducting the T-scan III computer guided occlusal adjustment comprises of several steps. The main aspect is the T-scan III occlusal analysis before the adjustment. The following records are taken on a regular base: multi-bite recording, centric occlusion recording, left and right laterotrusive recordings. Each recording is analyzed separately.

The centric occlusion recording shows the right/left side occlusal balance. It also shows contact distribution along the dental arch. The main aspect to pay attention in this recording is the presence of the contacts with more than average force, pointed in red and purple colors in 3D-diagram of the dental arch.

The multi-bite recording is aimed to track the A1-B1 time periods - occlusion time - the time of teeth coming together.

Lateral excursive movements are checked for the presence of excursive contacts that prolong the disclusion time. Moreover, the distribution of the contacts during the prolonged disclusion points on the areas where spacing may reoccur.

## Conclusion

Occlusion is one of the major contributing factors to orthodontic relapse. Occlusion should be analyzed thoroughly seeking for the excursive contacts that prolong the disclusion time and contribute to anterior teeth movements. T-scan III computer guided occlusal adjustment procedure shows dramatic impact on orthodontic retention.

## Bibliography

1. De Bernabé PG, et al. "Orthodontic treatment stability predictors: A retrospective longitudinal study". *Angle Orthodontist* (2016).
2. Oualalou Y, et al. "Residual craniofacial growth: A cephalometric study of 50 cases". *International Orthodontics* (2016).
3. Schütz-Fransson U, et al. "Twelve-year follow-up of mandibular incisor stability: Comparison between two bonded lingual orthodontic retainers". *Angle Orthodontist* (2016).
4. Brezulier D, et al. "A Protocol for Treatment of Minor Orthodontic Relapse During Retention". *Journal of Esthetic and Restorative Dentistry* (2016).
5. Shaughnessy TG, et al. "Inadvertent tooth movement with fixed lingual retainers". *American Journal of Orthodontics and Dentofacial Orthopedics* 149.2 (2016): 277-286.
6. Littlewood SJ, et al. "Retention procedures for stabilising tooth position after treatment with orthodontic braces". *Cochrane Database Systematic Reviews* 29.1 (2016): CD002283.
7. Riepponen A, et al. "Changes in posterior airway space and hyoid bone position after surgical mandibular advancement". *Acta Odontologica Scandinavica* 10 (2016):1-6.
8. J Mitsui SN, et al. "Long-term stability of conservative orthodontic treatment in a patient with temporomandibular joint disorder". *Journal of Orthodontic Science* 5.3 (2016): 104-108.
9. Shishkin KM, et al. "Stability of orthodontic correction: preconditions of relapses caused by occlusal forces". *Stomatologiia (Mosk)* 95.5 (2016): 47-50.
10. Duan YZ, et al. "[Orthodontic retention and adjustment of the occlusion after orthognathic surgery]". *Hua Xi Kou Qiang Yi Xue Za Zhi* 29.2 (2011): 173-174, 178.
11. Janson G, et al. "Stability of anterior open-bite treatment with occlusal adjustment". *American Journal of Orthodontics and Dentofacial Orthopedics* 138.1 (2010): 14.e1-7.
12. Qadeer S, et al. "Prevalence of excursive occlusal force parameters in post-orthodontic and non-orthodontic subjects using T-Scan@ III". *Cranio* 23 (2016): 1-8.
13. Kerstein RB and Radke J. "Average chewing pattern improvements following Disclusion Time reduction". *Cranio* (2016): 1-17.
14. KersteinRB. "Handbook of Research on Computerized Occlusal analysis Technology Applications in Dental Medicine". *IGI Global* (2015).

**Volume 6 Issue 2 December 2016**

**© All rights reserved by Koval Svitlana.**