

## Ultrastructure of Human Dental Pulp in Hepatitis C Virus Patients

Lobna RS Radwan<sup>1</sup>, Ahmed Shteivi<sup>2</sup> and Yousry M EL-Hawary<sup>1\*</sup>

<sup>1</sup>Department of Oral Biology, Faculty of Dentistry, Mansoura University, Egypt

<sup>2</sup>Dentist at ministry of health and population, Mansoura, Egypt

**\*Corresponding Author:** Yousry M EL-Hawary, Department of Oral Biology, Faculty of Dentistry, Mansoura University, Egypt.

**Received:** November 20, 2016; **Published:** November 30, 2016

### Abstract

**Introduction:** Hepatitis C virus (HCV) is a serious worldwide disease. The virus is small about 500A°, can be seen by transmission electron microscope. It consists of core of RNA surrounded by capsid. Transmission of the virus is through blood and blood products by using unsterilized or inadequately sterilized equipment. This study aimed to investigate the ultrastructure of human dental pulp in HCV infected and treated persons by transmission electron microscope.

**Methods:** Five freshly extracted human teeth were obtained; two teeth from two unique HCV patients, two teeth from two patients treated from HCV, and one tooth from normal person. Each tooth was opened by Hand-Held Pulp Isolator. The pulp was taken and processed for transmission electron microscope.

**Results:** Transmission electron microscope investigation revealed disorganized pulp tissue, presence of lipid droplets, autophages, collapsed capillaries, altered mitochondria and multiple HCV like particles in the perinuclear area of human dental pulp cells.

**Conclusion:** The HCV cases highlight the presence of HCV like particles in the human dental pulp which endangers pulp tissue and multiply the importance of dental equipment sterilization to avoid virus transmission.

**Keywords:** Hepatitis C Virus (HCV); Human Dental Pulp; Transmission Electron Microscope

### Introduction

The liver the largest digestive gland in the human body is the center of energy metabolism. It has an important role in regulating inflammation by its capacity to secrete a number of proteins that control both local and systemic inflammation. Hepatitis is a condition of liver inflammation [1,2].

Hepatitis C virus (HCV) infection is a serious public health problem. HCV infection is a worldwide disease affecting 185 million people, with an estimated prevalence of 2.8%. New infections continue to occur and morbidity is increasing involving a variety of extra hepatic conditions including oral regions [3,4].

HCV development of both liver-limited injury (fibrosis, cirrhosis and hepatocellular carcinoma) and extrahepatic HCV related diseases (atherosclerosis, cardiovascular, lympho-proliferative and brain disease, neuropsychiatric disorders have been reported up to 50% of chronic HCV [2,5-8]. The oral cavity can reflect the liver dysfunction in the form of mucosal membrane jaundice, bleeding disorders, petechiae, gingivitis, gingival bleeding even with minimal trauma, smooth and atrophic tongue, xerostomia and other dental symptoms [3].

HCV infection may result from viral transmission by blood or blood product, as a result of sexual contact or perinatal transmission.

Incubation period is 15 - 150 days. Only 15 - 30% will have self-limited case with spontaneous immune-mediated clearance. Seventy per cent of acute infection is asymptomatic. The rate of chronicity of HCV is 50 - 90%. Treatment is very important not only because it leads to further serious sequelae but also as HCV viremia has a risk for transmission to other persons and it can have significant social, legal and economic sequences especially for infected members of the health care systems. Various drugs have been approved for HCV treatment [9,10].

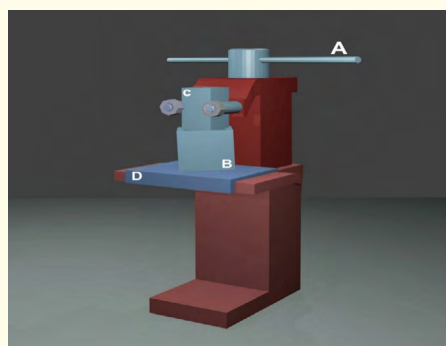
Viruses are small and most of them can be seen by transmission electron microscope. All viruses have at least 2 parts, an outer capsid (shell) composed of protein subunits surround the inner core of either DNA or RNA, but not both. Viruses reprogram the host cell to produce new virions. For the direct study of the different steps of the viral life cycle (attachment, entry, replication, assembly and egress) electron microscopy methods are valuable as the small size of viruses. HCV virions have a rather uniform size of 500Å [11-13].

The dental pulp is a specialized connective tissue located within rigid dentinal walls. It has a network of blood vessels and number of myelinated and non-myelinated nerves. It is essential for the vitality of the tooth and formation of dentin [14]. There are few available researches about the effect of HCV on the human dental pulp by light microscope but there are no available researches-as yet- about its effect by transmission electron microscope. So, this study was aimed to investigate the available changes in the human dental pulp of HCV infected and treated persons by transmission electron microscope.

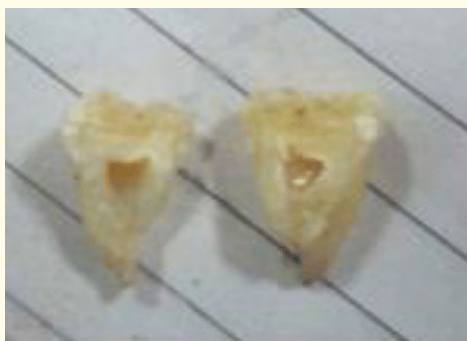### Material and Methods

Five freshly extracted human permanent molar teeth were obtained from the department of oral and maxillofacial surgery, Faculty of Dentistry - Mansoura University, Egypt. Two teeth from two unique chronic HCV patients, two teeth from two patients treated from HCV by Pegylated Interferon Alpha 2B150 MCG/week for 48 weeks and, Ribavirin 1200 mg/day for 48 weeks from two years ago, and one tooth from normal person. Informed consents were taken in accordance with the Helsinki Declaration of 2013. All these persons were aged from 40 - 50 years.

Each tooth was kept in sterile normal saline in a closed bottle; each tooth was washed by saline and immediately opened by Hand-Held Pulp Isolator (Figure 1) (Shteiwi. A device, patent pending No. PCT/ EG2015 / 000026) which opened the tooth into two equal halves (Figure 2) without heat generation. This device was designed to avoid any changes in the pulp caused by heat generation from rotary instrument and decalcification of the tooth.



**Figure 1:** Showing Hand-Held Pulp Isolator “first edition”  
A. force delivering unit; B. the container; C. the splitter; D. the supporter.



**Figure 2:** Molar tooth after cutting by Hand-Held Pulp Isolator "first edition".

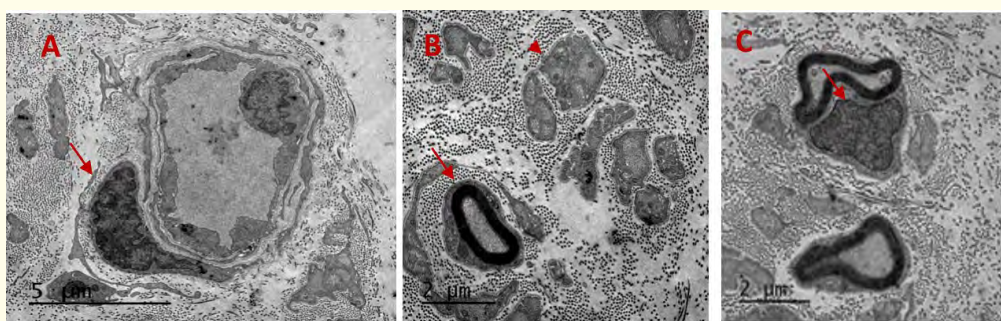
The pulp was taken and processed for transmission electron microscope in the following steps:

Fixation of the pulp using solution from: 2.5 % buffered glutaraldehyde + 2 % paraformaldehyde in 0.1M sodium phosphate buffer pH 7.4 and the pulp was left overnight at 4°C, washed in 0.1M sodium phosphate buffer + 0.1M Sucrose.

Post fixed in 2 % sodium phosphate buffered osmium tetroxide pH 7.4, washed in 0.1 M sodium phosphate buffer pH 7.4, then dehydrated by 50% ethanol (in distilled water), contrasted overnight using 70% acetone + 0.5% uranyl acetate + 1% phosphotungstic acid at 4°C. The specimens were incubated in incubator for ~ 48 hours at 65°C for polymerization. The specimens were cut with an ultramicrotome to 50 - 100 nm section thickness. Sections were rinsed to grids, whole grids made of cooper. Contrasted by 8% uranyl acetate, 0.7% lead citrate and 0.9% sodium citrate. After drying, ultrathin sections were observed at 80 kV using a JEOL 2100 TEM at 80 KV at EM Unit, Mansoura University, Egypt.

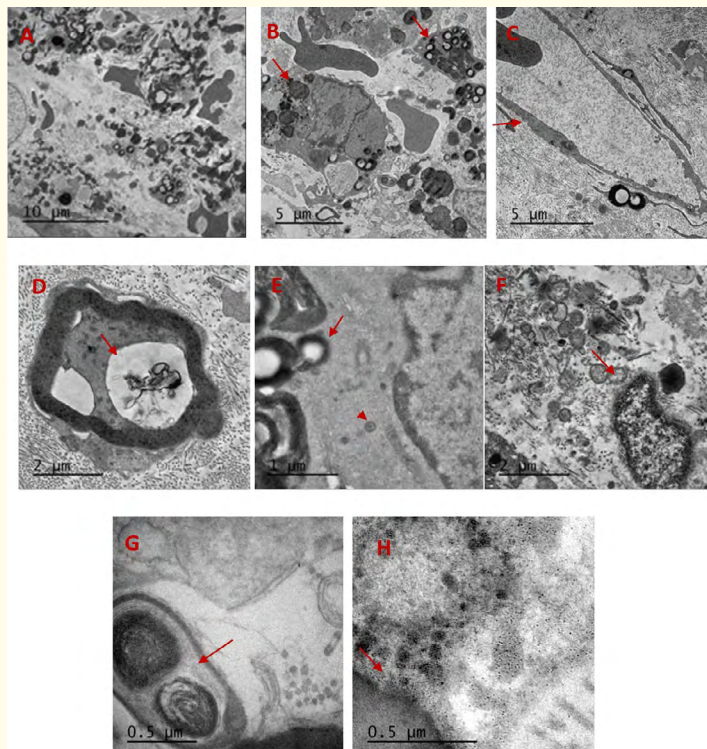
## Results

The healthy pulp tissue by transmission electron microscope (TEM) revealed normal appearance. Normal capillary with intact basement membrane, endothelial cells and pericytes surrounded by collagen fibers (Figure 3A). Myelinated nerve fibers, the axon surrounded by myelin sheath and Schwann cell and unmyelinated nerve fibers (Figure 3B and 3C).



**Figure 3:** TEM images of healthy human dental pulp A: shows normal capillary appearance with endothelial lining and pericyte (arrow). scale bar = 5  $\mu$ m; B: shows myelinated (arrow) and nonmyelinated (arrow head) nerve fibers and collagen fibers). scale bar = 2  $\mu$ m; C: The nucleus of Schwann cell can be seen. (arrow). scale bar = 2  $\mu$ m.

The HCV pulp tissue by TEM revealed disorganization, multiple autophages and lipid droplets surrounded by electron dense membrane, lysosomes in macrophage cells (Figure 4A and 4B). Collapsed capillary and lipid droplets (Figure 4C) Degeneration and vacuoles containing abnormal filaments in the axon of myelinated nerve fiber (Figure 4D). Lipid droplets and HCV like particles (core of protein surrounded by a shell) present in the perinuclear area (Figure 4E). Multiple HCV like particles can be seen in (Figure 4F and 4H). Also, disturbance in mitochondria can be seen in (Figure 4F).



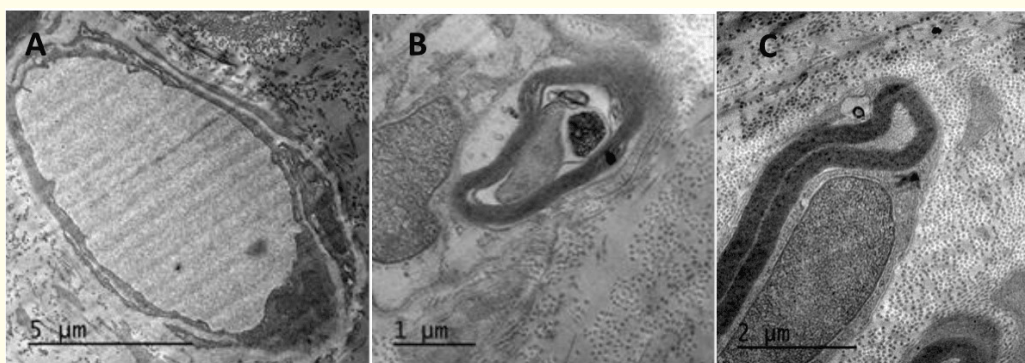
**Figure 4:** TEM images of infected HCV pulp A: shows disorganized pulp tissue with multiple lipid droplets surrounded by electron dense membrane. Scale bar = 10  $\mu\text{m}$ ; B: Autophages, macrophages contains lipid droplets and lysosomes. Scale bar = 5  $\mu\text{m}$ ; C: Collapsed capillary and lipid droplets Scale bar = 5  $\mu\text{m}$ .; D: Degeneration and vacuoles containing abnormal filaments in the axon of myelinated nerve fiber. Scale bar = 2  $\mu\text{m}$ ; E: lipid droplets and HCV like particles (arrow). HCV, core surrounded by a shell. (arrow head) in the perinuclear area. Scale bar = 1  $\mu\text{m}$ ; F: altered mitochondria (arrow). Scale bar = 2  $\mu\text{m}$ ; G: Autophagy. Scale bar = 0.5  $\mu\text{m}$ ; H: multiple HCV like particles at the nuclear periphery. Scale bar = 0.5  $\mu\text{m}$ .

The treated HCV pulp tissues showed better appearance of capillaries than infected HCV pulp capillaries and myelinated nerve fibers. However, degeneration in the axon of myelinated nerve fiber can be seen (Figure 5A, 5B and 5C).

## Discussion

The liver is responsible for removing harmful substances from the blood. HCV disturbs the liver function that can affect the entire body [1,5-8]. This research was done as there are, as yet, no reports that provide a full description of the hepatitis C infected pulp using transmission electron microscope.

The healthy specimens showed normal structure of capillaries, nerve fibers myelinated and nonmyelinated. The infected pulp showed disorganized tissue with collapsed capillaries, degeneration in the axons of myelinated nerve fibers, this in agreement with Grawish, *et al.* [15,16] who found by light microscope that the human dental pulp of chronic HCV patients were disorganized with inflammatory cells, stenosis, occlusion of large sized blood vessels and scanty amount of collagen, also they found ectopic calcification and vasculitis associated with cryoglobulinemia. Vasculitis may be attributed to the precipitation of cryoglobulins (abnormal proteins) inside the blood vessel wall causing inflammation (vasculitis). Cryoglobulinemia is one of the common disorders caused by HCV; mixed cryoglobulinemia vasculitis is a small-medium vessel vasculitis [7,17,18].



**Figure 5:** A: TEM image of treated HCV pulp shows capillary. Scale bar = 5  $\mu\text{m}$ ; B: Degeneration in the axon of myelin sheath. Scale bar = 1  $\mu\text{m}$ ; C: Intact myelin sheath, compressed nerve axon and Schwann cell.

The new and most important findings are the presence of multiple lipid droplets, autophages, lysosomes, altered mitochondria and degeneration in the axons of myelinated nerve fibers. These findings may indicate the presence of HCV like particles and replication in human dental pulp cells. Higher resolution showed HCV like particles with its core and surrounding capsid (shell) around the lipid droplets in the perinuclear area. Also, multiple virus like particles were detected in the perinuclear area of the pulp cells (odontoblasts and fibroblasts). These findings can be discussed and approved according to many previous valuable researches as follow.

HCV is blood-borne virus that replicates primarily in hepatocytes. Hepatocytes represent the major target for infection; however, HCV RNA was detected in the peripheral blood mononuclear cells, cerebrospinal fluid and the brain of chronically infected patients. HCV RNA has been associated with CNS tissue [19]. The brain is a suitable site for HCV replication, where the virus may directly exert neurotoxicity [6]. The vacuoles and degeneration in the axons of the nerve fibers are in agreement with Authier, *et al.* [20] who found that neurological involvement in HCV-mixed cryoglobulinemia, nerve biopsies reveal axonal degeneration and small vessel vasculitis. HCV RNA was found in epineural cells. This can be attributed to nerve ischemia secondary to occlusion or vasculitis causing axonal degeneration [21].

The lipid droplet (LD) is an organelle that is used for storage of neutral lipids. LD is involved in the production of infectious virus particles. Virus like particles were observed in close proximity to LDs, indicating some steps of virus assembly take place around LDs [22].

Also, Roingeard, *et al.* [23] confirmed that LDs have been shown to be important organelles for virus production. By three dimensional reconstructions of serial ultrathin electron microscopy, the budding of HCV-like particles was mostly initiated at membranes close to the lipid droplets. This explains the presence of HCV like particles close to the LDs in human dental pulp. This is in agreement with Depla, *et al.* [24] who found that HCV release is linked to the formation of LD clusters in the perinuclear area of infected cells induced by the core protein. Only the mature core protein induce LD clustering and emergence from endoplasmic reticulum membrane. This was associated with increase in LD synthesis. Intrahepatic HCV replication stimulates lipid metabolism resulting in accumulation of lipid droplets that facilitate virus assembly and maturation [25]. The altered mitochondria in the pulp infected cells can be explained as HCV has long been observed to take advantage of the host mitochondria to support viral replication and assembly. The HCV core protein has been implicated to fragment host mitochondria [26]. Increased autophagy in the infected pulp in this study has been reported. Degradation of specific autophagic targets is increased in HCV-infected cells, such as damaged mitochondria and lipid deposits. Evidence indicates that autophagy plays an important role in promoting the HCV life cycle in host cells [27]. HCV has induced autophagy. Autophagy is a lysosome-associated process that catabolizes components to recycle nutrients for further use. Induction of the cellular autophagy response is required to alleviate stress and improve survival of infected cells by inhibition of cellular apoptosis. In addition, autophagy can be induced during viral infection to generate energy for biosynthesis of new macromolecules by recycling metabolites, such as lipids, sugars and amino acids produced during lysosomal proteolysis [27-29]. Autophagy induction after virus infection was confirmed by transmission electron microscope using liver biopsies of chronically infected HCV patients [30].

The dental pulp of treated patients by Interferon alpha and Ribavirin has no lipid droplets, no autophages and no detection of virus like particles. This is in agreement with William and Stuart [31] who reported that interferons interfere with the viral replication within the host cell. There was improvement in capillary appearance in agreement with Ferri, *et al.* [32] who found that HCV-induced vasculitis responds to clearance during combination antiviral therapy with pegylated interferon plus ribavirin. Vacuoles are still present in the nerve axon as interferon is less effective with neural or renal involvement [33]. However; the patients with HCV cryoglobulinemia and peripheral neuropathy were treated by interferon Alpha and ribavirin for 48 weeks, the patient had negative HCV RNA and remission of neurological symptoms [34].

### Conclusion

- The dental pulp in patients infected with HCV revealed disorganized pulp tissues with the detection of HCV like particles.
- Improvement of pulp tissue and disappearance of virus like particles after treatment by Interferon Alpha with Ribavirin.

### Recommendation

- Dental equipment must be completely sterilized before and after dental procedures.
- More specimens and further investigations are recommended.

### Conflicts of Interest

None.

### Acknowledgements

Thanks to Electron Microscopic Unit, Faculty of Agriculture, Mansoura University.

## Bibliography

1. Manns MP, *et al.* "Diagnosis and management of autoimmune hepatitis". *Hepatology* 51.6 (2010): 2193-2213.
2. Zampino R, *et al.* "Chronic HCV infection and inflammation: clinical impact on hepatic and extra-hepatic manifestations". *World Journal of Hepatology* 5.10 (2013): 528-540.
3. Panov V. "Oral manifestations of hepatitis C virus". *Journal of International Medical Association Bulgaria* 19.4 (2013): 377-379.
4. Mohd Hanafiah K, *et al.* "Global epidemiology of hepatitis C virus infection: new estimates of age-specific antibody to HCV seroprevalence". *Hepatology* 57.4 (2013): 1333-1342.
5. Adinolfi LE, *et al.* "Chronic hepatitis C virus infection and atherosclerosis: clinical impact and mechanisms". *World Journal of Gastroenterology* 20.13 (2014): 3410-3417.
6. Adinolfi LE, *et al.* "Chronic hepatitis C virus infection and neurological and psychiatric disorders: an overview". *World Journal of Gastroenterology* 21.8 (2015): 2269-2280.
7. Cacoub P, *et al.* "Extrahepatic manifestations of chronic hepatitis C virus infection". *Digestive and Liver Disease* 46.5 (2014): S165-S173.
8. Franciscus A. "An overview of extrahepatic manifestations of hepatitis C". *HCSP* 7 (2015): 1-6.
9. Zaltron S, *et al.* "Chronic HCV infection: epidemiological and clinical relevance". *BMC Infectious Diseases* 12.2 (2012): S2.
10. "Hepatitis C New Drug Research and liver health" (2016).
11. Roingear P. "Viral detection by electron microscopy: past, present and future". *Biology of the Cell* 100.8 (2008): 491-501.
12. Romery-Brey I and Bartenschlager R. "Viral infection at high magnification: 3D electron microscopy methods to analyze the architecture of infected cell". *Viruses* 7.12 (2015): 6316-6345.
13. Yu X, *et al.* "Cryo-electron microscopy and three-dimensional reconstructions of hepatitis C virus particles". *Virology* 367.1 (2007): 126-134.
14. Nakashima M and Akamine A. "The application of tissue engineering to regeneration of pulp and dentin in endodontics". *Journal of Endodontics* 31.10 (2005): 711-718.
15. Grawish Mel-A, *et al.* "Altered coronal tissue of the human dental pulp in chronic hepatitis C virus infected patients". *Journal of Endodontics* 39.6 (2013): 752-758.
16. Grawish Mel-A, *et al.* "Vasculitis of dental pulp associated with cryoglobulinemia in hepatitis C virus patients: Case report". *Journal of Endodontics* 37.11 (2011): 1593-1595.
17. Galossi A, *et al.* "Extrahepatic manifestation of chronic HCV infection". *Journal of Gastrointestinal and Liver Diseases* 16.1 (2007): 65-73.
18. Ferri C, *et al.* "HCV-related cryoglobulinemia vasculitis: An update on its etiopathogenesis and therapeutic strategies". *Clinical and Experimental Rheumatology* 21.6 (2003): S78-S84.
19. Fletcher NF and Mckeating JA. "Hepatitis C Virus and the brain". *Journal of Viral Hepatitis* 19.5 (2012): 301-306.
20. Authier FJ, *et al.* "Detection of genomic viral RNA in nerve and muscle of patients with HCV neuropathy". *Neurology* 60.5 (2003): 808-812.

21. Vital C., *et al.* "Combined nerve and muscle biopsy in the diagnosis of vasculitic neuropathy. A 16-year retrospective study of 202 cases". *Journal of the Peripheral Nervous System* 11.1 (2006): 20-29.
22. Miyanari Y., *et al.* "The lipid droplet is an important organelle for hepatitis C virus production". *Nature Cell Biology* 9.9 (2007): 961-969.
23. Roingeard P., *et al.* "Hepatitis C virus budding at lipid droplet-associated ER membrane visualized by 3D electron microscopy". *Histochemistry and Cell Biology* 130.3 (2008): 561-566.
24. Depla M., *et al.* "Ultrastructural and quantitative analysis of the lipid droplets clustering induced by hepatitis C virus core protein". *Cellular and Molecular Life Sciences* 67.18 (2010): 3151-3161.
25. Aizawa Y., *et al.* "Chronic hepatitis C virus infection and lipoprotein metabolism". *World Journal of Gastroenterology* 21 (2015): 10299-10313.
26. Siu GK., *et al.* "Hepatitis C virus NS5A protein cooperates with phosphatidylinositol 4-kinase III $\alpha$  to induce mitochondrial fragmentation". *Scientific Reports* 6 (2016).
27. Ke PY and Chen SS. "Autophagy in hepatitis C virus-host interactions: Potential roles and therapeutic targets for liver associated diseases". *World Journal of Gastroenterology* 20.19 (2014): 5773-5793.
28. Srikanta Dash., *et al.* "Hepatitis C virus infection induces autophagy as a postsurvival mechanism to alleviate hepatic ER-stress response". *Viruses* 8.5 (2016): 150.
29. Rashid HO., *et al.* "ER stress: Autophagy induction, inhibition and selection". *Autophagy* 11 (2015): 1956-1977.
30. Rautou P E., *et al.* "Changes in autophagic response in patients with chronic hepatitis C virus infection". *American Journal of Pathology* 178.6 (2011): 2708-2715.
31. William K and Stuart K Roberts. "Treatment with interferon and ribavirin. Chronic Hepatitis C Virus". *Springer Science, Business Media* 10 (2012): 115-128.
32. Ferri C., *et al.* "Interferon-alpha in mixed cryoglobulinemia: a randomized, crossover-controlled trial". *Blood* 81.5 (1993): 1132-1136.
33. Lidove O., *et al.* "Cryoglobulinemia and hepatitis C worsening of peripheral neuropathy after interferon alpha treatment". *Gastroenterology Clinical and Biological* 23.3 (1999): 403-406.
34. Vigan AG., *et al.* "Hepatitis C virus infection, cryoglobulinemia, and peripheral neuropathy: a case report". *Brazilian Journal of Medical and Biological Research* 38.12 (2005): 1729-1734.

**Volume 6 Issue 2 November 2016**

**© All rights reserved by AYousry M EL-Hawary., *et al.***