

## **An Alternative Implant Impression Technique with Limited Interocclusal Space: Closed-Tray Impression Posts for Open-Tray Impression Technique**

**Mehmet Ali Kilicarslan<sup>1\*</sup>, OkanYucel<sup>2</sup>, AybenBayrak<sup>2</sup> and ZeynepEkici<sup>2</sup>**

<sup>1</sup>*Professor, Department of Prosthodontics, Faculty of Dentistry, Ankara University, Turkey*

<sup>2</sup>*Assistant Professor, Department of Prosthodontics, Faculty of Dentistry, Ankara University, Turkey*

**\*Corresponding Author:** Mehmet Ali Kilicarslan, Professor, Department of Prosthodontics, Faculty of Dentistry, Ankara University, Ankara, Turkey.

**Received:** April 27, 2016; **Published:** May 12, 2016

### **Abstract**

Accurate impression is a main requirement for obtaining passive fit of restorations. The aim of this case report is an alternative technique in using closed-tray impression posts for open-tray impression technique for exemplification at a patient that can have limited interocclusal vertical space.

After osseointegration, 7 implants examined in edentulous maxilla, open-tray impression technique should be used due to angulation and number of implants. Light-cured UDMA material is used for making personal tray. Closed-tray impression posts are inserted and impression is taken with polyether impression material. Impression posts are splinted to tray with light-cured UDMA. Tray is removed from mouth and a model is prepared. Metal-porcelain restorations are prepared conventionally.

This case report shows a modified technique that mixes two impression types. This technique can lead to new studies and clinical trials. Further investigations are needed for this technique.

**Keywords:** *Impression accuracy; Implant misfit; Direct technique; Indirect technique; Personal tray*

### **Introduction**

Dental implants can be used for prosthetic rehabilitation of complete and partial edentulism successfully. But implant-supported fixed partial dentures couldn't compensate impression failures like tooth supported fixed partial dentures, cause they do not have a periodontal ligament [1,2]. The accuracy of the impression becomes much more important in implant-supported restorations since the implant does not have an adaptive mechanism as in a tooth [1].

The passive fit of implant-supported fixed prosthesis is mandatory to ensure a correct and successful oral rehabilitation [1,3,4]. Passive fitness is the term used to address fitting status of the implant in which implant body shows adequate fitting for simultaneous remodeling and adaptation [5]. A non-passive framework results in the accumulation of stresses in the implant-prosthesis set, leading to certain biological and mechanical complications such as screw loosening, screw fracture, occlusal discrepancies, loss of osseointegration, plaque accumulation, soft and hard tissue reactions and bone loss [4-8]. A lot of factors are responsible for passive fitting. Among them there are castings, type of alloy which effect prosthetic component quality, manufacturing procedure. Another important factor is the transfer impression clinical procedure [9]. Many factors are involved in transferring the implant position from the mouth to the cast, including the implant connection type and impression coping design, the number of implants and angulation, the impression technique and the impression material. Where as the influence of different impression materials appears to be less critical, impression techniques are considered as a major factor that influences impression accuracy [2,10]. Even though obtaining absolute passive fit is practically impossible especially

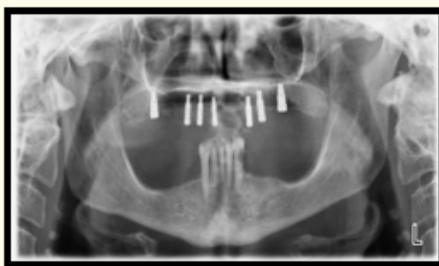
**Citation:** Mehmet Ali Kilicarslan., *et al.* "An Alternative Implant Impression Technique with Limited Interocclusal Space: Closed-Tray Impression Posts for Open-Tray Impression Technique". *EC Dental Science* 4.3 (2016): 815-821.

in partially or completely edentulous patients, minimizing the misfit to prevent possible complications is a generally accepted goal of prosthodontic implant procedures [6,7].

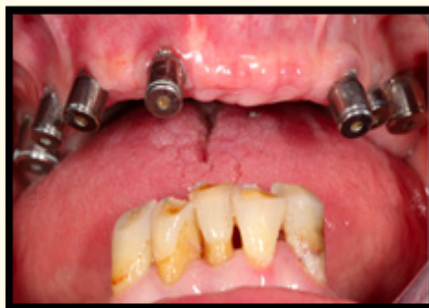Currently, two main different impression techniques are used in implant impressions: indirect technique and direct technique [4,9,11]. The indirect technique requires a closed tray and transfer impression copings. Once the impression is set, the tray is removed from the mouth leaving transfer impression copings attached on implants. The transfer copings are removed and tied to implant analogs and re-inserted in the impression to realize the master cast [4,11]. Conversely, the direct technique consists in the use of an open tray, allowing access to the exposed top of pick-up impression copings that have to be unscrewed and removed along with the tray. Implant analogs are directly connected to the pick-up copings incorporated within the impression. In the literature, there is no unanimous consent about which impression technique is more accurate for transferring the implants from mouth to the laboratory. Some studies found direct technique is more accurate than indirect technique [12,13]. Lee., *et al.* suggest to adopt the direct technique in case of 4 or more implants, whereas both direct and indirect techniques may be used when 3 or less implants are placed [6]. However, some studies found more accurate impressions with the indirect technique [14-16]. For the direct impression technique, several studies have compared the accuracy of splinted and non-splinted impression copings [2,4,11]. Many studies have shown no difference between two method and a few studies have reported that splinted technique is more accurate than nonsplinted [11,17]. Open-tray impression posts are longer than closed-tray impression posts so it is hard to have correct impression at patients that have limited vertical space especially posterior site of alveolar crest. The aim of this case report is an alternative technique in using closed-tray impression posts for open-tray impression technique for exemplification at a patient that can have limited interocclusal vertical space.

### Case Report

58 years old, female patient attended Ankara University Faculty of Dentistry, department of prosthodontics with complete edentulism of maxilla. After discussing treatment options with the patient, a treatment plan was agreed on implant therapy. Pretreatment panoramic radiograph evaluated for implant therapy then seven implants (Zimmer Dental, USA) placed at maxilla (Figure 1a and 1b) and after osseointegration prosthetic stage commenced.




**Figure 1a:** Panoramic Radiograph After 7 Implants Placed on Edentulous Maxilla.

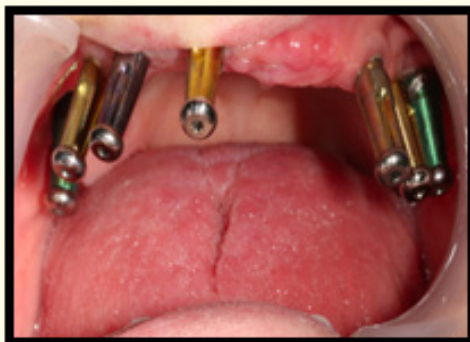

**Figure 1b:** Intra-oral View of Implants.

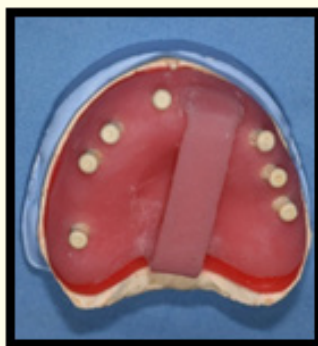
Preliminary examination shows that open-tray impression technique should be used due to angulation and number of implants. We used closed-tray impression posts instead of open-tray impression posts because they are shorter than others (Figure 2). First impression is taken on closed-tray impression posts to make model and to produce acrylic personal tray (Figure 3). Light-cured urethane dimethyl acrylate (UDMA) (Arcas LC, Berka, Turkey) is used for producing custom tray (Figure 4).



*Figure 2: Close and Open-Tray Impression.*

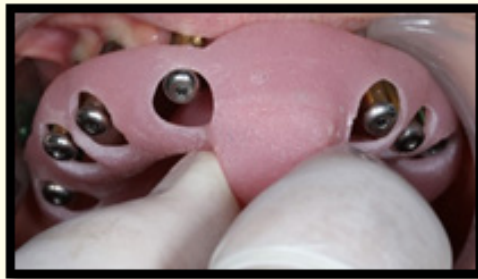

*Figure 3: View of Closed-Tray Impression Post in Place.*

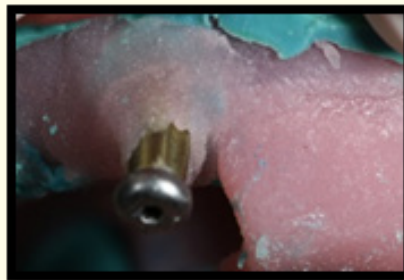

*Figure 4: View of Closed-Tray Impression Posts on Diagnostic Model and Acrylic Personal Tray.*

Closed-tray impression posts are placed on the implant and impression was taken with polyether medium viscosity (3M Espe Dental, Medizin, Germany) impression material with its specific tray adhesive (Polyether Adhesive, 3M Espe Dental, Medizin and Germany). After setting of impression, at removal stage we saw that impression posts didn't stay tightly at impression so we decided to remake impression. Although polyether impression material is quite rigid, it was unable to have correct impression without splinting impression posts. We insert personal tray with polyether impression material again and after setting we cut excessive impression material over impression posts and personal tray. Impression posts were splinted to personal tray with light-cured UDMA (Figure 5a and 5b).

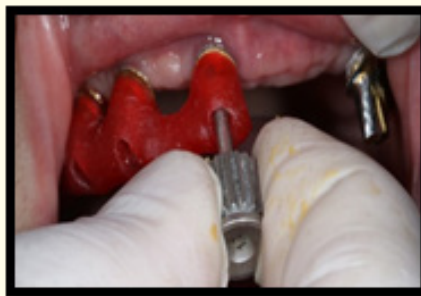

**Figure 5a:** *Trying of Custom Tray in Mouth.*



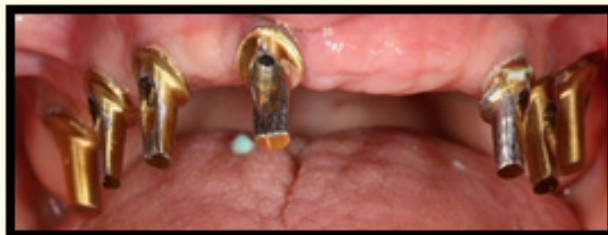**Figure 5b:** *Fixation of Impression Posts with Light-Cured UDMA.*

Impression is removed from mouth and definitive cast is obtained. After choosing prefabricated abutments, definitive cast sent to technicians for preparation of abutments. Preparation was done and the transfer key prepared with auto polymerizing acrylic resin (Pattern Resin, GC) for transferring abutments from definitive cast to mouth (Figure 6).

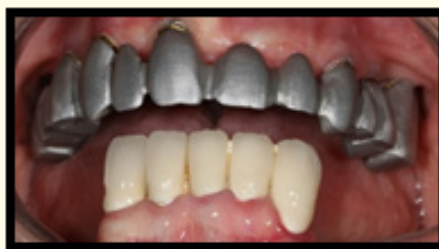

**Figure 6:** *Implant Abutments with the Transfer Key on the Master Cast and Mouth.*

Abutments were placed on implants (Figure 7). Then Co-Cr metal framework replaced on the abutments (Figure 8) but passive fit couldn't be obtained so we separated metal framework from connector at molar region. After separation, parts splinted with auto polymerizing acrylic resin. Splinted framework is removed from mouth. Abutments were not removed from mouth and we took impression on abutments. Metal framework soldered in the laboratory. Dentine and enamel ceramics were applied on framework and fitted in the mouth. After glazing procedure, final restoration was cemented conventionally.




*Figure 7: View of Abutments in Mouth.*



*Figure 8: View of Co-Cr Metal Framework on Abutments.*

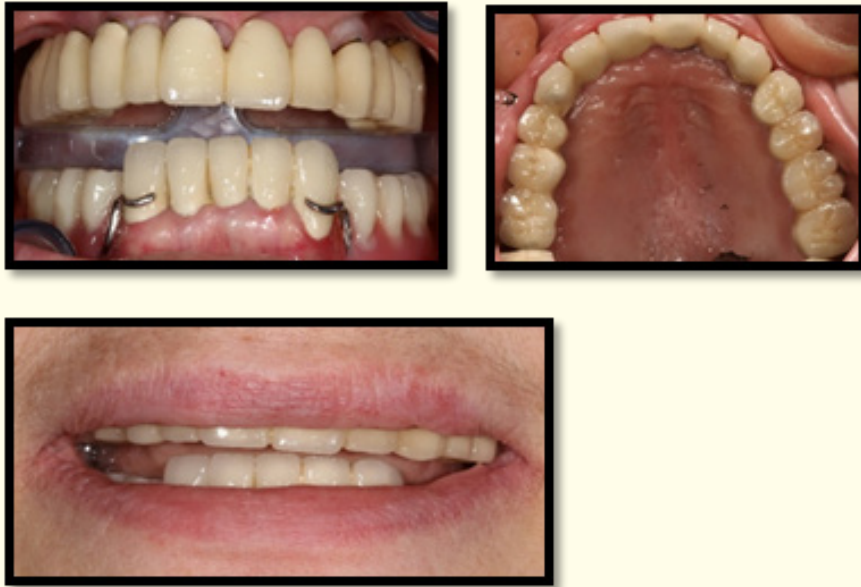Polyether light bodied viscosity impression material was used for control adaptation of metal framework and abutments and then it was inspected under stereo-microscope. Metal contacts with abutments were observed on only two abutments and eliminated (Figure 9).



*Figure 9: Microscopic View of Polyether Light Bodied Viscosity Impression Material between Metal Framework and Implants Abutments.*

Final prosthesis consisted of an implant-retained metal-ceramic restoration (Figure 10).





**Figure 10:** Rehabilitation of Totally Edentulous Maxilla with an Fixed Denture Supported by 7 Implants: Clinical View.

## Conclusion

Different impression techniques have been developed for implant rehabilitation, main difference among these techniques rely on the impression coping been incorporated and removed with impression or being repositioned into impression only after the tray has been removed from patients mouth. This case report shows a modified technique that combination of two impression types and can lead to new studies and clinical trials. This study point that with an appropriate splinting closed-tray impression posts can be used effectively at cases when open-tray impression posts hard to use. Further investigations are needed for this technique and must be developed for clinical usage.

## Bibliography

1. Sengun E., et al. "Implant Destekli Restorasyonlarda Kullanılan Ölçü Teknikleri: Derleme". *Ondokuz Mayıs Üniversitesi Diş Hekimliği Fakültesi Derg* 13.2 (2012): 37-43.
2. Rutkunas V and Ignatovic J. "A Technique to Splint and Verify the Accuracy of Implant Impression Copings with Light-Polymerizing Acrylic Resin". *Journal of Prosthetic Dentistry* 111.3 (2014): 254-256.
3. BalaMurugan T and Manimaran P. "Evaluation of Accuracy of Direct Transfer Snapon Impression Coping Closed Tray Impression Technique and Direct Transfer Open tray Impression Technique: An *in vitro* Study". *Journal of Indian Prosthodontic Society* 13.3 (2013): 226-232.
4. Pera F., et al. "Analysis of Different Impression Techniques and Materials on Multiple Implants Through 3-Dimensional Laser Scanner". *Implant Dentistry* 25.2 (2016): 232-237.
5. Balouch F., et al. "Comprasion of Dimensional Accuracy between Open-Tray and Closed-Tray Implant Impression Technique in 15 Angled Implants". *Journal of Dentistry, Shiraz University of Medical Sciences* 14.3 (2013): 96-102.
6. Lee H., et al. "The Accuracy of Implant Impressions: A Systematic Review". *Journal of Prosthetic Dentistry* 100.4 (2008): 285-291.

7. Moreira AHJ, *et al.* "Accuracy Comparison of Implant Impression Techniques: A Systematic Review". *Clinical Implant Dentistry And Related Research* 17.2 (2015): 751-764.
8. Vojdani M, *et al.* "Accuracy of Different Materials in Parallel and Nonparallel Implants". *Dental Research Journal* 12.4 (2015): 315-322.
9. Assunção WG, *et al.* "Prosthetic Transfer Impression Accuracy Evaluation for Osseointegrated Implants". *Implant Dentistry* 17.3 (2008): 248-256.
10. Assif D, *et al.* "Accuracy of Implant Impression Splinted Techniques: Effect of Splinting Material". *International Journal of Oral and Maxillofacial Implants* 14.6 (1990): 885-889.
11. Hazboun GBA, *et al.* "Effect of Implant Angulation and Impression Technique on Impression of Nobel Active Implants". *Journal of Prosthetic Dentistry* 113.5 (2015): 425-431.
12. Spector MR, *et al.* "An Evaluation of Impression Techniques for Osseointegrated Implants". *Journal of Prosthetic Dentistry* 63.4 (1990): 444-447.
13. Del'acqua MA, *et al.* "Accuracy of Impression and Pouring Techniques for an Implant-Supported Prosthesis". *International Journal of Oral and Maxillofacial Implants* 23.2 (2008): 226-236.
14. Humphries RM, *et al.* "The Accuracy of Implant Master Casts Constructed from Transfer Impressions". *International Journal of Oral and Maxillofacial Implants* 5.4 (1990): 331-336.
15. De La Cruz JE, *et al.* "Verification Jig for Implant-Supported Protheses: A Comparison of Standard Impression with Verification Jigs Made of Different Materials". *Journal of Prosthetic Dentistry* 88.3 (2002): 329-336.
16. Walker MP, *et al.* "Implant Cast Accuracy as a Function of Impression Techniques and Impression Material Viscosity". *International Journal of Oral and Maxillofacial Implants* 23.4 (2008): 669-674.
17. Burawi G, *et al.* "A Comprasion of the Dimensional Accuracy of the Splinted and Unplinted Impression Techniques for the Bone-Lock Implant System". *Journal of Prosthetic Dentistry* 77.1 (1997): 68-75.

**Volume 4 Issue 3 May 2016**

**© All rights reserved by Mehmet Ali Kilicarslan, *et al.***