

## **Incidental Radiographic Discovery of a Screw in a Primary Molar in a 8 Year Old Child: A Case Report**

**Khokhar V\*, Bushra H and Garg S**

*Department Of Pedodontics and Preventive Dentistry Government Dental College and Hospital, India*

**\*Corresponding Author:** Khokhar Vijender, Room No. 139, Doctor's Hostel, Rajindra Hospital, Patiala, Punjab, India.

**Received:** April 19, 2016; **Published:** May 03, 2016

### **Abstract**

Children often have the habit of placing objects in their mouth, and these objects may be accidentally implanted in the oral cavity, ingested or aspirated. The objects are frequently embedded in exposures that result from carious or traumatic lesions or from endodontic procedures that have been left open for drainage. The foreign objects in the teeth may act as a potential source of infection and pain. A detailed case history and clinical and radiographic examinations are necessary to conclude about the nature, size, location of the foreign body, and to determine the difficulty involved in its removal. We report a case of an 8-year-old boy who had inadvertently embedded a screw in his maxillary right first primary molar and its management. This case report considers the possible medical and dental consequences of placing foreign bodies in the mouth.

**Keywords:** Primary molar; Foreign bodies; Screw in deciduous teeth; Foci of infection

### **Introduction**

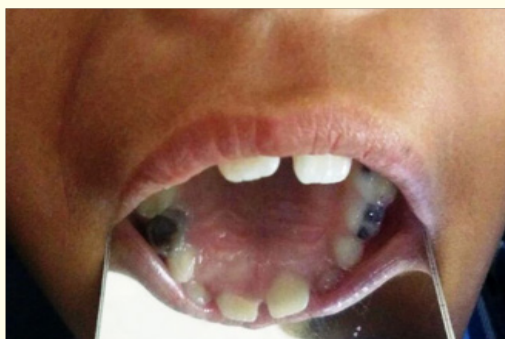Children explore and interact with the world by placing and sucking any object inside their mouth. These objects may be a foreign body or part of their bodies such as thumb or fingers [1]. Many children are in the habit of exploring various objects in the oral cavity that can cause hard or soft tissue injuries [2]. This practice may result in inadvertent insertion of foreign bodies within the pulp chamber or root canal. Oral foreign bodies may be the cause of a person seeking dental care to relieve the discomfort caused by impacted food in the interdental areas and cavities in the mouth and may be discovered by the dentist's during routine examinations [3,4]. Such a self injurious act made by the child might result in undue complications, such as exposure of the vital pulp or breakage of the foreign body leading to dental pain and infection. Also, there may be serious and alarming consequences, such as aspiration or inhalation of the foreign body.

Management of such foreign bodies requires a thorough clinical and radiographic examination to ascertain its exact location, the extent of damage, and the possible atraumatic methods to remove the lodged foreign body. So, the purpose of this paper was to describe one patient in whom foreign bodies were found to be lodged in the right maxillary primary molar and their management there after.

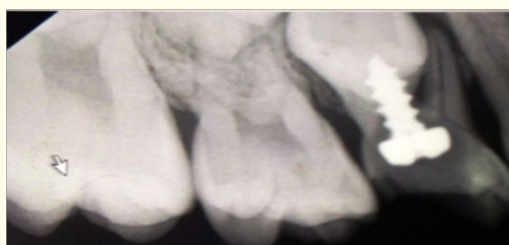### **Case Report**

An 8 year old boy reported to the Department of Pedodontics, government Dental College, patiala, India, complaining of pain in upper right back region of jaw, since 3–5 days. Intraoral clinical examination revealed deep occlusal caries in relation to #54. (Figure 1) Vestibular tenderness and mobility were absent. The radiovisiography (RVG) of the tooth revealed presence of a linear radiopaque object (metallic screw) 6.5× 5 mm in dimension, which was embedded in the pulp chamber of #54 throughout the furcation area and impinging on crown of developing first premolar. (Figure 2) A clinical history revealed that the patient did not remember anything about the placement of screw the cavitated tooth. As it is revealed from the radiograph root resorption and furcation involvement of #54. Based on the above findings, the treatment plan was decided, which included the extraction of #54 under local anesthesia. Informed consent for the extraction procedure was obtained from the parent and the treatment was rendered. A 6.5× 5 mm screw was retrieved from the extracted tooth and planned for space maintainer.


**Citation:** Khokhar Vijender., *et al.* "Incidental Radiographic Discovery of a Screw in a Primary Molar in a 8 Year Old Child: A Case Report". *EC Dental science* 4.3 (2016): 780-784.



**Figure 1:** Intraoral examination of patient reveal deep carious lesion # 54.



**Figure 2:** Radiovisiography (RVG) of #54 reveals screw pinching on crown of #24.



**Figure 3:** Screw retrieved after extraction of #54.

### Discussion

The habit of placing foreign bodies in the oral cavity is commonly found in children [5]. Sometimes children do not reveal such events to their parents due to fear and are detected accidentally during routine radiographic examinations. A review of the literature reveals numerous reports describing the various foreign objects such as wooden tooth picks, absorbent points, tomato seed, pins, pencil tip, plastic objects, toothbrush bristles, crayons and stapler pins that have been inserted in the exposed pulp chambers or root canals. Foreign bodies such as have been placed into the root canals of carious teeth in an attempt to remove food debris [6,7,8,9,10,11]. Wakpanjar M., *et al.* reported a piece of lead pencil tightly lodged in the pulp chamber #54 [12]. Gujjar, *et al.* cited cases involving metallic pin and lead pencil in pulp chamber of primary mandibular posterior teeth [13]. Azodo CC., *et al.* reported a cut-off part of the inner tube of a biro well-adapted to the cervical one-third of the crown of the #72. Katge F, *et al.* reported the removal of metallic screw from the pulp chamber of

#84 with intact pulpal floor [14]. Patil MC., *et al.* cited case involving twisted wire in pulp chamber of #52 in 8 yr old girl [15]. Aduri R., *et al.* reported the removal of staple pin from left maxillary molar teeth in 12 year old girl [16]. Pomarico L., *et al.* reported the removal of metal screw measuring approximately 3.5 mm × 1.5 mm was found firmly embedded in the pulp chamber of first lower left deciduous molar [17]. Dhull KS., *et al.* reported the removal of metallic pin from the distal canal of primary mandibular first molar and distal canal of primary mandibular second molar [18].

A radiograph forms a valuable diagnostic tool in determining the exact location and relative radio-opacity of the foreign bodies. McAuliffe<sup>7</sup> summarized various radiographic methods to localize a radiopaque foreign object, such as parallax views, vertex occlusal views, triangulation techniques, stereo radiography, and tomography. Vertex occlusal view is no longer favoured because of relatively high radiation exposure to the lens of the eye and because the primary beam is aimed towards the abdomen. Triangulation is by the use of two views right angle to one another. Interpretation is difficult because of the superimposition of the other incisor teeth over the root. Stereographic views and tomography were not considered since the availability of the facilities in a dental operator is very minimal. Specialized radiographic techniques such as radiovisiography, 3D CAT scans can play a pivotal role in localization of these foreign objects inside the root canal.

For retrieval of foreign objects lying in the pulp chamber or canal using ultrasonic instruments [19], the Masserann kit [20], modified Castroveijo needle holders [21] have been used. Ethylenediaminetetraacetic acid has been suggested as a useful aid in lubricating the canal when attempting to remove the foreign object. The Steglitz forceps have also been described for use of removal of silver points from the root canal. There is a description of an assembly of a disposable injection needle and thin steel wire loop formed by passing the wire through the needle being used. This assembly was used along with a mosquito hemostat to tighten the loop around the object [22]. Nehme had recommended the use of operating microscope along with ultrasonic filing to eliminate intra-canal metallic obstructions [23].

There may be serious and alarming consequences, such as aspiration or inhalation of the foreign bodies. Foreign body lodgement in primary teeth can lead to perforation of the pulp chamber. Impaction of the foreign bodies deeper beyond the furcation may cause trauma to the permanent tooth bud. This can destroy the permanent tooth bud completely or may form a complex odontoma. A force of lesser magnitude may result in a geminated and/or a hypo plastic successor tooth. The presence of a foreign body may also hamper the eruption of the underlying permanent tooth bud, resulting in ectopic or failed eruption. It may also cause mechanical obstruction at the time of root formation and may alter the angulation of its root, leading to dilaceration. Costa reported chronic maxillary sinusitis of a dental origin that occurred due to the pushing of foreign bodies into the maxillary sinus through the root canals [24]. Goldstein cited development of actinomycosis due to the lodgement of a piece of jewelry chain in a maxillary central incisor [25].

Health professionals should play a vital role in the early referral of young children with dental caries to the dentist. Educational campaigns should be conducted to emphasize the danger following the use of foreign bodies in the oral cavity. Anticipatory guidance to parents should also include potential complications caused due to self-injurious behaviour with foreign bodies in young children. The present case reports effectively illustrate the sequelae of untreated caries in children. Awareness about the sequelae of untreated dental caries is a prerequisite to both the patient and the dentist, which facilitates early diagnosis and prompt management of similar cases.

## **Conclusion**

The management of a foreign body impaction in a tooth depends on the location, accessibility, stage of tooth formation, restorability of the tooth, the patient's age, and level of cooperation. Educational campaigns should be conducted to emphasize the danger following inserting foreign bodies in the oral cavity. Parents should also be informed about the potential complications caused due to self injurious behavior with foreign bodies in young children.

## Bibliography

1. Azodo CC., et al. "Intraoral Foreign Body: A Case Report and Review of Literature". *Indian Journal of Multidisciplinary Dentistry* 5.2 (2015): 97-99.
2. Morewala Abdul. "Lecturer: An Unusual Foreign Body in an Open Apex Tooth, Guident". 6.12 (2013): 40-42.
3. Tay ABG. "Long-Standing Intranasal Foreign Body: An Incidental Finding On Dental Radiograph- A Case Report And Literature Review". *Oral Surgery Oral Medicine Oral Pathology Oral Radiology and Endodontology* 90.4 (2000): 546-549.
4. Yassin OM and Hattab FN. "Unusual Nasal Foreign Body Detected On Routine Dental Radiography: Case Report". *The Journal of Clinical Pediatric Dentistry* 20.2 (1996): 155-157.
5. Ram D and Peretz B. "Tongue Piercing and Insertion of Metal Studs: Three Cases of Dental and Oral Consequences". *Journal of Dentistry for Children* 67.5 (2000): 326-329.
6. Gelfman WE, Cheris LJ and Williams AC. "Self Attempted Endodontics: A Case Report". *Journal of Dentistry for Children* 36.4 (1969): 283-284.
7. Prabhakar AR, Basappa N and Raju OS. "Foreign Body in a Mandibular Permanent Molar: A Case Report". *Journal of Indian Society of Pedodontics and Preventive Dentistry* 16.4 (1998): 120-121.
8. Macauliffe N, Drage NA and Hunter B. "Staple Diet: A Foreign Body in a Tooth". *International Journal of Paediatric Dentistry* 15.6 (2005): 468-471.
9. Harris WE. "Foreign bodies in root canals: Report of two cases". *Journal of the American Dental Association* 85.4 (1972): 906-911.
10. Grossman JL and Heaton JF. "Endodontic Case Reports". *Dental Clinics of North America* 18.2 (1974): 209-27.
11. Reddy SVV, Mehta DS. "Beads". *Oral Surgery, Oral Medicine, and Oral Pathology* 69.6 (1990): 769-770.
12. Wakpanjar M, Katge F and Shivasharan P. "Foreign Body in Primary Molar: A Case Report". *Arch of Dental and Medical Research* 2.1 (2016): 72-74.
13. Gujjar KR., et al. "Foreign Bodies in Primary Molars: A Report of 2 Cases". *Journal of Dentistry for Children* 79.1 (2012): 40-43.
14. Katge F., et al. "Incidental Radiographic Discovery of a Screw in a Primary Molar: An Unusual Case Report in a 6 Year Old Child". *Case Reports in Dentistry* 2013 (2013): 3 pages.
15. Palit MC., et al. "Radiographic Revelation of Foreign Body in Primary Tooth: A Rare Case Report". *Journal of Dental Applications* 2.6 (2015): 251-253.
16. Aduri R., et al. "Foreign objects in Teeth: Retrieval and management". *Journal of Indian Society of Pedodontics and Preventive Dentistry* 27.3 (2009): 179-183.
17. Pomarico L., et al. "Unusual Foreign Body Detected On Routine Dental Radiograph". *Archives of Disease in Childhood* 90.8 (2005): 825.
18. Dhull KS., et al. "Foreign Body in Root Canals of Two Adjacent Deciduous Molars: A Case Report". *International Journal of Clinical Pediatric Dentistry* 6.1 (2013): 38-39.
19. Meidinger DL and Kabes BJ. "Foreign Object Removal Utilizing the Caviendo Ultrasonic Instrument". *Journal of Endodontics* 11.7 (1985): 301-304.

20. Williams VD and Bjourndal AM. "The Masseran Technique for the Removal of Fractured Posts in Endodontically Treated Teeth". *Journal of Prosthetic Dentistry* 49.1 (1983): 46-48.
21. Fros UG and Berg JO. "A Method for the Removal of Broken Endodontic Instruments from the Root Canals". *Journal of Endodontics* 9 (1983): 56-59.
22. Roig-Greene JL. "The Retrieval of Foreign Objects from Root Canals: A Simple Aid". *Journal of Endodontics* 9.9 (1983): 394-397.
23. Nehme WB. "Elimination of Intracanal Metallic Obstruction by Abrasion Using an Operational Microscope and Ultrasonics". *Journal of Endodontics* 27 (2001): 365-367.
24. Costa F, *et al.* "Endoscopically Assisted Procedure For The Removal Of A Foreign Body From The Maxillary Sinus And Contemporary Endodontic Surgical Treatment Of The Tooth". *Head and Face Medicine* 8 (2006): 37.
25. Goldstein BH, *et al.* "Actinomycosis Of The Maxilla: A Review Of Literature And A Report Case". *Journal of Oral and Maxillofacial Surgery* 30 (1972): 362-366.

**Volume 4 Issue 3 May 2016**

**© All rights reserved by Khokhar Vijender, *et al.***