

Reattachment of Fractured Tooth Fragment Using Fiber Post: A Case Report

Kulwant Rai*, Munish Goel, Gurmeet Sachdeva, Shweta Verma and Prabhat Mnadhotra

Department of Conservative Dentistry and Endodontics, Himachal Dental College, Sundernagar, Himachal Pradesh, India

***Corresponding Author:** Kulwant Rai, Department of Conservative Dentistry and Endodontics, Himachal dental college, Sundernagar, Mandi, Himachal Pradesh, India.

Received: March 31, 2016; **Published:** April 06, 2016

Abstract

Coronal tooth fracture, especially in maxillary anterior teeth are mostly common in children and adolescents but can occur in any age group. Trauma to maxillary anterior teeth affects the patient both socially and psychologically, so the immediate treatment of such patients is must. If the fractured tooth fragment is available (clean and hydrated) then the reattachment of such fragment is the best treatment option available, as such treatment will result in original anatomic form, colour and surface texture. Reattachment of complex tooth fracture requires reinforcement by fiber post and adhesive system. This article discusses a case report regarding successful reattachment of fractured tooth fragment using Parapost Fiber lux (Coltene Whaledent) fiber post.

Keywords: *Crown Fracture; Fragment Reattachment; Fiber Post; Adhesive Technology*

Introduction

In young patients, dental trauma is a more common event in permanent dentition and results in fracture of anterior teeth. These fractures subsequently lead to various problems like esthetic, function, and phonetics. Management of the dental trauma requires accurate diagnosis and treatment plan [1]. Various factors influence the treatment approach for a complicated crown fracture like, the level and position of tooth fracture line, availability of displaced tooth fragments, type of occlusion, and prognosis [2,3]. A number of techniques have been developed to restore the fractured anterior teeth such as the use of the tooth fragment either as a temporary or permanent crown, definitive crown after an orthodontic and surgical extrusion or a crown lengthening, extraction followed by implant or fixed partial denture, composite restoration and post and core supported restoration [4]. If the intact tooth fragment is available, reattachment of tooth fragments can be considered and this technique is a viable alternative to conventional approach with minimal or without violation of biologic width [5,6]. Reattachment of fragment offers various advantages like, better aesthetics and achievement of life-like translucency, incisal edge wears at a rate similar to that of the adjacent teeth, replacement of fractured portion involving less time, positive emotional and social response from the patient and relatively inexpensive procedure [7].

Reattachment of tooth fractured at the cervical level can be reinforced with the use of post as it interlocks the two fragments and minimizes the stresses on the reattached tooth fragment [8]. With the recent improvements in resin based restorative materials, tooth colored fiber posts along with resin luting cement are of choice because of several advantages such as esthetics, bonding to tooth structure and low modulus of elasticity similar to that of dentin [9]. The purpose of this article is to present a case report regarding the successful management of a complex tooth fracture by reattachment of fractured tooth fragment using fiber post with two years follow up.

Case Report

A 30 year-old female patient reported to the department of Conservative Dentistry and Endodontics with chief complaint of mobile maxillary right anterior tooth. She gave a history of injury due to fall which occurred 24 hours ago. On clinical examination an Ellis class III fracture was noticed with respect to the maxillary right lateral incisor (Figure1). An oblique supra-gingival fracture line was visible both labially and palatally. Fractured fragment was loosely attached to the tooth. There was no injury to the adjacent hard and soft tissue. On

radiographic examination it was found that there was no associated root fracture and the periapical tissue was healthy (Figure 2). As the fractured segment was available, the treatment plan decided was reattachment of the fractured segment. The treatment procedure was explained to the patient and she agreed to it.

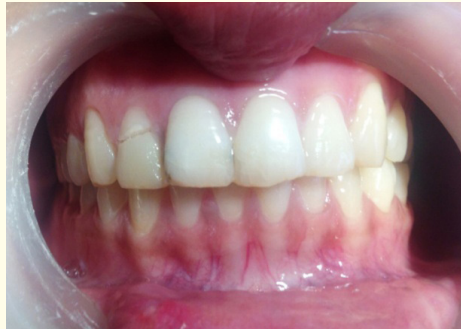

Figure 1: Pre-operative photograph.

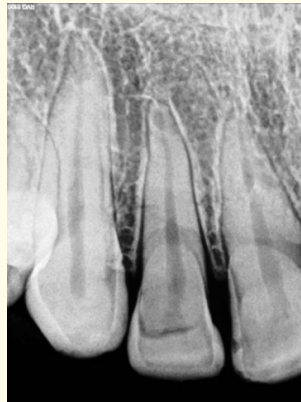

Figure 2: Pre-operative radiograph.

After administering local anesthesia, the fractured part was carefully removed and to prevent dehydration and discoloration, the original fragment was kept in distilled water till the completion of root canal treatment and post space preparation (Figure 3). Isolation was achieved using rubber dam and saliva ejector placed in position. Access opening was done and working length was determined with the help of apex locator (SmarPex, Meta Biomed) and later confirmed by radiograph. A glide path was prepared till no. 15 K files (Dentsply Maillefer, Switzerland). The biomechanical preparation was done with Protaper (Dentsply Maillefer, Switzerland) rotary file system. The last file used in the canal was F3. 2.5% sodium hypochloride and normal saline were used as irrigants. After the completion of biomechanical preparation, root canal was dried with the help of paper points (Dentsply Maillefer, Switzerland). The obturation was done with the help of F3 (Dentsply Maillefer, Switzerland) gutta-percha point using AH plus (Dentsply Maillefer, Switzerland) sealer following cold lateral compaction technique (Figure 4). After the completion of single visit root canal treatment, post space was prepared. Guttapercha filling was removed from two third of canal with the help of peeso-reamers till #4 (MANI), retaining approximately 5-6mm of gutta-percha apically. Parapost Fiber lux (Coltene Whaledent) reamer size no. 5 was used to shape the post space (Figure 5).

Corresponding size fiber post (Fiber Lux-Coltene) was placed in the root canal to the desired length and confirmed with the help of a radiograph. After the post length was confirmed, it was trimmed leaving about 2mm of post beyond the tooth to be adjusted within the fractured segment so that the fractured segment regains its original position as it was before fracture. The fractured fragment was prepared in such a way so as to receive the exposed 2mm of post and approximate to the remaining tooth structure with minimum discrepancy. The alignment of the coronal fragment was verified with the post. Once the length of the post and its alignment with the fractured segment was confirmed, the canal was dried and a non-rinse conditioner (Parabond CW) was applied for 30 seconds in the root canal. Excess was blown away with stream of air. Bonding agent (Parabond CW) was mixed according to manufacturer's instruction in 1:1 ratio and applied to root canal. It was left for 30 seconds; excess was blown away with stream of air. The post was then luted in the canal using dual cured resin luting cement and cured. Inner portion of the coronal fragment was etched and bonded to the tooth using flowable composite resin (EsthetX Flow, Dentsply) after proper shade matching and is cured. After curing, postoperative IOPA was done to check the proper placement of fiber post and fractured crown segment (Figure 6). The fracture line labially was then masked using composite resin (EsthetX, Dentsply) (Figure 7). The composite was then polished with polishing disks (Sof-lex, 3M/ESPE). Follow up examinations were carried out after one week, three month, one year and two years, the tooth was functional and asymptomatic (Figure 8, 9).



Figure 3: Fractured segment stored in normal saline

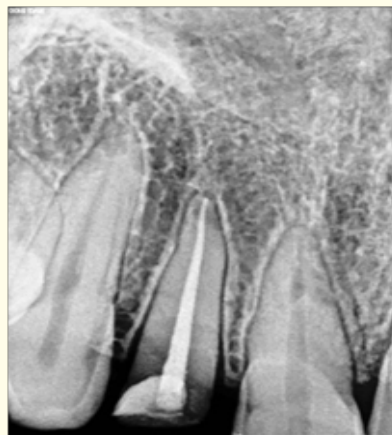


Figure 4: Radiograph of completed root canal treatment

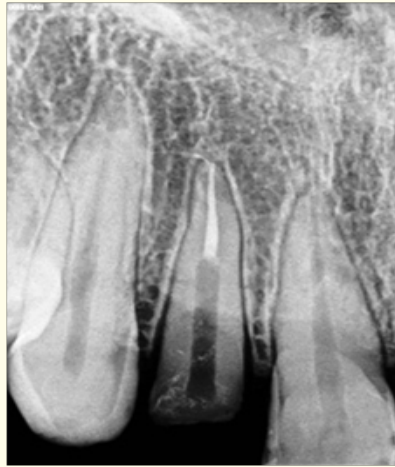

Figure 5: Post space radiograph.

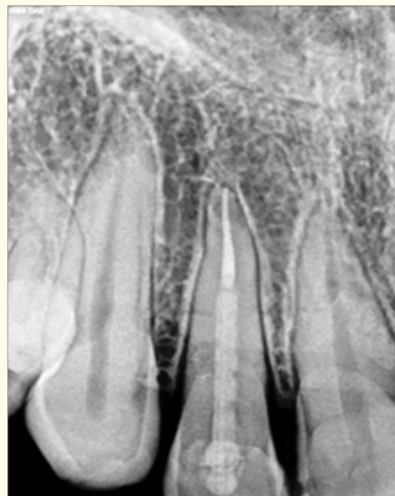

Figure 6: Post-operative radiograph.

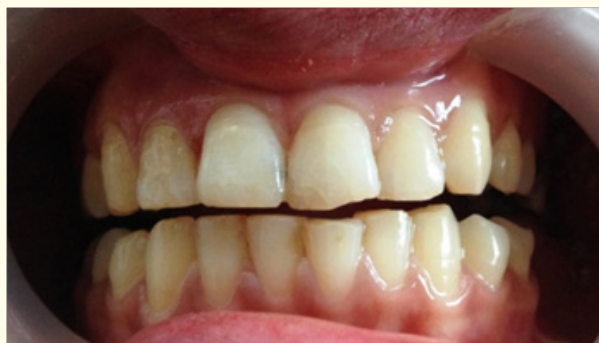

Figure 7: Post-operative photograph.

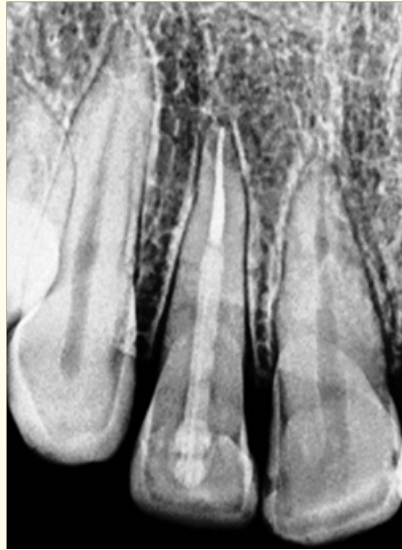

Figure 8: Follow up radiograph after 2 years.

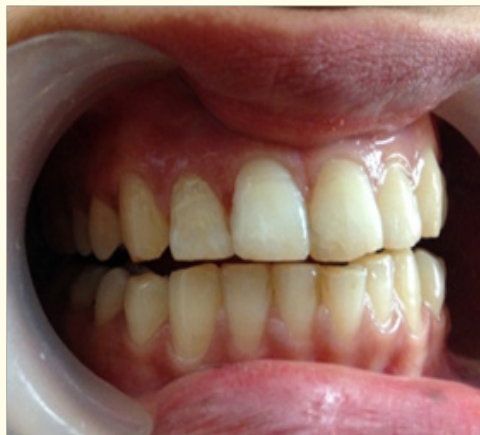

Figure 9: Follow up photograph after 2 years.

Discussion

Trauma with accompanying fracture of anterior teeth is a tragic experience for the young patients and requires immediate attention, not only because of the damage to the dentition but also due to psychological effect of the trauma to the patient. It has however been found that there is a positive emotional and social response from the patient to the preservation of natural tooth structure [10]. Functional, esthetic, and biologic restoration of the fractured incisor often present a daunting clinical challenge [11]. Protection of mechanical and functional integrity is one of the most important factors in the restoration of traumatized anterior teeth. There are many different treatment modalities for restoration of traumatized teeth such as composite resin restorations with or without pins and prosthetic repair [12].

Whenever the fractured fragment is available intact as in this case, the reattachment of the fragment has to be the most desired treatment. Using a natural tooth structure within a single appointment provides functional, esthetic and very cost effective treatment alternative to the patient. With advances in adhesive dentistry, the process of fragment reattachment has become simplified and more reliable [13]. The use of post and core is recommended when more than 50% of the coronal tooth structure is lost. It has been discussed extensively in literature that the use of post and core do not strengthen endodontically treated teeth but use of post for strengthening the reattached coronal fragment is justified [14]. Recently, different types of post materials have been introduced into the dental practice such as carbon fiber, quartz, and glass fiber [15]. The use of fiber post with composite core is also recommended as it can create a monobloc which is a multilayered structure with no weak interlayer interfaces [16].

Follow-up visits are critically important for all traumatic injuries. The patient should be followed for 3, 6, 12 months and yearly for 5 years [17]. Esthetics, tooth mobility, and periodontal status should be confirmed both clinically and radio-graphically on these follow-up visits. Fracture tooth reattachment allows restoration of the tooth with minimal damage to the remaining tooth structure. Various problems like differential wear of restorative material, unmatched shades and difficulty of contour and texture reproduction associated with other restorative techniques can be eliminated by the use of natural tooth structure [18].

Conclusion

This case report presents the progress in adhesive technology. Fiber reinforced resins allow not only creation of esthetic restoration but also the preservation and reinforcement to tooth structure. Time is also an important factor and should be considered in the management of trauma, especially in anterior teeth. Most of the reattachment procedures can be completed in single appointment, even in case of complicated crown fractures as done in the above case. At the 2-year follow-up, the resultant appearance was acceptable to the patient. However, before recommending a similar treatment on a regular basis, a longer follow-up period is required.

Bibliography

1. Bruschi, *et al.* "Reattachment of anterior fractured teeth: Effect of materials and techniques on impact strength". *Dental Traumatology* 26.4 (2010): 315-322.
2. Aggarwal V, *et al.* "Complicated crown fractures-management and treatment options". *International Endodontic Journal* 42.8 (2009): 740-753.
3. Villat C., *et al.* "Multidisciplinary approach to the immediate esthetic repair and long-term treatment of an oblique crown-root fracture". *Dental Traumatology* 20.1 (2004): 56-60.
4. Meiers JC and Kazemi RB. "Chair side replacement of posterior teeth using a prefabricated fiber-reinforced resin composite framework technique: A case report". *Journal of Esthetic and Restorative Dentistry* 17.6 (2005): 335-342.
5. Murchison DF, *et al.* "Incisal edge reattachment: indications for use and clinical technique". *British Dental Journal* 186.12 (1999): 614-619.
6. Murchison DF and Worthington RB. "Incisal edge reattachment: literature review and treatment perspectives". *Compendium of Continuing Education in Dentistry* 19.7 (1998): 731-734.
7. Simonsen RJ. "Restoration of a fractured central incisor using original tooth fragment". *Journal of American Dental Association* 105.4 (1982): 646-648.
8. Anil Kumar S and Jyothi KN. "Reattachment of fractured tooth using self etching adhesive and esthetic fiber post". *Journal of Dental Science and Research* 1.2 (2010): 75-83.

9. Zorba YO and Ozcan E. "Reattachment of coronal fragment using fiber-reinforced post: A case report". *European Journal of Dentistry* 1.3 (2007): 174-178.
10. Hegde RJ. "Tooth fragment reattachment-an esthetic alternative: Report of a case". *Journal of Indian Society of Pedodontics and Preventive Dentistry* 21.3 (2003): 117-119.
11. Murchison DF, *et al.* "Incisal edge reattachment: Indications for use and clinical technique". *British Dental Journal* 186 (1999): 614-619.
12. Ozel E, *et al.* "Two-year follow-up of fractured anterior teeth restored with direct composite resin: Report of three cases". *Dental Traumatology* 24.5 (2008): 589-592.
13. Wolcott J and Averbach RE. "Management of complicated crown fractures: tooth fragment reattachment". *Compendium of Continuing Education in Dentistry* 23.6 (2002): 520-524.
14. Hegde GS, *et al.* "Use of quartz fiber post for reattachment of complex crown root fractures: A 4-year follow up". *Journal of Conservative Dentistry* 17.4 (2014): 389-392.
15. Asmussen E, *et al.* "Stiffness, elastic limit, and strength of newer types of endodontic posts". *Journal of Dentistry* 27 (1999): 275-278.
16. Hayashi M, *et al.* "Fracture resistance of pulpless teeth restored with post-cores and crowns". *Dental Materials* 22.5 (2006): 477-485.
17. Rajput A, *et al.* "Uncomplicated crown fracture, complicated crown-root fracture, and horizontal root fracture simultaneously treated in a patient during emergency visit: A case report". *Oral Surgery Oral Medicine Oral Pathology Oral Radiology Endodontics* 107.2 (2009): e48-e52.
18. Maia EA, *et al.* "Tooth fragment reattachment: Fundamentals of the technique and two case reports". *Quintessence International* 34.2 (2003): 99-107.

Volume 4 Issue 1 April 2016

© All rights reserved by Kulwant Rai, *et al.*