

## Pick Up Impression: An Accurate Impression Technique for Successful Prosthetic Treatment

Nissaf Daouahi\*, Dalenda Hadyaoui, Mohamed ben Khelifa, Hassen Harzallah, Jilani Saafi, Hayet Hajjemi and Mounir Cherif

Department of fixed Prosthodontics, Faculty of Dentistry, Tunisia

\*Corresponding Author: Nissaf Daouahi, Department of fixed Prosthodontics, Faculty of Dentistry, Tunisia.

Received: November 06, 2015; Published: December 14, 2015

### Abstract

The Success of Implant is related not only to Implant placement but also to the accuracy of the impression which constitute the basis for a successful Prosthetic treatment. An impression procedure that reproduces the intraoral relationship of implants is the first step in achieving an accurately fitting prosthesis. Two commonly used implant impression techniques are the closed tray and the open tray techniques. This article is describing the pickup technique through a clinical report. It focused on its advantages in comparison with the closed tray technique.

**Keywords:** Implant; Pick up; Impression; Accuracy; Coping; Open tray

### Background

Recently, dental implants have been widely used for the rehabilitation of partially and fully edentulous areas. All clinicians are in general agreement that, imprecise implant supported prostheses may result not only in mechanical complications including screw loosening, fracture of the prosthesis or implant components, but also biological complications such as loss of osseointegration and marginal bone loss. Passive union between the prostheses' connections and the implants is considered as necessary condition for success of the therapy. That's why obtaining an accurate working cast seems to be a first step to achieve desirable outcomes. The achievement of a properly adaptation of the prosthesis with a minimized misfit requires an accurate impression which must be executed to prevent either mechanical or biological failures. So, obtaining an accurate working cast seems to be a first step to achieve desirable outcomes [1]. In fact, it allows a correct positioning of the implants in oral cavity. According to authors, many factors are affecting the accuracy of the implant impressions including the type of impression copings, surface treatment of the impression copings, direct or indirect impression techniques and different impression materials [1,2].

Different impression techniques, including indirect technique with closed tray, direct technique with open tray, and direct technique splinted with acrylic resin, have been analyzed since 1990 using *in vitro* studies but the results were extremely non-homogeneous [3]. Generally, there are two commonly used implant impression techniques. They are the closed tray and the open tray techniques. In the closed tray technique, the impression copings remain attached to the implants intraorally when the impression is removed from mouth. They have then to be positioned in the impression. In the open tray technique the copings are removed from the mouth along with the impression.

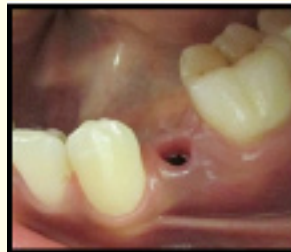Errors can occur on removal and replacement of the transfer type impression copings, especially in the occluso-gingival direction when performing a direct impression technique using a closed tray. For that, Pick up type impression copings is considered as the most accurate impression technique. However, there are limited indications to use the pickup technique. In fact, in cases with limited mouth opening there may not be sufficient space for access to the screws retaining pick up type impression [4].

**Citation:** Nissaf Daouahi., *et al.* " Pick Up Impression: An Accurate Impression Technique for Successful Prosthetic Treatment". *EC Dental Science* 3.3 (2015): 508-512.

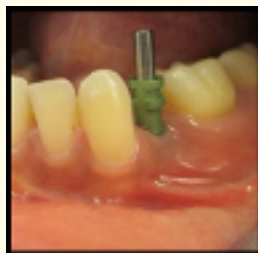### Clinical Presentation

A 23 year old female patient presented to the department of fixed prosthodontics for prosthetic replacement of her missing mandibular premolar. Clinical and radiographic evaluation (CBCT) showed the feasibility of implant placement in the edentulous site. It revealed thick cortical bone and adequate cancellous bone of type 3 quality in the premolar and molar area. The edentulous ridge was measured and it was suitable for adequate dimensions of second premolar. A flapless surgical technique was used for implant placement (Drive System; diameter 3.75 mm; Length 10 mm). Peri implant bone was also subsequently monitored by radiological control. Osseointegration was excellent and no bone resorption has been observed around the implant. After a period of healing and management of peri implant soft tissues, an accurate impression using the Pick-up technique was then performed. It uses square copings and an open tray allowing the coronal coping screw to be exposed. The copings are then unscrewed to be removed along with the impression. The analogs are connected to the copings to fabricate de definitive cast.

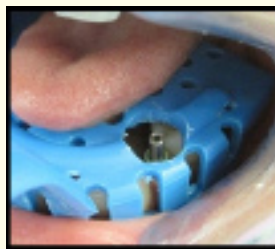
The abutment was selected and prepared according to the adjacent and opposite teeth. Final restoration, which consists on metal ceramic crown, was performed and cemented using Zinc phosphate cement.



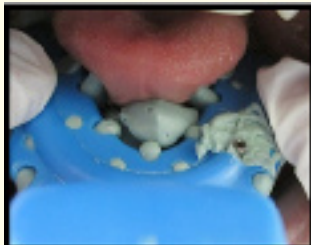*Figure 1: Management of peri implant soft tissues.*



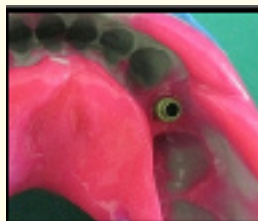
*Figure 2: The coping is screwed to the implant.*



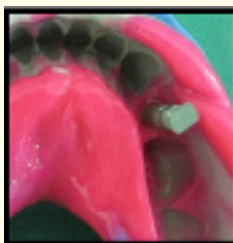*Figure 3: Open tray try in.*



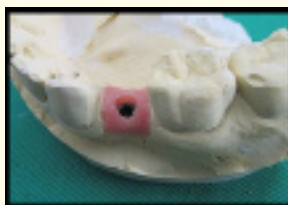*Figure 4: Pick up impression.*



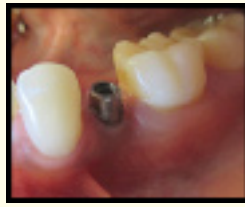*Figure 5: Coping removed with the impression.*



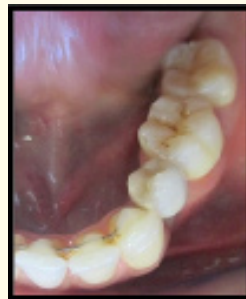*Figure 6: The implant analogue is connected to the coping.*



*Figure 7: Working cast.*



*Figure 8: Abutment preparation.*



*Figure 9: Final restoration; cemented metal ceramic crown with reduced buccolingually diameter.*

## Discussion

Passive adaptation of the prosthetic superstructure seems to be an important factor for success in implant-supported prosthesis [5]. According to Eames., *et al.* [] in order to obtain suitable and reliable superstructures, it is important to maintain fidelity with the impression procedures. That's why the reproduction of the intra-oral relationship of implants through impression procedures is considered as the first step for the achievement of accurate and passive fit prosthesis [6].

The choice of the type of impression technique is strongly related to the clinical situation, implant systems and/or prosthetic components used. Currently, the main impression techniques used are: closed tray with tapered copings and open tray with square copings. They may be used together or not. Open tray technique is indicated especially with non parallel implants. Greater accuracy of pick up technique is strongly related to the fact that transfers are removed together with the model and do not need to be repositioned inside the impression. This advantage minimizes errors. It reduces the effect of implant angulations and decreases deformation of the impression material. In the same time, a special care should be taken during clinical and laboratory phases.

In fact, movement of impression copings inside the impression material using an open-tray impression technique can cause inaccuracy in three dimensional spatial orientations of implants. This, also, leads to un precise prosthesis which may require corrective procedures [8].

There may be clinical situations in which the use of the closed tray technique is indicated including situations with limited inter-arch space, difficult access to posterior implants. In such situations, a rigid connection between the transfers is accomplished with a chemically-activated acrylic resin avoids movement and rotation of the transfers inside the model leading to a precise working cast [6,7].

According to studies there is no significant difference between the accuracy of the closed tray technique and unsplinted open tray technique at up to 15 degrees of angulation. These findings are related to the fact that most research has focused on the accuracy of techniques with parallel implants. Non parallel implants are commonly encountered in clinical situations.

### Conclusion

Reproduction of the intra-oral relationship of implants is considered as the first step in achieving an accurate and passive fit prosthesis. The accuracy of casts is strongly related to appropriate selection of impression materials and technique. Pick up technique seems to be the most accurate one because it allows direct access to the screws that hold the transfer copings correctly positioned against each implant.

### Bibliography

1. Aline Trembl. "Comparative evaluation of the accuracy of pick up transfer impressions performed with two different types of trays". *RSBO* 10.2 (2013): 128-134.
2. Si Hoon Jo and Kyoung Il Kim. "Effect of impression coping and implant angulation on the accuracy of implant impressions: an *in vitro* study". *Journal of Advanced Prosthodontics* 2.4 (2010): 128-133.
3. Chee and S Jivraj "Clinical study evaluating the discrepancy of two different impression techniques of four implants in an edentulous jaw". *Clinical Oral Investigations* 17.8 (2013): 1929-1935.
4. Lee H., et al. "The accuracy of implant impressions: a systematic review". *Journal of Prosthetic Dentistry* 100.4 (2008): 285-291.
5. Anil Sharma and Anuj Chhabra. "contemporary impression techniques in implant prosthodontics". *Indian Journal of Dental Sciences* 2.6 (2010): 61.
6. Heeje Lee and Joseph S So. "The accuracy of implant impressions: A systematic review". *Journal of Prosthetic Dentistry* 100.4 (2008): 285-291.
7. Paolo Vigolo., et al. "An evaluation of impression techniques for multiple internal connection implant prostheses". *Journal of Prosthetic Dentistry* 92.5 (2004): 470-46.

**Volume 3 Issue 3 December 2015**

© All rights are reserved by Nissaf Daouahi., et al.