

## Prosthetic Rehabilitation of Bilateral Cranial Defects: A Case Report

Godwin Clovis Da Costa<sup>1\*</sup>, Meena Aras<sup>1</sup>, Vidya Chitre<sup>1</sup>, Rajdeep Pavaskar<sup>2</sup> and Praveen Rajagopal<sup>1</sup>

<sup>1</sup>Department of Prosthodontics, Government Dental College and Hospital, Goa University, India

<sup>2</sup>Department of Conservative dentistry, Goa Dental College and Hospital, Goa University, India

**\*Corresponding Author:** Godwin Clovis Da Costa, Department of Prosthodontics, Government Dental College and Hospital, Goa University, Goa, 403601, India.

**Received:** July 11, 2015; **Published:** August 18, 2015

### Abstract

Cranial defects may result from trauma, disease, and congenital malformations. Repair of cranial defects is indicated to protect underlying brain tissue, provide pain relief at the defect site, improve cosmesis, and minimize patient anxiety. Cranioplasty is accomplished either with osteoplastic reconstruction or restoration with alloplastic implants. Cranial alloplastic implant materials used include metal, acrylic resin, polyethylene, and silicone. As an ever increasing number of expensive biomaterials for bone replacement have become available PMMA remains a cheap and readily available option that is potentially under used. There are no long term studies or case series published with the use of heat cure PMMA to the best of our knowledge. This case report describes the rehabilitation of a cranial defect using heat cure polymethacrylate resin with a novel impression technique to develop the external contour of the defect using modelling clay.

**Keywords:** cranioplasty; acrylic; PMMA; cranial defect

### Introduction

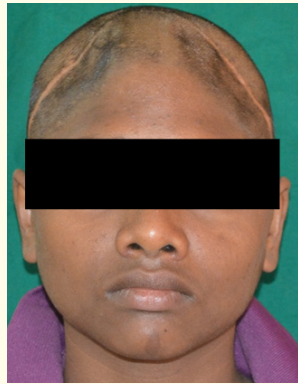*Cranioplasty* is the surgical intervention to repair cranial defects. Many different types of materials were used throughout the history of cranioplasty; judicious use of these materials is the key to success in cranioplasty. This case report illustrates the neuro prosthetic rehabilitation of a 25 year old male with cranial defects involving the frontal, temporal and parietal bones. It provides an evidence based approach to implant material selection and fabrication, leading to aesthetic and functional success.

### Case Report

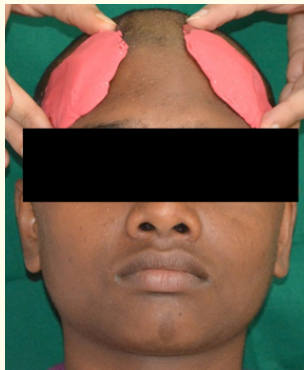A 15 year old male patient reported to the department of prosthodontics with a history of trauma from a road traffic accident six months prior, following which he underwent a craniectomy procedure. The craniectomy led to a defect in the form of a depression measuring 6 x 5 inches (Figure 1).

The patient had no other relevant medical history as on the day he reported, he was well oriented in time, space with no signs of amnesia. It was decided to rehabilitate the patient using heat cure PMMA cranial prosthesis. Modelling Wax (Modelling Wax No 2 Hindustan Dental Products) was heated and adapted to the defect the outer contour was developed using modelling clay (Play-doh modelling clay lego products) (figure 2). It was important to fabricate the plate marginally larger than the defect so that the prosthesis does not dip into the defect and lead to an unacceptable contour (Figure 3). The wax and clay pattern was then invested, dewaxed and acrylised at 1680F for 12 hours. The PMMA implant was retrieved finished and polished. Perforations were made using a 2 mm round bur. The prosthesis was tried on the patient for accuracy of fit and contour. Gutta percha radiographic markers were embedded into the prosthesis (Figure 4). It was then sterilised in 2% glutaraldehyde for 48 hours. The PMMA implants were then placed by the department of neurosurgery under general anaesthesia after raising the flap of the scalp. The implants were stabilised with the help of non-absorbable suture material (Figure 5). Follow up was done at 72 hours, 1 week, 3 months and yearly basis.

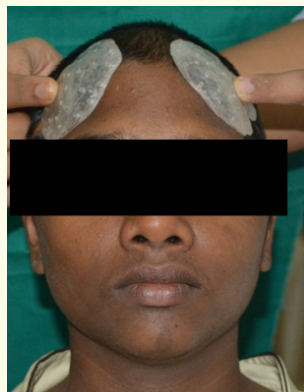**Citation:** Godwin Clovis Da Costa., *et al.* "Prosthetic Rehabilitation of Bilateral Cranial Defects: A Case Report". *EC Dental Science* 2.2 (2015): 266-270.



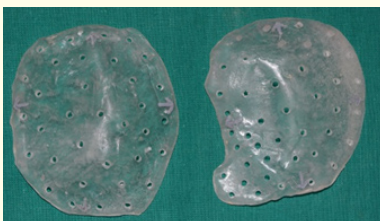*Figure 1: Preoperative frontal view.*



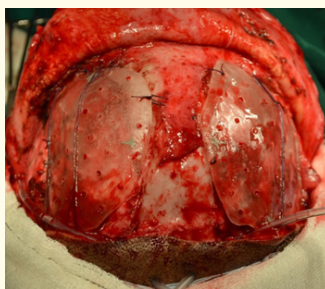
*Figure 2: Duplication of the external contour in modelling clay.*



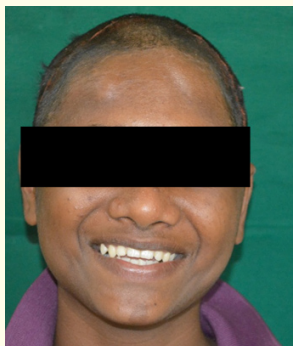*Figure 3: Trial of the PMMA implants and*



**Figure 4:** Incorporation of gutta percha markers for radiographic evaluation.



**Figure 5:** Surgical placement of the acrylic implant.



**Figure 6:** Post-operative frontal view.

### Discussion

Cranioplasty is the surgical intervention to repair cranial defects in both cosmetic and functional ways. The aim of cranioplasty is not only a cosmetic issue; also, the repair of cranial defects gives relief to psychological drawbacks and increases the social performances [1]. Cranioplasty in this case was done to rehabilitate a cranial defect following trauma, which accounts for 64% of all cases [2]. Other indications for cranioplasty include tumour removal or decompressive craniectomies. Growing skull fractures and congenital anomalies are common causes in children younger than 3 years [3]. Hydrocephalus, infection, and brain swelling are known contraindications for cranioplasty, there was no sign of residual infection in our case or any other systemic involvement. Preoperative routine blood and radiographic investigations were carried out prior to the surgery.

An ideal cranioplasty material must fit the cranial defect and achieve complete closure. It should be radiolucent, resistant to infections, not dilate with heat, and withstand biomechanical processes, easy to shape, inexpensive and ready to use [4]. Autografts from the cranium, tibia, ribs, scapula, fascia, sternum and ilium have been tried in the past with little success. Autogenous bone is usually preferred over alloplastic material; although, even cranial bone graft may be unpredictable and the potential donor site morbidity is a disadvantage [5]. Moreover cranial contour cannot be obtained easily with tibia grafts while grafts obtained from the sternum and ilium, undergo resorption more often [6].

Historically, the Incas used gold and silver in cranioplasty other metal allografts include aluminium, gold, silver, tantalum, stainless steel, titanium, lead, platinum and vitallium. Heat conduction, difficulty to shape, and radio-opacity has limited their use as a suitable cranioplasty material. Recently, titanium meshes were used as a support to cement materials. In this way, the strong resistance against mechanical stress of the titanium and the ability to remodelling of the cement materials were combined. It also showed good resistance to infection, even when in contact with the paranasal sinuses. However, it is not a good option in cases with bad skin viability like multiple operations and radiotherapy [7].

Non metal allografts include Celluloids, Methyl-methacrylate, Hydroxyapatite, Polyethylene, Silicon, Chorale, Ceramic and Cortoss™. Celluloids resulted in postoperative fluid collection and the need of aspiration of this fluid [4]. While the advantages of hydroxyapatite are minimal tissue reaction, increased bone repair, and good osteointegration, the most prominent disadvantage is that this material is not very resistant to mechanical stress and can easily break [8]. Silicon has been discontinued due to its soft built while chorale and ceramics lacked durability. Cortoss™ was not used due to the financial shortcomings of the patient.

Heat cured Poly Methyl Methacrylate (PMMA) was the material of choice for the implant fabrication, since it is easy to shape, lighter in weight, poor conductor of heat and radiolucent. The heat cured PMMA implant was fixed to the adjacent bone with the help of restorable suture material which provided initial primary stability. The perforations created in the prosthesis also helped in retention. Animal experiments have revealed that acrylic adheres to the dura mater with no reaction to other underlying layers [9].

A major disadvantage of using PMMA includes heat generation during its setting reaction which could cause harm to the underlying tissues and traces of residual monomer found have been reported to be carcinogenic [10]. The former was addressed by adopting heat cured PMMA implants which were fabricated by an indirect approach which also helped achieve proper contour and a smoother finish. Methods for reducing the residual monomer content of polymerised acrylic resins have been described in literature, few authors have advocated the use of water-bath post-polymerisation and others the microwave post-polymerisation for reducing the residual monomer contents [11]. The problem of residual monomer in the heat cured PMMA in this case was addressed by immersing it in water for 48 hours. Due to the radiolucency of the implant, post operative evaluation is limited however the gutta percha radiographic markers incorporated into the prosthesis allowed us to overcome this limitation of the prosthesis.

### Conclusion

Titanium-based implants may obscure follow-up imaging for tumour patients, and that the outcomes regarding hydroxyapatite-based ceramics, although similar to PMMA, are associated with a much higher cost [12]. Heat cure PMMA remains a cost-effective and proven method to repair cranial defects that fulfils the goals of cranial reconstruction for skull defects.

### Bibliography

1. Aydin S., *et al.* "Cranioplasty: Review of materials and techniques". *Journal of Neurosciences in Rural Practice* 2.2 (2011): 162-167.
2. Jaberi J., *et al.* "Long-term clinical outcome analysis of poly-methyl-methacrylate cranioplasty for large skull defects". *Journal of Oral and Maxillofacial Surgery* 71.2 (2013): 81-88.
3. Rish BL., *et al.* "Cranioplasty: a review of 1030 cases of penetrating head injury". *Neurosurgery* 4.5 (1979): 381-385.
4. Blake DP. "The use of synthetics in cranioplasty: a clinical review". *Military Medicine* 159.6 (1994): 466-469.
5. Viterbo F., *et al.* "Cranioplasty: the autograft option". *The Journal of Craniofacial Surgery* 6.1 (1995): 80-83.

6. Rosenthal AH and Buchman SR. "Volume maintenance of inlay bone grafts in the craniofacial skeleton". *Plastic and Reconstructive Surgery* 112.3 (2003): 802-811.
7. Kuttenger JJ and Hardt NJ. "Long-term results following reconstruction of craniofacial defects with titanium micro-mesh systems". *Journal of Cranio-maxillo-facial Surgery* 29.2 (2001): 75-81.
8. Gosain AK. "Hydroxyapatite cement paste cranioplasty for the treatment of temporal hollowing after cranial vault remodeling in a growing child". *The Journal of Craniofacial Surgery* 8.6 (1997): 506-511.
9. Drosos GI, *et al.* "Mechanical characterization of bone graft substitute ceramic cements". *Injury* 43.3 (2012): 266-271.
10. Key F. "Harmful effects of methyl methacrylate and Formaldehyde from acrylic resin denture base materials". *The Saudi Dental Journal* 10 (1999): 23-29.
11. Jorge H, *et al.* "Biocompatibility of denture base acrylic resins". *Gerontology* 24.1 (2007): 52-57.
12. Ruyter IE. "Release of formaldehyde from denture base polymers". *Acta Odontologica Scandinavica* 38.1 (1980): 17-27.

### Volume 2 Issue 2 August 2015

© All rights are reserved by Godwin Clovis Da Costa., *et al.*