

Non-Syndromic Multiple Supernumerary Teeth (Hyperdontia) - A Case Report with 7 Supernumerary Teeth

Ibrahim E El-Hakim*

Department of oral and maxillofacial surgery, Riyadh Colleges of Dentistry and Pharmacy, Saudi Arabia

***Corresponding Author:** Ibrahim E El-Hakim, Professor, Department of oral and maxillofacial surgery, Riyadh Colleges of Dentistry and Pharmacy, Riyadh, Saudi Arabia.

Received: June 12, 2015; **Published:** July 01, 2015

Abstract

This case describes a 30-year old male Yemeni patient who presented with the complaint of pain in the upper right premolar area and frequent lip and tongue biting on the right side. Intraoral examination revealed supernumerary fully erupted premolar palatally causing caries on the first premolar in the arch which was the cause of the chief complaint. Further clinical examination revealed two supernumeraries fully erupted palatally premolars on the left side of the maxillary arch with a supernumerary mesiodense between the upper central incisors which erupted palatally and the right lateral incisor was displaced palatally opposite the left central incisor. It was interesting to find another 3 supernumerary premolars in the lower jaw located lingually opposite the mandibular premolars. Patient was in a good health and there was no sign or symptoms of any associated medical condition. Extraction of the cause of the pain was done and patient was given appointment for further orthodontic consultation, but he lost follow up.

Keywords: *Supernumerary teeth, Maxillofacial Syndromes, Hyperdontia*

Introduction

A supernumerary tooth is one that is additional to the normal series and can be found in almost any region of the dental arch [1]. It is also known as polydontia or hyperdentition [2]. The prevalence for male is higher than that for females [3]. The supernumerary teeth prevalence in the primary and permanent dentition varies between authors, in primary dentitions it was reported to be 0.8% and in permanent dentitions it was 2.1% [4], while Kaya, *et al.* [5] reported a prevalence between 0.2%-0.8% for the primary dentition and 0.5%-5.3% for the permanent dentition, although Anthonappa, *et al.* [3] concluded that the prevalence of supernumerary teeth is higher than that indicated in the published reports and ranges from 2.4 percent to six percent or possibly even higher.

The exact etiology of supernumerary teeth is unknown; however, several theories have been postulated to explain their presence. Generally they resulted from any disturbance in the initiation and proliferation stages of odontogenesis [6]. Gardiner [7] suggested three possible mechanisms, including an abnormal proliferation of the dental lamina, an additional follicle, and an extension of the dental lamina after the deciduous as well as permanent follicles. Also Levine [8] suggested that it is formed as a result of local independent condition of hyperactivity of the dental lamina. Another theory suggested the dichotomy of the tooth bud (in which the whole tooth bud is divided into two parts) as an etiological factor [9]. Genetics and heredity factors were also considered to contribute to the development of supernumerary teeth, as these have been diagnosed in twins, siblings and sequential generations of a family than in the general population [1]. Khambete and Kumar [10] reported the presence of multiple supernumerary teeth without presence of any other syndrome in 3 generations; father, son, and two grandsons.

Citation: Ibrahim E El-Hakim. "Non-Syndromic Multiple Supernumerary Teeth (Hyperdontia) - A Case Report with 7 Supernumerary Teeth". *EC Dental Science* 2.1 (2015): 211-215.

The supernumerary teeth may be single, multiple, unilateral or bilateral, erupted or unerupted. Although they have been reported mainly in the mandibular premolar, molar and anterior regions [11], Kulkarni [12] reported the presence of supernumerary teeth in the maxilla; also they may be diagnosed in both jaws at the same time. The most frequent supernumerary teeth identified were mesiodentes, followed by premolars and fourth molars or distal molars [13]. Supernumerary teeth are often found in association with syndromes such as cleidocranial dysplasia, Gardner's syndrome, or cleft lip and palate [11,14]. The occurrence of multiple supernumerary teeth in the absence of an associated systemic condition or syndrome is considered a rare phenomenon [15].

The aim of this report is to document a rare unusual case of multiple supernumerary teeth in both maxilla and mandible in a healthy non-syndromic patient. The patient had 7 supernumerary teeth in both the maxilla and mandible.

Case Report

A 30-year-old Yemini male patient presented to the Department of Oral and Maxillofacial Surgery, King Abdel Aziz University with the chief complaint of pain related to the upper right premolar area and frequent lip and tongue biting on the right side. Family, medical and dental histories were non-contributory. Extra-oral examination did not reveal any abnormality. On intra-oral examination, a well-aligned full complement of teeth up to third molar was present in all quadrants except a carious destructed lower right first molar with fair oral hygiene. There were two supernumerary teeth related to the upper left premolar area which were fully erupted palatally. On the right side there was one extra fully erupted premolar on the palatal side causing caries on the first premolar and clinical examination revealed exposed pulp which was the cause of the main complain. Also there was a mesiodense between the upper central incisors which erupted palatally and the right lateral incisor was displaced palatally opposite the left central incisor (Figure 1). Interesting finding was the presence of another 3 supernumerary premolars in the lower jaw located lingually in the premolar areas (one on the right side and two on the left side) (Figure 2). An Orthopantomograph (Opg) and peri-apical radiographs were taken which did not reveal any other supernumerary teeth in both jaws. A decision was made to extract the premolar and the supernumerary teeth on the right side to relief the patient's complain, and then to refer the patient for orthodontic consultation to align the right lateral incisor which erupted on the left side, and to extract the two supernumerary teeth on the left side, and to extract the three premolars on the mandibular arch, then complete orthodontic treatment. Extraction of the first right premolar was done routinely to relieve the patient's complain and the root of the supernumerary tooth on the right side was broken during extraction and surgically removed and showed root curvature (Figure 3). Patient did not return back to complete the treatment and after calling him he stated that he was relieved from pain, and cannot afford the orthodontic treatment.

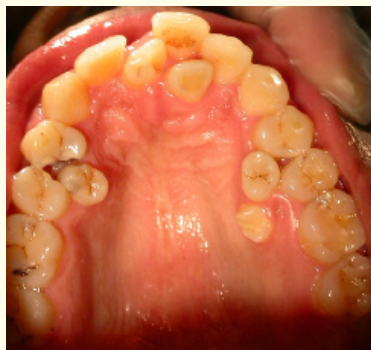

Figure 1: The maxillary arch shows right supernumerary premolar, causing carious lesion on the right premolar. On the left side, there are two supernumerary premolars. A mesiodense can be seen between the central incisor and the right lateral incisor is displaced palatally opposite the left central incisor.

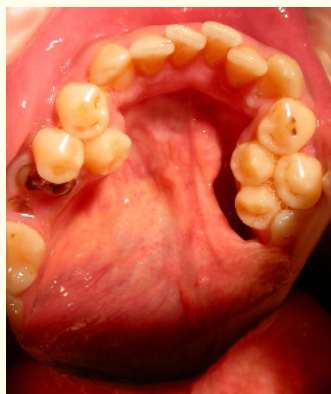


Figure 2: Mandibular arch of the same patient showing one supernumerary premolar tooth lingual to the right premolar, and two supernumerary premolars lingual to the left premolars.

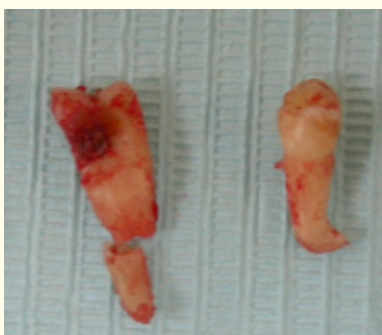

Figure 3: Extracted carious maxillary premolar on the right side together with the right supernumerary right premolar which appears with curved root.

Discussion

The occurrence of multiple supernumerary teeth is a rare phenomenon and is often found in association with syndromes such as cleidocranial dysplasia, Gardner's syndrome, or cleft lip and palate, Fabry-Anderson syndrome, Ehlers-Danlos syndrome [16]. Multiple supernumerary teeth in the absence of associated systemic condition or syndrome is an uncommon phenomenon [17], and only few reports of non-syndromal multiple supernumerary teeth have been reported in the literature [11]. The prevalence of more than three supernumerary teeth is less than 1% [6].

Around 90-98% of supernumerary teeth occur in maxilla, and 90% of these are restricted to pre-maxilla. The most common supernumerary teeth, listed in order of frequency are the mesiodens, maxillary fourth molars, maxillary paramolars, mandibular premolars, maxillary lateral incisors, mandibular fourth molars, and maxillary premolars [11].

Supernumerary teeth can be classified according to the morphology into rudimentary or supplemental; according to the number into single or multiple; and according to location they are classified into mesiodens, paramolars, or distomolars [15]. Single supernumeraries occur in 76% to 86% of cases, double supernumeraries in 12% to 23% of cases, and multiple supernumeraries in less than 1% of cases. The prevalence for non-syndrome multiple supernumerary teeth is less than 1% [18]. In the primary dentition, the morphology of supernumerary teeth is usually normal or conical, while in the permanent dentition four different morphological types of supernumerary teeth were described; these are conical, tuberculate, supplemental and odontome [19,20].

Most of the supernumerary teeth are asymptomatic [21], although they may cause crowding, formation of pathological condition such as dentigerous cyst [1]. The presence of supernumerary teeth may give rise to a variety of clinical problems. These include failure of a tooth to erupt, delayed eruption, ectopic eruption, diastema, rotation of adjacent teeth, displacement of teeth and crowding [22]. In the present case, the supernumerary tooth caused damage to the adjacent premolar tooth; therefore early intervention is required in the form of surgical or orthodontic treatment and combination in order to minimize unwanted side effects to the developing dentition [21]. Careful examination is necessary because they may develop into pathological status such as dentigerous cysts. Surgical removal of such teeth is indicated if evidence of any pathology, such as cystic lesion, resorption, delayed eruption, altered eruption and displacement of adjacent teeth, is evident or has occurred [17]. The case presented herein, is unique in that there are 7 supernumerary teeth in both the mandible and maxilla in a non-syndromic patient.

Extraction is not always the treatment of choice for supernumerary teeth especially if orthodontic treatment is not required or there is no associated pathology [1]. If removal is recommended, the best time to remove supernumerary teeth is at 4-5 years where it exhibits minimum complications. Arrested root development is likely to occur if the supernumerary tooth is removed at 5-6 years, therefore it is best to defer removal at this age unless it is justified by the presence of existing pathology. Removal at 6-7 years carries minimum risk of arresting root development of adjacent permanent teeth. Generally removal at younger age makes the procedure less invasive compared to the delayed approach, because of the ease bone removal in young children and the superficial position of the supernumerary teeth. The exception for these recommendations is those supernumerary teeth that are likely to erupt and those located above the apices of normal teeth [23]. It is essential to enumerate and identify the teeth present clinically and radiographically before a definitive diagnosis and treatment plan regarding supernumerary teeth can be formulated [21].

Conclusion

The supernumerary teeth may be single, multiple, unilateral or bilateral, erupted or unerupted. Supernumerary teeth are often found in association with syndromes such as cleidocranial dysplasia, Gardner's syndrome, or cleft lip and palate. The occurrence of multiple supernumerary teeth in the absence of an associated systemic condition or syndrome is considered a rare phenomenon. The prevalence for non-syndrome multiple supernumerary teeth is less than 1%. It is essential to enumerate and identify the teeth present clinically and radiographically before a definitive diagnosis and treatment plan can be formulated.

Bibliography

1. Garvey MT, et al. "Supernumerary teeth: an overview of classification, diagnosis and management". *Journal of Canadian Dental Association* 65.11 (1999): 612-616.
2. Baker GJ. "Abnormalities of development and eruption". In Baker GJ and Easley J. "Equine Dentistry". WB Saunders Co. London (1999): 53.
3. Anthonappa RP, et al. "Prevalence of supernumerary teeth based on panoramic radiographs revisited". *Journal of Pediatric Dentistry* 35.3 (2013): 257-261.
4. Brook AH. "Dental anomalies of number, form and size: their prevalence in British school children". *Journal of the International Association of Dentistry for Children* 5.2 (1974): 37-53.
5. Kaya GŞ, et al. "Non syndromic supernumerary premolars". *Medicina Oral, Patología Oral y Cirugía Bucal* 16.4 (2011): e522-e525.
6. Rallan M, et al. "Surgical management of multiple supernumerary teeth and an impacted maxillary permanent central incisor". *BMJ Case Reports* May 22; 2013. doi: 10.1136/bcr-2013-009995.

Citation: Ibrahim E El-Hakim. "Non-Syndromic Multiple Supernumerary Teeth (Hyperdontia) - A Case Report with 7 Supernumerary Teeth". *EC Dental Science* 2.1 (2015): 211-215.

7. Gardiner JH. "Supernumerary teeth". *Dental Practice* 12 (1961): 63-73.
8. Levine N. "The clinical management of supernumerary teeth". *Journal of Canadian Dental Association* 28 (1961): 297-303.
9. Liu JF. "Characteristics of pre-maxillary supernumerary teeth: a survey of 112 cases". *ASDC journal of dentistry for children* 62.4 (1995): 262-265.
10. Khambete N and Kumar R. "Genetics and presence of non-syndromic supernumerary teeth: A mystery case report and review of literature". *Contemporary Clinical Dentistry* 2012;3: 499-502.
11. Orhan AI, *et al.* "Familial occurrence of non-syndromal multiple supernumerary teeth: a rare condition". *Angle Orthodontist* 76.5 (2006): 891-897.
12. Kulkarni VK, *et al.* "Multidisciplinary management of multiple maxillary anterior supernumerary teeth: a case report". *Quintessence International* 2010; 41(3):191-195.
13. Umweni AA and Osunbor GE. "Non-syndrome multiple supernumerary teeth in Nigerians". *Odonto-stomatologie tropicale* 25 (2002): 43-48.
14. Yildirim D, *et al.* "Case report: multiple impacted permanent and deciduous teeth". *Dentomaxillofacial Radiology* 33.2 (2004): 133-135.
15. Reddy GS, *et al.* "Nonsyndromic bilateral multiple impacted supernumerary mandibular third molars: A rare and unusual case report". *Case Reports in Dentistry* (2013): doi.org/10.1155/2013/857147.
16. Ratson T and Peretz B. "Non-syndromic multiple hyperdontia in monozygotic twin sisters: a report of two cases". *Journal of Dentistry for Children* 81.1 (2014): 50-53.
17. Yadav RK, *et al.* "Non-syndromic multiple supernumerary teeth in permanent dentition: a rare phenomenon". *BMJ Case Reports* May 22; 2013 doi: 10.1136/bcr-2013-009026.
18. Gomes CO, *et al.* "A survey of 460 supernumerary teeth in Brazilian children and adolescents". *International Journal of Paediatric Dentistry* 18.2 (2008): 98-106.
19. Mitchell L. "An Introduction to Orthodontics". 1st edn. Oxford University Press, (1996): 23-25.
20. Andlaw RJ and Rock WP. "A Manual of Paediatric Dentistry". 4th edn. Churchill Livingstone, New York (1996): 156.
21. Kumar A, *et al.* "Supernumerary teeth: Report of four unusual cases". *Contemporary Clinical Dentistry* 3 (2012): S71-S77.
22. Ansari AA, *et al.* "Non-syndromic multiple supernumerary teeth: report of a case with 13 supplemental teeth". *BMJ Case Report* 6 (2013).
23. Omer RS, *et al.* "Determination of the optimum time for surgical removal of anterior supernumerary teeth". *Pediatric Dentistry* 2010; 32:14-20.

Volume 2 Issue 1 July 2015

© All rights are reserved by Ibrahim E El-Hakim.