

## Management of an Incomplete Vertical Root Fracture: An Alternative Clinical Approach and Treatment Finalisation Concept for A Case

M Omer Gorduysus<sup>1,2\*</sup> and Burcu A Pektas<sup>1</sup>

<sup>1</sup>Department of General and Specialist Dental Practice, University of Sharjah, United Arab Emirates

<sup>2</sup>Department of Endodontics, Hacettepe University, Turkey

**\*Corresponding Author:** M Omer Gorduysus, Department of General and Specialist Dental Practice, University of Sharjah, College of Dentistry, United Arab Emirates, Department of Endodontics, Faculty of Dentistry, Hacettepe University, Ankara, Turkey.

**Received:** April 14, 2015; **Published:** June 02, 2015

### Abstract

In this case, the management of an incomplete vertical root fracture of a right lower second molar of sixty years old female patient, the finalization of the treatment and follow-up were presented as an alternative clinical approach versus extracting the tooth.

**Keywords:** *Incomplete vertical root fracture; Root fracture; Treatment finalization; Vertical root fracture*

### Introduction

Patients regularly complain of painful teeth, and it is prudent to determine the cause and providing the indicated treatment. Cracked tooth syndrome (CTS) refers to an incomplete fracture of a vital tooth which describes the clinical character that involves the dentin and may extend to pulp [1]. Patients often report a history of teeth that occasionally give a sharp pain when biting certain foods. Sometimes they can specifically identify the offensive tooth, but often they cannot tell where the pain is coming from [2]. Because of the wide variety of different types of cracks in teeth, there may be a myriad of symptoms and presentations, making the diagnosis of a crack often difficult. The extensiveness of a crack may directly alter the prognosis assessment. Therefore, any possible crack should be examined prior to dental treatment [3].

Cracks in teeth can be divided into three basic categories [3]:

1. Craze lines
2. Fractures (also referred to as cracks)
3. Split roots

Fractures extend deeper into the dentin than superficial craze lines. Dyes and transillumination are very helpful in visualizing potential root fractures [3]. Symptoms from a fractured tooth range from none to severe pain. A fractured tooth may be treated by a simple restoration, endodontics, or even extraction, depending upon the extent and orientation of the fracture, the degree of symptoms, and whether or not the symptoms can be eliminated [3]. Fractures may be present prior to endodontic treatment, secondary to endodontic treatment, or they may develop after endodontic treatment has been completed. Typically, these cracks lead to a split root, leaving the tooth with a poor prognosis. Therefore, diagnosing the existence and extent of a vertical root fracture is imperative prior to any restorative or endodontic treatment since these cracks can dramatically affect the overall success of treatment [3].

Vertical root fractures may arise from a physical traumatic injury, occlusal prematurities [4], repetitive parafunctional habits of heavy stressful chewing [5], or resorption-induced pathologic root fractures [6]. However, the most common cause of vertical root fractures may be iatrogenic dental treatment [4,6,7]. Dental Procedures such as the placement of posts and pins [8,9] or the tapping into place of a tightly

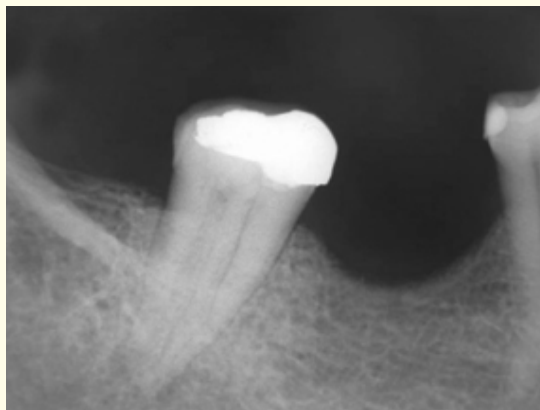
**Citation:** M Omer Gorduysus and Burcu A Pektas. "Management of an Incomplete Vertical Root Fracture: An Alternative Clinical Approach and Treatment Finalisation Concept for a Case" *EC Dental Science* 1.4 (2015): 180-185.

fitting post or intra coranal restoration may induce a vertical root fracture. The most common dental procedure contributing to vertical root fracture is endodontic treatment [6].

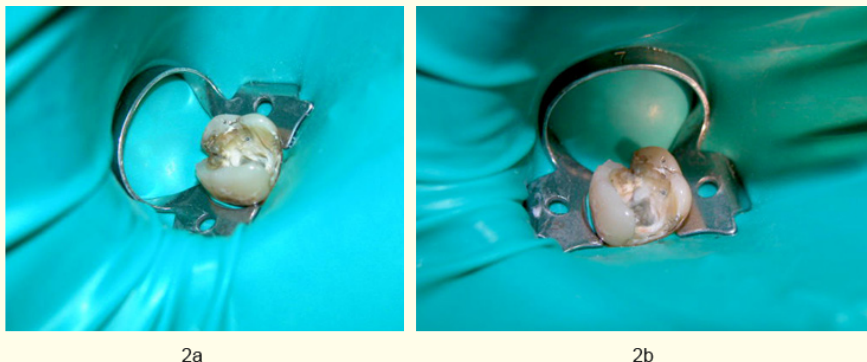
Mandibular second molars have a higher incidence of vertical root fractures, followed by maxillary first molars and maxillary premolars [5]. Dental operating microscope, with magnification capabilities of over 25x, and with superb illumination, the clinician is now capable of observing intracoronal and extra coronal details with great precision [3].

### Methodology

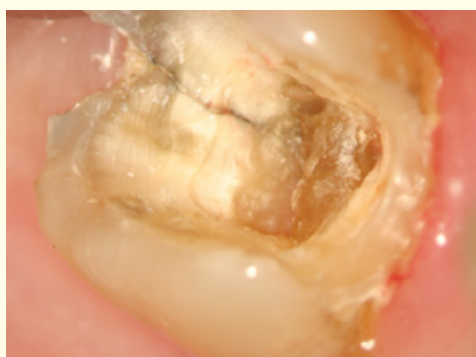
A 60 year-old female patient presented with “intermittent, sharp pain”. An intraoral exam revealed that a large failing amalgam with leaking margins on the right lower second molar. The tooth had a very painful response to percussion. No soft tissue changes recorded. The radiograph of the tooth (Figure 1) exhibited a widened periodontal ligament space but no periradicular radioluceny. The medical and dental histories of the patient were unremarkable. The bite test was increasing the discomfort. Amalgam filling was removed and seen a fracture line prolonged from distal to mesial also alongside of the distal axial wall and also towards to the floor of the pulp chamber partially (Figure 2a-b, Figure 3) conventional root canal therapy was completed with rotary system (ProTaper, Dentsply-Maillefer, Switzerland) and RC Prep (Premier, Norristown, PA, USA) as a lubricant. Copious irrigation with 2% sodium hypochlorite solution was employed throughout the procedure. Obturation of the root canals was performed using Protaper’s gutta-percha (For mesial canals F2 and for distal canal F3) and AH 26 (Dentsply Maillefer) root canal sealer was used (Figure 4) Later the tooth was submitted under the operation microscope to pursuit the incomplete vertical fracture line with Mueller burs and ultrasonic tips until the line disappears as much as possible (Figure 5a-b). After that the tooth was restored with glass ionomer following the bonding of two sides of the remaining craze line at the floor of the pulp chamber with an adhesive which was left over in obligation to the tooth structure and the critical extension of the vertical crack line (Figure 6) and crowned to finalize the case without any post for not to increase the stress over the tooth (Figure 7).



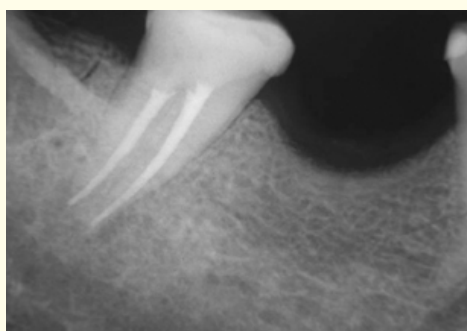
**Figure1:** Initial (preoperative) radiograph.



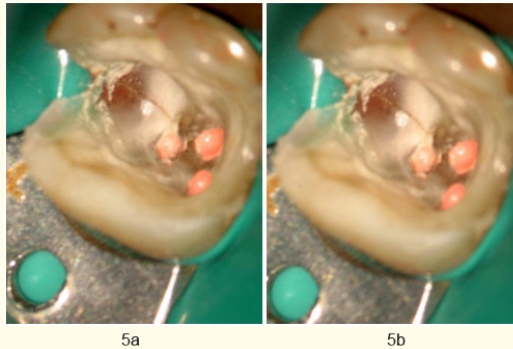
**Figure 2a-b:** Intraoral views of vertical root fracture on the mandibular right second molar with rubber dam.



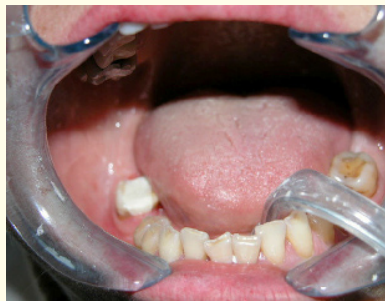**Figure 3:** Intraoral views of vertical root fracture with operation microscope.



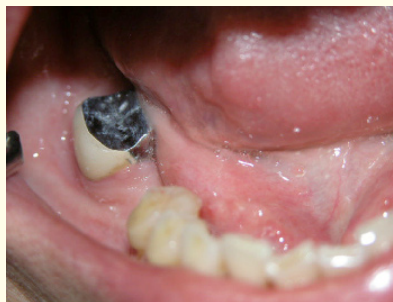**Figure 4:** Final radiograph after endodontic treatment.



*Figure 5a-b: Intraoral views using operation microscope after endodontic treatment.*



*Figure 6: Intraoral view after endodontic therapy, restoration with glass ionomer cement.*



*Figure 7: The finalized restoration with a crown.*

The outcome of the case was successful after one year follow up (Figure 8) and patient was using the tooth without any discomfort and pain, in spite of some small craze line left over. This small craze line which was left over was away from the canals. Removal or pursue of this small craze was not possible technically because of its strategically location which was the structure around it was consolidating the tooth structure and intentionally was decided to be left and decided to followed up.

**Citation:** M Omer Gorduysus and Burcu A Pektas. "Management of an Incomplete Vertical Root Fracture: An Alternative Clinical Approach and Treatment Finalisation Concept for a Case" *EC Dental Science* 1.4 (2015): 180-185.

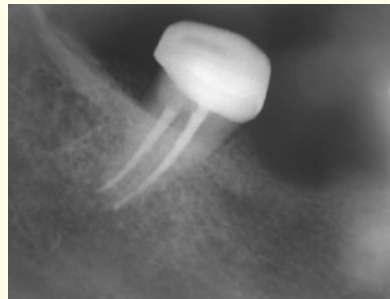


Figure 8: One year follow up.

### Results

In this case the vertical incomplete root fracture of a 60 years old female on her right lower second molar managed successfully and the treatment finalized. After one year follow up patient had no any complaint or any x-ray finding.

### Discussion

Vertical root fractures (VRF) sometimes represented by incomplete vertical lines extend through the long axis of the tooth. According to Gher, *et al.* the incidence of VRF is 2.3% [10]. In the literature generally trauma or iatrogenic factors are mentioned as the main reasons of the VRFs. In our case an old large amalgam filling and possible lateral or vertical forces related the chewing and mastication were the reason of the incomplete VRF which we had diagnosed. In most of the cases extraction seem the only alternative or rarely bonding and observing [11]. In our case we pursued the crack line to eliminate as deeper as possible and the remaining part bonded with a resin. After that the tooth was crowned to prevent the tooth from the forces and consolidate the tooth structure.

### Conclusion

Using the magnification methods (Figure 9a-b-c) and related devices in clinical endodontics increase the success. In that context, the tooth which was mentioned in this case redeemed with an alternative clinical approach to a possible extraction. In this study, as an alternative to extraction, reinstating the comfort and function endodontically in a mandibular second right molar of a 60 years old female patient due to an incomplete vertical root fracture where localized distally.




Figure 9a-b-c: The loop, ultrasonic tips and operation microscope which was used in this case.

### Bibliography

1. Lynch CD and Mc Connell RJ. "The cracked tooth syndrome". *Journal (Canadian Dental Association)* 68.8 (2002): 470-475.
2. Jack DG Jr, DMD, FAGD, Compendium/February 2006/vol.27, No.2.
3. Louis HB and Gary RH. "Pathways of the pulp". Chapter1.
4. Cameron CE. "Cracked tooth syndrome". *Journal of the American Dental Association* 68.3 (1964): 405-411.
5. Yeh CJ. "Fatigue root fracture: a spontaneous root fracture in nonendodontically treated teeth". *British Dental Journal* 182.7 (1997): 261.
6. Bender IB and Freedland JB. "Adult root fracture". *Journal of the American Dental Association* 107.3 (1983): 413-419.
7. Pitts DL and Natkin E. "Diagnosis and treatment of vertical root fractures". *Journal of Endodontics* 9 (1983): 338.
8. Fuss Z, et al. "An evaluation of endodontically treated vertical root fractured teeth: impact of operative procedures". *Journal of Endodontics* 27.1 (2001): 46.
9. Meister F, et al. "Diagnosis and possible causes of vertical root fractures". *Oral Surgery, Oral Medicine, and Oral Pathology* 49.3 (1980): 243-253.
10. Gher ME., et al. "Clinical survey of fractured teeth". *Journal of the American Dental Association* 114.2 (1987): 174-177.
11. Hedge MN., et al. "Vertical root fractures: Review and case report". *Journal of Interdisciplinary Dentistry* 1.2 (2011): 101-104.

**Volume 1 Issue 4 June 2015**

© All rights are reserved by M Omer Gorduysus., et al.