

Review of Skin Disorders after Prolonged Exhaustion and Hunger

Benjamin Yuehtung Lee^{1*} and Julia H Bai²

¹Retired Research Physician from Biochemical Genetics/Pediatrics/Louisiana State University Health Sciences Center, Katy, TX, USA

²Student of Master Program in the Department of Epidemiology, Texas University of A & M, College Station, TX, USA

***Corresponding Author:** Benjamin Yuehtung Lee, Retired Research Physician from Biochemical Genetics/Pediatrics/Louisiana State University Health Sciences Center, Katy, TX, USA.

Received: December 16, 2019; **Published:** December 30, 2019

Abstract

This review describes the common and unique skin disorders observed in a population with severe physical labor and inadequate of food, 1958 - 1962. The common ones were hyperactive dermatographism, palmoplantar fissures, which were usually found among regular people but much less severe. The unique ones were rare, such as palmar crease clefts in a little girl: or terribly severe, such as intra-nail hemorrhage. Nail layering phenomena should be introduced because it may be not rare and can be easily cured. A teenage with congestive burning foot plate and a pediatric fibril case with red eruption due to riboflavin deficiency were also described. Fever and its temperature curve should be reported in another separate paper.

Keywords: *Congestive Burning Soles; Cutaneous Pigmentation Over the Bony Prominence; Hyperactive Dermatographism; Intra-Nail Hemorrhage; Nail Layering Phenomena; Palmar Crease Clefts; Palmoplantar Fissures; Red Eruptions in Ariboflavinosis Fever*

Introduction

Cutaneous lesions are common in nutritional deficiencies, such as scurvy, pellagra, ariboflavinosis, vitamin A deficiency, and kwashiorkor. However, dermal lesions caused by deficiencies of thiamine and/or other B vitamins are seldom reported although they were either very common or very unique as observed in a population with terribly hard labor and inadequate food, 1958 - 1962. These are described in the following with hand drawings.

Case Study

Dermatological lesions

Cutaneous pigmentation over the bony prominence

About one third of cases with obvious emaciation or cachexia had cutaneous brownish pigmentation over the bony prominence. They were found after several months when food supply was not enough or after several weeks when food was drastically reduced. According to the descending order of their frequencies, pigmentation sites are listed in the following as seen in figure 1. No pigmentation was observed overlying the mastoid process behind the ear or the patella of the knee:

- a. The olecranon of the elbow.
- b. The spine of the seventh cervical vertebra,
- c. The great trochanter of the femur.

- d. The lateral malleoli of the ankle.
- e. The tip of coccyx.
- f. The head of the humerus.
- g. The styloid process of the ulna.
- h. The head of the fibula near the knee.

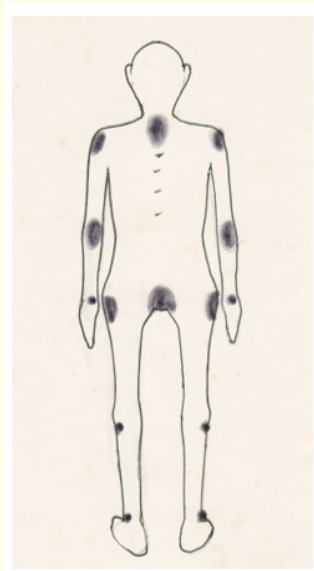


Figure 1: Distribution of cutaneous pigmentation [1].

Pigmentation was dark brownish, like that in Addison's disease. It was a singular circumscribed or oval macule, about 2-10 cm in diameter with a clear border, covering the protruded bony site. It was found usually at the examination without known local signs or symptoms, such as tender, hot, edema, pain, itching, or scaling. Its clinical significance might be the prediction of patient expiration. Death would ensue within weeks when more than 6 sites, regardless their locations, became pigmented. If diet improved, they disappeared within a few months (Figure 1).

Palmoplantar fissures with keratoderma

Isolated fissures are commonly found as perleches in the corner of the mouth, the scrotum, or the anus during ariboflavinosis. Similar skin fissures haven't been described in other vitamin deficiencies. In a large number of labor population, every laborer had dry and callous palms and soles due to prolonged mechanical wear and tear, which had never been the complaints for cure. However, the fissures or clefts on palmoplantar surfaces were very troublesome and intractable clinical problems. Palmar fissures were short, fine, and shallow cracks distributed chiefly at the fingertips, fingers, and sometimes complicated with bleeding or infection.

On the fingertips and the palm, small, thin pyramidal pieces of epidermis would peel up but not detach. These caused pain and made the roughness of palm worse. The largest and deepest cleft or cleavage was between the thumb and the index finger, while on the palmoplantar surfaces, fine fissures interweaved as a dense net. They branched nearly in rectangular angle, not in random.

A typical inverted Y-shaped or an inverted small tree-shaped crack was a conspicuously common feature. It could be seen on each fingertip and the distal palm areas at the website between the finger roots at the palm. The inverted Y-shaped crack was very deep and often painful or bleeding. No fissure was found in the dorsal part of the hand except for a short singular deep fissure, extended from the lateral border of the nails.

Factors accelerating the progress of the fissures included vibration labor, prolonged washing or soaking, cold weather, and menstruation in women. The fine fissures caused mild pain, while the deep fissures were very painful and occasionally accompanied with bleeding or infection. Response to thiamine was dramatic but multiple nutrients worked better.

Fissures in the soles were essentially similar as that in the palms but less numerous. They clustered chiefly in the weight-bearing areas especially the heel. There were two constant large cleavages or folds, one before the heel (the proximal thenar cleavage) and another after the distal end of the first metatarsal bone (the distal thenar cleavage). Some patients also had deep vertical fissures in the Achilles tendon area and then turned to the surface of the heel. These deep fissures or clefts were painful and occasionally accompanied with bleeding or infection. Therapeutic response to nutritional administration or dietary improvement was similar to that of the palm (Figure 2).

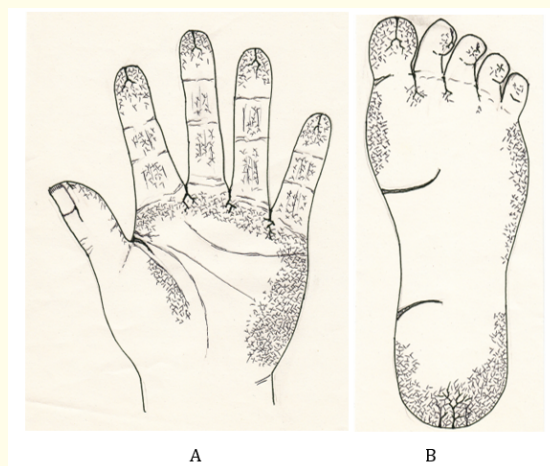


Figure 2: Mild case of palmar (A) and plantar (B) fissures with keratoderma.

Palmar crease clefts

Involvement of palmar creases had never been observed in the adults, however, in a 5 year-old girl, painful, deep, wide clefts along the palmar creases were found in a village of Tianjin west suburban area 1969. Her fingers and her palm were normal. About 2 weeks after the onset of clefts, the thenar creases, and the distal and proximal palmar creases opened about 3 - 5 mm in width, like a fresh incision without local edema or bleeding. Two injections of thiamine 50 mg stopped splitting tendency and pain, and initiated healing. Niacin alone, 50 mg three times a day for the following two days accelerated the healing. Oral niacin 50 mg and thiamine 50 mg, three times a day, for the following 2 weeks led to a complete cure (Figure 3).

Obvious yellow nail lines

According to Pinkus, yellow line is a normal structure at the free edge of the nail [1]. However, this is totally wrong because it is absent in health individuals while in the population of severe hard laborers, these lines became exaggerated. Yellowish, straw-colored, parallel

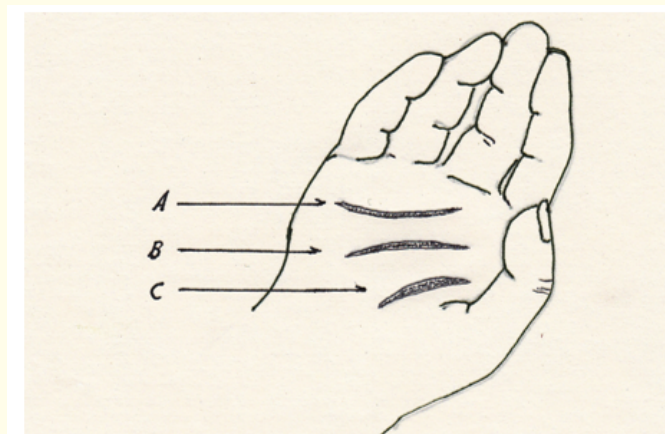


Figure 3: Palmar crease clefts of a 5-year old girl. A. Distal, B. proximal, C. thenar palmar crease.

fine lines in the free margin of the thickened nails were observed in every one. The appearance emulated the longitudinal ridges of the nail. The proximal nail fold and cuticle were lost. The lacuna couldn't be seen. Obvious yellow lines were often preceded or accompanied by other nail abnormalities, such as pitting, transverse line, white spots, or a longitudinal pigmentation band. The transverse white broadband in pellagra, reported by Brownson [2] in 1915 had not been seen. The obvious yellow lines disappeared after dietary improvement, therefore, it was a uniform sign of malnutrition. Similar lines can be observed in other dermatological conditions, such as fungal infections of the nail. Therefore, this sign is non-specific for malnutrition.

Nail layering

Over 75% of cases with severe malnutrition, the nail plate became thickened and separated into two layers. The upper layer was very thin, brittle, flattened or spoon-like (koilonychia). The lower layer was a soft, flattened mass like dirty rubber, inseparable from underlying finger tissue. The separation distance from the free edges of both layers to their conjunction was about 2 - 7 mm (average 3 mm). If a portion of the thin upper layer was accidentally removed, the rough dorsal surface of the lower layer revealed as very regular, grayish slightly yellow colored multiple longitudinal ridges and grooves. Gentle touch of it caused pain. The severity of layering closely correlated with degree of malnutrition. Nutritional therapy, especially thiamine, provided dramatic improvement.

This is caused by the destruction of the nail sealing parts, hyponychium and onychodermal band. And the nail matrix were severely injured due to severe malnutrition. Destruction of hyponychium and onychodermal band opened the detrimental way for nail matrix. The germinal matrix (intermediate matrix) became dysfunctional in producing hardened, flat, translucent, non-living, keratin nail cells. Its distal extension, the sterile matrix on the nail bed, totally failed leading to the formation of hollow space under the thin upper layer (Figure 4).

In a case of 85 years old, her fingers were severely cold injured when she worked all winter days out of the room without gloves at her 21 years old. Her upper thin layer gradually became very thick and clay-like and the lower layer disappeared totally leaving a hollow space underneath in 10 fingers for 64 years [3] (Figure 5).

Her ten finger nails became normal when she received parenteral thiamin therapy for her coronary heart disease. The lower layer regenerated in the following order: small finger in first, and then the middle, the index and the ring fingers. Generation of the lower layer of the thumb nails was very sluggish and incomplete probably due to its heavy thickness and the patient old age.

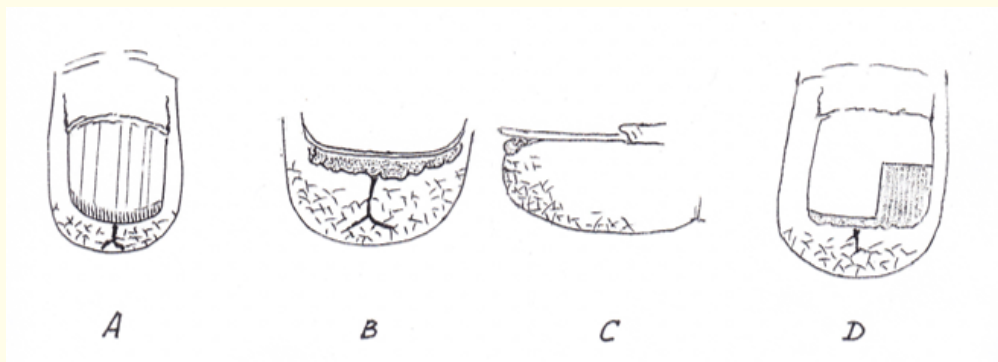


Figure 4: The nail changes. A. The obvious yellow lines and longitudinal ridges on the surface of the nail. B and C. Nail layering, D. longitudinal ridges of the soft lower layer of the nail after removing the upper thin layer.

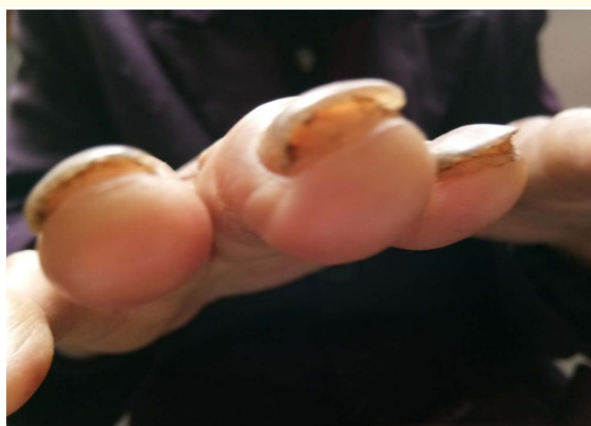

Figure 5: Hollow space under the upper layer.

Intra-nail hemorrhage

Five cases of intra-nail hemorrhage were observed among thousands of laborers within 4 years. Its onset was abrupt without prodrome. The clinical picture consisted of:

- a. **Pain:** An acute, fulminating, severe, and sharp pain occurred simultaneously in 2 - 7 fingertips in one or both hands, including the thumb, the middle, the index and occasionally the ring fingers but excluding the small fifth finger. The tip of the fifth finger was also painful but less in severity and never involved with pigmentation.
- b. **Pigmentation:** Simultaneously or the next day, longitudinal, parallel, red or rustic strips appeared on the distal portion of the involved nails. They were 3 - 7 mm in length and about 1 - 2 mm in width. Longer or more numerous strips were associated with severer pain. The strips diffused slightly along their longitudinal courses without inter-connections. There was no bulge over the strip, and no bleeding in the fingertip or other sites.

- c. **Nail flexion:** Almost simultaneously, the distal portion of the involved nail turned upward conspicuously, forming a clear angle with the remaining large part of the nail. The angle was about 170 degrees and its apex plotted a very clear, visible and fine crescent line, not a groove or long dent, paralleling the free margin of the nail. The unaffected nails had no flexion but sometimes very painful. Nail flexion usually occurred at night and therefore escaped medical observation.
- d. **Avulsion:** Next, the whole epidermis layer beneath the nail of the involved fingertips peeled off extensively up to the distal interphalangeal joint. The fresh tips, with fingerprints, became as red as pork without hemorrhage.
- e. **Thiamin effect:** No analgesic, either tablet or injection, was effective while intramuscular thiamine gave a prompt and dramatic relief. One injection of thiamine 50 mg could keep the patient pain-free for a few hours while a blackening process of the red strips might be initiated. Pain was controlled with 1 - 3 injections of thiamine 50 mg, and then homemade liquid yeast was given. With continuous nutritional therapy, healing would occur over 10 - 15 days. The colored strips became black and their orifices of the blind tunnels could be found at the free edge when you cut the nail. The nail flexion disappeared gradually over about 20 days (Figure 6).

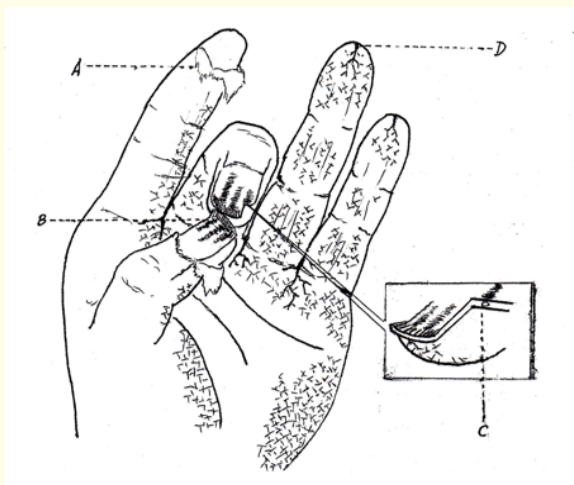


Figure 6: Diagram of intra-nail hemorrhage. A. Avulsion of the involved finger. B. Pigmentation and angle formation at the nail margin. C. A tunnel left along the course of pigmentation. D. Typical fissure at the finger tip.

Congestive burning soles

This case with congestive burning soles was observed in a 15 years old boy. He had experienced with refractory erosive and ulcerate scrotum, which was finally cured with large dose of riboflavin and yeast. Within a few days in the September, his soles or the bottom surfaces of the feet became sore, red, hot, and swelling. They became painful when touching the ground for walking. On physical examination, the whole plantar surfaces including the ventral parts of the toes of both feet became extensively freshly red, warm, and swollen. They were highly congested and edematous, however, no bleeding, tenderness, or loss of sensation. The soles looked 2 times thicker than the normal. The redness and swelling were exactly confined only to the plantar surfaces while the dorsal parts of the feet or legs were free from congestion and edema. The groin lymph nodes were not enlarged. Plantar congestion, edema, and pain vanished without recurrence after injection of vitamin B complex 2 ampules twice a day for 4 days. Each ampule contained thiamin 10 mg, riboflavin derivative 2 mg, niacinamide 30 mg, pyridoxine 2 mg, and pantothenic acid 1 mg. No similar report has ever been found in literature [4,5].

It was not burning feet syndrome, a quite different disease found in US prisoners of war during the 2nd world war from Japanese camp.

Red eruptions in ariboflavinosis fever

Ariboflavinosis fever was commonly found among young children in winter and spring. Three-year old boy in the camp with riboflavin deficiency became febrile in the winter. Several transient freshly red patches of different sizes and shapes were developed during the course of fever although no medication was held before or after fever except for thiamin, ascorbic acid and occasionally aspirin. The eruptions were irregular in shape with clear borders, not above or below the skin surface, and not associated with local edema, swelling, or exudates. They were about 3 - 6 square centimeters in size and scattered around the eyes, on the forehead, the chin, the thorax, and the arms. Essentially, they were transient local congestive lesions without hemorrhage. When scratching the skin gently, no white-line reaction appeared but induced red-line, which became a band and persisted for several minutes. If mildly pressing the skin with a fingertip for a minute, it caused local congestion and the formation of eruption similar as observed in other sites. Patient had cheilosis and bilateral angular stomatitis. His bulbar conjunctiva became congestive immediately around corneas. This sign was characteristic for riboflavin deficiency as reported by HC Hou many decades ago [6]. Fever and red patches vanished dramatically after prompt large doses of riboflavin and no recurrence [7].

Hyperactive dermatographism

Normally, when one scratches the skin with the tip of a fingernail, a white line appears immediately on the scratched portion for a few seconds and then it becomes a red line of 1 - 2 mm in width for a few seconds before its disappearance. However, in malnourished patients, the red line appeared almost immediate and in some occasions even not preceded by white line. It became about 4 - 7 mm in width or even wider and persisted over 30 seconds regardless of any season or age. The occurrence among the inmates was over 70% while among the poor farmers, about 20%. No evidence of allergy had been found in thousands of cases with this sign. Practically, it could be used as a screening test for checking the severity of malnutrition.

Discussion

Skin pigmentation

Association of skin hyperpigmentation in malnutrition is well known but has never been described in thiamine deficiency. It 1963, Baker, *et al.* [8] reported its association with vitamin B₁₂ deficiency. Brown pigmentation involved the dorsal aspect of fingers, the finger joints, toes, and the palm, but not the bony prominence as described above. Ridley [9] noted reticulate and brownish pigmentation on the finger pulps and nails in a patient with pernicious anemia. Vitamin B₁₂ was effective. Marks, *et al.* [10] described hyperpigmentation of the knuckles and palms in a case of megaloblastic anemia. After vitamin B₁₂ therapy pigmentation disappeared. Hirsch and Weinberg [11] reviewed the benign and malignant etiologies of nail pigmentation, such as longitudinal melanonychia. They emphasized the etiology was melanoma, not malnutrition.

Although vitamin B₁₂ deficiency might be suspected in the inmates, however, the clinical manifestation of skin pigmentation in the inmates was quite different and their response to thiamin was dramatic. No report about intra-nail hemorrhage has ever been found.

Palmoplantar fissures

Itin reviewed palmoplantar keratoderma [12]. Many inherited diseases were involved while malnutrition was excluded. Thomas, *et al.* [13] reported a somewhat related case of epidermolytic palmo-plantar keratoderma but it was congenital. Keratoderma climacterium (Haxthausen's disease) had some similarity with palmoplantar fissures in malnutrition as report by Deschamps, *et al.* [14] but was also congenital.

Since extensive palmoplantar keratoderma was found in all of the inmate patients, it was unnecessary to discuss their possible genetic origin. Evidently, its primary cause was chronic mechanical injury combined with malnutrition. In this discussion, the subject is not palmoplantar keratoderma, but its never described fissures or clefts, which caused severe signs and symptoms.

Intra-nail hemorrhage

No report on intra-nail hemorrhage has been found in the literature. However, a few papers reported hemorrhage close or around the nails. For example, Baran and Goettmann [15] reported focal hemorrhages at multiple proximal nail folds or in nail tissues in 3 patients with neurological deficits. Their extra-nail bleeding might be due to peripheral vascular dilatation, not malnutrition. Miller [16] reported hemorrhage under but not inside the nails in scurvy. The picture of nail longitudinal melanonychia in a case of Bowen disease reported by Lambiase, *et al.* [17] resembled intra-nail hemorrhages in some extent but not intra-nail hemorrhage.

Congestive burning soles

This was congestive lesion of the soles. The patient suffered from overt local burning, hot, swelling, and pain of the soles without decreased local sensation as in peripheral neuritis. This skin disorder was entirely different from the so-called burning feet syndrome, which was peripheral neuritis, found among the American prisoners of World War II from Japanese camp. Actually, its word "burning" may be misleading because it describes peripheral neuritis with tingling or burning pain of the feet and the legs without congestive cutaneous lesion and local hot sensation or warmth.

Possible mechanism of skin lesions in thiamine deficiency

When thiamine is deficient, some biochemical reactions may be changed and some bio-molecules may be increased, decreased, or produced, including [18]:

- a. Reduced activities of thiamine-dependent enzymes.
- b. Decreased endogenous antioxidants, such as glutathione (GSH),
- c. Glutathione peroxidase (GPx), glutathione reductase (GR), and catalase system decrease.
- d. Intake of exogenous antioxidants might be inadequate, such as beta-carotene, ascorbic acid or vitamin E.
- e. Free radicals, alpha-aldehydes, advanced glycation end-products (AGEs), and lipid peroxides might be excessively accumulated or produced. Other antioxidant enzymes and proteins might be also decreased, such as mitochondrial manganese superoxide dimutase, cytoplasmic copper-zinc superoxide dimutase, the thioredoxin/thioredoxin reductase system, metallothioneins, and ferritin.

Many organs or tissues might become the primary or secondary targets of the detrimental reactions of these excessive metabolites, for example, endothelial cells. Dysfunctional endothelial cells not only evoked free radical generation but also reduced the production of matrix substances, such as fibronectin, laminin, collagen, proteoglycans and proteases. This may be a preliminary interpretation of the formation of palmoplantar fissures, clefts, or nail layering. And perhaps, intra-nail hemorrhage may be resulted from the angiogenic reaction of vascular endothelial growth factor released from dysfunctional endothelium [19]. Endothelial dysfunction may be the basis of erythematous patches in riboflavin deficiency and hyperactive dermatographism. However, the detrimental metabolites and target tissues involved are numerous; the pathologic mechanism would be very complicated and involved more metabolic changes.

Conclusion

1. Vitamin B1 deficiency may cause multiple and different severe skin diseases.
2. Vitamin B1 is a very powerful pain reliever; especially in myocardial infarction, osteolytic osteosarcoma, and intra-nail hemorrhage.

Conflict of Interests

No conflict of interests to anybody at any aspect.

Acknowledgment

The retired author without fund is very grateful to the Editor and Publisher for the Total Waiver of the submission, processing and publication charges.

Bibliography

1. Baran R, *et al.* "Diseases of the nails and their management". 3rd edition, Blackwell Science Ltd, London (2001): 261-263.
2. Brownson WC. "An unusual condition of the nail in pellagra". *Southern Medical Journal* 8 (1915): 672.
3. Lee BY. "Nail layering phenomena and its Nutraceutic Therapy". *Annals of Nutritional Disorders and Therapy* 5.1 (2018): 1052.
4. Lee BY. "New Diseases caused by Hunger and Fatigue". Chapter 6, Skin Disorders. International Education Science Culture Press (2009): 54.
5. Lee BY, *et al.* "Personal observation of thiamin therapy of coronary heart disease". *Jacob Journal of Coronary Heart Disease* 4.1 (2018): 22.
6. Hou HC. "Outline and atlas of nutritional disorders". People's Health Publisher, Beijing (1956).
7. Lee BY and Thurmon TF. "Nutritional Disorders in a Concentration Camp". *Journal of American College of Nutrition* 16.4 (1997): 366-375.
8. Baker SJ, *et al.* "Hyperpigmentation of skin". *British Medical Journal* 1 (1963): 1713-1715.
9. Ridley CM. "Pigmentation of fingertips and nails in vitamin B12 deficiency". *British Journal of Dermatology* 97 (1977): 105.
10. Marks VJ, *et al.* "Hyperpigmentation in megaloblastic anemia". *Journal of the American Academy of Dermatology* 12 (1985): 914-917.
11. Hirsch RJ and Weinberg JM. "Evaluation of pigmented lesions of the nail unit". *Cutis* 67 (2001): 409-411.
12. Itin PH and Fistarol SK. "Palmoplantar keratoderma". *Clinics in Dermatology* 23 (2005): 15-22.
13. Thomas JR, *et al.* "Epidermolytic palmo-plantar keratoderma". *International Journal of Dermatology* 23.10 (1984): 652-655.
14. Deshamps P, *et al.* "Keratoderma climactereium (Hexthausen's disease): Clinical signs, laboratory findings and etretinate treatment in 10 patients". *Dermatologica* 172.5 (1986): 258-262.
15. Bara R and Goettmann S. "Nail bleeding associated with neurological diseases: all that uncommon? Report of 3 cases". *Dermatology* 187.3 (1993): 1978-1979.
16. Miller SJ. "Nutritional deficiency and the skin". *Journal of the American Academy of Dermatology* 21 (1989): 1-30.
17. Lambiase MC, *et al.* "Bowen disease of the nail bed presenting as longitudinal melanonychia: Detection of human papillomavirus type 56 DNA". *Cutis* 72 (2003): 305-309.
18. Tropouba KJ, *et al.* "Oxidative stress and its role in skin disease". *Antioxidants and Redox Signaling* 4 (2002): 665-673.
19. Galley HF and Webster NR. "Physiology of endothelium". *British Journal of Anaesthesia* 93 (2004): 105-113.

Volume 7 Issue 1 January 2020

©All rights reserved by Benjamin Yuehtung Lee and Julia H Bai.