

Atrial Septal Defect (Secundum Type) Associated with Mitral Regurgitation in an Elderly Woman

Ayesha Saman, Ibrar Anjum*, Amna Khalid and Shoaib Ghulam Sarwar Hashmi

Rawalpindi Medical College, Pakistan

***Corresponding Author:** Ibrar Anjum, Akhter Saeed Medical and Dental College Lahore, Pakistan.

Received: October 18, 2019; **Published:** January 07, 2020

Abstract

Atrial septal defect (ASD) is one of the commonly recognized congenital cardiac anomalies presenting in adulthood. ASD is characterized by a defect in the interatrial septum allowing blood is moving from the left atrium to the right atrium. Mitral regurgitation associated with atrial septal defect (ASD) Secundum type is uncommon. The incidence of heart failure and Eisenmenger syndrome due to ASD and MR is rare. We report a 61-year-old female without significant past medical history arrived in the emergency department with dyspnea, orthopnea and palpitations. Transthoracic echocardiography revealed an Atrial septal defect ostium secundum type, with bidirectional shunt and 4th-degree mitral insufficiency. The most common type of ASD is ostium secundum which is almost 70% of all atrial septal defects. The patient presented at this age could be a late development of symptoms because physical signs and symptoms usually take 35 - 40 years to develop. The objective of reporting this case is that the patient lived for over 60 years almost asymptomatic.

Keywords: ASD and MR in Adult Age; ASD with Heart Failure; Heart Failure and ASD (Secundum Type)

Introduction

ASD is characterized by a defect in the interatrial septum allowing pulmonary venous return from the left atrium to pass directly to the right atrium. Depending on the size of the defect, size of the shunt, and associated anomalies, this can result in a spectrum of disease ranging from no significant cardiac sequelae to cardiac failure ASD usually remain underdiagnosed because patients are symptom-free until middle adult age. Mitral regurgitation (MR) is defined as an abnormal reversal of blood flow from the left ventricle (LV) to the left atrium (LA). It is caused by the disruption in any part of the mitral valve (MV) apparatus. Mitral regurgitation associated with secundum atrial septal defect (ASD) is uncommon. Complications include Incidence of heart failure, atrial arrhythmias, paradoxical embolization and pulmonary hypertension that may lead to right-to-left shunting (Eisenmenger syndrome) [1,2]. These complications rarely present as cardiac defects are usually corrected surgically when the patient becomes symptomatic.

Case Report

61 year old female presented to emergency department with the complaints of shortness of breath, palpitations, orthopnea and headache on and off for the past few years. She had no other significant recent medical history as this was her first hospital visit. On examination, the patient was dyspneic with a blood pressure of 100/70 mmHg and decreased oxygen saturation on pulse oximetry. Further examination showed raised jugular venous pressure, central cyanosis and bilateral pitting pedal oedema. Abdominal examination showed hepatomegaly. Chest auscultation revealed a grade IV systolic murmur at the left border of the stern. Ultrasound abdomen showed an enlarged liver. The remaining examination was unremarkable. Investigations revealed Hematocrit of 39.4, Total Leukocyte Count (TLC) of 4.37, Serum Bilirubin of 5.2, Alanine transaminase (ALT) 339, Aspartate transaminase (AST) 273 and Blood Urea Nitrogen (BUN) of 82 with slightly deranged activated partial thromboplastin time (aPTT). Rest of the labs were unremarkable. She was initially diagnosed as

a case of heart failure NYHA (New York Heart Association) class III/IV. She has managed accordingly and underwent various investigations for further evaluation. Transthoracic echocardiography showed large secundum ASD (43 mm) with a bidirectional shunt (Figure 1) dilated right atrium of 72 mm, dilated right ventricle of 42 mm, dilated left atrium of 62 mm and dilated left ventricle of 64 mm. There is moderately impaired RV systolic function and severe 4th-degree tricuspid regurgitation. The ejection fraction of 60%. Aortic root size of 37 mm. Severe pulmonary hypertension of 60mm Hg and 3th-degree mitral insufficiency. Interventricular septum with paradoxical motion but there was no intracardiac thrombus. Chest X-Ray showed right atrial and right ventricular enlargement (Figure 2). Electrocardiography (ECG) also gave findings of right ventricular hypertrophy (Figure 3). Arterial Blood Gas studies (ABGs) showed the reduced partial pressure of oxygen and metabolic acidosis. The patient was diagnosed as a case of ASD (secundum type) with 4th-degree mitral insufficiency and tricuspid regurgitation leading to cardiac failure grade III/IV NYHA, pulmonary hypertension and Eisenmenger syndrome. She was given oxygen, aspirin, clopidogrel, furosemide, ACE inhibitors, spironolactone, warfarin and proton pump inhibitors. She was not a candidate for surgical repair of cardiac defects, so she was managed and discharged on medications with follow up after two weeks.

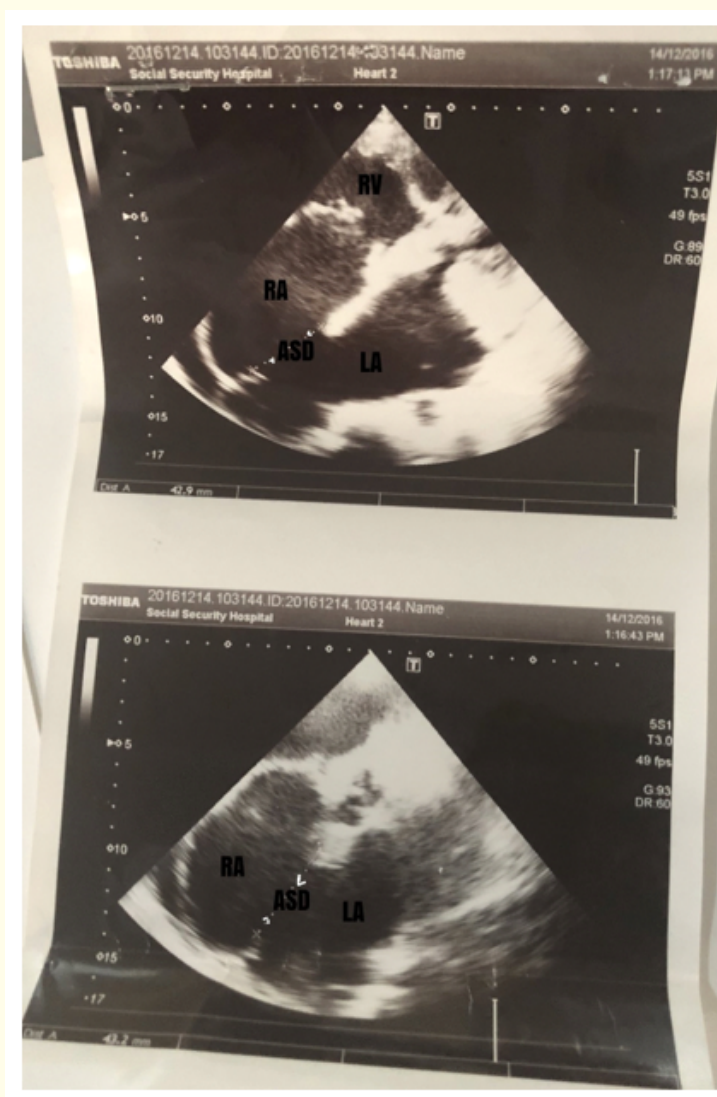

Figure 1: Transthoracic echocardiography showing atrial septal defect (ASD). RA: Right Atrium; LA: Left Atrium; RV: Right Ventricle.

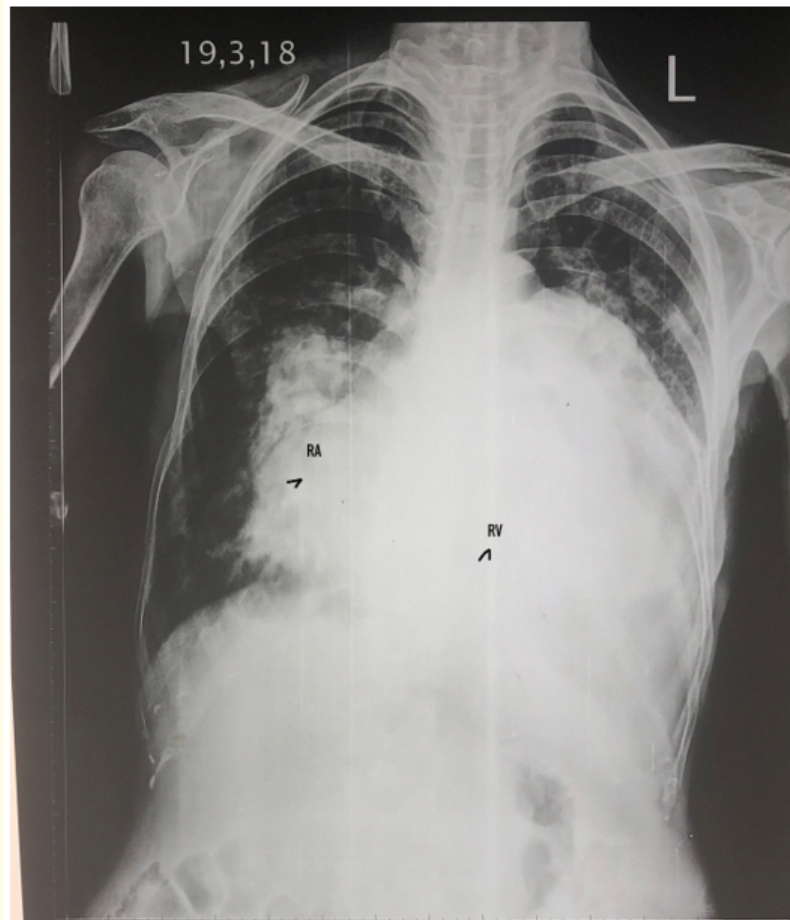


Figure 2: X-ray chest PA view showing right heart failure. RA: Right Atrium; RV: Right Ventricle.

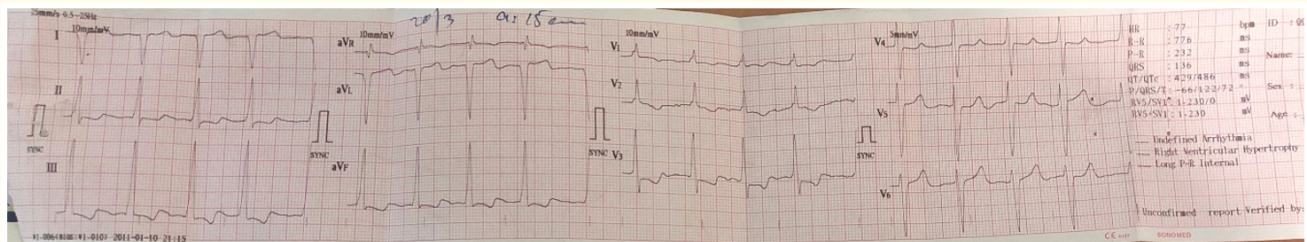


Figure 3: ECG showing right heart failure in leads V1-V6.

Discussion

Atrial septal defect is about 1/3rd cause of congenital heart disease diagnosed in adults and is less than 10% of all congenital heart disease. The most common type of ASD is ostium secundum which is almost 70% of all atrial septal defects. Atrial septal defect is twice as

common in females as in males [3]. There are four types of atrial septal defects depending on the location of the defect in the interatrial septum:

- Ostium Secundum ASD which occurs in the area of fossa ovalis (Almost 70% of all cases).
- Ostium Primum ASD which occurs in the lower part (15 - 20% of all cases).
- Sinus Venosus ASD which occurs in the upper part (5 - 10% of all cases).
- Coronary sinus ASD which is a defect in the common wall between the coronary sinus and the left atrium (< 1% of all cases)

In patent foramen ovale although there is a communication between the atria, this is not considered as an ASD as there is not an absence of interatrial septal tissue [4]. Atrial Septal defects are clinically important. They typically present with a left to right shunt but the direction of blood flow may reverse when the right heart fails thus leading to cyanosis. There is transient right-to-left shunting which coincides with the onset of ventricular contraction in nearly all patients, especially during decreased intrathoracic pressure as well as bradycardia. This explains the occurrence of neurological events in patients who are not cyanotic. The effects of septal defects depend on the size of the defect, amount as well as the duration of shunting and also the reactivity of pulmonary vascular bed [5]. Signs and symptoms are usually absent in infancy and childhood. Symptoms appear as a person grows old. These include dyspnea, palpitations, fatigue, exercise intolerance, syncope, heart failure and atypical chest pain. Sometimes the patients are not symptomatic even until 60 years or older. Symptoms occur because of pulmonary hypertension, atrial tachyarrhythmias and, at times because of associated mitral valve disease. This patient also remained almost asymptomatic until 63 years of age.

There is an association between the atrial septal defect and mitral valve prolapse. Although not proved yet, it has been suggested that valve gets damaged due to age effects and abnormal stress placed on it because of the atrial septal defect. But at the same time, mitral valve prolapse does occur after atrial septal defect closure. So, the patients should be followed up regularly after ASD closure to assess the mitral valve [6].

There is also an association between secundum atrial septal defect in old age and mitral regurgitation. The incidence is significantly higher in old age as compared to people with age less than 50 years. The appearance of the mitral valve in mitral regurgitation in old age ASD patients consisted of fibrous thickening as well as deformity of mitral valve leaflets along with shortening and thickening of chordae tendineae. The pathogenesis is still not clear. It has been said that altered valvular hemodynamics due to chronic interatrial shunting along with altered left ventricular shape due to large right ventricle can lead to deformity as well as fibrosis of mitral valve. In rare cases, rheumatic valvulitis, ruptured chordae tendineae, and bacterial endocarditis can cause severe MR in patients with ASD.

Echocardiography provides a definitive diagnosis. It provides information about the size and location of ASD, the hemodynamic impact of shunting, and the presence as well as the degree of pulmonary hypertension. It also confirms if there is any concomitant other defect or valve involvement. This particular female also had associated mitral regurgitation as well as mitral valve prolapse [7].

Almost half of these defects resolve on their own or by just medical management whereas the rest will require intervention. If the ASD is surgically closed in old patients there is low mortality as well as morbidity whereas it is almost none in younger patients [8].

Conclusion

Atrial septal defect (ASD) is commonly recognized as a congenital cardiac anomaly in adulthood. This present case represents the unusual and very late presentation of an atrial septal defect ostium secundum type with mitral regurgitation, which is usually diagnosed at the middle adult age. She was not an ideal candidate for surgical repair of cardiac defects, so she was managed with medications with two weeks of follow up.

Bibliography

1. Douglas S. "Moodie: Adult Congenital Heart Disease". *Ochsner Journal* 4.4 (2002): 221-226.
2. Warnes CA. "The adult with congenital heart disease: born to be bad?" *Journal of the American College of Cardiology* 46.1 (2005): 1-8.

3. Speechly-Dick ME., *et al.* "Secundum atrial septal defect repair: long-term surgical outcome and the problem of late mitral regurgitation". *Postgraduate Medical Journal* 69.818 (1993): 912-915.
4. Diaconu CC. "Atrial Septal Defect in an Elderly Woman-a Case Report". *Journal of Medicine and Life* 4.1 (2011): 91-93.
5. Sutton MGSJ. "Clinical manifestations and diagnosis of atrial septal defects in adults". In SB Yeon (Ed), *UpToDate* (2017).
6. Liberthson RR., *et al.* "Severe Mitral Regurgitation: A Common Occurrence in the Aging Patient with Secundum Atrial Septal Defect". *Clinical Cardiology* 4 (1981): 229-232.
7. Vick GW and Bezold LI. "Classification of atrial septal defects (ASDs), and clinical features and diagnosis of isolated ASDs in children". In C Armsby (Ed.), *UpToDate* (2017).
8. Rao PS and Harris AD. "Recent advances in managing septal defects: atrial septal defects". *F1000Research* 22.6 (2017): 2042.

Volume 7 Issue 2 February 2020

© All rights reserved by Ibrar Anjum., *et al.*