

## Hybrid Management of Complex Coarctation-Associated Aortopathy in an Adult: A Case Report

Melisa Kandemir<sup>1</sup>, Cahit Saricaoğlu<sup>1</sup>, Evren Ozcinar<sup>1</sup>, Mehmet Çakici<sup>1</sup>, Bahadır İnan<sup>1</sup>, Sadik Bilgiç<sup>2</sup> and Ahmet Ruchan Akar<sup>1\*</sup>

<sup>1</sup>Department of Cardiovascular Surgery, Heart Center, Ankara University School of Medicine, Ankara, Turkey

<sup>2</sup>Department of Radiology, İbni-Sina Hospital, Ankara University School of Medicine, Ankara, Turkey

**\*Corresponding Author:** Ahmet Ruchan Akar, Department of Cardiovascular Surgery, Heart Center, Ankara University School of Medicine, Ankara, Turkey.

**Received:** July 30, 2020; **Published:** August 18, 2020

### Abstract

We report a 31-year-old male with upper extremity hypertension, untreated coarctation of the aorta, bicuspid aortic valve, and ascending aortic aneurysm measuring 8.5 cm. On admission, transthoracic echocardiography revealed severe aortic regurgitation, 27 mm aortic annulus, 48 mm aortic root diameter at the Valsalva sinuses. The ascending aorta was 85 mm. The patient underwent a hybrid retrograde balloon dilatation at the primary coarctation site to decrease afterload initially combined with the repair for a proximal aortic aneurysm through Bentall's procedure. Postoperative recovery was uneventful, and the patient was discharged on the 10th postoperative day without any complication. At a one-year follow-up, he remained asymptomatic and free from antihypertensive medication. Our case represents a rare condition in adults that aortic coarctation-associated aortopathy involves aortic coarctation and a giant ascending aortic aneurysm with grade III aortic valvular insufficiency. This case report highlights the importance of a staged hybrid approach combining endovascular repair of coarctation first with subsequent open surgery of the ascending aorta in complex coarctation cases to avoid complications related to lower body hypoperfusion and upper body hypertension following cardiopulmonary bypass.

**Keywords:** Aortic Coarctation; Ascending Aortic Aneurysm; Hybrid Repair

### Abbreviations

AAA: Ascending Aortic Aneurysm; BAV: Bicuspid Aortic Valve; CPB: Cardiopulmonary Bypass; CoA: Coarctation of the Aorta; CTA: Computerized Tomographic Angiography

### Introduction

Coarctation of the aorta (CoA) accounts for 4 - 8% of all congenital heart disease and significantly reduces life expectancy [1,2]. Nearly half of the patients with CoA have an associated bicuspid aortic valve (BAV) [2,3]. Among 943 cases of repaired CoA, aortic aneurysms were identified in 5.8% [2] in which one third was ascending aortic aneurysms (AAA). Association with CoA and aortic dissections have also been reported [2,4]. The presence of the combination of CoA and other critical cardiovascular anomalies are classified as "complex CoA" [5].

Unless it is primarily detected and surgically intervened in childhood, complex CoA may progress asymptotically and be noticed during a routine physical examination [6]. Primary adult CoA patients may also present with upper extremity hypertension or complications related to aortic vasculopathy [7]. At long-term follow-up, late complications include the sequel of differential hypertension, including intracranial hemorrhage, left ventricular hypertrophy and dysfunction, premature coronary artery disease, bacterial endocarditis, aneurysm formation, aortic dissection, and rupture [5,8]. In this concern, primary adult CoA is related to congenital or acquired vascular pathologies that conclude with dysfunctions at multiple levels, defined as “aortopathy”.

The management of primary adult CoA and associated aortopathies poses a multidisciplinary challenge. Management strategies include a single-stage complex open surgical approach, staged open surgery, or hybrid approaches combining open surgery of the ascending aorta and root with endovascular repair techniques for CoA [6,9,10]. Endovascular techniques consist of balloon angioplasty alone or with stent implantation [5,6]. Furthermore, the timing of the CoA repair is also controversial.

We present herein an adult male patient with CoA combined with aneurysmal dilatation of the ascending aorta and concomitant BAV with severe aortic regurgitation. We performed a hybrid procedure, including consecutive percutaneous balloon dilatation of CoA, to decrease afterload and avoid cardiopulmonary bypass (CPB) complications associated with high afterload and lower body hypoperfusion. Then the Bentall procedure was performed for AAA, aortic regurgitation and BAV.

### Case Report

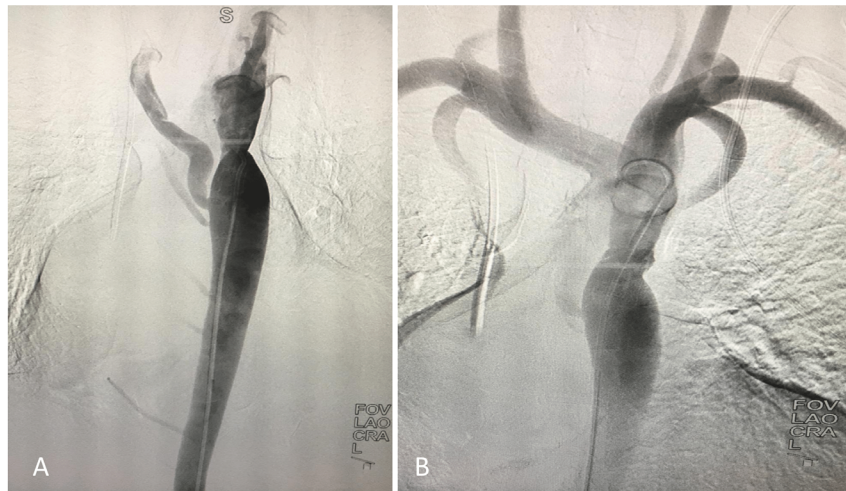
Informed consent was obtained from the participant of this study. A 31-year-old male complained of progressive shortness of breath on exertion, fatigue, and hypertension for one year and was in New York Heart Association functional class III. He denied any smoking history, cough, accompanying emotional stress, and syncopal attacks. The physical examination was notable for increased second heart sound with an associated gallop rhythm, and soft, high-pitched, early diastolic decrescendo murmur at the third intercostal space, and weaker femoral pulses than the radial pulses. Blood pressure measured at the left arm was 140/55 mmHg. His ankle-brachial index was 0.66 and 0.52 on the right and left, respectively. The rest of the physical examination was regular. Further evaluation with transthoracic echocardiography demonstrated that left heart cavity sizes are more prominent than usual with severe aortic regurgitation and left ventricular hypertrophy. The aortic annulus was measured 27 mm and 48 mm aortic root diameter Valsalva sinuses. Computerized tomographic angiography (CTA) revealed a coarctation characterized by a discrete narrowing distal to the aortic isthmus. The ascending aorta was 85 mm, arcus aorta diameter was 29 mm and the distal part was 19 mm. Cardiac catheterization was performed showing normal coronary arteries and a 30 mm Hg gradient was detected through the CoA (Figure 1A).

### Operating procedure

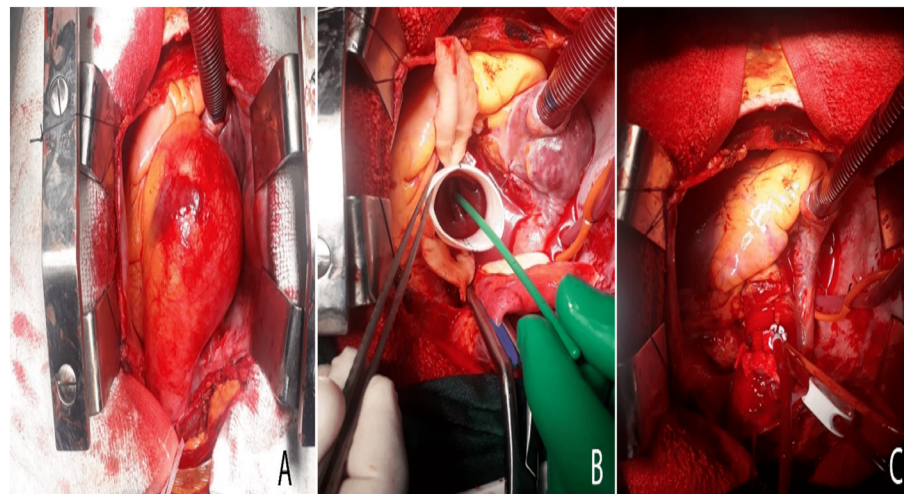
After heparinization and antibiotic prophylaxis administration, the left femoral artery was exposed surgically under local anesthesia, and an arterial sheath was inserted through the left femoral artery for guidewire access to the ascending aorta. Following the replacement of introducer with 16Fr - The Medtronic Sentrant™ Introducer Sheaths with Hydrophilic Coating [Medtronic Australasia Pty Ltd, Macquarie Park NSW, Australia]. A 0.035 Terumo Glide-wire [Terumo Medical Corp., Somerset, NJ, US] was inserted into the ascending aorta to deliver the 46 mm Reliant balloon (Medtronic Vascular, Santa Clara, CA) for dilatation of CoA. Post-dilatation aortography showed an excellent immediate result of a pressure gradient of 0 mmHg (Figure 1B). Finally, introducer was removed, and the femoral artery was repaired primarily.

A day after balloon angioplasty, Bentall procedure was carried out under general anesthesia. Initially, the right axillary artery and the inferior vena cava were cannulated. After median sternotomy, the patient was cooled to 26°C. Cardiac arrest was obtained with Custodiol HTK cardioplegia. Following aortotomy, there was no dissection in ascending aorta. The sinuses of Valsalva were dilated and suspended.

The aortic valve was bicuspid and thickened. There was a partial fusion at the commissures. The aneurysmal ascending thoracic aorta and aortic root were excised. Benthall procedure was applied with a 25/28 mm valved Dacron tube graft - Medtronic Open Pivot Aortic Valved Graft [Medtronic Aortic Medical, Inc., USA]. Then, the coronary buttons were reimplemented. Warmblood cardioplegia was administered, and after the spontaneous beating, decannulation was carried out (Figure 2).

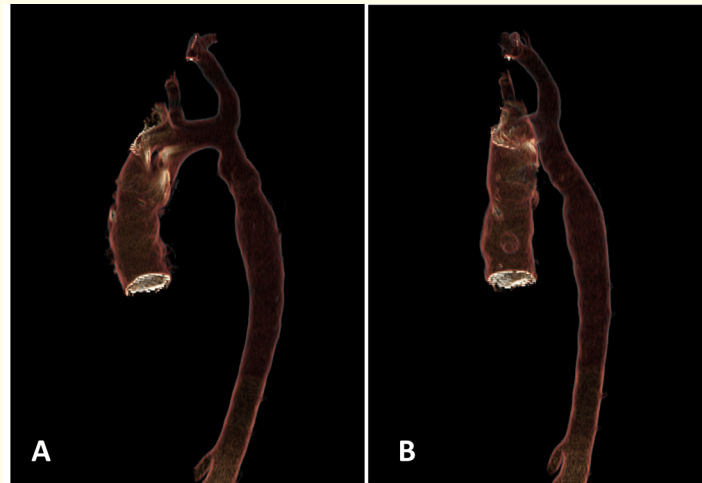


**Figure 1:** A) Descending thoracic aorta angiography, before balloon dilatation; B) after angioplasty.



**Figure 2:** A) Operative picture of ascending and aortic root aneurysm, B) Ascending aorta and aortic root replacement with a valved Dacron tube graft, C) operative image during weaning from cardiopulmonary bypass after modified Bentall technique for surgical reconstruction of the aortic root and ascending aorta.

Postoperative recovery was uneventful; the patient was discharged on the 10<sup>th</sup> postoperative day without any complication. Control CTA at a 6-month follow-up revealed no evidence of CoA recurrence or aneurysm formation (Figure 3). At a one-year follow-up, he remained asymptomatic and free from antihypertensive medication.



**Figure 3:** Three-dimensional reconstruction images (Volume Share 7-Advantage Workstation 4.7, General Electric Co., 2015, Rosslyn, USA) of multi-slice computed tomography angiography performed at 6th month follow-up.

### Discussion and Conclusion

CoA is characterized by a discrete narrowing, often seen on the thoracic aorta, generally in the region of the ductus arteriosus, just distal to the origin of the left subclavian artery. Since the first surgical repair of CoA by Crafoord and Nylin [11] and Gross and Hufnagel [12] surgical techniques for simple CoA has evolved from end-to-end anastomosis, patch aortoplasty, placement of an interposition graft and subclavian flap angioplasty [5]. In the 1980s initial experience with balloon angioplasty in the treatment of CoA has been reported [13]. However, long-term complications of balloon angioplasty for CoA included aortic dissection, cerebrovascular accidents, significant residual gradients and aneurysm formation [14].

However, many patients remain asymptomatic until adulthood, where CoA may be discovered incidentally during routine physical examination during adulthood. At this stage, CoA may be seen as a stand-alone lesion or can be related to localized disease or diffuse aortopathies [2]. In fact, in our case, we believe CoA, BAV and AAA were connected to aortic vasculopathy. Combined CoA and AAA repair is generally considered to be a complex procedure for technical reasons.

Previous literature review emphasized the importance of identifying the associated conditions that might influence treatment or outcomes [2,5]. The management of patients with multiple aortic pathologies associated with CoA is a surgical challenge. The current practice is not based on controlled trials and standard guidelines. However, several approaches have been described for the repair of aortopathies and complex CoA. A single-stage complex open surgical approach can be an option with a relatively high surgical risk. Complications of direct surgical approach to CoA has been previously well-defined elsewhere [5]. Previously described several extra-anatomic bypass grafting techniques were not optimal for the presented case. Staged open surgery is also another alternative approach. Staged

hybrid approaches combining open surgery of the ascending aorta and root with endovascular repair techniques for CoA has evolved over the last decade.

Although the long-term follow-up mortality rates are considerably lower after endovascular repair than after surgical repair for CoA, the long-term follow-up results show that the risk of reintervention is higher after endovascular repair than after surgical repair [6,14]. Endovascular repair is a less invasive and effective method for CoA if overdistention is avoided [6,14].

The following step after choosing the appropriate procedure is to determine which lesion should be corrected first; CoA or other complex abnormalities. Conditions that could influence treatment strategy include the degree of residual coarctation, location of the aneurysm relative to the coarctation, the shape, size, and degree of calcification of the aneurysm and patient age. For instance, in patients just like ours with AAA and CoA are together, firstly, CoA must be repaired to minimize the complications regarding upper body hypertension, and lower body hypoperfusion during CPB, decrease left ventricular afterload, diminish the chances of progressive dissection or rupture and enable safe perfusion during correction of the aortic aneurysm. We, with this, performed a two-stage hybrid procedure for the presented case. During the first step, successful balloon angioplasty was used for CoA repair because it is a less invasive method. Then concomitant AAA and aortic valve regurgitation were corrected with a modified Bentall procedure.

In conclusion, we would like to highlight two critical points in this case report. First is the staged hybrid treatment modality, which lowers mortality compared to a single simultaneous operation. Second is the beneficial effects of CoA's elimination before the surgical procedure, as safe perfusion during CPB, and fewer complications. Primary, complex adult CoA and aortopathy may benefit from multidisciplinary vascular teams' hybrid procedures. However, close follow-up is mandatory.

### Conflict of Interest Statement

No conflicts of interest to declare.

### Funding

No sources of funding.

### Ethical Approval

Not required.

### Consent

A copy of the written consent is available for review by the Editor-in-Chief of this journal.

### Bibliography

1. Francois K. "Aortopathy associated with congenital heart disease: A current literature review". *Annals of Pediatric Cardiology* 8 (2015): 25-36.
2. Preventza O., et al. "Coarctation-associated aneurysms: a localized disease or diffuse aortopathy". *The Annals of Thoracic Surgery* 95 (2013): 1961-1967.
3. Lewin MB and Otto CM. "The bicuspid aortic valve: adverse outcomes from infancy to old age". *Circulation* 111 (2005): 832-834.

4. Jiang Y, *et al.* "Ascending aortic aneurysm and acute type A aortic dissection in a patient with congenital severe coarctation of the aorta". *International Journal of Cardiology* 190 (2015): 18-19.
5. Webb G. "Treatment of coarctation and late complications in the adult". *Seminars in Thoracic and Cardiovascular Surgery* 17 (2005): 139-142.
6. Wheatley GH, *et al.* "Is endovascular repair the new gold standard for primary adult coarctation?" *European Journal of Cardio-Thoracic Surgery* (2010): 305-310.
7. Koletsis E, *et al.* "Two stage hybrid approach for complex aortic coarctation repair". *Journal of Cardiothoracic Surgery* 4 (2009): 10.
8. Jenkins NP and Ward C. "Coarctation of the aorta: natural history and outcome after surgical treatment". *QJM: An International Journal of Medicine* 92 (1999): 365-371.
9. Russell TA, *et al.* "A single-stage hybrid approach for the management of severely stenotic bicuspid aortic valve, ascending aortic aneurysm, and coarctation of the aorta with a literature review". *Journal of Cardiology Cases* 17 (2018): 183-186.
10. Sumi K, *et al.* "Staged open surgery for bicuspid aortic valve regurgitation and coarctation of the aorta in a Jehovah's witness". *BMC Cardiovascular Disorders* 20 (2020): 216.
11. Crafoord C and Nylin G. "Congenital coarctation of the aorta and its surgical treatment". *The Journal of Thoracic and Cardiovascular Surgery* 14 (1945): 347-361.
12. Gross R and Hufnagel CA. "Coarctation of the aorta, experimental study regarding its surgical correction". *The New England Journal of Medicine* (1945): 287-293.
13. Lababidi ZA, *et al.* "Transluminal balloon coarctation angioplasty: experience with 27 patients". *The American Journal of Cardiology* 54 (1984): 1288-1291.
14. Salcher M, *et al.* "Balloon Dilatation and Stenting for Aortic Coarctation: A Systematic Review and Meta-Analysis". *Circulation: Cardiovascular Interventions* (2016): 9.

**Volume 7 Issue 9 September 2020**

**All rights reserved by Ahmet Ruchan Akar, *et al.***