

Positive Long-Term Result of Surgical Treatment of a Rare Malignant Tumor of the Right Ventricle of the Heart

RM Vitovskiy*, VV Isaienko, OA Pishchurin, VF Onishchenko, DN Dyadyun and IV Martyshchenko

N.M. Amosov National Institute of Cardio-Vascular surgery of the Academy of Medical Sciences of Ukraine, Kyiv, Ukraine

***Corresponding Author:** RM Vitovskiy, N.M. Amosov National Institute of Cardio-Vascular surgery of the Academy of Medical Sciences of Ukraine, Kyiv, Ukraine.

Received: June 10, 2020; **Published:** July 09, 2020

Abstract

The presented case is an unusual example of secondary damage to the malignant tumor process of the right ventricle (RV) of the heart. The primary focus of malignant lesion of RV was a malignant tumor - seminoma (low-differentiated embryonic G3 cancer). The peculiarities of the surgical treatment of such a lesion that included a valve-preserving operation on the tricuspid valve. Metastatic malignant tumors of the heart can also affect not only its walls, but also spread to its valve structures, which may require correction of valves lesions. It is necessary to strive in the surgical removal of a malignant heart tumor, as far as possible, to preserve the valve and subvalvular structures in order to avoid prosthetic heart valves. Treatment tactics aimed at removal neoplasms, detoxification therapy and emergency chemotherapy proved to be adequate for the treatment of malignant heart tumors.

Keywords: *Malignant Tumors; Metastasis; Seminoma*

Introduction

Heart tumors were divided into primary benign and malignant neoplasms and secondary (metastatic) malignant tumors [1-5]. Primary malignant heart tumors are extremely rare, which is apparently explained by the features of myocardial metabolism, coronary blood flow and limited lymphatic joints inside the heart [2]. Secondary tumors of the heart had occur in 13 - 40 times more often than primary tumors [2,4].

In modern studies, up to 75% of all primary cardiac neoplasms were divided into benign by histological structure, 25% belong to primary malignant neoplasms [1-3,6,7]. These tumors were detected much more often at autopsies, than in clinical studies. Clinical manifestations in heart tumors depend on the location and size of the tumor to a greater extent, than on its histological type.

Heart metastasis or the germination of the tumor in the myocardium and pericardium were recorded in 0,3 - 27% of those who died from malignant neoplasms, according to various data. Heart metastases most often occur on the background of a comprehensive clinical picture of the underlying disease, usually there are primary or metastatic lesions anywhere in the chest cavity. However, metastases in the heart can be the first manifestations sometimes of a tumor of a different location.

The clinical manifestations of secondary tumors depend more on the location and size of the tumor than on its histological type, as with primary tumors of the heart. Surgical treatment of malignant heart tumors (MHT) in most cases is ineffective and does not made

fundamental changes in the prognosis of patients with this pathology. The main explanation for this is still the late diagnosis of this disease [2-4].

Clinical manifestations begin to appear with a significant tumor of the heart in most cases and can progress very quickly. This had evidenced by a clinical case, which was observed in the N.M. Amosov National Institute of Cardio-Vascular surgery of the Academy of Medical Sciences of Ukraine.

Purpose of the Study

The purpose of the study is to present positive long-term result an extraordinary case of metastatic lesion of the right ventricle of the heart with the malignant neoplasm. The nature and size of neoplasm was finally determined during the operation, as well as the features of the surgical treatment of such the lesion, which included the valve-preserving operation on the tricuspid valve.

Material and Methods

According to the N.M. Amosov National Institute of Cardio-Vascular surgery of the Academy of Medical Sciences of Ukraine since 1970 to date, 63 patients with various types and localization of cardiac malignant tumors (MHT) have been observed, which accounted for 6,9% of the total number of patients with cardiac tumors (912). Localization of MHT in the right ventricle (RV) was observed in 6 (9.5%) patients, which was the rarest in the frequency of localization of isolated detection in the heart chambers of this pathology (most often in the left atrium (LA) - 24, which amounted to 38,1%).

Case Report

Patient T., 24 years old, was hospitalized on 16.01.2018. to the N.M. Amosov National Institute of Cardio-Vascular surgery of the Academy of Medical Sciences of Ukraine, with a diagnosis of a tumor of the RV. From the anamnesis it was known that the patient had elevations in blood pressure (BP) occasionally after physical exertion. Shortness of breath appeared for the last month, which intensified over time, and the patient turned to a cardiologist at the place of residence., The sedentary neoplasm was found in the cavity of RV tightly connected with the wall of RV, when conducting an echocardiographic study (Figure 1).

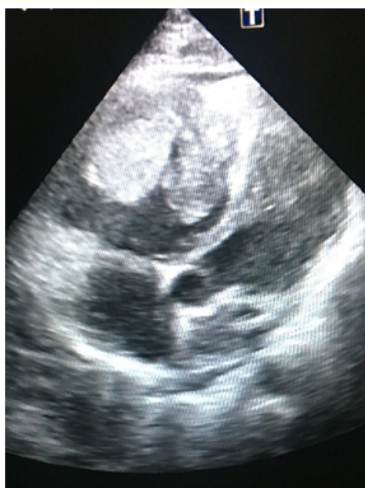

Figure 1: Echo: the tumor in the cavity of the right ventricle.

There were complaints of persistent dyspnea and fatigue associated with slight exertion. There were no clinical signs of severe congestive heart failure, BP - 120/80. From the history of life, it became known that a patient in childhood had cryptorchidism, but the correction of this pathology was not performed.

From other organs and systems no pathological changes were noted, as well as laboratory results. The systolic murmur with the low intensity was determined during auscultation in the projection of the tricuspid valve. X-ray examination revealed a slight increase in the heart. The complete block of the right foot of HIS bundle on the electrocardiography (ECG) and the pulse rate was 80 beats per 1 minute. Signs of moderate hypertrophy of the right ventricle of the heart, signs of coronary insufficiency - not identified. General clinical and biochemical blood tests were within normal limits.

With a two-dimensional echo: a massive inactive formation of 9 × 6 cm was localized in the RV with a transition to the exit path of the RV with obstruction of the latter, and the small insufficiency of mitral and tricuspid valves. Contractility and size of the left ventricle were satisfactory: end diastolic index (EDI) - 42 ml/m², ejection fraction (EF) - 58%. It was not possible to differentiate the nature of the tumor according to the signs revealed by echo. The formation of the RV was revealed during CT, which was fill its cavity and tightly spliced with its anterior-apical wall. At the same time, it was not possible to differentiate the degree of damage to the subvalvular apparatus.

The patient was offered surgical treatment, which was conducted on 22.01.2018, taken into consideration the significant risk of complete obstruction of the right atrioventricular orifice, neoplasm fragmentation and the development of embolic complications. The estimated volume of the operation was the removal of tumors of the RV. The operation was performed using cardiopulmonary bypass. The aorta and superior vena cava were cannulated according to standard techniques. Artificial cardiac fibrillation was established. The inferior vena cava was cannulated after dissection of the right atrium.

The visually unusual configuration of the heart attracted attention: enlarged right heart sections. At the same time, the RV was especially large in relation to even the enlarged right atrium (RA), the “saddle-shaped” deformation of the anterior wall of the RV was determined. The mobility of the wall of the RV was very limited, the fullness of its dense formation was determined by palpation.

The tumor tissue with blood clots was found after a longitudinal incision of RA in the cavity of RV, which was adjacent to the tricuspid valves and was stuff its clearance (Figure 2).

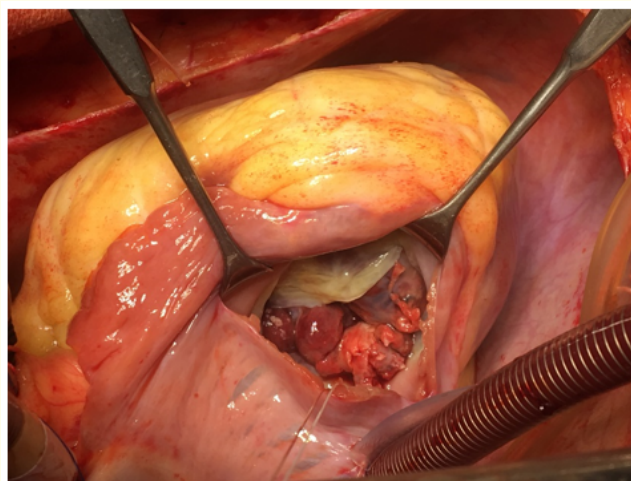


Figure 2: Tumor tissue in the clearance of the tricuspid valve.

The whitish formation of a firmly-elastic consistency and an uneven shape 8 × 6 × 6 cm was found, after removal of blood clots. The tumor was spliced with the anterior wall of RV and papillary muscles, and spread to the apex of the RV, where it penetrated the myocardium most intensively. The tumor was removed by an acute and blunt path, which presented considerable difficulties due to the close proximity of the tumor tissue to the papillary muscles and the tricuspid valves chords (Figure 3). It was possible to understand that their condition was satisfactory, with the direct assessment of the latter, as the tumor tissue fragments were removed. The tissues of the valvular apparatus were not affected by the pathological process.

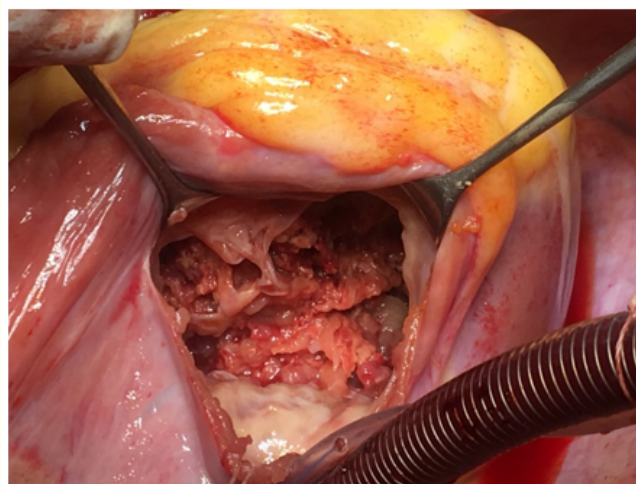


Figure 3: Stage of intraoperative removal of the tumor. Isolation of the chordal papillary apparatus of the tricuspid valve.

This circumstance served as the basis for the decision to perform a valve-preserving operation on a tricuspid valve. It was performed De Vega tricuspid annuloplasty after the maximum removal of tumor tissue from the RV and the release of the subvalvular apparatus of the tricuspid valve. The hydraulic test revealed the satisfactory competence of the tricuspid valve.

The satisfactory mechanics of the right heart were visually determined at the final stage of the operation - the anterior wall of the RV moved almost normally, contracting and relaxing adequately to the cardiac cycle, which indicated normalization of intercardiac hemodynamics.

It was became necessary to clarify the diagnosis of performing an immunohistological study, when conducting a histological study of a remote tumor. According to the conclusion in the studied material there was metastasis of seminoma.

The patient was transferred to spontaneous breathing after 5 hours and transferred from the intensive care unit to the clinical department for 4 days in the postoperative period. The patient needed detoxification therapy, because was made a significant trauma of the tissue of the malignant tumor and the release of tumor toxins during the operation. The patient was need for detoxification therapy and pain-relieving therapy all this time, which lasted until discharge from the cardiac surgery hospital, repeatedly arose.

The patient had no signs of heart failure - shortness of breath and swelling of the lower extremities, increased tolerance to moderate physical exertion in the postoperative period. The patient was discharged in satisfactory condition on the 10th day after the operation and sent for further treatment in the oncological hospital at the place of residence.

The patient in the oncology department underwent an operation to remove an undescended left testicle (histopathological study et February 21, 2018: low-differentiated embryonic cancer G3) (Figure 4), after 2 weeks.

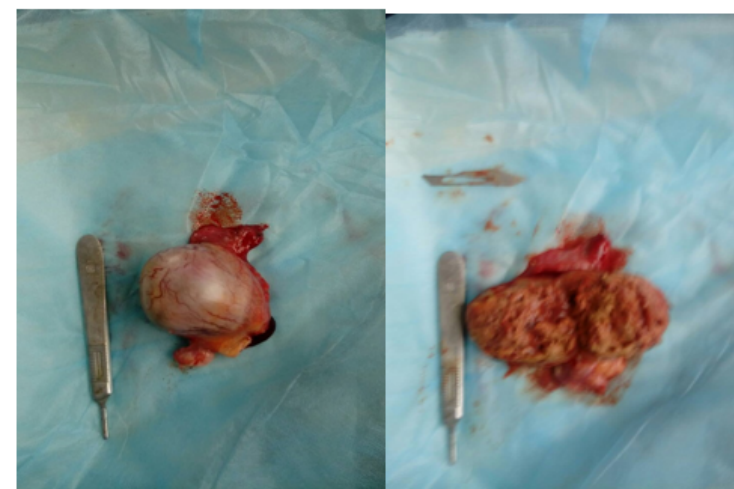

Figure 4: Low-differentiated embryonic cancer of the left testicle.

Based on the determination of cancer markers in a patient (09.02.2018): alpha-fetoprotein - 1058 ng/ml (N < 7 ng/ml), beta-chorionic gonadotropin - 67,92 mIU/ml (N < 2,0 mIU/ml), LDH - 538 I.U./l (N = 225 I.U./l), polychemotherapy was carried out. The composition of the course of polychemotherapy for the radical program included: Cisplatin 40 mg - 1 - 5 days - 30 minutes, Etoposid 200 mg - 1 - 5 days - 60 minutes, Bleomycin 30m - 1, 8, 15 days - 30 minutes (intravenously). The patient satisfactorily underwent the first courses of chemotherapy according to oncologists.

The data of the echo study before and after the courses of polychemotherapy indicate that there is no progression of the tumor process, especially that part of the tumor tissue, which could not be completely removed from the area of the apex of the RV due to the high probability of perforation of its wall. The patient was examined 1 year after surgery. The condition was satisfactory, no signs of tumor recurrence were observed. This was confirmed by an echo study (Figure 5).

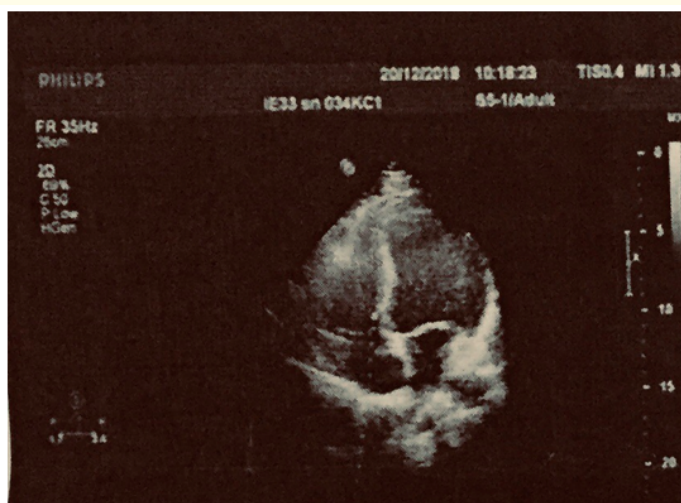


Figure 5: Echo of patient T, 1 year after the operation to remove the seminoma from the right ventricle

The patient was examined 1 year after surgical treatment: echo and CT were performed. No manifestations of recurrence of the disease, or its metastasis were detected.

The attending doctor of the place of residence informed by telephone that patient T. had passed a general clinical examination 1.5 years after the heart operation, was in satisfactory condition, no recurrence of the disease was detected, the effect of the treatment was positive.

Results and Discussion

The presented case is an extraordinary example of a secondary lesion of the malignant tumor process of the right ventricle of the heart. The primary focus of malignant lesions of the RV was a malignant tumor - seed (low-differentiated embryonic cancer G3) in the described clinical case. It became known that the patient had cryptorchidism from the anamnesis of the disease, which did not receive adequate treatment in childhood, and which caused the formation of a seed that metastasized to the heart. There is no data on metastases of the seminoma (low-differentiated embryonic cancer G3) of the heart in the available cardiac literature. It was certainly possible to suggest tumor metastasis in the heart, with some difficulties, given the anamnesis of the disease. In this case, a complex of measures: surgical treatment with subsequent detoxification therapy and emergency chemotherapy had a positive result, which persisted in the long term period.

Conclusion

1. One of the variants of a malignant tumor of the heart may be metastasis of the seminoma (low-differentiated embryonic cancer G3).
2. Metastases in the heart usually occur due to their hematogenous or lymphogenous spread or due to direct invasion. Clinical manifestations in the early stages of the development of heart tumors can be very scarce, but when symptoms appear, progress rapidly. Timely use of echo in malignant diseases, due to clinical alertness in this pathology.
3. Metastatic malignant tumors of the heart can also affect not only its walls, but also spread to its valve structures, which may require correction of valves lesions. It is necessary to strive in the surgical removal of a malignant heart tumor, as far as possible, to preserve the valve and subvalvular structures in order to avoid prosthetic heart valves. The presence of blood clots in the chambers of the heart cannot be ruled out, given the hemodynamic impairment associated with the presence of a neoplasm.
4. Treatment tactics aimed at removal neoplasms, detoxification therapy and emergency chemotherapy proved to be adequate for the treatment of malignant heart tumors.

Bibliography

1. Habertheuer A., *et al.* "Primary cardiac tumors on the verge of oblivion: a European experience over 15 years". *Journal of Cardiothoracic Surgery* 10 (2015): 56.
2. Cresti A., *et al.* "Incidence rate of primary cardiac tumors: a 14-year population study". *Journal of Cardiovascular Medicine* 17.1 (2016): 37-43.
3. Burazor I., *et al.* "Primary malignancies of the heart and pericardium". *Clinical Cardiology* 37.9 (2014): 582-588.
4. Isogai T., *et al.* "Factors affecting in-hospital mortality and likelihood of undergoing surgical resection in patients with primary cardiac tumors". *Journal of Cardiology* 69.1 (2016): 287-292.

5. Barreiro M., *et al.* "Primary cardiac tumors: 32 years of experience from a Spanish tertiary surgical center". *Cardiovascular Pathology* 22.6 (2013): 424-427.
6. Dias RR., *et al.* "Mortality and embolic potential of cardiac tumors". *Arquivos Brasileiros de Cardiologia* 103.1 (2014): 13-18.
7. Barnes H., *et al.* "Clinicopathological and surgical experience with primary cardiac tumors". *Asian Cardiovascular and Thoracic Annals* 22.9 (2014): 1054-1058.

Volume 7 Issue 8 July 2020

©All rights reserved by RM Vitovskiy, *et al.*