

Aortic Isthmus Rupture: A Fatal Complication during Transcatheter Aortic Valve Implantation

Baquero Luis^{1*}, Mesquita Armindo¹, Correia Eduardo², Toscano Ricardo¹, Branco Gonçalo³ and Gama Ribeiro Vasco¹

¹Heart Center of Red Cross Hospital, Lisbon, Portugal

²Anesthesiology Department of Red Cross Hospital, Lisbon, Portugal

³Red Cross Hospital, Lisbon, Portugal

***Corresponding Author:** Baquero Luis, Cardio-Thoracic Surgeon, Director of Heart Center of the Red Cross Hospital, Lisbon, Portugal.

Received: June 18, 2019; **Published:** July 29, 2019

Abstract

Treatment of symptomatic aortic stenosis with transcatheter aortic valve implantation (TAVI) has become a routine procedure and the accumulated experience has allowed to perform the aortic valve replacement with a less invasive approach, with declining rates of complications [1].

Acute aortic rupture has been described as a very rare complication [2]. Most of the reports describing the acute rupture of the aorta are those with rupture of the aortic annulus and there are other reports of the acute aortic arch and descending aorta [3,4].

We report a case of an 86-year old male, with severe aortic stenosis and a fatal acute rupture of the aortic isthmus during a TAVI procedure. To the best of our knowledge is the first report in the literature of an acute Aortic Isthmus rupture as a complication in transcatheter aortic valve implantation.

Keywords: Acute Aortic Isthmus Rupture; Transcatheter Aortic Valve Implantation; Fatal Complications; TAVI; Aortic Stenosis

Abbreviation

TAVI: Transcatheter Aortic Valve Implantation

Introduction

Since 2007, more than 250 000 TAVI procedures have been performed worldwide, It has been estimated that in 2025 there will be 280 000 such procedures per year [5].

Although there has been an extraordinary improvement in technique and case selection, major complications still occur in $\leq 6\%$ to 8% of cases.

Such complications, have been associated with a significant increase in 30-day mortality [6].

Despite the incidence of the acute aortic rupture, dissection or perforation being reported as low as $0,2\%$ - $1,1\%$ [7] during TAVI, the management of such complications is always challenging and the participation of the cardiac surgery team is often needed, but a 2-3 fold increase in procedure mortality is still noted.

Our patient had a STS score of 4 and was offered either a minimally invasive approach through mini-thoracotomy for aortic valve replacement or TAVI procedure, with the patient preferring the latter.

Case Report

A 86 years old man with a history of DDD pacemaker implantation due to intermittent AV block, Diabetes Mellitus (non-insulin dependent) and hypertension was referred to our Institution with the diagnosis of severe symptomatic aortic stenosis in NYHA II.

Transthoracic echocardiography data shows mean gradient of 50 mmHg and the aortic valve area was $0.4 \text{ cm}^2/\text{m}^2$, with a Vmax 4,72 m/s. No other structural cardiac disorders were found and the left and right ventricular function were normal.

A coronary angiography was performed, showing no coronary artery disease and a multidetector computer tomography was performed to evaluate vascular access and aortic anatomy. The femoral and iliac arteries which were straight with some degree of parietal calcification and an adequate internal diameters.

Under a conscious sedation, the procedure took place via right transfemoral artery. A self- expandable 26-mm Core Valve prosthesis (Medtronic, Inc., Minneapolis, MN) was chosen.

We started the procedure by performing a femoral crossover with a 6F catheter in each femoral artery and a hydrophilic catheter to access properly the right femoral artery. Two Perclose ProGlide SMC System (Abbott, Santa Clara) were implanted to ensure the hemostasis after the TAVI delivery system removal.

Once this first step was done uneventfully, an 6F pigtail catheter was introduced into the right femoral artery and a pigtail catheter was introduced to reach the non- coronary sinus of Valsalva, following by an aortography that confirm the right position of the catheter and the anatomy of the aortic root.

A Medtronic DXT5AL20 diagnostic catheter Amplatz was introduced till the ascending aorta and a new straight wire 0,035 x 260 was advanced to cross the aortic valve successfully.

And aortic valve balloon valvuloplasty was planned so a Safari 2 Pre-shaped guidewire (Boston Scientific Corporation) was advanced through the aortic valve to the left ventricle.

Immediately after this step was taken, unexplained hypotension occurred.

Cardiopulmonary resuscitation was initiated and an aortography showed a rupture of the aorta at the level of the isthmus immediately after the emergence left subclavian artery (Figure 1 and 2). Initially, we thought that the shock was cardiogenic due to the severity of the aortic stenosis, so during the reanimation maneuvers an unsuccessful attempt to implant the valve was done. Despite all attempts, the patient succumbed 45 minutes later.

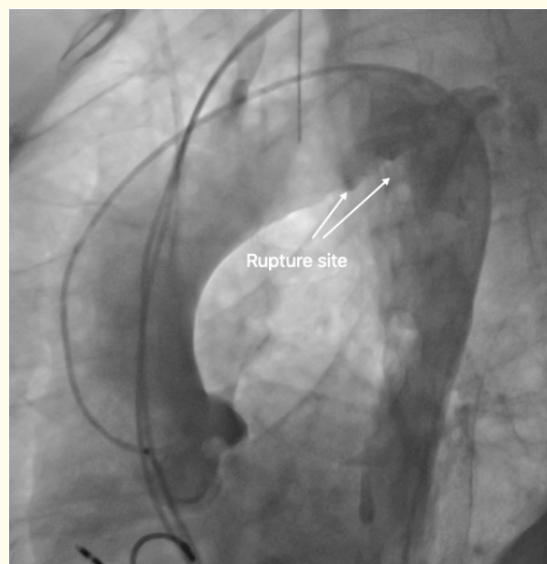


Figure 1: Aortic angiography showing the rupture site.

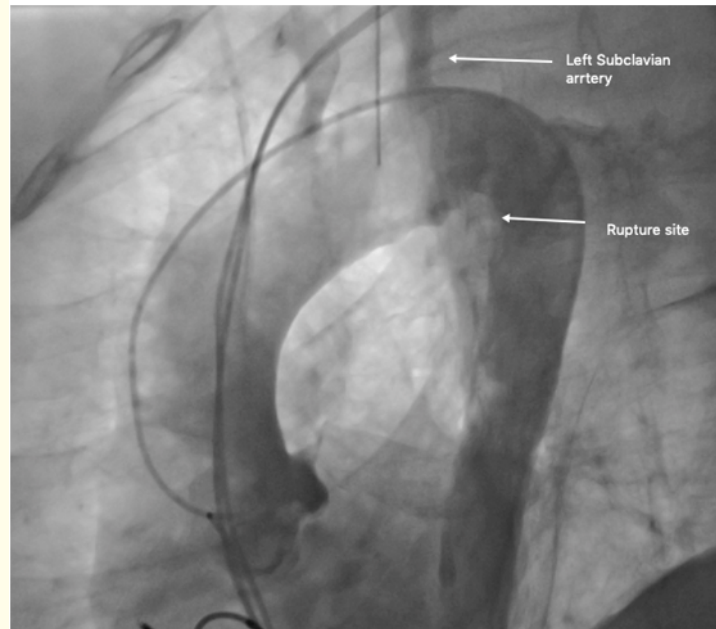


Figure 2: Aortic angiography showing the rupture site.

Discussion

This case of acute rupture of the Isthmus of the aorta happened in a patient with no exuberant calcification of the Aorta as shown in the CT scan 3D reconstruction (Figure 3). The 3D reconstruction of the abdomen showed an abdominal aorta with some parietal calcifications. The thoracic aorta had some calcification at the isthmus immediately after the emergence of the subclavian artery (Figure 4 and 5).

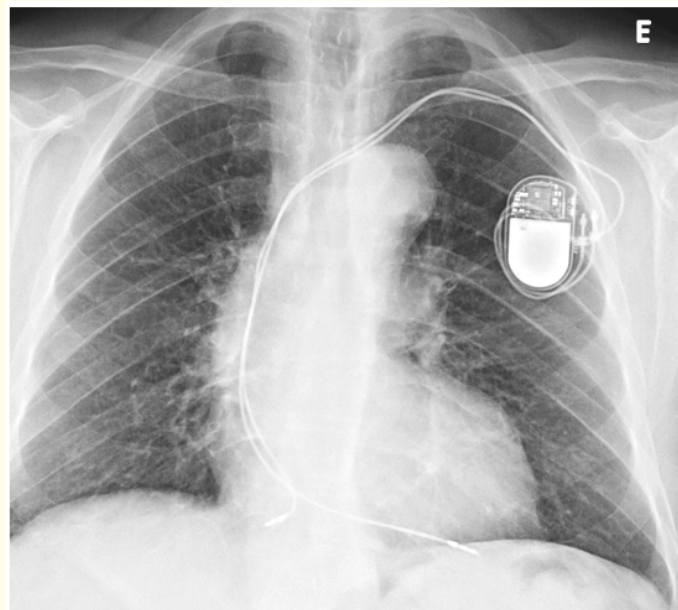


Figure 3: Thorax radiography.

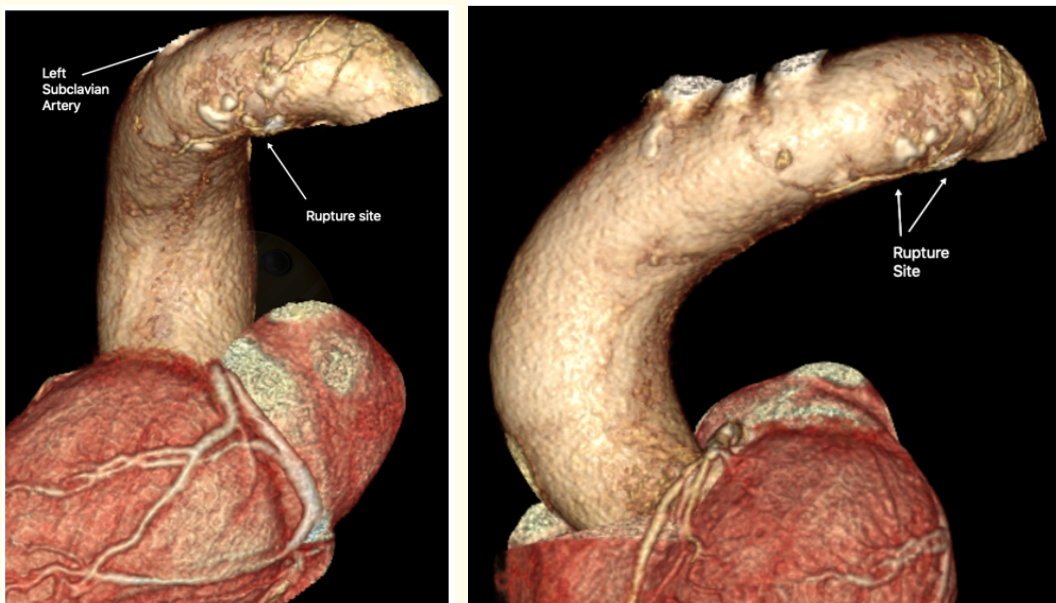


Figure 4 and 5: Aortic angiography.

No other segment of the aorta shows any exuberant calcification or tortuosity.

We believe that our case was more an acute rupture due to the tempestuous clinical presentation. Iatrogenic perforation of the aorta is a rare complication with little time to address the rapidly deteriorating clinical situation.

The calcification seen in the CT scan coincided with the zone of the aortic rupture and it is possible that some guidewire could have damaged the weak aortic wall in the region where an unstable plaque or calcification was placed. We didn't find any resistance by passing the wires and the proximal angle of the Aortic arch was favorable.

Emergent implantation of a thoracic stent graft or even an emergent thoracotomy could be two possibilities of management of such a complication, in this case, we couldn't have the chance due to the devastating clinical scenario.

As the family didn't authorize an autopsy, we couldn't confirm the clinical diagnosis.

Conclusions

Transcatheter valve replacement has changed the paradigm of heart valve treatment and a logarithmic growth with increasing indications is expected.

Any unexplained hypotension during TAVI could include aortic annulus rupture, ventricular perforation, aorta dissection or perforation and acute aortic rupture.

Extreme care should still be exercised in this technique and a high index of suspicion should be maintained when this happens and either a quick stent graft or an open thoracotomy may be needed to save the patient.

Bibliography

1. Smith CR, et al. "Transcatheter versus surgical aortic-valve replacement in high-risk patients". *New England Journal of Medicine* 364.23 (2011): 2187-2198.
2. Lange R, et al. "Incidence and treatment of procedural cardiovascular complications associated with trans-arterial and trans-apical interventional aortic valve implantation in 412 consecutive patients". *European Journal of Cardio-Thoracic Surgery* 40.5 (2011): 1105-1113.

3. Aminian A., *et al.* "Perforation of the descending thoracic aorta during transcatheter aortic valve implantation (TAVI): an unexpected and dramatic procedural complication". *Catheterization and Cardiovascular Interventions* 77.7 (2011): 1076-1078.
4. Dahdouh Z., *et al.* "Aortic arch rupture: an uncommon but fatal complication during transcatheter aortic valve implantation". *JACC: Cardiovascular Interventions* 6.4 (2013): 416-417.
5. Carroll JD. "TAVR Prognosis, Aging, and the Second TAVR Tsunami: Insights From France". *Journal of the American College of Cardiology* 68.15 (2016): 1648-1650.
6. Kahlert P., *et al.* "Vascular access site complications after percutaneous transfemoral aortic valve implantation". *Herz* 34.5 (2009): 398-408.
7. Holmes DR Jr., *et al.* "Annual outcomes with transcatheter valve therapy: from the STS/ACC TVT registry". *Journal of the American College of Cardiology* 66.25 (2015): 2813-2823.

Volume 6 Issue 8 August 2019

©All rights reserved by Baquero Luis., *et al.*