

## Stenting Carotid by Direct Carotid Puncture. Infrequent Accesses

**Roberto Valerio Sapino\***, Aldo Rodriguez Saavedra, Leandro Schiro, Daniela Roguier, Carlos De La Vega Martin and Franco Janicha

*Instituto Cardiovascular Rawson Interventional Cardiology Service, Av Pedro Martinez, Rawson, Chubut, Argentina*

**\*Corresponding Author:** Roberto Valerio Sapino, Nancy Butter Interventional Cardiology Service, Av Pedro Martinez, Rawson, Chubut, Argentina.

**Received:** June 24, 2019; **Published:** July 09, 2019

### Abstract

With the advent of new technologies, and the medical learning curve, Carotid angioplasty with stent implant, has been transformed in the last 20 years, in a technique accepts internal carotid revascularization. One of the limitations of it is the selective catheterization of the Primitive Carotid when the access roads (classically femorals) are not feasible, or when the aortic arch is very unenrolled, aortic arc type C. It is here, where the direct carotid puncture, could play an interesting role, to achieve the revascularization of the internal carotid with stent implant.

**Keywords:** *Stenting Carotid; Stent Implant*

The carotid puncture technique was performed on a standard as a Seldinger technique, by direct puncture of the Common Primitive Carotid, at the C5 level, without surgical exposure, with introducers 611 cm long french (femortousual), using short Magic strings (BostonScinetific) 0.035" housed in the External Carotid, for the implant of the introducers, without getting any deeper, leaving half outside the neck, and giving a stitch point for anchoring it. Once access was made, 5,000 IU sodium heparin was administered, and the relevant angiographic tests are performed by the same side port of the introducer. At this point, the 0.035" string is carefully removed, and through the opener, string 0.014 of choice is passed (in our case floppy and without brain protection, to make the implant directly with Maynar's butter) and through it, stent is positioned stent autoexpandable 10 x31 full open Wall Stent in all patients. The deployment of the stent, if deemed necessary, according to Maynar criteria and operator preference, was post dilate with coronary balloon 4.5 x 20 mm at nominal pressure (6 patients) or else, was thus left the stent for the radial force to work on the working late. Subsequently, angiographic control was carried out, and then the cannula was removed by performing in all patients heparin reversal with protamine sulfate 1 ampoule, eventual leveling of the high blood pressure with enparinous vasodilators, to have no more than 110 mmhg of systolic pressure, manual compression under monitoring in hemodynamics room for 15 minutes minimum and then compressive bandage transfer of the patient to special services unit for 24 hours with early high [1-6].

### Objectives of the Study

To publicize, our consecutive series of patients approached by direct carotid puncture, to achieve the revascularization of internal carotid with stent implant.

**Materials and Methods**

Since April 2013, 12 Internal Carotid PTAs were performed on 12 consecutive patients. All patients were male, with an average age of 72 years (67 - 84) (See table 1). All patients had previously had an invasive angiographic study of cervical neck vessels by some route (9 femorals, 3 brachials), to confirm the diagnosis and to understand the alt carotid fork, to perform the puncture, usually at the level of C5.

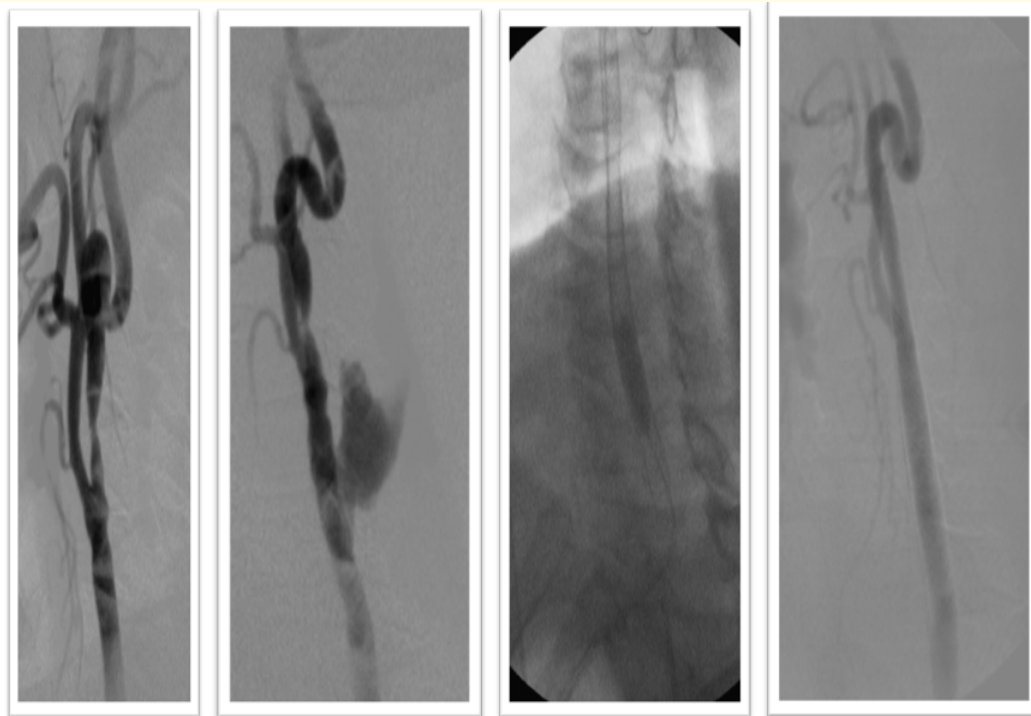
**Results**

Successful direct puncture was achieved in all patients, and through it, carotid stenting was achieved for revascularization in properly. In only one patient, we had an in-house carotid in the puncture sit io, which forced a second stent to be placed, and to perform two prolonged institutions of more than 30 seconds to contain it, with a successful result, and in two more patients, we had two neck bruises (not suffocating) but they required strict control of the area track for an hour, and administration of endovenous corticosteroids. In all other patients, we have had no complications either from the puncture site or carotid stenting.

All men
Average age 69 years (range 63 - 78)
Diabetics 9/12
HTA 9/12
Dyslipidemias 9/12
Current smoker 7/12
Peripheral arteriopathy 12/12
We Lerich 7/12
Aortic arch type C 5/12
Ischemic heart disease 9/12
Previous Stroke 3/12

**Table 1:** Demographic table.

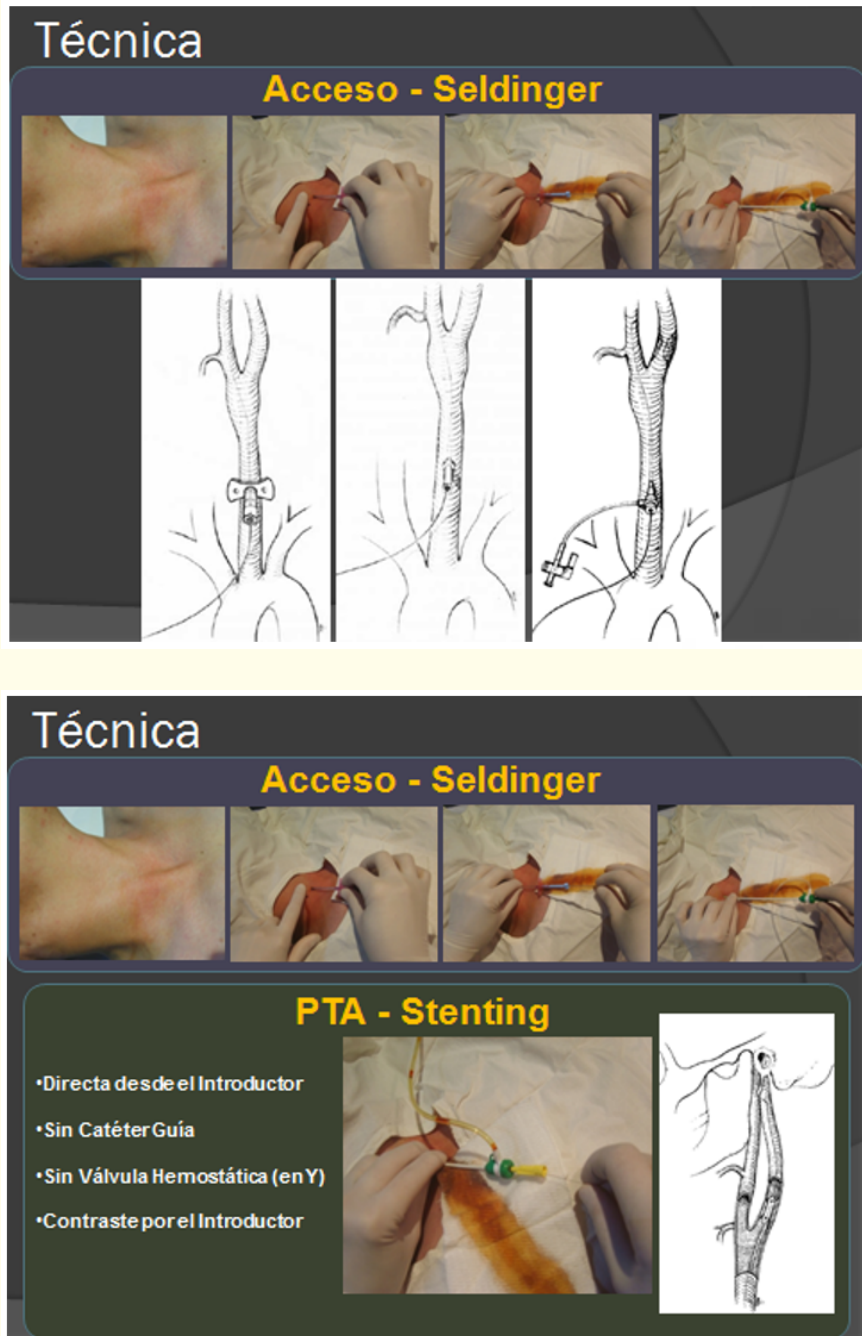
Patient	Age	Sex	Brain Protection	Type stent	Pre dilation	Post dilation	Complications
#1	75	M	No	Wall stent	No	No	No
#2	68	M	No	Wall stent	No	No	No
#3	72	M	No	Wall stent x2	No	Yes	Effraction
#4	76	M	No	Wall stent	No	Yes	No
#5	68	M	No	Wall stent	Undersize	Yes	No
#6	59	M	No	Wall stent	No	No	Hematoma
#7	64	M	No	Wall stent	No	Yes	Hematoma
#8	66	M	No	Wall stent	No	No	No
#9	63	M	No	Wall stent	No	No	No
#10	72	M	No	Wall stent	No	No	No
#11	78	M	No	Wall stent	No	No	No
#12	71	M	No	Wall stent	No	No	No



**Figure 1:** #3 Patient Carotid Effraction.



**Figure 2:** Dr Edgar Moniz.



### Discussion

Carotid angioplasty with stent implant, is a proven therapeutic, which has more than 20 years of experience. With the advent of new materials dedicated to it (dedicated stents, guide pods, ropes, etc.) and new imaging technologies, this type of internal carotid revascularization is increasingly being used. However, today, one of the main limitations of carotid stenting, is the lack of possibility of arterial access, classically femoral, and the difficulty of positioning a guide catheter in the developed aortic archetype C. That is why the shortcut should be taken into account.

In the literature consulted, it is also considered a valid option, the direct puncture of carotid when there are no accesses, or the aortic arch is extremely tortuous.

The first operator to describe direct puncture cerebral angiography was Dr. Edgar Moniz in 1927, and that led us to propose this kind of approach.

In our institution, this technical has a well-established place, since our hospital is a provider of services for the elderly, with which, the complexity of the accesses are greater, already lack thereof (Lerich's me, etc.) or excessive aortic tortuosity. This approach, we do not routinely use it for all Internal Carotid PTAs, we only leave it reserved for when: 1- There is no possibility of access, 2- the aortic arch is so unrolled, that it adds a lot of morbidity to the procedure. So that's how himself, we don't we use systematically protecting systems, and we adopted the steal by Prof Manuel Maynar (Tenerife, Spain) in the stents Carotids on a routine basis for a more than 15 years.

In all cases, we counted with angiography prior to the puncture, either to reconfirm the diagnosis of carotid injury, which in all cases was previously made by Doppler echo, and in addition, to know the height of the carotid fork prior to puncture, and be sure to puncture the upper part of the primitive carotid, at the C5 level. For a few months now, now before carotid pup, we do not systematically do invasive angiography, in many cases, we use multi-cut tomography.

### Conclusion

We believe that the direct puncture technology, regulated, is safe and feasible, therefore, should be taken into consideration when there is impossibility of access, or we find excessively unrolled aortic arches, type C.

### Bibliography

1. Guimaraens L., *et al.* "Carotid artery stenting by direct percutaneous puncture". *Journal of Vascular Surgery* 54.1 (2011): 249-251.
2. Strickman N., *et al.* "Percutaneous cervical carotid artery access with stenting of the left internal carotid artery in an elderly patient". *Journal of Geriatric Cardiology* 4.2 (2007): 111-114.
3. Hsien Li Kao. "All roads lead to Rome Direct cervical carotid artery access in carotid artery intervention". *Journal of Geriatric Cardiology* 4.2 (2007): 115.
4. Mark Wholey. "Concepts in stent design, Carotid Access and embolic protection". *Endovascular Today* (2009): 53-58.
5. Dalai S., *et al.* "Carotid artery stenting by non femoral arterial approach in patients with difficult anatomy". *Indian Journal of Neurosurgery* 2.1 (2013).
6. Matsumoto., *et al.* "Direct carotid approach for carotid angioplasty and stenting with a small incision: a technical case report". *No Shinkei Geka* 32.7 (2004): 735-740.

**Volume 6 Issue 8 August 2019**

**©All rights reserved by Roberto Valerio Sapino., et al.**