

TAVI with Balloon Expandable Aortic Valve Prosthesis in the Presence of Mechanical Mitral Valve Prosthesis

Christos Eftychiou^{1*}, Chrysostomos Kokkinos², Saverios Houris³, Nicolaos Eteocleous¹, Krikor Simamonian¹, Erotokritos Evangelakis², Vassilios Yiannikourides¹ and Mauro Cassese⁴

¹Cardiology Department of Nicosia General Hospital, Nicosia, Cyprus

²Cardiothoracic Surgery Department of Nicosia General Hospital, Nicosia, Cyprus

³Anaesthesiology Department of Nicosia General Hospital, Nicosia, Cyprus

⁴Department of Cardiovascular Surgery, Casa sollievo della sofferenza Hospital, San Giovanni Rotondo FG, Italy

***Corresponding Author:** Christos Eftychiou, Interventional Cardiologist, Cardiology Department, Nicosia General Hospital, Lemesou Ave, Latsia, Nicosia, Cyprus.

Received: April 13, 2019; **Published:** May 17, 2019

Abstract

Transcatheter aortic valve implantation (TAVI) is an established method for aortic valve replacement in intermediate and high-risk patients. Patients who have undergone previous sternotomy for mitral valve surgery have a higher mortality rate, therefore TAVI for these patients is a reasonable option. However, the risk of under-expansion and/or deformation of the aortic valve from the non-compliant mechanical mitral prosthesis, the risk of embolization of the aortic prosthesis and the risk of post-procedural dysfunction of the mitral prosthesis have initially made the presence of mitral prosthesis a relative contraindication for TAVI. Through several case reports in the literature, it has been shown that TAVI is both feasible and safe provided the necessary considerations have been taken. The mitroaortic distance, the type of pre-existing mitral prosthesis, the use of balloon valvuloplasty and the choice of access site are of paramount importance for a successful procedure. We present two cases of severe aortic stenosis with pre-existing mitral valve prosthesis, treated with TAVI and balloon expandable aortic valves and discuss the relative considerations.

Keywords: *Transcatheter Aortic Valve Implantation; Aortic Valve Replacement; Mitral Valve Replacement; Mechanical Prostheses*

Introduction

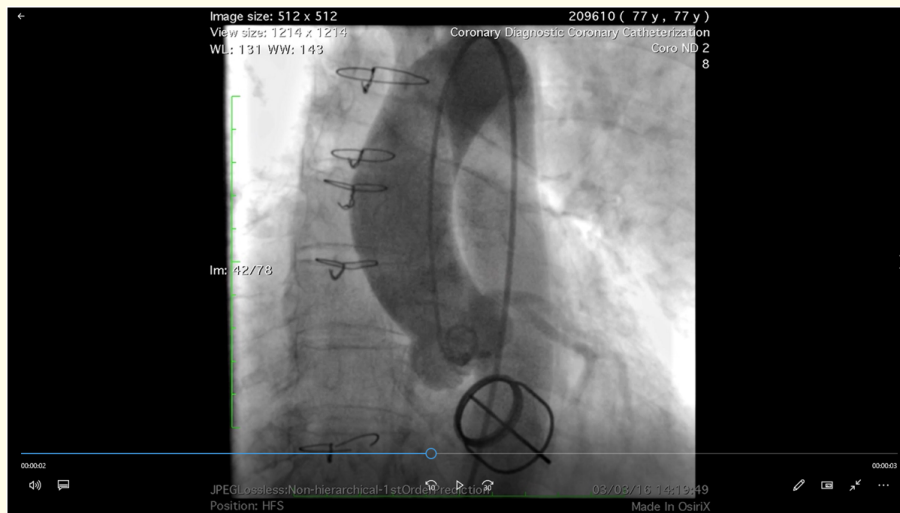
Transcatheter aortic valve implantation (TAVI) is an established method for aortic valve (AV) replacement in intermediate and high-risk patients [1]. However, patients with previous mitral valve (MV) replacement have been excluded from large trials and this was considered a relative contraindication [2]. This is a result of the concern over possible interference between the AV and the mitral prosthesis or annuloplasty ring both during and after deployment [3]. The perioperative risk is elevated in patients undergoing conventional AV replacement with previous cardiac surgery and cases of TAVI in patients with previous MV replacement have already been reported; however, there are no guidelines on the topic and there is no preferred type of a transcatheter valve for such cases [4,5]. We report two cases of TAVI with a balloon expandable AV in the presence of a mechanical mitral prosthesis and discuss the clinical and technical considerations that need to be addressed.

Case Report

Case 1

A 77-year old female patient was referred because of severe symptomatic AV stenosis (NYHA III). She had a history of a MV replacement with a Starr Edwards (ball in cage) mechanical valve in 1982 because of rheumatic valve disease, hypertension, atrial fibrillation (AF), LBBB and diabetes mellitus. Her echo showed a preserved systolic function with a well-functioning MV prosthesis, moderate tricuspid valve (TV) regurgitation, severe stenosis of a calcified and thickened tricuspid AV with mild regurgitation. Catheterization showed

coronaries free of significant disease and normal pulmonary artery pressures (Video 1). Measurements from CT indicated that the AV annulus area was 450 mm² and the AV annulus diameter was 25 x 21 mm. The mitroaortic distance was 6.2 mm (Figure 1). Her Euroscore II was 10%, the STS was 5,9% and she was elected to be treated with a transapical TAVI using a Sapien XT 26 mm valve.



Video 1: Case 1. Aortogram.

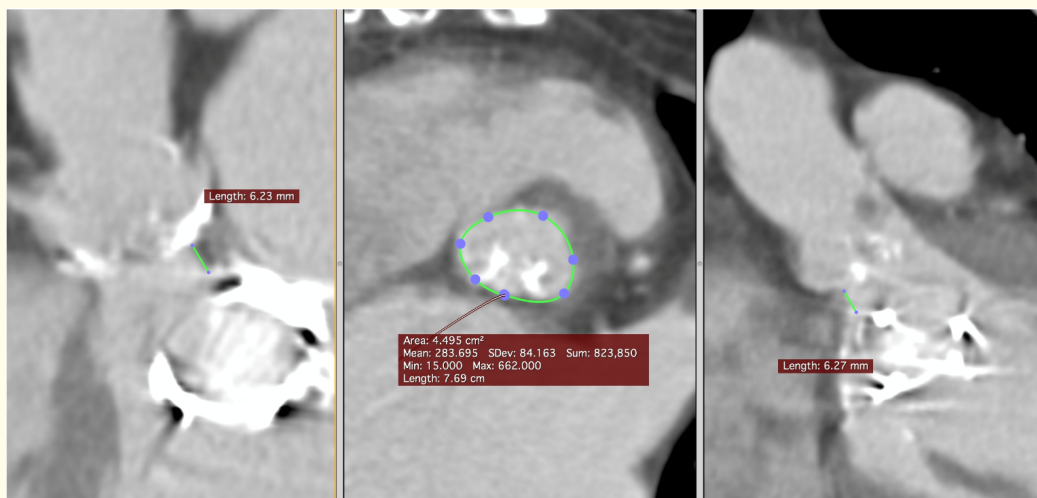
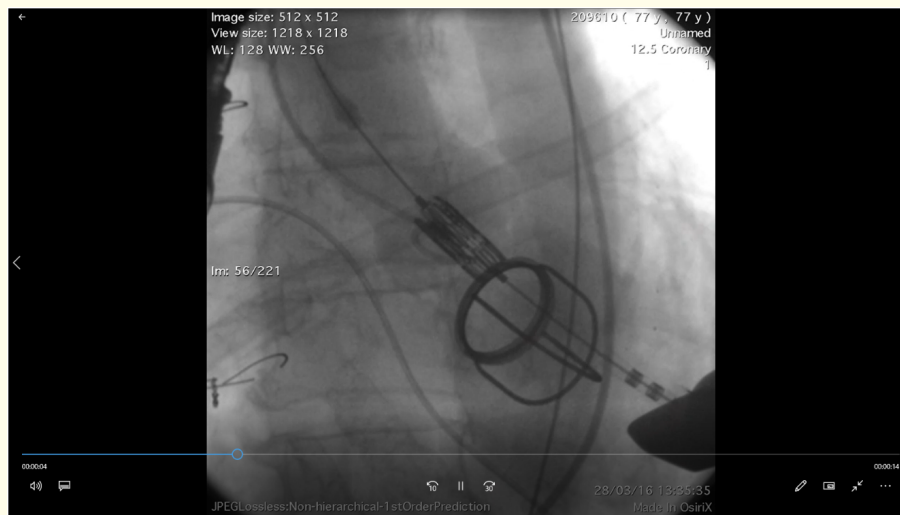
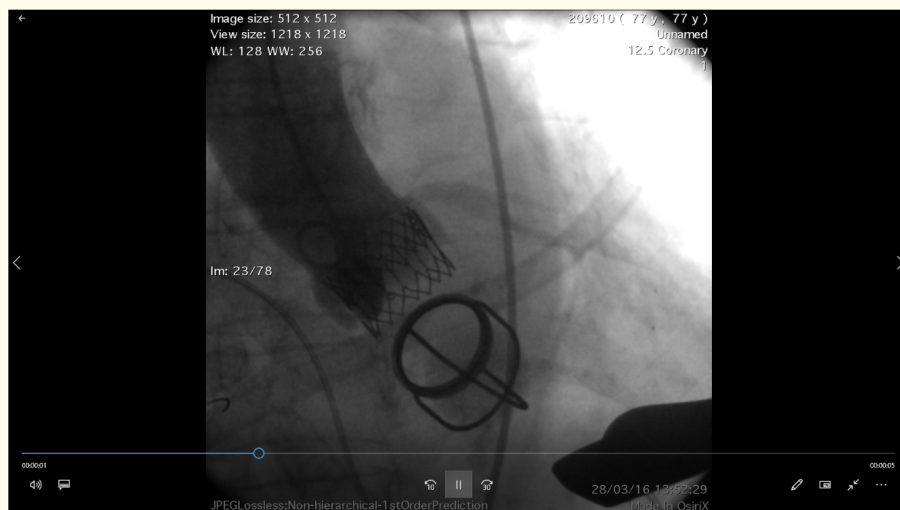


Figure 1: Case 1. AV annulus and AV-MV distance.

The procedure was done under general anesthesia and TOE guidance. After puncturing the apex, it proved to be challenging to cross the AV with the standard 0.035” wire without crossing through the “cage” of the mechanical mitral prosthesis. A 6F sheath through the apex was used to guide the wire away from the MV prosthesis and through the AV to place a JR4 catheter in the descending aorta and exchange to an Amplatz extra stiff wire. A 26mm Sapien XT valve was implanted without pre-dilatation (Video 2). Aortogram and TOE images showed a good result with only traces of paravalvular regurgitation (Video 3). Her TTE at follow up showed a well-functioning prosthetic AV with traces of regurgitation. Twelve months after the procedure the patient was well with only mild dyspnoea on effort (NYHA I-II) but a pacemaker implantation was needed because of bradycardia.



Video 2: Case 1. Valve deployment.

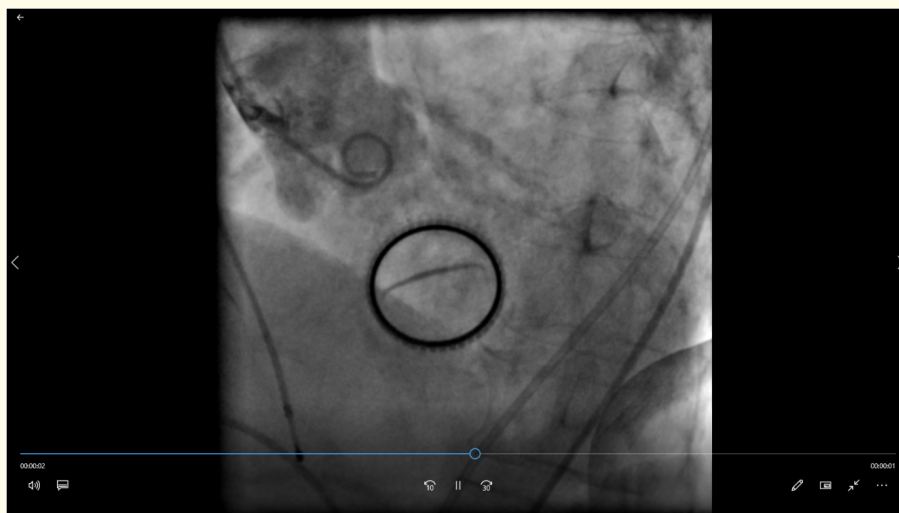

Video 3: Case 1. Final result.

Case 2

A 71 year old female patient with severe symptomatic AV stenosis (NYHA III) had a history of MV replacement with a bileaflet mechanical valve (Carbomedics) in 1988, pulmonary hypertension, chronic AF, LV hypertrophy and LV strain. Her echo showed a preserved systolic function, a well-functioning MV prosthesis, moderate TR regurgitation with RVSP: 50 mmHg and severe stenosis of a calcified and thickened tricuspid AV with mild regurgitation. Cardiac catheterization showed coronaries without significant disease and a heavily calcified AV with restricted opening and moderate regurgitation (Video 4). The LV-Aorta pullback gradient was 30 mmHg. She had pulmonary hypertension with a mean PA pressure of 48 mmHg. CT showed an AV annulus area of 420 mm² while the mitroaortic distance was ≥ 10

mm (Figure 2). She had good sized peripheral arteries without significant disease. Her Euroscore II was 6.6%, and her STS score 4.5%. Due to previous history of thoracotomy and frailty the decision was to proceed with TAVI. Because of good peripheral arteries and large enough mitroaortic distance we elected to proceed with a transfemoral approach.



Video 4: Case 2. Aortogram.

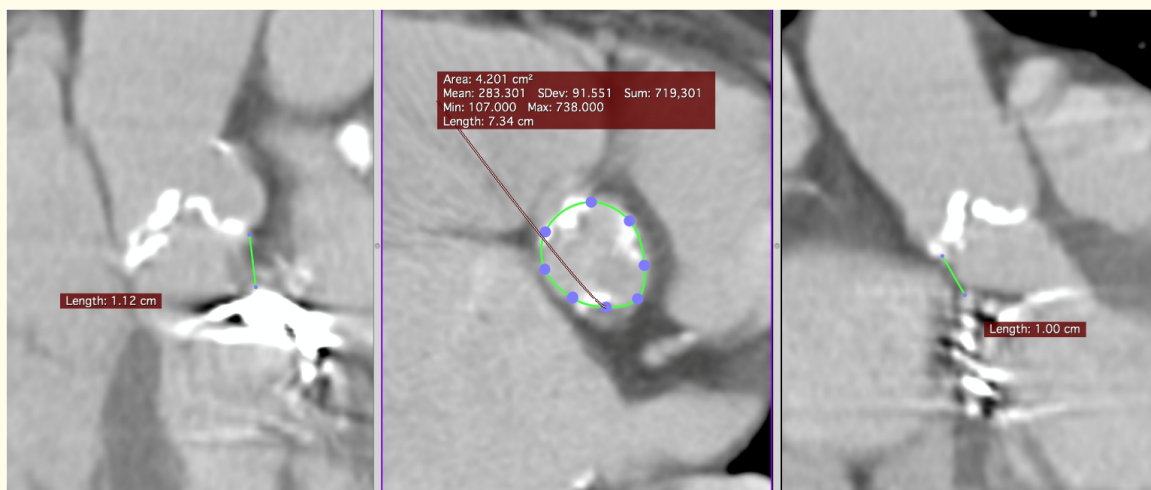
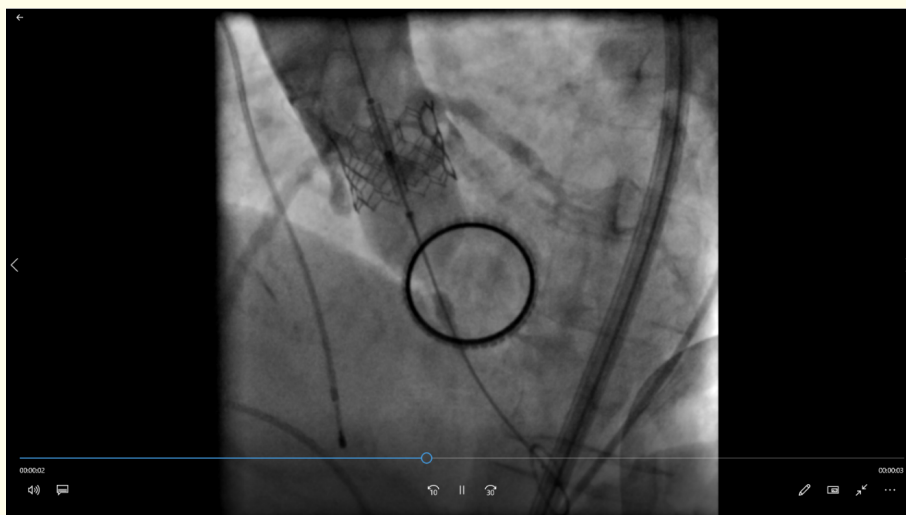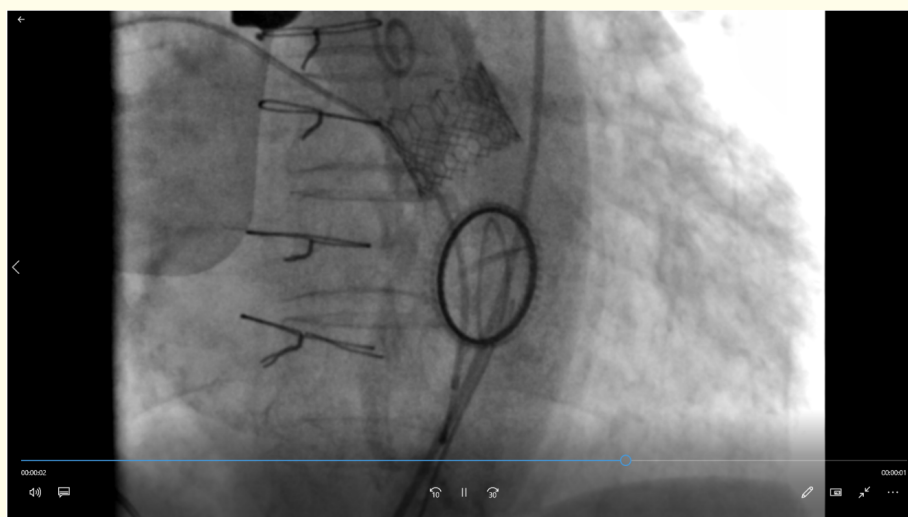


Figure 2: Case 2. AV annulus and AV-MV distance.

A 20 mm Edwards balloon was used for valvuloplasty and a 23 mm Edwards Sapiens 3 valve was deployed (Video 5). The valve was deployed rather high while there was moderate paravalvular aortic regurgitation. A post-dilatation was performed using the same balloon and adding 2ml of volume. Aortogram and TOE at the end of the procedure showed a good result with only mild paravalvular regurgitation (Video 6).



Video 5: Case 2. Valve deployment.



Video 6: Case 2. Final result.

Twelve months after the procedure the patient was well with improved NYHA I-II status and only mild dyspnoea on effort. Her TTE at follow up showed a well-functioning prosthetic valve with only mild regurgitation.

Discussion

Transcatheter AV implantation has emerged as an alternative therapy to treat patients with severe symptomatic aortic stenosis, who are high-risk surgical candidates, such as patients who have undergone previous sternotomy for MV repair or replacement. In these patients, there is a higher mortality rate and the possibility of a percutaneous approach is an attractive concept [3]. However, there are several issues that should be considered when planning a TAVI in the presence of a pre-existing mechanical mitral prosthesis: 1) the mitroaortic distance 2) the risk of under-expansion and/or deformation of the AV from the noncompliant mechanical mitral prosthesis 3) the risk of embolization of the device due to “watermelon seeding” effect 4) the risk of post-procedural dysfunction of the mitral prosthesis due to its damage during percutaneous manipulation or interference between the prosthesis and distal edge of the AV and 5) the choice of access [6-8].

The mitroaortic distance is very important and can be accurately measured with a CT. It has been reported that for a space less than 4mm the balloon expandable Edwards Sapien valve should be considered to avoid interference with the function of the mitral prosthesis leaflets [7]. Otherwise the inflow part of the Medtronic self-expandable Corevalve frame can interact with the mitral prosthesis causing embolization and or under-expansion of the aortic prosthesis [6,7]. There is no consensus on an ideal distance that would allow the implantation of an AV without problems, although a distance of 3 mm between the lower edge of the aortic ring and the upper edge of the mitral prosthesis ought to be sufficient when using the transapical route. In patients, which are treated via the transfemoral route, this distance should preferably be > 7 mm [9].

The risk of under-expansion and/or deformation of the AV from the noncompliant mechanical mitral prosthesis can be less with the balloon expandable Edwards Sapien valves which have a shorter protrusion in the LV outflow track and by avoiding oversizing [7].

The risk of embolization of the device due to “watermelon seeding” effect is more relative with the balloon expandable valves due to the possible displacement of the inflated balloon from the rigid mitral ring [3,7]. Balloon valvuloplasty allows for observation of balloon “shifts” and using a similar balloon for subsequent prosthesis deployment provides the best prediction of the degree of balloon shift during actual deployment. Slow balloon inflation usually minimizes balloon displacement [10].

Malfunction of the mitral prosthesis by interference with the aortic prosthesis is a potentially lethal complication [2]. The type of the pre-existing mitral prosthesis is important especially in cases where the Corevalve is going to be used which has a portion of the frame in the LV outflow tract and can interact with a mechanical mitral prostheses with longer struts. When the balloon expandable valve is going to be used, observation of mitral prosthesis during balloon pre-dilatation of the AV has been suggested as a means of assessment of feasibility before aortic bioprosthesis implantation [7].

Transapical approach has several advantages. It allows the operator to have more efficient prosthesis manoeuvres due to the shorter access-site balloon distance and coaxial alignment while it can be used when the mitroaortic distance is less than 7 mm [7,10]. If the transfemoral approach has been decided, then balloon valvuloplasty is mandatory to assess the degree of balloon displacement [10].

Our two cases represent a very good example of the multiple considerations that need to be taken before deciding the type of the AV prosthesis and the access route to be used. In the first case where a large and bulky Starr Edwards (ball in cage) mechanical MV was in place with a small mitroaortic distance less than 7mm, we chose to use the balloon expandable Edwards Sapien XT valve through a transapical approach. A procedural challenge of crossing the valve with the standard 0.035” wire without crossing through the “cage” of the mechanical mitral prosthesis was overcome using a standard 6F femoral sheath through the apex, to guide the wire away from the mitral valve prosthesis and through the AV. In the second case where a low profile bileaflet mechanical mitral valve (Carbomedics) was in place, with a mitroaortic distance well above 7mm the transfemoral access was used and a balloon expandable Sapien S3 valve. In the femoral case a balloon valvuloplasty was also used to predict the degree of balloon shift during actual deployment and any mitral prosthesis dysfunction.

Conclusion

TAVI in patients with pre-existing mitral prosthesis is both feasible and safe provided the necessary considerations have been taken. The mitroaortic distance, the type of pre-existing mitral prosthesis, the use of balloon valvuloplasty and the choice of access site are of paramount importance for a successful procedure.

Disclosure

There is no potential conflict of interest for any of the authors.

Bibliography

1. Linke A, *et al.* “Treatment of aortic stenosis with a self-expanding transcatheter valve: the International Multi-centre ADVANCE Study”. *European Heart Journal* 35.38 (2014): 2672-2684.
2. Asil S, *et al.* “Transcatheter aortic valve implantation in patients with a mitral prosthesis single center experience and review of literature”. *International Journal of Cardiology* 221 (2016): 390-395.

3. Bruschi G., *et al.* "Self-expandable transcatheter aortic valve implantation for aortic stenosis after mitral valve surgery". *Interactive Cardiovascular and Thoracic Surgery* 17.1 (2013): 90-95.
4. Wachter K., *et al.* "Transapical aortic valve implantation in patients with pre-existing mitral valve prostheses: a case report". *Journal of Cardiothoracic Surgery* 11.1 (2016): 133.
5. Jones JM., *et al.* "Repeat heart valve surgery: risk factors for operative mortality". *Journal of Thoracic and Cardiovascular Surgery* 122.5 (2011): 913-918.
6. Bung M., *et al.* "Successful TAVI in Patients with Previous Mitral Valve Replacement". *International Journal of Clinical Medicine* 3.7 (2012): 603-606.
7. Vavuranakis M., *et al.* "TAVI in the Case of Preexisting Mitral Prosthesis: Tips & Tricks and Literature Review". *Journal of Invasive Cardiology* 26.11 (2014): 609-613.
8. Latsios G., *et al.* "TAVI with the self-expandable 29 mm core valve prosthesis in a patient with a metallic mitral valve". *International Journal of Cardiology* 175.1 (2014): e4-e5.
9. García E., *et al.* "Transcatheter aortic valve implantation in patients with a mechanical mitral valve". *Revista Española de Cardiología* 64.11 (2011): 1052-1055.
10. Soon JL., *et al.* "Transapical transcatheter aortic valve implantation in the presence of a mitral prosthesis". *Journal of the American College of Cardiology* 58.7 (2011): 715-721.

Volume 6 Issue 6 June 2019

©All rights reserved by Christos Eftychiou., *et al.*