

## **Paediatric Nasopharyngeal Rhabdomyosarcoma: A Rare Case and Literature Review**

**Iziki O\*, Beghdad M, Rouadi S, Abada R, Roubal M and Mahtar M**

*Department of Otolaryngology Head Neck Surgery, University Hospital Ibn Rochd, Casablanca, Morocco*

**\*Corresponding Author:** Iziki Omar, Department of Otolaryngology Head Neck Surgery, University hospital Ibn Rochd, Casablanca, Morocco.

**Received:** November 29, 2019; **Published:** December 23, 2019

### **Abstract**

Rhabdomyosarcoma (RMS) is the most common soft tissue tumor in children, with the head and neck location accounting for up to 40% of cases. It is a malignant tumor that is characterized by its ability to rapidly grow and infiltrate neighboring structures. The treatment must be quickly undertaken, and relies on the combination of surgery, chemotherapy and radiotherapy.

We report here the case of a 4 years old boy who was diagnosed with nasopharyngeal RMS revealed by unilateral epistaxis and exophthalmia, and whose received surgical treatment before undergoing chemotherapy and radiotherapy.

**Keywords:** *Rhabdomyosarcoma (RMS); Paediatric Nasopharyngeal*

### **Introduction**

Rhabdomyosarcoma (RMS) represents up to 8% of all children tumors and is the most frequent soft tissue tumor in children [1,2]. In 35 to 40% of cases, RMS is localized in the head and neck region, and the nasopharynx is not a rare localization among younger children [1].

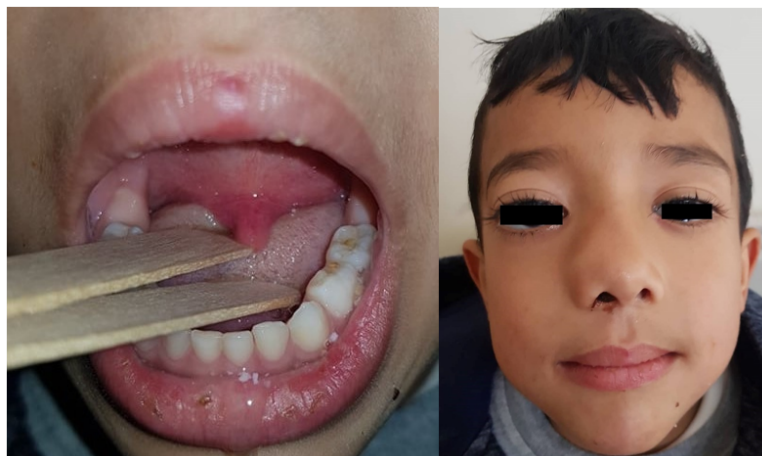As RMS is a highly malignant tumor, its diagnosis must be made promptly, to enable a quick and efficient management. Nasopharyngeal RMS usually causes rhinologic symptoms, including nasal or sinus obstruction, and purulent or blood discharge. As nasopharyngeal RMS can stay asymptomatic for months, it has often already invaded adjacent structures at the time of diagnosis, especially the skull base [3].

### **Case Report**

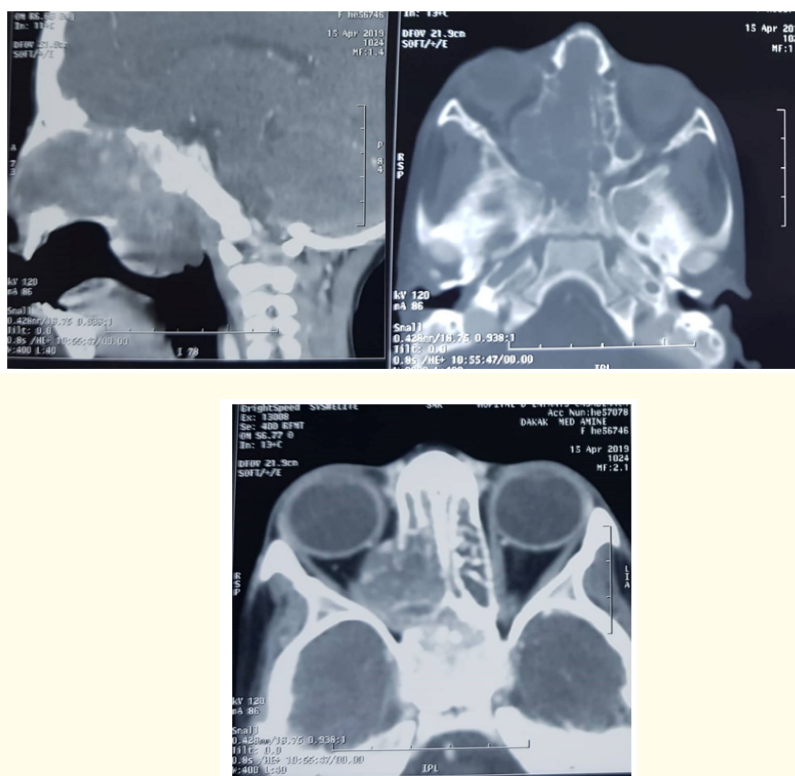
We report the case of a four years old patient, with no prior medical record, who presented to our department with a one-month history of unilateral right epistaxis with nasal obstruction, associated to a swift weight loss and asthenia.

Clinical examination revealed the presence of a voluminous mass which completely filled the right nasal fossa, causing a bulging of the soft palate. The patient also presented with right eye exophthalmia (Figure 1).

Computed tomography (CT) imaging showed a tumor of tissular density, taking up both nasal cavities and the nasopharynx, measuring 30 x 33 x 82 mm. This tumor infiltrated the right nasal cavity, the middle meatus, and both maxillary sinuses, with a lysis of the nasal septum and the turbinates. It was also responsible for the dissolution of the cribriform plate of the ethmoid bone, and reached the ethmoidal labyrinth, whose wall was infiltrated. Intra-orbital infiltration was also noted with a mass affecting the medial and inferior rectus muscles (Figure 2).



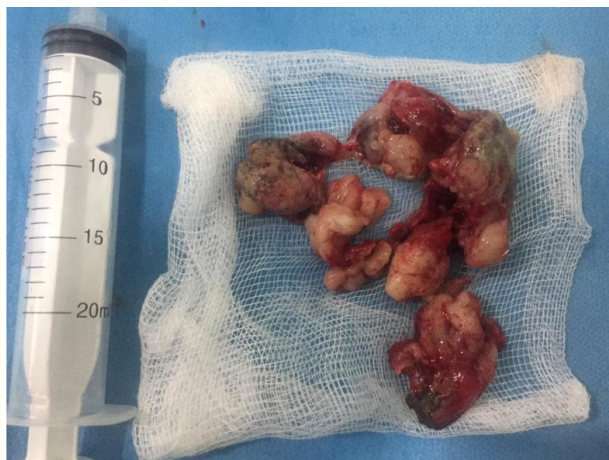**Figure 1:** Images showing the tumor filling the right nasal cavity and causing the soft palate to bulge in the oral cavity.



**Figure 2:** CT images showing the tumor completely invading the nasal cavities, the nasopharynx, and the ethmoid cells, as well as infiltrating the ethmoid bone and the right orbit.

An initial biopsy was realized and suggested a diagnosis of capillary hemangioma.

The patient quickly received surgical treatment, where most of the tumor was removed through endoscopic surgery (Figure 3).



**Figure 3:** Image of the tumour after it was surgically removed.

The final histological diagnosis was that of an embryonal rhabdomyosarcoma.

The patient was then transferred to the hematology department, where he is currently receiving treatment. The chemotherapy protocol used involves Vincristine, Ifosfamide and Dactinomycin. After 3 courses of chemotherapy, the patient will be moved to the radiotherapy department to continue his treatment.

### Discussion

Rhabdomyosarcoma is a highly malignant tumor of childhood arising from the rhabdomyosarcoma of mesenchymal connective tissue it frequently involves the head and neck region as orbit, nasopharynx, cheek, external ear, maxilla, tonsillar area and soft palate [4].

It affects the head and neck in approximately 35 - 40% of cases, he has a bimodal distribution in children, occurring in those aged 2-4 years and 12-16 years [5].

The presentation in the nasopharynx is very rare only few cases have been reported in the literature.

The period of time between the onset of symptoms and diagnosis varied between one week and nine months “average of 13.1 weeks”; this delay in diagnosis may be due to the close similarity of the presenting symptoms with those of adenoidal hypertrophy, common in this age group [6].

The presenting symptoms included nasal obstruction, nasal discharge, upper airway obstruction, symptoms of obstructive sleep apnea, disturbed sleep and snoring.

Physical examination of the head and neck region includes visualization and palpation of the face, scalp, oral cavity and pharyngeal structures, anterior and posterior rhinoscopy, evaluation of cranial nerve function, eye and lymph node examination.

When malignancy is suspected, radiological evaluation and biopsy should be performed as quickly as possible.

Magnetic resonance imaging (MRI) with contrast is thought to be the basic radiological imaging in the diagnosis of RMS of the head and/or neck. It allows one to precisely localize and measure tumor size, evaluate local invasiveness, and visualize metastases to the lymph nodes as well as meninges and brain tissue infiltration. Computed tomography with a contrast is also of great value, especially in evaluation of bone infiltration in the facial cranium and neurocranium. According to some reports positron emission tomography (PET) looks promising in imaging residual tumor mass [7].

Considering the fact that 15% of children with RMS already have distant metastases at the moment of diagnosis [8], it is essential to complete the diagnosis with chest radiograph and/or CT, skeletal scintigraphy.

The actual treatment strategy for RMS of the head and neck is an effect of the revolution in the last 30 years. Until the early 1960s the gold standard was a primary surgical procedure in every case of RMS followed by radiation therapy. Therefore it is not surprising that the survival rate was 5 - 9%.

Surgical excision of the primary RMS with satisfactory cosmetic and functional result is rarely possible. Therefore, the role of surgery is generally confined to biopsy or subtotal excision of residual disease [9].

The preferred radiotherapy technique for pediatric RMS has been sourced from the children's oncology Group (USA): trials ARST 0331, ARST 0431, ARST 0531. Treatment is delivered to the planning target volume (PTV) which is determined as follows: gross tumor volume+1 cm = clinical target volume (CTV). The PTV may vary according to anatomy and respects normal tissue tolerance, especially organs at risk. Lymph nodes are only included if they are pathologically involved. This technique advises radiotherapy doses of 50.4 Gy in 28 fractions at 1.8 Gy per fraction to the isocenter, using 6 MV photons and CT scan planning. Treatment should be once a day, 5 days a week in five and half weeks.

Prognostic factors for RMS arising in the head and neck include anatomical site, tumor size, invasiveness, metastatic spread tumor histology and tumor stage [10].

### Conclusion

In summary, encouraging the early diagnosis and management of nasopharyngeal RMS is of paramount importance to reduce morbidity and mortality. A multimodal treatment involving chemoradiotherapy, and surgery when necessary, must be adopted for optimal therapeutic effectiveness.

### Bibliography

1. Healy JN and Borg MF. "Paediatric nasopharyngeal rhabdomyosarcoma: A case series and literature review". *Journal of Medical Imaging and Radiation Oncology* 54.4 (2010): 388-394.
2. Pappo AS, et al. "A phase II trial of high-dose methotrexate in previously untreated children and adolescents with high-risk unresectable or metastatic rhabdomyosarcoma". *Journal of Pediatric Hematology/Oncology* 19.5 (1997): 438-442.
3. Kazkayasi M and Köybaşoğlu F. "Unusual Brain and Temporal Bone Metastases of a Botryoid Type of Embryonal Nasopharyngeal Rhabdomyosarcoma". *International Journal of Hematology and Oncology* 29.2 (2007): 157-162.
4. Horn RC Jr and Enterline HT. "Rhabdomyosarcoma a clinicopathological study and classification". *Cancer* 11 (1958): 181.
5. Huh WW and Skapek SX. "Childhood rhabdomyosarcoma: new insight on biology and treatment". *Current Oncology Reports* 12.6 (2010): 402-410.

6. Rinaldo F Canalis., *et al.* *Archives of Otolaryngology* 104 (1978).
7. Breitfeld PP and Meyer WH. "Rhabdomyosarcoma : new windows of opportunity". *Oncologist* 10.7 (2005): 518-527.
8. Crist W., *et al.* "The third intergroup Rhabdomyosarcoma study". *Journal of Clinical Oncology* 13 (1995): 610-630.
9. Chien C., *et al.* "Volumetric considerations in radiotherapy for pediatric parameningeal rhabdomyosarcomas". *International Journal of Radiation Oncology, Biology, Physics* 55.5 (2003): 1294-1299.
10. Weiss SW and Goldblum JR. "Rhabdomyosarcoma". 4<sup>th</sup> edition. Mosby, St. Louis, Missouri (2001): 785-835.

**Volume 3 Issue 1 January 2020**

**©All rights reserved by Iziki O., *et al.***