

## Hematocolpos Secondary to Hymenal Imperforation: a Case Report

O Baroud<sup>1\*</sup>, S Mahdaoui<sup>2</sup>, M Serraj<sup>1</sup>, H Boufettal<sup>2</sup> and N Samouh<sup>3</sup>

<sup>1</sup>Resident, Gynecology Department, University Hospital Center Ibn Rochd Casablanca, Morocco

<sup>2</sup>Professor, Gynecology Department, University Hospital Center Ibn Rochd Casablanca, Morocco

<sup>3</sup>Professor, Head of Service, Gynecology Department, University Hospital Center Ibn Rochd Casablanca, Morocco

**\*Corresponding Author:** O Baroud, Resident, Gynecology Department, University Hospital Center Ibn Rochd Casablanca.

**Received:** March 12, 2021; **Published:** March 30, 2021

### Abstract

Hymenal imperforation is a rare and isolated congenital malformation easily diagnosed at birth. It manifests itself at puberty as hematocolpos. The diagnosis is based on the clinic aided by ultrasound and MRI which allows the elimination of associated malformations. In the absence of early treatment, the fertility prognosis may be threatened by certain complications (endometriosis, infection). Treatment is surgical. However, recurrence requires adequate postoperative follow-up.

**Keywords:** Hematocolpos Secondary; Hymenal Imperforation

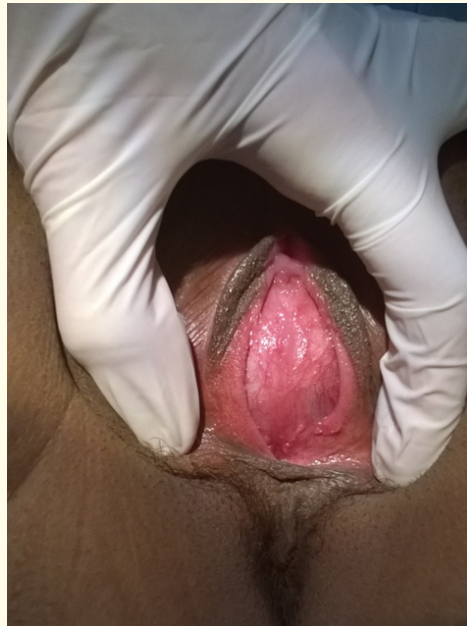### Introduction

Hematocolpos is defined as a collection of menstrual blood in the vagina, by imperforation of the hymen or atresia of the vulvar orifice as part of a malformation of the genitourinary system. We report an observation of a case of hymenal imperforation hospitalized in the gynecology department at the Ibn Rochd Casablanca University Hospital. Through the observation of this case, which has the particularity of being diagnosed at a late age and a review of the literature, we mainly try to focus on the clinical diagnosis at this stage of the evolution without treatment, but also on the paraclinical, the treatment and the prevention of this affection.

### Observation

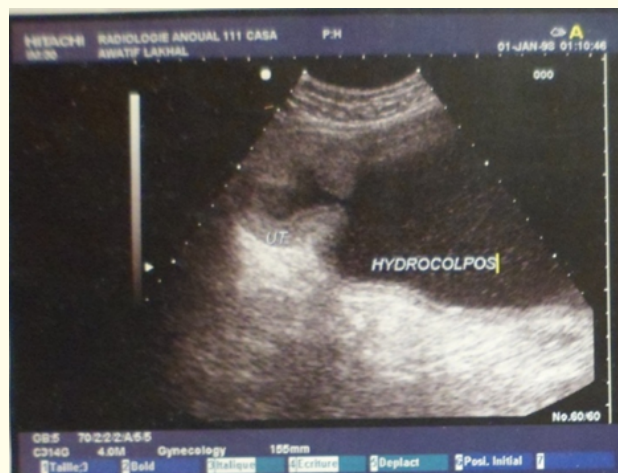A 26-year-old young woman was referred to our Gynecology department by a general practitioner for hypogastric pain developing in a context of apyrexia and maintenance of general condition. The history reveals the notion of primary amenorrhea associated with cyclic pelvic pain that has been evolving over the past 5 years; the patient reports never having had sex.

On physical examination, we palpated a soft abdominopelvic mass, reaching sub-hepatic. Gynecological examination revealed an imperforate, bulging, pale hymen with complete occlusion of the vagina (Figure 1). The urethral opening appeared normal. On the other hand, the secondary sexual characteristics seemed to be normally developed.

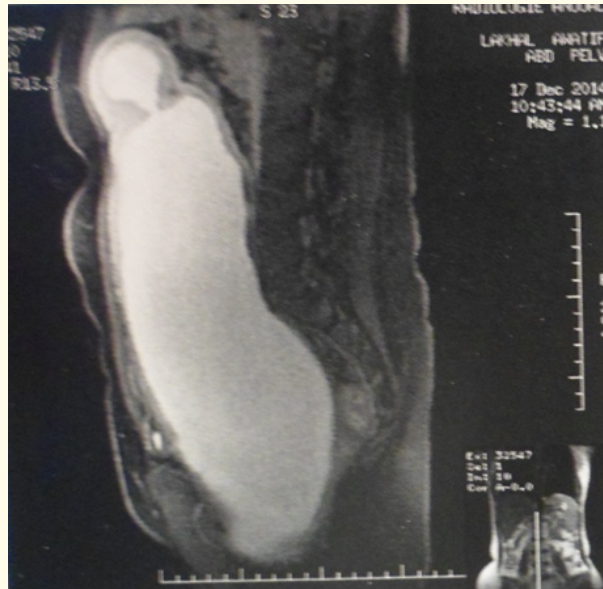

**Figure 1:** Appearance of Imperforate Hymen, With Complete Occlusion of the Vagina.

Pelvic ultrasound showed a large accumulation of fluid in the vagina, measuring approximately 20 cm, reaching up to the right flank (Figure 2), and MRI an oblong, elongated formation, occupying almost the entire pelvis, and the anterior part of the abdomen, arriving suprahepatic, with a thin regular wall, corresponding to a distended vagina, site of blood retention, kidneys without pyelocalicular dilation, without other urogenital malformation (Figure 3).

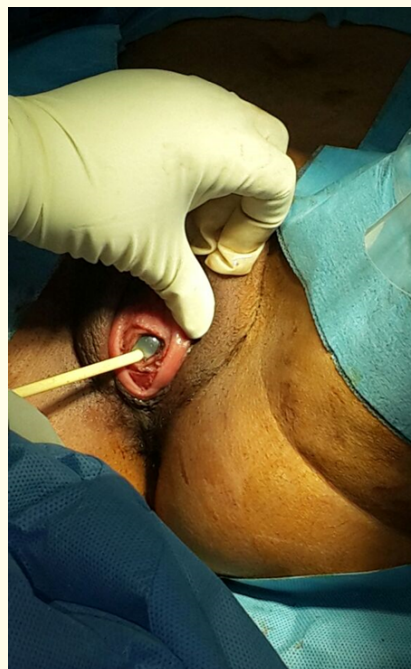


**Figure 2:** Ultrasound Image of Hematocolpos.



**Figure 3:** MRI Image of Hematocolpos.

A vertical hymenotomy was performed under local anesthesia. Marsupialization of the edges of the hymen with Vicryl 4 - 0 is performed for drainage. 1400 ml of chocolate-colored menstrual blood was drained from the vagina after the hymenotomy (Figure 4).



**Figure 4:** Peroperative Image of the Radial Incision at the Level of the Hymen with Eversion of the Edges.

The symptoms disappeared after the procedure. A week later in her follow-up examination, the hymen had thus obtained a central opening of 1 cm in size, and the suprapubic ultrasound revealed normal pelvic anatomy with a vagina gradually recovering its shape. normal size.

### Discussion

The hymen is a remnant of mesodermal tissue that normally perforates during embryonic development.

Hymenal imperforation is the most common obstructive congenital anomaly of the female genital tract with an incidence between 0.01% and 0.05% in newborns [1]. The effect of estrogen secretion by the mother during the prenatal or postnatal period can cause secretion of mucus from the cervical glands [2]. Imperforate hymen, transverse vaginal septum, and vaginal atresia with or without persistence of urogenital cloacal sinus are common causes of secretory hydrometrocolpos [3]. This condition could rarely be diagnosed during the prenatal period during the third trimester ultrasound [4]. Hymen perforation frequently occurs during fetal life or during the perinatal period, but there are reports of spontaneous hymen rupture during the period of adolescence [5].

The clinical presentation of hymenal imperforation is varied ranging from fortuitous discovery, median abdomino-pelvic mass with or without protruding hymen, urinary retention, urinary tract infection, acute renal failure, constipation, acute abdomen with paralytic ileus, primary amenorrhea with cyclic abdominal pain and respiratory distress [6]. Most cases are diagnosed after menarche due to an accumulation of blood in the vagina (hematocolpos) and in the uterus (hematometry). Urological complications have been reported in more than 50% of cases presenting with a complex congenital vaginal malformation, either in the newborn or during puberty [1].

The diagnosis of hymenal imperforation in pubescent adolescent girls must first and foremost be clinical based on the tripod: cyclic pelvic pain, absence of the first menstruation and acute retention of bladder urine. This tripod, once observed, should lead to inspection of the vulva in the gynecological position for a bulging of the vulva and perineum. This bulge is made more visible when a digital rectal exam is performed. However, the use of ultrasound is necessary for several reasons: first, it confirms the hematocolpos in the form of a liquid collection in the vaginal cavity and approximately assesses its quantity; second, she appreciates the impact of hematocolpos in the internal genital tract when she sees hematometry or metrosalpinx; third, she appreciates the impact of hematocolpos on the upper urinary tract when she sees ureterohydronephrosis [7]. Some authors, including Salvat, *et al.* [8], systematically recommend imaging, especially MRI; this has a high sensitivity compared to ultrasound or computed tomography (CT) in the diagnosis of malformations of the genital tract [9].

There is a clear consensus on the surgical treatment of hematocolpos [10-14]. This is a hymenotomy which uses a variety of techniques described by Salvat, *et al.* [8]. A Foley Charrière 18 catheter is placed in the vaginal cavity through the opening of the incision made and the balloon inflated to 10 cm3. It is used to perform a vaginal toilet with physiological serum. It is maintained permanently for 5 days for 2 reasons: firstly to continue the drainage of any metrocolpos suspected on ultrasound; secondly, to direct the healing of the hymenotomy and to leave an orifice after its removal that just admits the pulp of the little finger, now allowing the externalization of the flow of future menstruation. The postoperative period is generally simple with the onset of menstruation within the following 30 days, then on a regular monthly basis as reported by the patients; this is the case for our patient who was followed for 2 years after treatment. However, a subsequent study would be necessary to assess the fertility of these patients [7].

### Conclusion

Early diagnosis of imperforate hymen in adolescent girls is associated with a good prognosis; therefore, a careful examination of the newborn at birth is of utmost importance. Virginity-sparing surgery is a good treatment option for cultural and religious reasons. These same reasons are often the main cause of delayed consultation, as in the case of our patient.

### Bibliography

1. TO Egbe., *et al.* "Virginity-sparing management of hematocolpos with imperforate hymen: case report and literature review". *SAGE Open Medical Case Reports* (2019): 7.
2. G Yildırım., *et al.* "Prenatal diagnosis of imperforate hymen with hydrometrocolpos". *Archives of Gynecology and Obstetrics* 278.5 (2008): 483.
3. A Cerrah Celayir., *et al.* "Spectrum of Etiologies Causing Hydrometrocolpos". *Journal of Neonatal Surgery* 2.1 (2013).
4. « Fetal hydrometrocolpos and congenital imperforate hymen: Prenatal and postnatal imaging features - Garcia Rodriguez – 2018". *Journal of Clinical Ultrasound - Wiley Online Library* (2020).
5. BHH., *et al.* "[Spontaneous rupture of the imperforate hymen in two newborns]". *Archives de Pédiatrie Organe Off. Soc. Francaise Pédiatr* 23.3 (2016): 275-278.
6. RS Ramareddy., *et al.* "Imperforate Hymen: Varied Presentation, New Associations, and Management". *Journal of Indian Association of Pediatric Surgeons* 22.4 (2017): 207-210.
7. K Rimtebaye. "Hematocolpos Revele Par La Retention Aiguë D'urine Vesicale". *Rev. Afr. Urol. Androl.*, 1.8 (2017): 8.
8. D Wirthner., *et al.* "Tissot, « FMC: revue générale », undefined (2008).
9. JD Olpin., *et al.* "MR Imaging of Müllerian Fusion Anomalies". *Magnetic Resonance Imaging Clinics* 25.3 (2017): 563-575.
10. O Al-Hunaidi., *et al.* "Acute urine retention caused by hematocolpos after failed hymenotomy in 23 year old female". *Urology Case Reports* 3.2 (2015): 50.
11. CM Ercan., *et al.* "Imperforate hymen causing hematocolpos and acute urinary retention in an adolescent girl". *Taiwanese Journal of Obstetrics and Gynecology* 50.1 (2011): 118-120.
12. C Clinique. "Hematocolpos cause inhabituelle de retention chronique d'urine chez l'adolescente: a propos d'un cas". *Clinics in Mother and Child Health* 7.1 (2010).
13. J Dennie., *et al.* "Laparoscopic drainage of hematocolpos: a new treatment option for the acute management of a transverse vaginal septum". *Fertility and Sterility* 94.5 (2010): 1853-1857.
14. AB Salem., *et al.* "Masse pelvienne chez une jeune fille: penser à l'hématocolpos". *The Pan African Medical Journal* 17 (2014).

**Volume 4 Issue 4 April 2021**

**© All rights reserved by O Baroud., et al.**