

Platelet Rich Plasma Therapy in Congenital Sensorineural Hearing Loss: A Case Report

Brajpal S Tyagi^{1*} and Mamatarani Rout²

¹*Professor, Head of Department of ENT, Harsh ENT Hospital, Ghaziabad, India*

²*Consultant, Department of ENT, Harsh ENT Hospital, Ghaziabad, India*

***Corresponding Author:** Brajpal S Tyagi, Professor, Head of Department of ENT, Harsh ENT Hospital, Ghaziabad, India.

Received: January 30, 2021; **Published:** April 26, 2021

Abstract

Congenital hearing loss (hearing loss since birth) is one of the most prevalent chronic conditions in children. Hearing loss is a significant public health concern as approximately 0.1 - 0.2% of infants are born deaf or hard-of-hearing. In our case, a two-year-old female child was presented to our institution with a history of congenital hearing loss (Deaf) and inability to speak (Mute). With subsequent evaluation, the child was diagnosed with profound sensorineural hearing loss in both ears, which was confirmed with the BERA report. The child was treated with intra-tympanic platelet rich plasma injections. After appropriate doses for 10 months' duration, significant improvement in hearing was observed.

Keywords: *Platelet Rich Plasma (PRP); Congenital Sensorineural Hearing Loss; BERA; Intratympanic*

Introduction

Sensorineural hearing loss (SNHL) occurs when there is damage to the inner ear (cochlea) or to the nerve pathways from inner ear to brain. Most of the time SNHL cannot be medically or surgically corrected. This is the most common type of permanent hearing loss. Four in every 1000 children suffer from severe to profound hearing loss with over 100,000 babies born with hearing deficiency every year. Congenital SNHL can be due to genetic or non-genetic causes [1-11].

Case Report

A two years old female child was brought to our institution with a history of deaf and mute since birth. The child was not having any relevant past history relating to hearing loss. After taking history, the child was examined in OPD. Otoendoscopy was done which showed normal tympanic membrane in both ears. She was advised for BERA testing. Initial BERA report showed profound hearing loss in both ears with a V wave at 90 dB in the left ear. In the right ear, V wave was not observed beyond 110 dB.

Relevant blood investigation and imaging was done. After counseling the parents, we convinced the parents for intratympanic PRP injection administration for treatment of hearing loss. With consent of parents, we went ahead with injection PRP intratympanic administration in both ears under general anesthesia. Under aseptic precautions, with the help of 22 gauge spinal needle PRP was injected in round window niche in both ears and abgel soaked with PRP was kept on Tympanic membrane. Post injection period child was on antibiotics and analgesic for 3 days and iron supplements with antioxidants for 2 weeks. This procedure was repeated every 2 weeks interval.

Citation: Brajpal S Tyagi and Mamatarani Rout. "Platelet Rich Plasma Therapy in Congenital Sensorineural Hearing Loss: A Case Report". *EC Clinical and Medical Case Reports* 4.5 (2021): 49-54.

After completion of 3rd injection (after 60days), we repeated the BERA. Report was quite satisfactory, showing V wave at 50 db in both ears. So, we continued PRP injections. After 6 sessions of injection PRP in both ears, BERA was done. It showed V wave at 30 dB in left ear and at 50 dB in right ear. By this time, child was already attentive to parents and started saying by-syllables. Speech therapy was advised. Child was consistent with our treatment and speech therapy. After 10months of treatment, the child is able to hear and speak. Throughout the treatment we did not notice any side effects or complications.

1st BERA report

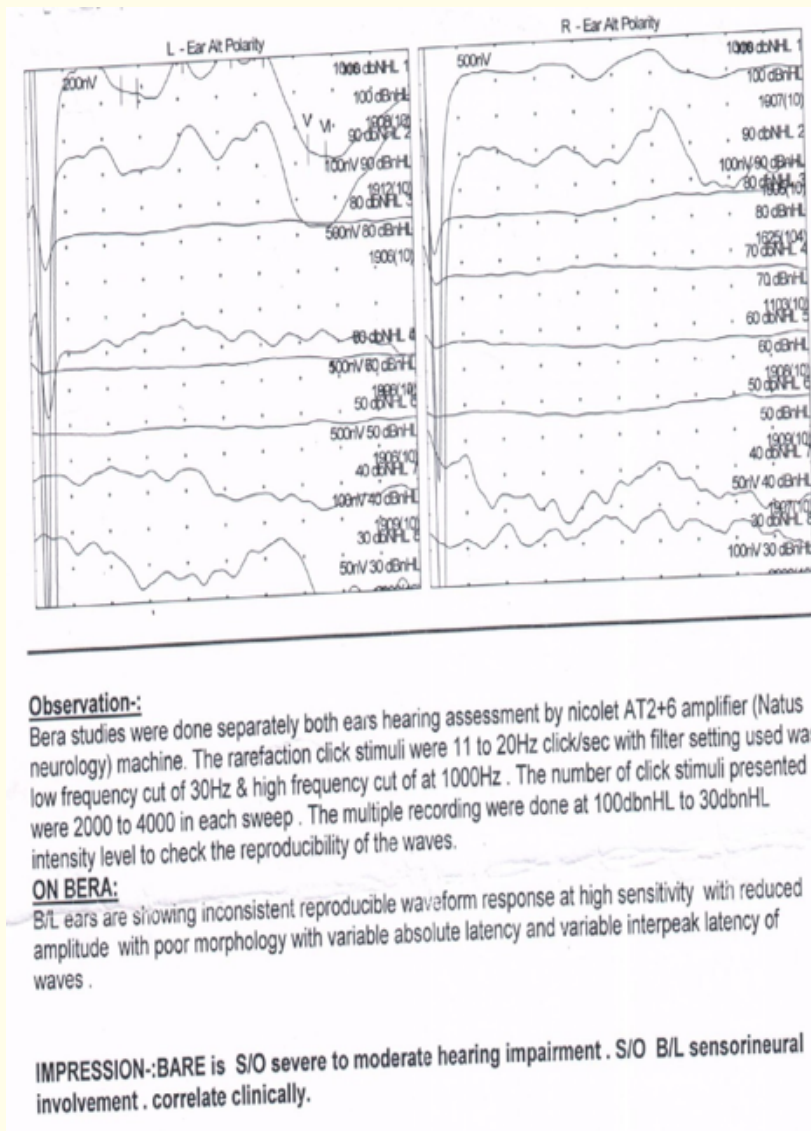


Figure 1

2nd BERA report

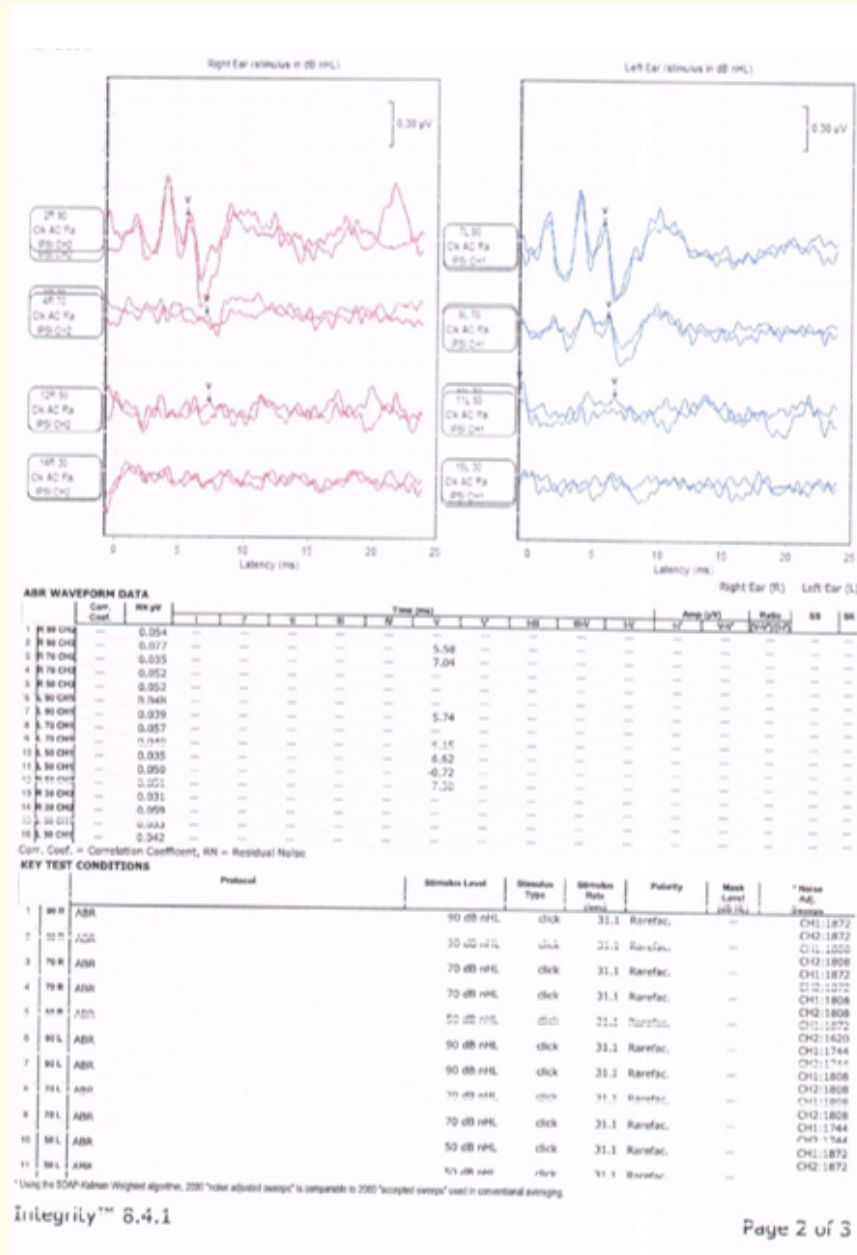


Figure 2

3rd BERA report

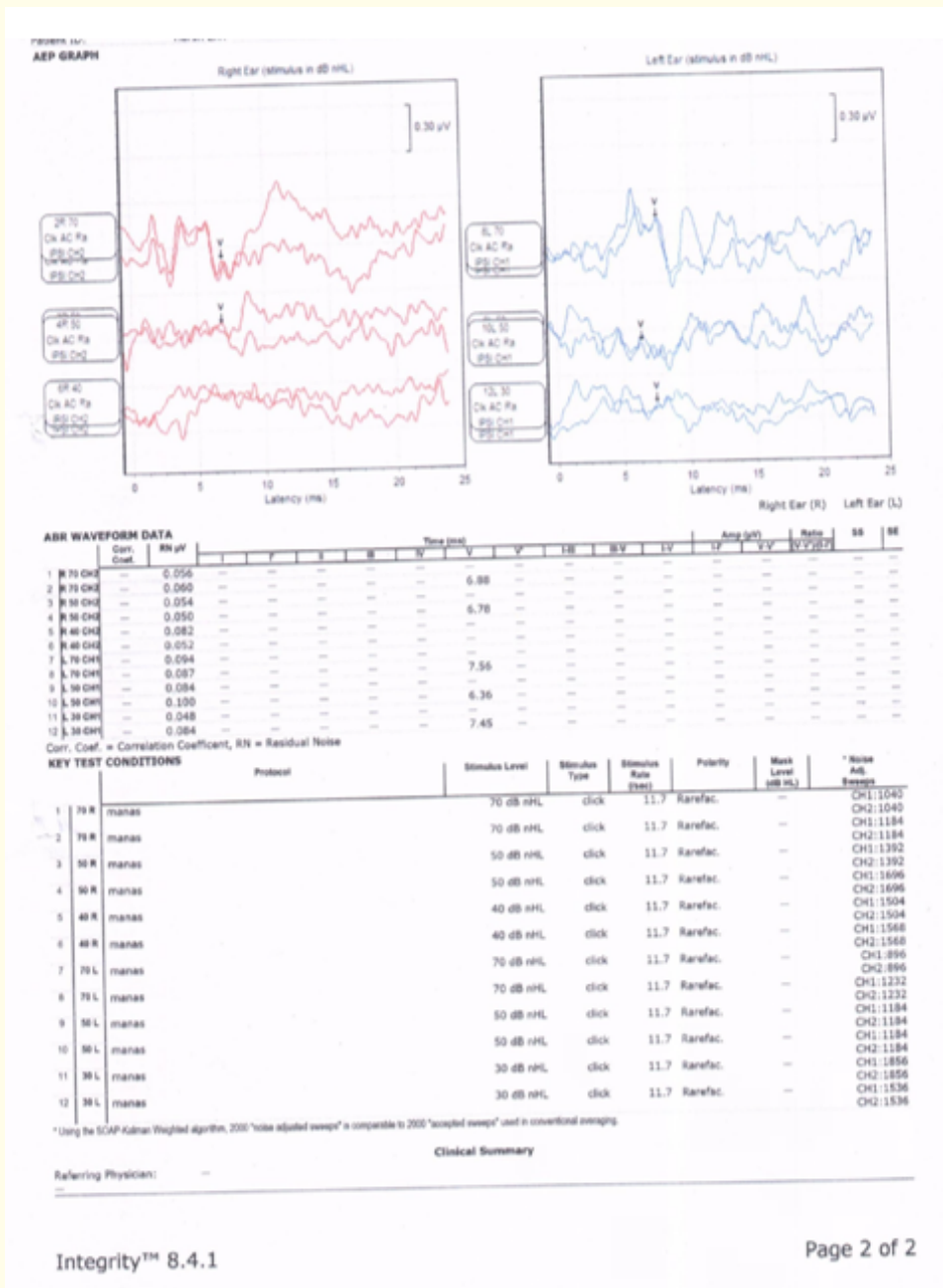


Figure 3

Citation: Brajpal S Tyagi and Mamatarani Rout. "Platelet Rich Plasma Therapy in Congenital Sensorineural Hearing Loss: A Case Report". *EC Clinical and Medical Case Reports* 4.5 (2021): 49-54.

Discussion

Platelet-rich Plasma (PRP) Therapy is an advanced procedure that is transforming the treatment of hearing loss and deafness. Intra-tympanic instillation of Platelet-rich Plasma (PRP) repairs and regenerates the nerves of the inner ear, thus improving the hearing. Platelet rich plasma (PRP) is a form of blood plasma that has been enriched with platelets and growth factors that encourage cellular growth and stimulate healing. Platelet-rich plasma (PRP), also known as autologous conditioned plasma, is a concentrate of platelet-rich plasma protein derived from whole blood, centrifuged to remove red blood cells.

Conclusion

The key to the management of congenital hearing loss is early diagnosis and early intervention. Evaluation of congenital hearing loss starts with newborn hearing screenings with ABRs and includes a thorough history and physical exam, diagnostic imaging, genetic testing and consultation. Treatment with platelet rich plasma therapy combined with speech and language therapy, in an appropriate educational environment, can give excellent result. It is a cost effective treatment with no side effect.

Source of Support

Nil.

Conflict of Interest

None.

Bibliography

1. Ikumi A., *et al.* "Effect of local administration of platelet-rich plasma (PRP) on peripheral nerve regeneration: An experimental study in the rabbit model". *Microsurgery* 38.3 (2018):300-309.
2. Küçük L., *et al.* "Effects of platelet-rich plasma on nerve regeneration in a rat model".
3. Fijnheer R., *et al.* "Platelet activation during preparation of platelet concentrates: a comparison of the platelet-rich plasma and the buffy coat methods". *Transfusion* 30 (1990): 634-638.
4. Dohan Ehrenfest DM., *et al.* "Three-dimensional architecture and cell composition of a Choukroun's platelet-rich fibrin clot and membrane". *Journal of Periodontology* 81 (2010): 546- 555.
5. Akira Ikumi., *et al.* "Intraoperative Local Administration of Platelet-Rich Plasma (PRP) during Neurolysis Surgery for the Treatment of Digital Nerve Crush Injury". *Case Reports in Orthopedics* (2018).
6. José Sidney RoqueI., *et al.* "Inside-out and standard vein grafts associated with platelet-rich plasma (PRP) in sciatic nerve repair" (2017).
7. Ramak Roohipour., *et al.* "The Effect of Panretinal Photocoagulation (PRP) versus Intravitreal Bevacizumab (IVB) Plus PRP on Peripapillary Retinal Nerve Fiber Layer (RNFL)Thickness Analyzed by Optical Coherence Tomography in Patients with Proliferative Diabetic Retinopathy". *Journal of Ophthalmic and Vision Research* 14.2 (2019): 157-163.
8. H B Lu., *et al.* "Experimental study of using chitosan nerve conduit combined with PRP to repair facial nerve defect" (2017): 1496-1500.

9. Luiz Augusto Lucas Martins De Rizzo., *et al.* "Nerve Regeneration: Is There an Alternative to Nervous Graft?". *Journal of Reconstructive Microsurgery* 30.9 (2014): 607-616.
10. Canbin Zheng., *et al.* "Improved Peripheral Nerve Regeneration Using Acellular Nerve Allografts Loaded with Platelet-Rich Plasma". *Tissue Engineering Part A* (2014): 3228-3240.
11. Hakan Teymur., *et al.* "Effect of platelet-rich plasma on reconstruction with nerve autografts". *The Kaohsiung Journal of Medical Sciences* 33.2 (2017): 69-77.

Volume 4 Issue 5 May 2021

© All rights reserved by Brajpal S Tyagi and Mamatarani Rout.